

# Evaluation of Indoleamine 2,3-Dioxygenase (IDO) Expression in Osteosarcoma: Insights From a 10-Year Retrospective Cohort

Asim Farooq<sup>1,2</sup>, Aatif Amin<sup>2</sup>, Shaarif Bashir<sup>3</sup>, Merium Fatima<sup>4</sup>, Muhammad Hassan<sup>1</sup>, Ali Zafar Sheikh<sup>5</sup>, Muhammad Tahseen<sup>3</sup>, Umer Nisar Sheikh<sup>3</sup>, Kashif Asghar<sup>1</sup>

<sup>1</sup>Basic Sciences Research, Shaukat Khanum Memorial Cancer Hospital and Research Centre, Lahore, Pakistan; <sup>2</sup>Department of Microbiology, Faculty of Science and Technology, University of Central Punjab, Lahore, Pakistan; <sup>3</sup>Department of Pathology, Shaukat Khanum Memorial Cancer Hospital and Research Centre, Lahore, Pakistan; <sup>4</sup>Department of Pharmacy, Shaukat Khanum Memorial Cancer Hospital and Research Centre, Lahore, Pakistan; <sup>5</sup>Department of Radiology, Shaukat Khanum Memorial Cancer Hospital and Research Centre, Lahore, Pakistan

Correspondence: Kashif Asghar, Email drkashifasghar@gmail.com

**Introduction:** Osteosarcoma, a prevalent bone malignancy in children and adolescents, is currently treated through surgical resection and chemotherapy. Advancements in cancer research are targeting immune checkpoint molecules, such as indoleamine 2,3-dioxygenase, to advance the development of immunotherapy. However, the scarcity of research on IDO in osteosarcoma results in an absence of comprehensive data, highlighting the conflicting findings surrounding IDO's role in various cancers. Our study aims to explore IDO expression in primary tumors and metastatic lesions among osteosarcoma patients, investigating its association with clinicopathological characteristics and assessing its impact on survival outcomes.

**Methods:** 150 patients diagnosed with osteosarcoma were selected between 2009 and 2019 from the Shaukat Khanum Memorial Cancer Hospital and Research Centre, Lahore, Pakistan. FFPE tissue samples of primary tumors and metastatic lesions were retrieved to conduct immunohistochemical analysis. Moreover, the clinicopathological data of these patients were gathered from the hospital information system.

**Results:** Out of 150 patients, primary tumors were accessible for 134 individuals, while metastatic lesions were available for 49 patients. IDO expression was identified in 9 (6.71%) primary tumors and 2 (4.08%) metastatic lesions among osteosarcoma patients. Furthermore, 3 patients exhibited high expression (27.3%), while 8 displayed low IDO expression (72.7%).

**Conclusion:** Our comprehensive study findings indicate that most osteosarcoma patients do not exhibit expression of IDO. This absence of expression aligns with the characteristic “cold” tumor microenvironment observed in osteosarcoma. Further investigations are imperative to provide deeper insights into the intricacies of this immunomodulatory factor in the context of osteosarcoma.

**Keywords:** osteosarcoma, indoleamine 2, 3-dioxygenase, biomarkers, metastatic lesions, immunohistochemistry

## Introduction

Osteosarcoma, the predominant bone malignancy, primarily affects children and adolescents, with another susceptible group being individuals aged 60 and above.<sup>1-4</sup> Recent data from the US National Cancer Institute's Surveillance, Epidemiology, and End Results (SEER) program reported 3970 new cases of bone and joint cancers, resulting in 2170 deaths.<sup>5</sup> Despite substantial focus on osteosarcoma's epidemiology, prevalence, and prognostic factors,<sup>6-13</sup> a global lack of comprehensive data persists, particularly in regions like Pakistan.<sup>14-16</sup> The current treatment involves surgical resection and chemotherapy, with advanced-stage patients undergoing radiation therapy and metastasectomy for resectable pulmonary disease.<sup>17-20</sup> Despite efforts elevating 5-year survival rates to 70% for localized osteosarcoma, progress remains limited for progressive and metastatic cases.<sup>1,21-26</sup> Clinical trials consistently report lower-than-expected survival rates in metastatic osteosarcoma patients.<sup>25,26</sup>

Osteosarcoma, characterized by significant heterogeneity, manifests a complex immune environment, often termed a “cold” tumor.<sup>27</sup> To enhance immunotherapy’s efficacy, decoding the regulatory mechanisms governing anti-cancer immunity in osteosarcoma is crucial.<sup>28</sup> Recent advancements target immune checkpoint molecules, including potential intervention in indoleamine 2,3-dioxygenase (IDO), a checkpoint protein pivotal in creating an immunosuppressive tumor microenvironment. IDO, an intracellular enzyme catalyzing tryptophan, not only modulates immune responses but also plays a pivotal role in tumorigenesis.<sup>29</sup> IDO catalyzes the breakdown of L-tryptophan into kynurenine and other metabolites, which reduces tryptophan availability and weakens T cell activity. Kynurenine can induce T cell apoptosis and promote immune tolerance by enhancing regulatory T cell (T-reg) differentiation.<sup>29</sup> IDO overexpression in tumors creates an immunosuppressive environment, aiding tumor survival and immune evasion.<sup>29</sup> Dysregulation of IDO expression thus supports tumor progression by contributing to immune suppression and tolerance. The role of IDO has been extensively studied in various cancers including breast cancer, esophageal cancer, endometrial cancer, hepatocellular carcinoma, and pancreatic cancer.<sup>30–34</sup> IDO’s role in osteosarcoma was first reported by Urakawa et al, revealing its impact on clinical outcomes.<sup>35</sup> Recent studies show promise in combining chemotherapeutic agents and IDO inhibitors for osteosarcoma patients.<sup>36,37</sup> However, limited research on IDO in osteosarcoma,<sup>38,39</sup> results in a lack of comprehensive data. Conflicting findings regarding the role of IDO in different cancers and the cell types expressing this immunosuppressive mediator underscore context-dependent, and multi-dimensional mechanisms.<sup>40</sup> Our study aims to explore IDO expression in primary tumors and metastatic lesions among osteosarcoma patients, investigating its association with clinicopathological characteristics and assessing its impact on survival outcomes.

## Material and Methods

### Patients and Data

We conducted a retrospective cross-sectional analysis involving osteosarcoma patients registered at Shaukat Khanum Memorial Cancer Hospital and Research Centre (SKMCH&RC) in Pakistan. The study included 150 patients diagnosed with osteosarcoma between 2009 and 2019. Formalin-fixed, paraffin-embedded (FFPE) blocks of primary tumors and metastatic lesions were sourced from the pathology department at SKMCH&RC. The primary tumors were derived from diagnostic specimens, ensuring that all specimens were treatment-naïve. Analysis was conducted using metastatic lesions from the same patients for whom primary tumors were accessible. Comprehensive patient data, encompassing demographics, pathological and radiological features, and treatment details, were extracted from the electronic medical records system of SKMCH&RC. For survival analysis, patient follow-up continued until January 2024. The study received approval from the institutional review board (IRB) of SKMCH&RC (EX-05-06-23-06), with the IRB granting a waiver of informed consent due to the minimal risk posed to patients’ rights, safety, and well-being, considering the data and FFPE samples were derived from archived records. Our study complies with the declaration of Helsinki.

### IDO Expression Analysis by Immunohistochemistry

FFPE sections of primary tumors and metastatic lesions were cut at a thickness of 4 µm. The immunohistochemical analysis for IDO involved staining with an anti-IDO antibody (Cell Signaling Technology, Massachusetts, the United States; #86630). Heat-mediated epitope retrieval using a Tris-EDTA buffer was performed, and immunoreactivity was detected using the Dako EnVision kit (K5007). Normal reactive human lymph nodes served as a positive control. Slides were deparaffinized, and antigen retrieval was performed concurrently with the target retrieval solution (#GV805 Dako). The visualization of slides was conducted with an optical microscope (Provis AX-70, Olympus, Melville, NY). Two pathologists blindly numerically scored the slides through histopathologic evaluation as described earlier.<sup>33</sup>

### Statistical Analysis

Statistical analysis was carried out using SPSS software (version 26.0; SPSS, Chicago, IL, USA). Percentages (proportions) were used for categorical variables while mean and standard deviation was used for continuous variable. Bivariate analysis was done using chi-square or fisher exact test (when necessary). For continuous explanatory variable such as

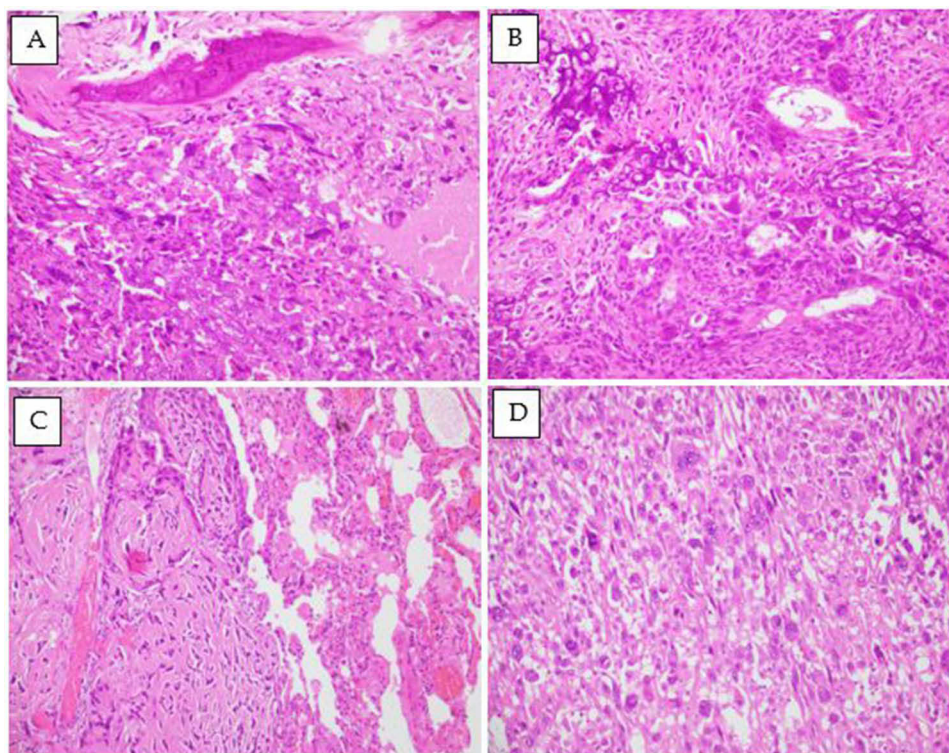
age, one way ANOVA was performed. The Kaplan-Meier method was used to estimate overall survival and survival differences. Statistical significance was defined as a two-tailed p-value of less than 0.05.

## Results

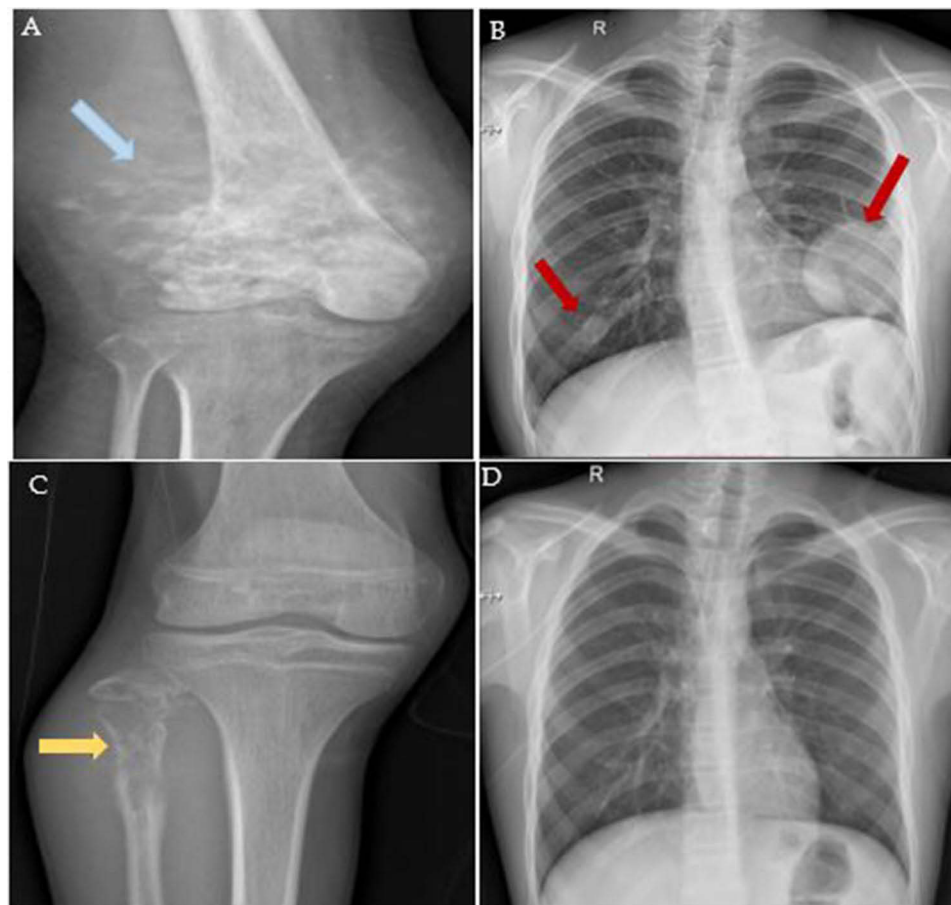
### Clinicopathological Profiles of Osteosarcoma Patients

The average age at the time of osteosarcoma diagnosis was 14 years, with a notable variability of  $\pm 17.66$  years and a wide age range spanning from 6 to 54 years. The study population comprised 60.7% males and 39.3% females. Predominantly, patients diagnosed with osteosarcoma hailed from the Punjab region, followed by Khyber Pakhtunkhwa. Additionally, the study encompassed 22 patients from Afghanistan who were undergoing treatment at SKMCH&RC, highlighting the regional diversity of the patient cohort.

Within the cohort of 150 patients, osteosarcoma emerged as the predominant diagnosis, accounting for 130 cases. Further classification unveiled specific subtypes, including chondroblastic osteosarcoma (n=16), telangiectatic osteosarcoma (n=2), small cell osteosarcoma (n=1), and parosteal osteosarcoma (n=1) among the remaining 20 cases. A histological representation of osteosarcoma primary tumors and metastatic lesions is shown in [Figure 1](#). The radiological depiction of osteosarcoma tumors and metastatic lesions is illustrated in [Figure 2](#). The neutrophil-lymphocyte ratio (NLR) was assessed to evaluate immune responses in patients with osteosarcoma.<sup>41</sup> In our cohort, most patients (n=97) had an NLR within the normal range of 0.7 to 3. Two patients had an NLR below 0.7, while 35 patients exhibited an NLR above 3. There was a significant association between NLR and T-stage of the osteosarcoma patients. However, in this study, we were unable to identify any significant association between NLR and factors such as tumor size, post-chemotherapy necrosis grade, IDO expression, or patient survival ([Supplementary Table 1](#)). In the context of treatment, among the 140 patients who underwent neo-adjuvant chemotherapy, responses exhibited variability. Specifically, 15 patients displayed a grade I response, 84 exhibited a grade II response, and 31 demonstrated a grade III



**Figure 1** Histological representation of primary osteosarcoma tumors and metastatic lesions. **(A)** Fragments of bone with a malignant neoplasm composed of sheets of oval to spindle markedly pleomorphic cells with vesicular nuclei. Areas of necrosis are also noted. (H&E; 20X) **(B)** Sheets of oval to spindle pleomorphic cells with lace-like osteoid formation and tumor giant cells. (H&E; 20X) **(C+D)** Metastatic osteosarcoma in lung: **(C)** Lung alveoli with adjacent sheets of atypical oval cells. **(D)** Few high-grade areas with markedly pleomorphic cells and tumor giant cells. (H&E; 20X).



**Figure 2** Radiological findings of osteosarcoma tumors. (A) a 22-year-old male patient exhibits an aggressive osseous lesion with a calcified soft tissue component at the distal end of the femur, confirmed by biopsy as osteosarcoma (indicated by the blue arrow). (B) the same patient shows pulmonary metastasis evident on the initial radiograph at the time of diagnosis (highlighted by red arrows). (C) displays an 8-year-old male patient with biopsy-confirmed osteosarcoma of the proximal fibula (depicted by the yellow arrow). (D) Remarkably, this patient did not develop pulmonary metastasis even after a 6-year follow-up chest radiograph.

response to chemotherapy. While only 1 patient exhibited a grade IV response, highlighting the range of treatment outcomes within the cohort (Table-1). The median survival duration was 69 months, with corresponding overall survival rates of 62% at three years and 54% at five years (as shown in Figure 3).

### Immunohistochemical Analysis of IDO Expression

Within the cohort comprising 150 patients, FFPE blocks of primary tumors were accessible for 134 individuals, while blocks of metastatic lesions were obtainable for 49 patients. The immunohistochemical analysis revealed IDO expression in 9 (6.71%) patients' primary tumors and 2 (4.08%) patients' metastatic lesions. Out of the 9 patients who exhibited IDO expression in their primary tumors, metastatic lesions were accessible for two patients; however, both displayed no IDO expression in the metastatic sites. Likewise, among the two patients with IDO expression in their metastatic lesions, the primary tumor of one patient was accessible, but it did not demonstrate any IDO expression. Further categorization within the IDO-positive subgroup demonstrated high expression in 3 patients and low expression in the remaining 6 patients. Contrastingly, the majority of the cohort, totaling 125 patients, did not exhibit any discernible expression of IDO, as elucidated in detail in Table 1. We found no association of IDO expression with age, sex, histology or clinical outcome of osteosarcoma patients.

A comprehensive analysis of clinicopathological features in the 11 osteosarcoma patients expressing IDO is shown in Table 2. The majority of the tumors had histology of osteosarcoma while one patient had parosteal osteosarcoma. The absence of pulmonary metastasis at diagnosis is a consistent feature among the cases. The IDO expression levels



**Table 1** Patients and Tumor Characteristics by IDO Low and High

Variables	Characteristics	IDO negative N = 125 (83.3%)	IDO low N = 6 (4.0%)	IDO high N = 3 (2.0%)	P-value
Age (years)					0.40
	Mean $\pm$ SD*	17.1 $\pm$ 7.3	13.8 $\pm$ 2.7	13.8 $\pm$ 4.9	
Gender					0.29
	Male	78 (62.4)	2 (33.3)	2 (66.7)	
	Female	47 (37.6)	4 (66.7)	1 (33.3)	
Diagnosis					0.12
	Parosteal osteosarcoma	-	-	1 (33.3)	
	Small cell osteosarcoma	1 (0.8)	-	-	
	Telangiectatic osteosarcoma	2 (1.6)	-	-	
	Chondroblastic osteosarcoma	15 (12.0)	-	-	
	Osteosarcoma	107 (85.6)	6 (100.0)	2 (66.7)	
Laterality					0.73
	Left	54 (43.2)	4 (66.7)	1 (33.3)	
	Right	64 (51.2)	2 (33.3)	2 (66.7)	
	Unknown	7 (5.6)	-	-	
Size (cm)					0.13
	Mean $\pm$ SD*	11.5 $\pm$ 5.9	6.1 $\pm$ 4.5	11.8 $\pm$ 3.5	
Necrosis grade (post-chemo)					0.29
	1	11 (8.8)	1 (16.7)	1 (33.3)	
	2	72 (57.6)	2 (33.3)	1 (33.3)	
	3	25 (20.0)	2 (33.3)	-	
	4	1 (0.8)	-	-	
	Unknown	16 (12.8)	1 (16.7)	1 (33.3)	
Lymph-vascular invasion					0.63
	Negative	63 (50.4)	2 (33.3)	2 (66.7)	
	Positive	2 (1.6)	-	-	
	Unknown	60 (48.0)	4 (66.7)	1 (33.3)	
pT stage					0.73
	pT0	2 (1.6)	-	-	
	pT1	33 (26.4)	3 (50.0)	1 (33.3)	
	pT2	83 (66.4)	3 (50.0)	2 (66.7)	
	Unknown	7 (5.6)	-	-	
Status					0.97

(Continued)

**Table 1** (Continued).

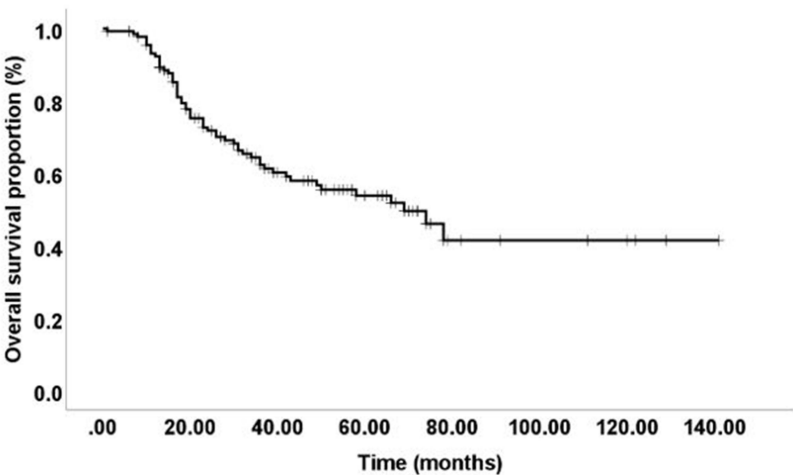
Variables	Characteristics	IDO negative N = 125 (83.3%)	IDO low N = 6 (4.0%)	IDO high N = 3 (2.0%)	P-value
	Alive	42 (33.6)	2 (33.3)	1 (33.3)	
	Death	53 (42.4)	2 (33.3)	1 (33.3)	
	Unknown	30 (24.0)	2 (33.4)	1 (33.4)	

**Notes:** \*Standard deviation. Percentages (proportions) were used for categorical variables while mean and standard deviation were used for continuous variables. Bivariate analysis was done using chi-square or fisher exact test (when necessary). For continuous explanatory variables such as age, one way ANOVA was performed. The Kaplan-Meier method was used to estimate overall survival and survival differences.

demonstrate variability, with cases exhibiting both low and high expressions, as shown in [Figures 4 and 5](#). Interestingly, patient diagnosed with parosteal osteosarcoma, showed high IDO expression while maintaining a status of being alive.

# Discussion

Osteosarcoma is considered as a “cold tumor”, displaying insufficient local immune activation and inadequate recognition of cancer cells, even when immune cells are present within the tumor microenvironment.<sup>42–44</sup> The immune microenvironment in osteosarcoma constitutes a complex system characterized by significant heterogeneity.<sup>45</sup> This complexity facilitates tumor immune escape and tumorigenesis, leading towards metastasis.<sup>45</sup> Understanding and addressing the immune markers is crucial for devising innovative therapeutic strategies to enhance immune responsiveness and counteract the challenges posed by osteosarcoma’s immune microenvironment. Several studies have demonstrated the roles of immune markers in cancer development and progression including osteosarcoma. Among these markers, IDO has been extensively investigated in breast cancer, colorectal cancer, hepatocellular carcinoma, ovarian cancer, head and neck cancers, pancreatic cancer and glioblastomas.<sup>30,33,34,46–48</sup> In the context of cancer, IDO expression and activity have been observed not only in tumor cells but also within the tumor-associated stroma, which includes endothelial cells, immune cells, fibroblasts, and mesenchymal cells.<sup>49</sup> Furthermore, IDO expression has been detected in peripheral blood, highlighting its systemic involvement in immune regulation.<sup>49</sup> Increased IDO expression can be targeted through IDO inhibitors to regulate the immune responses in cancer. Several IDO inhibitors are part of clinical trials as co-therapy of various cancers. These include Epcadostat, Indoximod, KHK2455 and BMS-986205.<sup>50</sup>



**Figure 3** Survival analysis of osteosarcoma patients. The median survival duration of osteosarcoma patients was 69 months. Furthermore, the proportions of overall survival at three and five years were 62% and 54%, respectively.

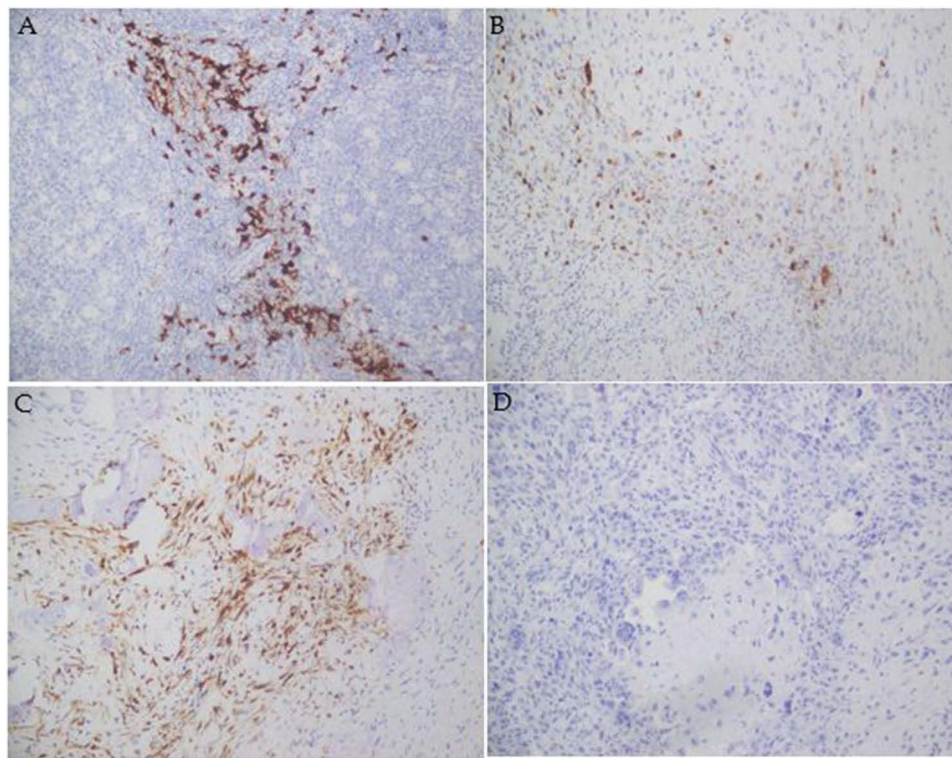
**Table 2** Clinicopathological and Radiological Features of Osteosarcoma Patients With IDO Expression

Case	Gender	Age (Y)	Tumor Site	Histology	Neutrophil Lymphocyte Ratio	Pulmonary Metastasis at Diagnosis	Necrosis Grade (post-chemo)	Status	IDO
01	F	11	Lower Limb	Osteosarcoma	1.81	-ve	2	UNK	Low
02	F	12	Lower Limb	Osteosarcoma	2.18	-ve	2	UNK	Low
03	M	16	Lower Limb	Osteosarcoma	1.70	-ve	1	Alive	Low
04	M	9	Upper Limb	Osteosarcoma	2.14	-ve	UNK	UNK	High
05	F	17	Lower Limb	Osteosarcoma	3.40	-ve	3	Alive	Low
06	F	15	Lower Limb	Osteosarcoma	1.78	-ve	1	Deceased	Low
07	M	14	Lower Limb	Osteosarcoma	2.94	-ve	2	Deceased	High
08	M	11	Upper Limb	Osteosarcoma	1.58	-ve	3	Deceased	Low
09	F	18	Lower Limb	Parosteal Osteosarcoma	2.89	-ve	1	Alive	High
10	M	41	Lower Limb	Osteosarcoma	2.59	-ve	UNK	UNK	Low
11	F	19	Lower Limb	Osteosarcoma	3.25	-ve	1	UNK	Low

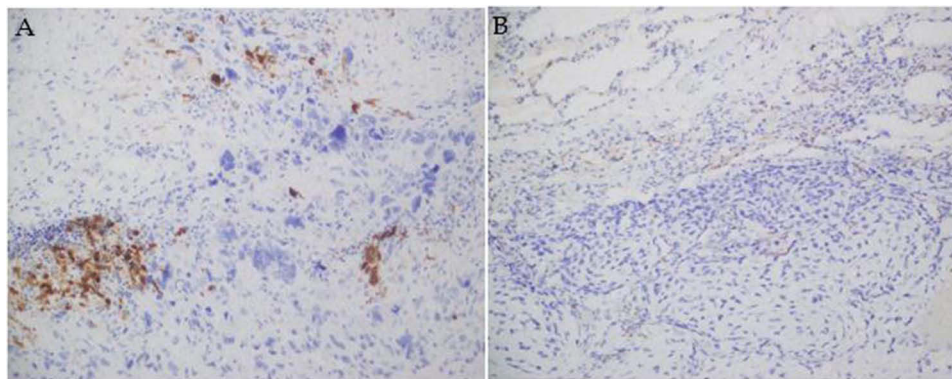
In the current study, we investigated IDO expression in primary tumors and pulmonary metastases of osteosarcoma patients using immunohistochemistry. Intriguingly, most patients did not exhibit IDO expression. Among those expressing IDO, 8 demonstrated low expression levels, while 3 exhibited high expression. Notably, within our dataset, a patient with the highest IDO expression (score =9) was observed to have survived. Toda et al noted comparable IDO expression patterns in their study, with 12 out of 56 osteosarcoma patients exhibiting IDO expression in primary tumors, while 11 patients displayed IDO expression in metastatic lesions.<sup>38</sup> In contrast, Urakawa et al observed a higher prevalence of IDO expression, with 45 out of 47 osteosarcoma patients demonstrating this expression in their cohort.<sup>35</sup> Ligon et al examined IDO expression in tumor-infiltrating lymphocytes (TILs) and discovered elevated levels of IDO expression at the interface of pulmonary metastases, surpassing the levels observed in primary tumors of osteosarcoma patients.<sup>39</sup>

Wu et al observed the poor immune cell infiltration within the microenvironment of osteosarcoma. This deficiency, coupled with diminished T cell activity, a scarcity of immune-stimulating neoantigens, and the existence of various immune-suppressing pathways, collectively converge to dampen the efficacy of immunotherapy responses.<sup>51</sup> They categorized three distinct immune subsets characterized by low (C1), intermediate (C2), and high (C3) levels of immune infiltrate.<sup>51</sup> Tumors with lower immune infiltrate exhibited a scarcity of various immune cell types,<sup>51</sup> indicating an inadequate cell-mediated anti-tumor immune response within the C1 subset of patients. Similarly, Ligon et al demonstrated that the primary osteosarcoma tumors were devoid of meaningful immune infiltrates and were unable to generate effective anti-tumor immune responses.<sup>39</sup>

IDO is an immunoregulatory enzyme which is induced in the tumor microenvironment through spontaneous inflammation and T cell activation.<sup>52</sup> Although IDO suppresses the immune system, the presence of IDO indicates that an immune response was mounted against the tumor. In our cohort, the absence of IDO expression in osteosarcoma patients suggests an impaired ability of the immune system to initiate an anti-tumor response. Conversely, the small subset of patients expressing IDO may signify a more effective anti-tumor immune response. This could be a contributing factor to the survival of one patient with the highest IDO expression in our cohort. In earlier investigations, we identified high IDO expression in patients with breast cancer and hepatocellular carcinoma from Pakistan.<sup>30,33</sup> The variability in IDO expression across diverse solid tumors underscores its context-dependent and multi-dimensional mechanisms. These distinct patient subsets expressing immune markers warrant further investigation to establish personalized immune profiles, paving the way for patient-specific as well as tumor-specific immunotherapies.



**Figure 4** IDO Expression in primary osteosarcoma tumors detected by immunohistochemical staining. Representative images of immunohistochemical staining of IDO in primary tumors of osteosarcoma cases. **(A)** Positive control (normal human reactive lymph node). **(B)** Low IDO expression. **(C)** High cytoplasmic IDO expression. **(D)** Negative expression of IDO. All images were captured at 20X magnification.



**Figure 5** IDO Expression in metastatic lesion of osteosarcoma patients detected by immunohistochemical staining. Representative images of immunohistochemical staining of IDO in metastatic lesions of osteosarcoma cases. **(A)** Low IDO expression. **(B)** Negative expression of IDO. All images were captured at 20X magnification.

Our study has several limitations, primarily being a retrospective cohort study. Resource constraints have restricted our analysis to the expression of a single immune marker through IHC. Nevertheless, it is noteworthy that our study represents the largest cohort to date investigating IDO expression in osteosarcoma patients. Despite the limitations, our findings offer valuable insights into the potential utility of immune markers for identifying patient subsets that may derive benefits from immunotherapies. To advance the field, future studies with larger cohorts and comprehensive panels of immune markers are essential for developing impactful therapeutic strategies tailored to the unique challenges posed by osteosarcoma.

The aim of our study was to explore IDO expression in primary tumors and metastatic lesions among osteosarcoma patients, investigating its association with clinicopathological characteristics and assessing its impact on survival



outcomes. Our findings reveal that IDO is expressed in a limited subset of osteosarcoma patients. To comprehensively understand the immune landscape, it is imperative to explore the expression of a diverse array of immune markers in osteosarcoma patients, laying the foundation for the development of companion diagnostics. This approach holds promise in elucidating unique immune profiles associated with osteosarcoma, ultimately contributing to improved outcomes in the realm of immunotherapies.

## Data Sharing Statement

All data generated or analyzed during this study are included in this article. Further enquiries can be directed to the corresponding author.

## Statement of Ethics

The institutional review board (IRB) of SKMCH&RC approved the current retrospective study (EX-05-06-23-06). The IRB granted waiver for informed consent for this study. The patient data accessed complied with relevant data protection and privacy regulations.

## Author Contributions

All authors made a significant contribution to the work reported, whether that is in the conception, study design, execution, acquisition of data, analysis and interpretation, or in all these areas; took part in drafting, revising or critically reviewing the article; gave final approval of the version to be published; have agreed on the journal to which the article has been submitted; and agree to be accountable for all aspects of the work.

## Disclosure

The authors report no conflicts of interest in this work.

## References

1. Belayneh R, Fourman MS, Bhogal S, Weiss KR. Update on osteosarcoma. *Curr Oncol Rep*. 2021;23(6):71. doi:10.1007/s11912-021-01053-7
2. Mirabello L, Troisi RJ, Savage SA. Osteosarcoma incidence and survival rates from 1973 to 2004: data from the surveillance, epidemiology, and end results program. *Cancer*. 2009;115(7):1531–1543. doi:10.1002/cncr.24121
3. Hansen MF, Seton M, Merchant A. Osteosarcoma in Paget's disease of bone. *J Bone Miner Res*. 2006;21 Suppl 2:P58-63. doi:10.1359/jbmr.06s211
4. Meltzer PS, Helman LJ. New horizons in the treatment of osteosarcoma. *N Engl J Med*. 2021;385(22):2066–2076. doi:10.1056/NEJMra2103423
5. SEER Cancer Stat Facts. Bone and Joint Cancer. National Cancer Institute. Bethesda, MD, Available from: <https://seer.cancer.gov/statfacts/html/bones.html>. Accessed March 06, 2025.
6. Pan Y, Chen D, Hu T, Lv G, Dai Z. Characteristics and prognostic factors of patients with osteosarcoma older than 60 years from the SEER database. *Cancer Control*. 2019;26(1):1073274819888893. doi:10.1177/1073274819888893
7. Wu J, Sun H, Li J, et al. Increased survival of patients aged 0-29 years with osteosarcoma: a period analysis, 1984-2013. *Cancer Med*. 2018;7(8):3652–3661. doi:10.1002/cam4.1659
8. Worch J, Matthay KK, Neuhaus J, Goldsby R, DuBois SG. Osteosarcoma in children 5 years of age or younger at initial diagnosis. *Pediatr Blood Cancer*. 2010;55(2):285–289. doi:10.1002/pbc.22509
9. Mirabello L, Troisi RJ, Savage SA. International osteosarcoma incidence patterns in children and adolescents, middle ages and elderly persons. *Int J Cancer*. 2009;125(1):229–234. doi:10.1002/ijc.24320
10. Wang Z, Wu B, Zhou Y, et al. Predictors of the survival of primary and secondary older osteosarcoma patients. *J Cancer*. 2019;10(19):4614–4622. doi:10.7150/jca.32627
11. Duchman KR, Gao Y, Miller BJ. Prognostic factors for survival in patients with high-grade osteosarcoma using the Surveillance, Epidemiology, and End Results (SEER) program database. *Cancer Epidemiol*. 2015;39(4):593–599. doi:10.1016/j.canep.2015.05.001
12. Cole S, Gianferante DM, Zhu B, Mirabello L. Osteosarcoma: a surveillance, epidemiology, and end results program-based analysis from 1975 to 2017. *Cancer*. 2022;128(11):2107–2118. doi:10.1002/cncr.34163
13. Xu Y, Shi F, Zhang Y, et al. Twenty-year outcome of prevalence, incidence, mortality and survival rate in patients with malignant bone tumors. *Int J Cancer*. 2024;154(2):226–240. doi:10.1002/ijc.34694
14. Tufail M, Wu C. Cancer statistics in Pakistan From 1994 to 2021: data from cancer registry. *JCO Clin Cancer Inform*. 2023;7(e2200142). Erratum in: *JCO Clin Cancer Inform*. 2023 Sep;7:e2300181. doi:10.1200/CCI.22.00142
15. Bhurgri Y, Usman A, Bhurgri H, et al. Primary malignancies of bone and cartilage in Karachi. *Asian Pac J Cancer Prev*. 2009;10(5):891–894.
16. Imtiaz S, Kazmi A. Patterns of care and outcomes of adult osteosarcoma in a tertiary care cancer centre in Pakistan. *J Pak Med Assoc*. 2014;64(10):1166–1170.
17. Gill J, Gorlick R. Advancing therapy for osteosarcoma. *Nat Rev Clin Oncol*. 2021;18(10):609–624. doi:10.1038/s41571-021-00519-8
18. Daw NC, Chou AJ, Jaffe N, et al. Recurrent osteosarcoma with a single pulmonary metastasis: a multi-institutional review. *Br J Cancer*. 2015;112(2):278–282. doi:10.1038/bjc.2014.585

19. Briccoli A, Rocca M, Salone M, Guzzardella GA, Balladelli A, Bacci G. High grade osteosarcoma of the extremities metastatic to the lung: long-term results in 323 patients treated combining surgery and chemotherapy, 1985-2005. *Surg Oncol.* **2010**;19(4):193–199. doi:10.1016/j.suronc.2009.05.002
20. Tsukamoto S, Righi A, Kido A, et al. Effect of adjuvant chemotherapy on periosteal osteosarcoma: a systematic review. *Jpn J Clin Oncol.* **2022**;52(8):896–904. Erratum in: *Jpn J Clin Oncol.* **2022**;52(11):1358. doi:10.1093/jjco/hyac059
21. Isakoff MS, Bielack SS, Meltzer P, Gorlick R. Osteosarcoma: current treatment and a collaborative pathway to success. *J Clin Oncol.* **2015**;33(27):3029–3035. doi:10.1200/JCO.2014.59.4895
22. Smeland S, Bielack SS, Whelan J, et al. Survival and prognosis with osteosarcoma: outcomes in more than 2000 patients in the EURAMOS-1 (European and American Osteosarcoma Study) cohort. *Eur J Cancer.* **2019**;109:36–50. doi:10.1016/j.ejca.2018.11.027
23. Horkoff MJ, Kendal JK, Blackmore C, Truong TH, Guilcher GMT, Brindle ME. A population-based analysis of the presentation and outcomes of pediatric patients with osteosarcoma in Canada: a report from CYP-C. *Can J Surg.* **2022**;65(4):E527–E533. doi:10.1503/cjs.008220
24. Piperno-Neumann S, Ray-Coquard I, Ocean BV, et al. Results of API-AI based regimen in osteosarcoma adult patients included in the French OS2006/Sarcome-09 study. *Int J Cancer.* **2020**;146(2):413–423. doi:10.1002/ijc.32526
25. Lagmay JP, Krailo MD, Dang H, et al. Outcome of patients with recurrent osteosarcoma enrolled in seven phase II trials through children's cancer group, pediatric oncology group, and children's oncology group: learning from the past to move forward. *J Clin Oncol.* **2016**;34(25):3031–3038. doi:10.1200/JCO.2015.65.5381
26. Harris MA, Hawkins CJ. Recent and ongoing research into metastatic osteosarcoma treatments. *Int J mol Sci.* **2022**;23(7):3817. doi:10.3390/ijms23073817
27. Bonaventura P, Shekarian T, Alcazer V, et al. Cold tumors: a therapeutic challenge for immunotherapy. *Front Immunol.* **2019**;10:168. doi:10.3389/fimmu.2019.00168
28. Yu B, Geng C, Wu Z, et al. A CIC-related-epigenetic factors-based model associated with prediction, the tumor microenvironment and drug sensitivity in osteosarcoma. *Sci Rep.* **2024**;14(1):1308. doi:10.1038/s41598-023-49770-2
29. Guo Y, Liu Y, Wu W, et al. Indoleamine 2,3-dioxygenase (IDO) inhibitors and their nanomedicines for cancer immunotherapy. *Biomaterials.* **2021**;276:121018. doi:10.1016/j.biomaterials.2021.121018
30. Asghar K, Loya A, Rana IA, et al. Indoleamine 2,3-dioxygenase expression and overall survival in patients diagnosed with breast cancer in Pakistan. *Cancer Manag Res.* **2019**;11:475–481. doi:10.2147/CMAR.S184221
31. Jia Y, Wang H, Wang Y, et al. Low expression of Bin1, along with high expression of IDO in tumor tissue and draining lymph nodes, are predictors of poor prognosis for esophageal squamous cell cancer patients. *Int J Cancer.* **2015**;137(5):1095–1106. doi:10.1002/ijc.29481
32. Ino K, Yoshida N, Kajiyama H, et al. Indoleamine 2,3-dioxygenase is a novel prognostic indicator for endometrial cancer. *Br J Cancer.* **2006**;95(11):1555–1561. doi:10.1038/sj.bjc.6603477
33. Asghar K, Bashir S, Ali Rana I, et al. PD-L1 is fascinating but IDO needs attention in non-HCV and non-HBV-associated hepatocellular carcinoma patients. *J Hepatocell Carcinoma.* **2023**;10:921–934. doi:10.2147/JHC.S409741
34. Zhang T, Tan XL, Xu Y, Wang ZZ, Xiao CH, Liu R. Expression and prognostic value of indoleamine 2,3-dioxygenase in pancreatic cancer. *Chin Med J (Engl).* **2017**;130(6):710–716. doi:10.4103/0366-6999.201613
35. Urakawa H, Nishida Y, Nakashima H, Shimoyama Y, Nakamura S, Ishiguro N. Prognostic value of indoleamine 2,3-dioxygenase expression in high grade osteosarcoma. *Clin Exp Metastasis.* **2009**;26(8):1005–1012. doi:10.1007/s10585-009-9290-7
36. Fan Q, Zuo J, Tian H, et al. Nanoengineering a metal-organic framework for osteosarcoma chemo-immunotherapy by modulating indoleamine-2,3-dioxygenase and myeloid-derived suppressor cells. *J Exp Clin Cancer Res.* **2022**;41(1):162. doi:10.1186/s13046-022-02372-8
37. Xiang D, Han X, Li J, et al. Combination of IDO inhibitors and platinum(IV) prodrugs reverses low immune responses to enhance cancer chemotherapy and immunotherapy for osteosarcoma. *Mater Today Bio.* **2023**;20:100675. doi:10.1016/j.mtbio.2023.100675
38. Toda Y, Kohashi K, Yamada Y, et al. PD-L1 and IDO1 expression and tumor-infiltrating lymphocytes in osteosarcoma patients: comparative study of primary and metastatic lesions. *J Cancer Res Clin Oncol.* **2020**;146(10):2607–2620. doi:10.1007/s00432-020-03242-6
39. Ligon JA, Choi W, Cojocaru G, et al. Pathways of immune exclusion in metastatic osteosarcoma are associated with inferior patient outcomes. *J Immunother Cancer.* **2021**;9(5):e001772. doi:10.1136/jitc-2020-001772
40. Zhai L, Bell A, Ladomersky E, et al. Immunosuppressive IDO in cancer: mechanisms of action, animal models, and targeting strategies. *Front Immunol.* **2020**;11:1185. doi:10.3389/fimmu.2020.01185
41. Zahorec R. Neutrophil-to-lymphocyte ratio, past, present and future perspectives. *Bratisl Lek Listy.* **2021**;122(7):474–488. doi:10.4149/BLL\_2021\_078
42. Panez-Toro I, Muñoz-García J, Vargas-Franco JW, et al. Advances in osteosarcoma. *Curr Osteoporos Rep.* **2023**;21(4):330–343. doi:10.1007/s11914-023-00803-9
43. Heymann M-F, Lézet F, Heymann D. The contribution of immune infiltrates and the local microenvironment in the pathogenesis of osteosarcoma. *Cell Immunol.* **2019**;343:103711. doi:10.1016/j.cellimm.2017.10.011
44. Heymann M-F, Schiavone K, Heymann D. Bone sarcomas in the immunotherapy era. *Br J Pharmacol.* **2021**;178(9):1955–1972. doi:10.1111/bph.14999
45. Zhu T, Han J, Yang L, et al. Immune microenvironment in osteosarcoma: components, therapeutic strategies and clinical applications. *Front Immunol.* **2022**;13:907550. doi:10.3389/fimmu.2022.907550
46. Tang S, Wang J, Yu S. IDO in colorectal tumorigenesis: involvement of immune tolerance and significance in prevention and therapy. *Cell Mol Gastroenterol Hepatol.* **2021**;12(4):1503–1504. doi:10.1016/j.jcmgh.2021.06.021
47. Lin DJ, Jek N, Huang L, et al. The immunotherapeutic role of indoleamine 2,3-dioxygenase in head and neck squamous cell carcinoma: a systematic review. *Clin Otolaryngol.* **2021**;46(5):919–934. doi:10.1111/coa.13794
48. Zhai L, Bell A, Ladomersky E, et al. Tumor cell IDO enhances immune suppression and decreases survival independent of tryptophan metabolism in glioblastoma. *Clin Cancer Res.* **2021**;27(23):6514–6528. doi:10.1158/1078-0432.CCR-21-1392
49. Meireson A, Devos M, Brochez L. IDO expression in cancer: different compartment, different functionality? *Front Immunol.* **2020**;11:531491. doi:10.3389/fimmu.2020.531491
50. Le Naour J, Galluzzi L, Zitvogel L, Kroemer G, Vacchelli E. Trial watch: IDO inhibitors in cancer therapy. *Oncoimmunology.* **2020**;9(1):1777625. doi:10.1080/2162402X.2020.1777625

51. Wu CC, Beird HC, Andrew Livingston J, et al. Immuno-genomic landscape of osteosarcoma. *Nat Commun.* 2020;11(1):1008. doi:10.1038/s41467-020-14646-w
52. Munn DH, Mellor AL. IDO in the tumor microenvironment: inflammation, counter-regulation, and tolerance. *Trends Immunol.* 2016;37(3):193–207. doi:10.1016/j.it.2016.01.002

### OncoTargets and Therapy

### Publish your work in this journal

OncoTargets and Therapy is an international, peer-reviewed, open access journal focusing on the pathological basis of all cancers, potential targets for therapy and treatment protocols employed to improve the management of cancer patients. The journal also focuses on the impact of management programs and new therapeutic agents and protocols on patient perspectives such as quality of life, adherence and satisfaction. The manuscript management system is completely online and includes a very quick and fair peer-review system, which is all easy to use. Visit <http://www.dovepress.com/testimonials.php> to read real quotes from published authors.

Submit your manuscript here: <https://www.dovepress.com/oncotargets-and-therapy-journal>

**Dovepress**  
Taylor & Francis Group