

Delayed Remote Intracerebral Hemorrhage after Wingspan Stenting for Internal Carotid Artery Stenosis Following the On-Label Usage Guidelines

Jae Ho Kim and Joonho Chung

Department of Neurosurgery, Yonsei University College of Medicine, Seoul, Korea.

Remote intracerebral hemorrhage (ICH) is defined as an ICH that occurs at a distant site from the treated lesion and is a considerable post-neurointerventional complication. Because such a life-threatening complication should not be neglected, we report our experience with delayed remote ICH in a patient with symptomatic intracranial atherosclerotic stenosis (ICAS) treated by Wingspan stenting following on-label usage guidelines. A middle-aged person suffered a lobar-type subcortical hemorrhage on the left temporal lobe 22 days after Wingspan stenting in the left internal carotid artery. The present case seemed to correspond with a previous report in which remote ICH tended to occur as an ipsilateral lobar-type hemorrhage in patients with unruptured intracranial aneurysm on the internal carotid artery undergoing treatment with stents or flow diverters. Delayed remote ICH should be considered as a potential risk of using a Wingspan stent covering the carotid siphon for ICAS.

Key Words: Atherosclerosis, hemorrhage, stenosis, stent

INTRODUCTION

Remote intracerebral hemorrhage (ICH) is defined as an ICH that occurs at a site distant from the treated lesion and is a considerable post-neurointerventional complication.^{1,2} Researchers have indicated that remote ICH after endovascular treatment of unruptured intracranial aneurysms occurs in 0.46% of patients.³ In the SAMMPRIS trial, remote ICH occurred in 3.1% of patients.^{4,5}

Recently, the Wingspan stent (Stryker Neurovascular) for intracranial atherosclerotic stenosis (ICAS) has been found to exhibit a low periprocedural complication rate and excellent safety profile when performed by experienced interventionalists with proper patient selection following on-label usage

guidelines.⁶ However, delayed remote ICH after Wingspan stenting following the on-label usage guidelines has not been reported. Because such a life-threatening complication should not be neglected, we report our experience with delayed remote ICH after Wingspan stenting in a patient with symptomatic ICAS.

CASE REPORT

A middle-aged person presented to our institution because of right sided weakness lasting 10 minutes. On admission, there was one small diffusion restriction on the left frontal lobe (Fig. 1A). Images from magnetic resonance angiography and digital subtraction angiography showed 70% stenosis of the left internal carotid artery communicating segment (Fig. 1B and C). Because the patient's medications included antihypertensive medication, a statin, and aspirin (100 mg), we administered daily clopidogrel (75 mg). The patient was discharged without neurological deficit. Three months later, the patient experienced four episodes of transient right-sided weakness. There was no diffusion restriction, and antiplatelet (P2Y12) resistance testing was within normal range (60–240 PRU). Ten days after the second attack, the patient underwent endovascular treat-

Received: May 28, 2020 **Accepted:** July 4, 2020

Corresponding author: Joonho Chung, MD, PhD, Department of Neurosurgery, Severance Hospital, Yonsei University College of Medicine, 50-1 Yonsei-ro, Seodaemun-gu, Seoul 03722, Korea.

Tel: 82-2-2228-2150, Fax: 82-2-393-9979, E-mail: ns.joonho.chung@gmail.com

•The authors have no potential conflicts of interest to disclose.

© Copyright: Yonsei University College of Medicine 2020

This is an Open Access article distributed under the terms of the Creative Commons Attribution Non-Commercial License (<https://creativecommons.org/licenses/by-nc/4.0>) which permits unrestricted non-commercial use, distribution, and reproduction in any medium, provided the original work is properly cited.

ment for ICAS.

Under general anesthesia, a 2.5×9 mm-sized Gateway (Stryker Neurovascular) was used with step-wised inflation (4 atm, 5 atm, and 6 atm for 30 seconds each). Then, a Wingspan stent (4.0×20 mm) was deployed. Post-operative angiography indicated good patency of the internal carotid artery, and the stent covered the carotid siphon (Fig. 2). The patient was discharged without neurological deficit on the fifth postoperative day.

However, the patient returned with deep drowsy consciousness and right hemiparesis grade 3 on the 22nd postoperative day. On computed tomography scan, there was a lobar-type subcortical ICH on the left temporal lobe (Fig. 3A). We performed ICH catheterization (Fig. 3B). Fourteen days later, the

ICH was well resolved, and 12-month follow-up computed tomography scan showed encephalomalacic change on the left temporal lobe without any other abnormal lesion (Fig. 3C and D). The patient had minimal motor weakness on hand grasping at 12-month clinical follow-up.

DISCUSSION

We report the case of a patient with symptomatic ICAS treated with the Wingspan stent following on-label usage guidelines who experienced delayed remote ICH at 22 days after the procedure. The ICH was lobar type in the subcortical white matter of the ipsilateral temporal lobe. The present case seemed to correspond with previous reports in which remote ICH tended to occur as an ipsilateral lobar-type hemorrhage within 1 week (up to 3 weeks).¹⁻³

In the SAMMPRIS trial,^{4,5} remote ICH occurred in 3.1% (7/224).

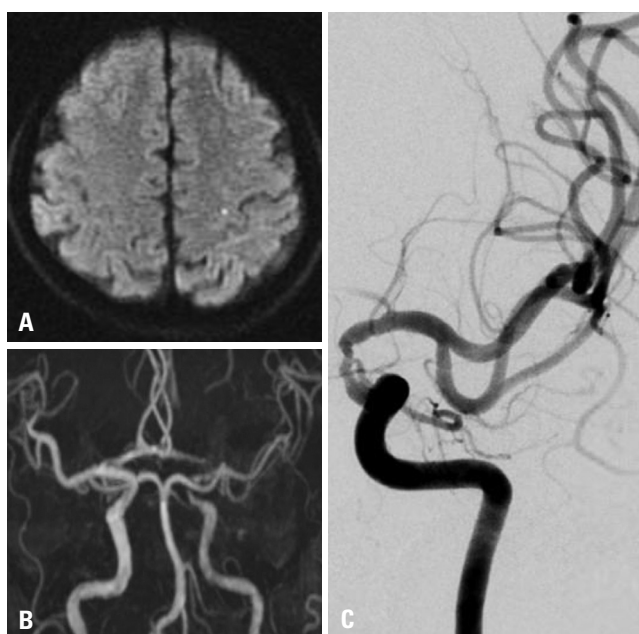


Fig. 1. (A) On the diffusion weighted image, a small high signal intensity lesion on the left frontal lobe indicating acute cerebral infarction is visible. Severe stenosis (70%) is noted in the left internal carotid artery communicating segment on (B) magnetic resonance angiography and (C) digital subtraction angiography.

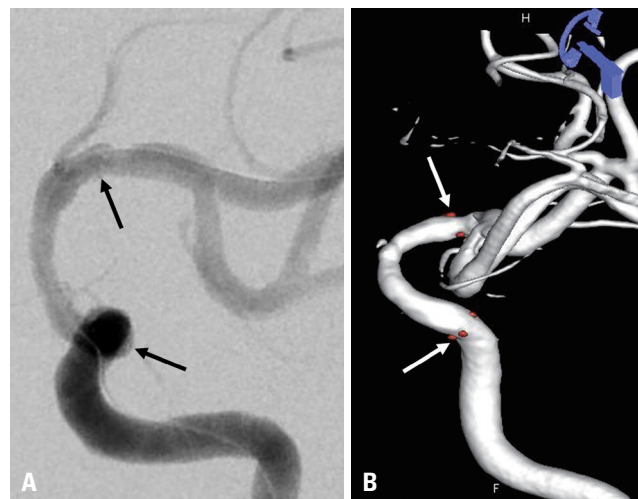


Fig. 2. (A) A Wingspan stent (4.0×20 mm) was deployed. (B) Post-operative three-dimensional reconstructive angiography shows good patency of the internal carotid artery. Arrows indicate the distal and proximal markers of the Wingspan stent covering the carotid siphon.

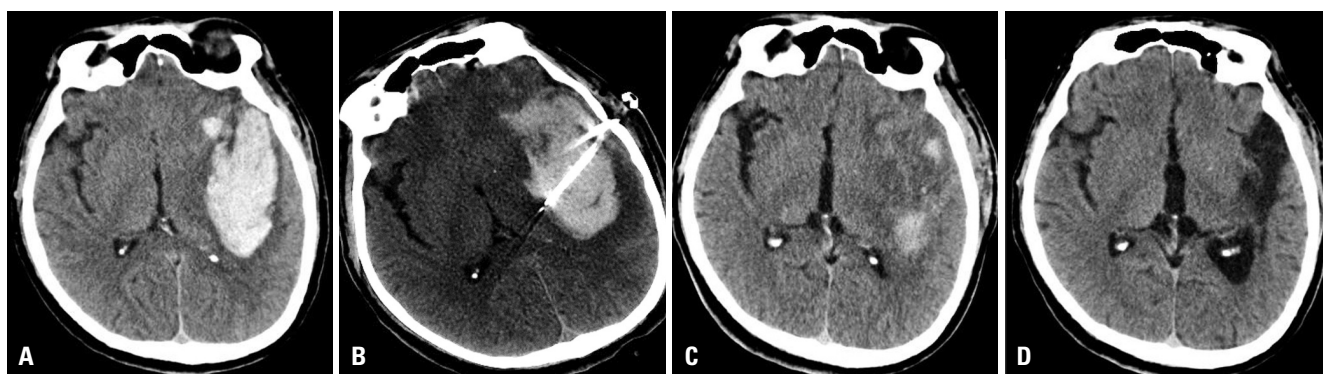


Fig. 3. On a computed tomography scan, (A) a lobar-type subcortical hemorrhage is noted on the left temporal lobe. (B) We performed catheterization for hematoma drainage. (C) Fourteen days later, the hemorrhage was well resolved. (D) On 12-month follow-up, encephalomalacic change (tissue defect) was detected on the left temporal lobe without any other abnormal lesions.

Of the 224 patients randomized to the Wingspan arm, 13 had hemorrhagic strokes. Seven of the 13 were ICH, and all were remote from the stented vessels. Subgroup analysis of the patients with ICH revealed associations with higher degree ICAS, administration of a preoperative clopidogrel loading dose of 600 mg, and high procedural activated clotting time >300 seconds. In the WEAVE trial,⁶ a low periprocedural event rate of intracranial stenting was observed, compared to the SAMMPRIS trial (2.6% vs. 14.7%). Among the 152 patients, they did not report delayed remote ICH after Wingspan stenting, although there was one (0.7%, 1/152) large reperfusion hemorrhage that resulted in death. In the present case, best medical treatment may have been insufficient because the patient had four episodes of transient ischemic attack with right-sided weakness 3 months after the first stroke. However, the present case does correspond with on-label usage guideline. Thus, delayed remote ICH after Wingspan stenting following on-label usage guidelines is possible.

The etiology of this hemorrhage remains unknown. However, the use of any intracranial stent, a coil-assistant stent, a flow diverter, or a Wingspan stent, can be complicated by remote ICH. The mechanism of delayed remote ICH that occurs after endovascular treatment has been explained in several ways.³ First, dual antiplatelet therapy is the most common cause of hemorrhagic complications. The annual risk of major ICH is 1.1–1.8% with dual antiplatelet therapy for secondary stroke prevention.⁷ The present case used dual antiplatelet therapy due to ischemic stroke. Thus, dual antiplatelet therapy could increase bleeding risk and might cause delayed remote ICH. Second, hemorrhagic transformation is another common cause of hemorrhagic complications. However, the present case demonstrated no ischemic lesions on postoperative magnetic resonance images; therefore, hemorrhagic transformation might not have been a true cause of remote ICH. Third, flow modification after intracranial stenting, called the “Windkessel effect,” could cause remote ICH. Reconstruction of the flexible arteries of the carotid siphon with stents could change blood pressure waveforms, thereby creating a larger pulse pressure that increases the pressure transmitted to the distal cerebral arteries.^{1–3,7} A reduced arterial compliance results in a higher systolic peak and a lower diastolic trough in the blood pressure waveform transmitted beyond the segment. This alteration could contribute to remote ICH that occurs in the same vascular distribution of the segment of stent deployment. In the present case, the Wingspan stent covered the carotid siphon, and thus, the Windkessel effect might have contributed to the occurrence of remote ICH.

In conclusion, the present report described a case of delayed remote ICH in a patient with ICAS treated by a Wingspan stent following on-label usage guidelines. This complication should not be neglected and the potential risk of using the Wingspan stent covering the carotid siphon for ICAS should be considered.

AUTHOR CONTRIBUTIONS

Conceptualization: Joonho Chung. **Data curation:** Joonho Chung. **Investigation:** Joonho Chung. **Methodology:** Jae Ho Kim and Joonho Chung. **Project administration:** Joonho Chung. **Resources:** Joonho Chung. **Supervision:** Joonho Chung. **Validation:** Jae Ho Kim and Joonho Chung. **Visualization:** Jae Ho Kim. **Writing—original draft:** Jae Ho Kim. **Writing—review & editing:** Joonho Chung. **Approval of final manuscript:** All authors.

ORCID iDs

Jae Ho Kim <https://orcid.org/0000-0002-6292-5223>
Joonho Chung <https://orcid.org/0000-0003-2745-446X>

REFERENCES

1. Cruz JP, Chow M, O’Kelly C, Marotta B, Spears J, Montanera W, et al. Delayed ipsilateral parenchymal hemorrhage following flow diversion for the treatment of anterior circulation aneurysms. *AJNR Am J Neuroradiol* 2012;33:603-8.
2. Tomas C, Benaissa A, Herbreteau D, Kadziolka K, Pierot L. Delayed ipsilateral parenchymal hemorrhage following treatment of intracranial aneurysms with flow diverter. *Neuroradiology* 2014;56:155-61.
3. Sim SY, Song J, Oh SY, Kim MJ, Lim YC, Park SK, et al. Incidence and characteristics of remote intracerebral hemorrhage after endovascular treatment of unruptured intracranial aneurysms. *World Neurosurg* 2016;95:335-40.
4. Chimowitz MI, Lynn MJ, Derdeyn CP, Turan TN, Fiorella D, Lane BF, et al. Stenting versus aggressive medical therapy for intracranial arterial stenosis. *N Engl J Med* 2011;365:993-1003.
5. Derdeyn CP, Chimowitz MI, Lynn MJ, Fiorella D, Turan TN, Janis LS, et al. Aggressive medical treatment with or without stenting in high-risk patients with intracranial artery stenosis (SAMMPRIS): the final results of a randomised trial. *Lancet* 2014;383:333-41.
6. Alexander MJ, Zauner A, Chaloupka JC, Baxter B, Callison RC, Gupta R, et al. WEAVE trial: final results in 152 on-label patients. *Stroke* 2019;50:889-94.
7. Diener HC, Bogousslavsky J, Brass LM, Cimminiello C, Csiba L, Kaste M, et al. Aspirin and clopidogrel compared with clopidogrel alone after recent ischaemic stroke or transient ischaemic attack in high-risk patients (MATCH): randomised, double-blind, placebo-controlled trial. *Lancet* 2004;364:331-7.