

**Received:** 2012.01.24  
**Accepted:** 2012.04.12  
**Published:** 2012.09.01

**Authors' Contribution:**

- A** Study Design
- B** Data Collection
- C** Statistical Analysis
- D** Data Interpretation
- E** Manuscript Preparation
- F** Literature Search
- G** Funds Collection

## Evaluation of arteriovenous fistulas made with the diamond-shaped anastomosis technique

Muhip Kanko<sup>1ABCEFG</sup>, Cenk Sen<sup>2AC</sup>, Sadan Yavuz<sup>1ACDF</sup>, Cigdem Unal<sup>2E</sup>,  
 Ahmet Aksoy<sup>1BDA</sup>, Turan Berki<sup>1E</sup>

<sup>1</sup> Department of Cardiovascular Surgery, Kocaeli University Faculty of Medicine, Kocaeli, Turkey

<sup>2</sup> Department of Plastic and Reconstructive Surgery, Kocaeli University Faculty of Medicine, Kocaeli, Turkey

**Source of support:** The authors received no financial or other support for this study

### Summary

**Background:**

Obtaining vascular access suitable for long-term use in hemodialysis patients is of utmost importance. In these patients, autogenous methods are generally used for access. There are various techniques for obtaining autogenous access in hemodialysis patients.

**Material/Methods:**

Our objective was to evaluate the outcomes of the “diamond-shaped anastomosis” technique used as a surgical technique during the creation of arteriovenous fistulas in patients with chronic renal failure. We randomly selected and retrospectively examined 67 patients on whom the “diamond-shaped anastomosis” technique had been performed.

**Results:**

We found an 89% patency rate in the 67 randomly selected patients on whom we applied this technique in the early stage (first 6 months).

**Conclusions:**

Maintaining fistula patency in the early postoperative period is important in fistula functioning. The diamond-shaped anastomosis is a simple technique with proven efficiency. This method can be applied in all situations and contributes to postoperative early stage latency.

**key words:**

**diamond • anastomosis technique • arteriovenous fistula**

**Full-text PDF:**

<http://www.medscimonit.com/fulltxt.php?ICID=883337>

**Word count:**

1681

**Tables:**

–

**Figures:**

1

**References:**

20

**Author's address:**

Muhip Kanko, Department of Cardiovascular Surgery, Kocaeli University Faculty of Medicine, 41380, Kocaeli, Turkey, e-mail: muhipkanko@yahoo.com

## BACKGROUND

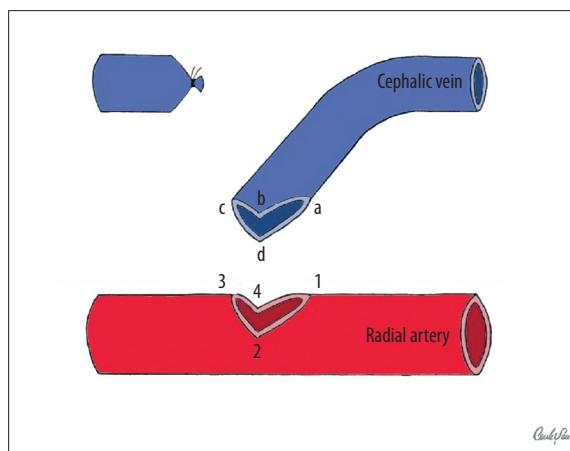
Hemodialysis is one of the most important treatment options in end-stage renal failure patients. There are synthetic and autogenous intervention methods to implement hemodialysis; the best of these methods is autogenous arteriovenous fistulas. There are various factors that affect the long term patency of autogenous arteriovenous fistulas. One of these factors is the different surgical methods used. In this study we examined the fistula cases that we constituted as using the “diamond-shaped anastomosis” technique. Sen et al. obtained successful results using this method in plastic and reconstructive surgery applications [1]. The diamond-shape method has been compared with other methods via geometrical analysis and it has been reported that this method permits more blood flow as compared with other methods of anastomosis [2]. The objective of this study was to compare the success rates of the diamond-anastomosis technique to those of other arteriovenous fistula methods reported in the literature.

## MATERIAL AND METHODS

We retrospectively examined 67 randomly selected cases (33 radiocephalic and 34 brachiocephalic), on whom the “diamond-shaped anastomosis” technique was performed. No radiological examination was used in patient selection before the application of this technique and the patients were selected in a totally randomized fashion. Twenty-three of the patients were females with a mean age of 49.2 (between 38 and 71 years), and 44 were males with a mean age of 55.1 (between 31 and 78 years). The most distal region of the non-dominant arm was used for the first procedure. After the evaluation of the palmar arcus by performing an Allen test before the anastomosis, radiocephalic anastomosis was performed if no fistulas were formed previously.

### Surgical technique

The artery and vein on which the anastomosis was planned to be performed on were prepared and dissected on the non-dominant arm. After determining the site where the anastomosis would be performed, the vein is distally ligated, cut and transposed to the site of anastomosis. Proximal and distal arterial and proximal venular clamps were placed and then a diamond-shaped arteriotomy was done as described by Sen et al. (Figure 1) [1]. Then, the vein to be used for anastomosis was freed and longitudinal venotomy was done. The length (between a-b or a-d) of this incision performed on the vein wall is important as it defines the angle of the anastomosis and the cross-sectional area. The distance between the b and a points in the vein must be equal to that between points 2 and 1 in the arteriotomy. Similarly, the distance between the d and a points in the vein must be equal to that between points 4 and 1 in the arteriotomy. Thereby, the long legs of the diamond arteriotomy are equal to the length of the longitudinal venotomy created. The sum of the distance of each of the b and d points at the vein to point c is equal to the perimeter of the vein. This constitutes the shorter leg of the diamond arteriotomy. The half-perimeter of the vein (between points b and c and points c and d) should be equal to half (between 3 and 2 and between 3 and 4) of the shorter leg of the diamond arteriotomy. Although these requisites might seem complex, they



**Figure 1.** Schematic diagram of end to side arteriovenous fistula creation with diamond technique. The vein is distally ligated with proximal vertical venotomy. Arteriotomy is done in the diamond shape as described in the literature.

can be easily adapted to surgery when geometrical rules are well known. Following arteriotomy, the first procedure is to place single sutures with Prolene 7-0 to 3 corners (from 3 to c; from 4 to d; and from 1 to a) (Fig.1). The objective in placing these sutures at the beginning is to ensure that the corners are seated in harmony with each other. Starting from 3 and c, the suture is continued until arriving at 4 d, then it is affixed to the suture placed in 4d. After this, with the suture placed from 4d, the suture is continued until point a1 and it is affixed to the suture at point a1. Following this, the suture placed at point a1 is continued until point b2. Finally, a new suture is placed between point b and point 2, which is then continued to point c3 to conclude the procedure. Therefore, sutures that do not follow each other were used with 4 different sutures between a1 and d4, between d4 and c3, between c3 and b2, and between b2 and a1. As each suture starts at exactly the right location, additional sutures to eliminate diameter mismatches are not required. Turbulence is reduced in this method as no abrupt difference of diameter occurs between the artery and vein.

## RESULTS

In 1 case (radiocephalic anastomosis) we failed to find any thrill at all after surgery. Severe calcification was observed intraoperatively in the radial artery of this patient. Thrill was found to be positive for the rest of the patients. The patients were observed without any changes in the dialysis protocols during the postoperative period. They were allowed to have hemodialysis from their operated arms on the 3<sup>rd</sup>–4<sup>th</sup> weeks of their surgery. Patency in the arteriovenous fistula was observed in 60 out of 67 patients at 180 days after surgery. Thrombosis was seen in 1 case and 1 patient had hematoma that was drained after diagnosis. Enoxaparin was administered to the patient with calcific radial artery for 3 days postoperatively (4000 anti-XA IU). None of the others received any anticoagulant therapy.

## DISCUSSION

Safe, comfortably accessible, and easily implementable intervention routes are required for hemodialysis. The methods

that fulfill these criteria are autogenous methods of intervention [3]. With their high complication rates and ephemeral nature, synthetic methods are less favored. Complication rates at the end of the first year are reported to be between 33% and 99% in shunt operations performed via synthetic grafts [4]. Autogenous arteriovenous fistulas are methods that have low infection rates, low costs, and lower complication rates, and are easily applicable [5]. Autogenous fistulas are frequently preferred due to the advantages they provide. Although autogenous fistulas have advantages, dysfunction rates at the early period (in the first 1-month period) reach to as high as 29% [6,7]. This rate is reported to be 79% to 94% in the long term [8–13]. In the standard end-to-side slit technique that we applied in the periods before and after this study, the dysfunction rate was 25%, which is consistent with results from the literature.

The most frequently used anastomosis methods used while creating fistulas since the beginning have been side-to-side or end-to-side anastomoses. In performing these anastomoses, arteriotomy and venotomy are generally applied in a slit form. In this type of anastomoses, the rates of remaining patent of anastomoses created in the proximity of the upper extremities are found to be higher than those made in the distal upper extremities. In anastomoses made at the distal upper extremities, (Brescia-Cimino; snuff-box) patency rates in the first 6 postoperative months are reported as 66% and 70%, respectively [7,12,14,15]. In our study the patency rate at the end of the first 6 months was 89%. Thromboses that emerge in fistulas at the early stage negatively affect treatment. The causes of thromboses that evolve at the early stage include the surgical technique used, vasospasm, arterial calcification, unpropitious artery and vein diameters (below 1.5–2 mm), high vein pressure, and external pressure [13,16]. The problems that can emerge while applying the surgical technique include irregularity in the alignment of vascular walls during anastomosis, iatrogenic injury to the intima, accidental suturing from the rear wall, diameter mismatch between the artery and the vein in question, tissue penetration in between the sutures while placing the sutures, and a stretched anastomosis. Apart from these factors, the drop in the blood that flows through the shunt in the early stage is another significant reason for dysfunction. The reason for flow drop is usually hypotension that develops during dialysis and vasospasm. There is a requirement for higher pressure in order to maintain slit arteriotomy patency [1]. When hypotension develops, arteriotomy lips can come next to each other, which may result in a further drop in the flow and cut off fistula flow, in cases in which slit arteriotomy is used. In diamond-shaped anastomosis, arteriotomy lips cannot come exactly next to each other and thus dysfunction is prevented. In end-to-side anastomoses, success generally depends on appropriate application of arteriotomy at the correct location. A sudden change in vessel diameter can result in turbulence, which may cause thrombosis [1,17]. In addition, as vasospasms are reduced in end-to-side anastomoses, flow drop or cessation associated with vasospasm might be prevented in diamond-shaped anastomoses as well [18–20]. In addition, the incisions made and the suturing technique are also important in thrombosis formation. Sutures can be comfortably placed with the diamond technique. Further, because 4 separate sutures are placed, no circular effect on the anastomosis takes places and, as the sutures are made under easy-to-view

conditions, accidental suturing from the rear wall is prevented. Additionally, postoperative hematomas are thus prevented and dysfunction may also be avoided [1].

The bifurcation region is straighter in the diamond technique as compared with the slit technique, which reduces turbulent flow. The wider anastomosis surface in the diamond-shaped anastomosis technique compared to other techniques also increases the flow passing through the fistula [2]. The major reason turbulence emerges in an anastomosis is sudden change of diameter. Sen et al. performed mathematical modeling and calculation of the diamond-shaped anastomosis, finding that the diamond-shaped anastomosis technique increases the surface area of anastomosis, which reduces turbulence. The same study reports that the angle that forms between the artery and the vein is taken as an angle- $\alpha$  and a calculation was made based on that. According to this calculation, when  $\alpha$  is lower than  $60^\circ$ , the anastomosis allows for more flow [1,2].

## CONCLUSIONS

With its flow-related and hemodynamic advantages, diamond-shaped anastomosis is an effective method in reducing fistula dysfunction.

## Acknowledgements.

We thank to Dr. Sen for study of figures.

MK conceived of the study, participated in its design and coordination, and drafted the manuscript. SY participated in the design of the study and performed the statistical analysis. All authors have read and approved the final manuscript.

## Competing interests

The authors declare that they have no competing interests.

## REFERENCES:

1. Sen C, Agir H, Iscen D: Simple and reliable procedure for end-to-side microvascular anastomosis: the diamond technique. *Microsurgery*, 2006; 26(3): 160–64
2. Sen C, Hasanov A: Comparative geometric analysis of diamond and hole techniques in end-to-side microvascular anastomosis. *Microsurgery*, 2008; 28: 262–64
3. Young PR Jr, Rohr MS, Marterre WF: High output cardiac failure secondary to a brachiocephalic arteriovenous fistula. Two cases. *Am Surg*, 1998; 64: 239–41
4. Görmüş N, Özergin U, Özpınar C, Solak H: Vena Cubiti media for creation of a loop-shaped arteriovenous fistula at the elbow region. *Ann Vasc Surg*, 2004; 18(5): 589–92
5. Sands J, Perry M: Where are all the AV fistulas? *Semin Dial*, 2002; 15(3): 146–48
6. Palder SB, Kirkman RL, Whittemore AD et al: Vascular access for hemodialysis. Patency rates and results of revision. *Ann Surg*, 1985; 202: 235–39
7. Fernström A, Hylander B, Olofsson P, Swedenborg J: Long and short term patency of radiocephalic arteriovenous fistulas. *Acta Chir Scand*, 1988; 154: 257–59
8. Bitker MO, Rottembourg J, Mehama R: Early failures in the creation of arteriovenous fistulas for hemodialysis in adults. *Ann Urol*, 1984; 182(2): 98–102
9. Cassiouis D, Fatouros MS, Siamopoulos KC: Short-and long-term evaluation of arteriovenous fistulas for chronic hemodialysis. *Microsurgery*, 1992; 13(5): 236–37

10. Kinnaert P, Vereerstraeten P, Toussaint C, Van Geertruyden J: Nine years' experience with internal arteriovenous fistulas for haemodialysis: a study of some factors influencing the results. *Br J Surg*, 1977; 64(4): 242–46
11. Zerbino VR, Tice DA, Katz LA, Nidus BD: 6 year experience with arteriovenous fistulas and bypasses for hemodialysis. *Surgery*, 1974; 76: 1018–23
12. Nazzal MMS, Neglen P, Naseem J et al: The brachiocephalic fistula: a succesful secondary vascular access procedure. *VASA*, 1990; 19: 326–29
13. Kherlakian GM, Roedersheimer LR, Arbaugh JJ et al: Comparison of autogenous fistula versus expanded polytetrafluoroethylene graft fistula for angioaccess in hemodialysis. *Am J Surg*, 1986; 152: 238–43
14. Gade J, Aabech J, Hansen RI: The upper arm arterio-venous fistula-an alternative for vascular access in haemodialysis. *Scand J Urol Nephrol*, 1995; 29: 121–24
15. Miller PE, Tolwani A, Luscly CP et al: Predictors of adequacy of arteriovenous fistulas in hemodialysis patients. *Kidney Int*, 1999; 56: 275–80
16. Brimble KS, Rabbat ChG, Treleaven DJ, Ingram AJ: Utility of ultrasonographic venous assessment prior to forearm arteriovenous fistula creation. *Clin Nephrol*, 2002; 58: 122–27
17. Lopez-Monjardin H, de la Pena-Salcedo JA: Techniques for management of size discrepancies in microvascular anastomosis. *Microsurgery*, 2000; 20: 162–66
18. Dotson RJN, Bishop AT, Wood MB, Schroeder A: End to end versus end to side arterial anastomosis patency in microvascular surgery. *Microsurgery*, 1998; 18: 125–28
19. Verhelle NAC, Heymans O: How to deal with difficult microsurgical end to side anastomosis. *Microsurgery*, 2005; 25: 203–8
20. Yoleri L, Songur E: Different venous end-to-side microanastomotic techniques: comparative study in a new rat model. *Ann Plast Surg*, 2002; 48: 410–14