

Successful leadless pacemaker retrieval from the left pulmonary artery: A case report



Maria Terricabras, MD, Yaariv Khaykin, MD, FHRS

From the Southlake Regional Health Centre, University of Toronto, Newmarket, Canada.

Introduction

Leadless pacemakers are a common and effective alternative for patients requiring only ventricular pacing,¹ with low major complication rates and fewer long-term complications given the absence of leads and a device pocket.^{2,3}

Situations such as infection, increase in the capture thresholds, or dislodgement may warrant a device retrieval.⁴ Successful retrieval from the septal location has been described using the Micra transcatheter pacing system (TPS) (Medtronic Inc, Minneapolis, MN) introducer sheath, a Micra delivery catheter, or a steerable sheath that allows better alignment with the device and a loop snare.⁵ However, retrieval from high septal locations or the pulmonary artery can be challenging given the lack of support and coaxial positioning. Some clinicians may advocate to abandon the device in the absence of symptoms.

Herein we report the case of a patient with a leadless pacemaker dislodgement to the pulmonary artery and acute respiratory failure.

Case report

An 82-year-old man with history of transcatheter aortic valve replacement for aortic stenosis and symptomatic slow atrial fibrillation and prolonged pauses was referred for a single-chamber pacemaker implant. Given his end-stage chronic kidney disease on hemodialysis, the patient received a Micra leadless cardiac pacemaker (Medtronic Inc) to try to minimize the risk of infection. The device was initially implanted via the right femoral vein at the right ventricular septum with a capture threshold of 2 V @ 0.24 ms, impedance of 610 ohms, and sensing of 5.3 mV. Engagement was confirmed with the pull and hold test, demonstrating 2 of the tines changing morphology as expected with the pull and then resuming their shape.

Less than 1 hour post procedure the patient developed acute respiratory failure and required intubation. The device

KEY TEACHING POINTS

- Dislodgement and embolization of a Micra transcatheter pacing system (TPS) (Medtronic Inc, Minneapolis, MN) is a rare complication that may warrant a device retrieval in some cases.
- Micra TPS can be successfully retrieved from the pulmonary artery using telescoping tools.
- The most challenging part of the procedure is to obtain support and alignment to the right ventricular outflow tract and pulmonary artery.

was interrogated and there was no capture. A chest radiograph confirmed the dislodgement to the left pulmonary artery (PA) (Figure 1).

Percutaneous retrieval was performed from the left femoral vein. The Micra TPS introducer sheath (Medtronic Inc) was used, followed by a steerable Agilis NXT sheath (Abbott Inc, St. Paul, MN). The deflectable sheath provided better support and access to the right ventricular apex and septum. However, in order to reach the outflow tract a multi-purpose catheter over a hydrophilic wire was used to engage the main pulmonary artery. A Whisper MS guide wire (Abbott Inc) was then used to engage the left PA branch, position the multipurpose catheter at its takeoff, and direct a single-loop 8 mm snare that was used to engage the Micra TPS. Given the lack of support in the outflow tract, directing the snare towards the left pulmonary artery was technically challenging. One of the tines was initially engaged, and the Micra TPS was retracted down to the right atrium; however, when the apparatus stretched at the tip of the Micra sheath, it was released. The device embolized, again passing through the tricuspid and pulmonic valves, and was lodged in the same left pulmonary artery. The same exact procedure was repeated, but this time the proximal retrieval feature was engaged and the device was successfully retrieved into the introducer (Figure 2).

Discussion

Acute Micra TPS dislodgement is an uncommon complication. The incidence of leadless pacemaker dislodgements is

KEYWORDS Case report; Dislodgement; Leadless pacemaker; Pacemaker revision; Retrieval
(Heart Rhythm Case Reports 2020;6:798–799)

Funding Sources: The authors have no funding sources to disclose. **Disclosures:** The authors declare no conflicts of interest. **Address reprint requests and correspondence:** Dr Yaariv Khaykin, Southlake Regional Health Centre, 602-581 Davis Dr, Newmarket, Ontario, Canada, L3Y 2P6. E-mail address: YKhaykin@southlakeregional.org.

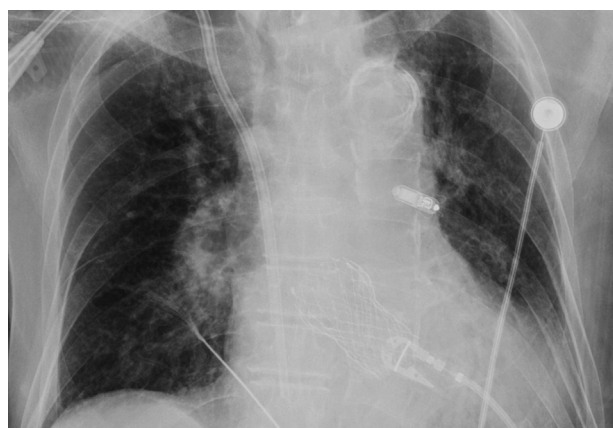

Figure 1 Chest radiograph. The Micra leadless cardiac pacemaker (Medtronic Inc, Minneapolis, MN) is dislodged to the left pulmonary artery.

significantly lower than lead dislodgement with conventional pacemakers. Small studies reported a 0.13% incidence of Micra TPS dislodgement while the reported incidence was higher with Nanostim (1.1%)⁶ (Abbott Inc). The reason for this device dislodgement is unclear. Even though the pacing threshold was suboptimal at 2 V @ 0.24 ms, the location of the Micra TPS and sensing at this location were acceptable and the pull and hold test was successfully performed before the tether was cut.

Micra TPS was designed with a small button on the proximal end of the device to allow a snare to engage it around the waist and then be pulled back into the introducer sheath. Prior to encapsulation of the device, the extraction has been described from the right ventricle⁵ but, to the best of our knowledge, not from the pulmonary artery. The tines could potentially be a target for retrieval from a septal position⁷; however, in this report we could not retrieve the device from the PA when we initially engaged 1 of the tines. An alternative approach could be a second snare used to capture the retrieval feature having first engaged 1 of the tines with the first snare, instead of trying to complete the entire procedure only having snared a tine.

The most challenging part of the procedure was to obtain support and alignment to the right ventricular outflow tract and PA. Effectively, one has to have a workstation maneuver 3 bends: across the tricuspid valve into the right ventricle, from the right ventricle into the PA, and from the main PA into a branch. While no dedicated telescoping tools have yet been developed to enable such an approach, in this report we describe the tools successfully used to accomplish device retrieval.

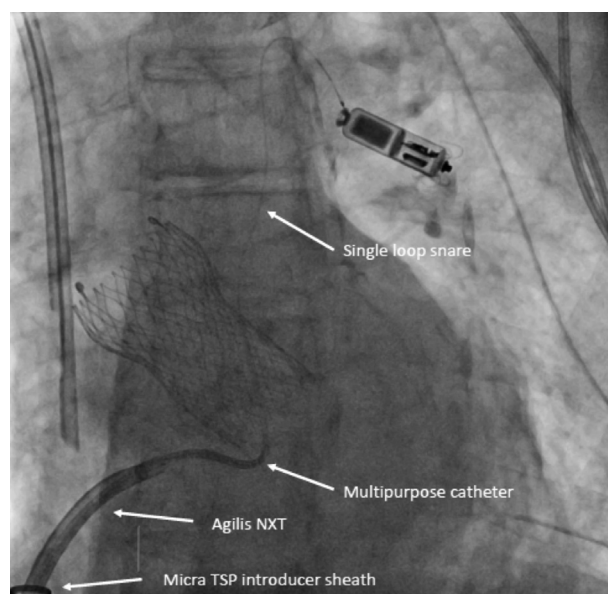


Figure 2 Engagement of the proximal retrieval feature of the Micra transcatheter pacing system (Medtronic Inc, Minneapolis, MN) using the different tools: Micra introducer, steerable sheath, multipurpose catheter, and single-loop snare.

Conclusion

Despite being a rare complication, dislodgement of a Micra TPS and embolization to the pulmonary artery has been described. Retrieving the device can be challenging given the lack of support in the right ventricular outflow tract to direct the snare loop towards the device; however, with the appropriate technique and tools, it can be performed by most implanters.

References

1. Kusumoto FM, Schoenfeld MH, Barrett C, et al. 2018 ACC/AHA/HRS Guideline on the Evaluation and Management of Patients With Bradycardia and Cardiac Conduction Delay: A Report of the American College of Cardiology/American Heart Association Task Force on Clinical Practice Guidelines and the Heart Rhythm Society. *J Am Coll Cardiol* 2019;74:e51–e156.
2. Reynolds D, Duray GZ, Omar R, et al. A leadless intracardiac transcatheter pacing system. *N Engl J Med* 2016;374:533–541.
3. Boveda S, Lenarczyk R, Haugaa KH, et al. Use of leadless pacemakers in Europe: results of the European Heart Rhythm Association survey. *EP Europace* 2018; 20:555–559.
4. Grubman E, Ritter P, Ellis CR, et al. To retrieve, or not to retrieve: System revisions with the Micra transcatheter pacemaker. *Heart Rhythm* 2017;14:1801–1806.
5. Li J, Hou W, Cao M, et al. Safety and efficacy of leadless pacemaker retrieval. *J Cardiovasc Electrophysiol* 2019;30:1671–1678.
6. Wang Y, Hou W, Zhou C, et al. Meta-analysis of the incidence of lead dislodgement with conventional and leadless pacemaker systems. *Pacing Clin Electrophysiol* 2018;41:1365–1371.
7. Karim S, Abdelmessih M, Marieb M, Reiner E, Grubman E. Extraction of a Micra Transcatheter Pacing System: First-in-human experience. *HeartRhythm Case Rep* 2016;2:60–62.