

CASE REPORT

A RARE ASSOCIATION OF MONOSOMY 18p SYNDROME AND POLYGLANDULAR AUTOIMMUNE SYNDROME TYPE IIIA

Dolek-Cetinkaya D*, Demirpence MM, Gorgel A, Salgur F, Bahceci M

***Corresponding Author:** Devrim Dolek Cetinkaya, M.D., Division of Endocrinology, Ataturk Training and Research Hospital, 35020, Izmir, Turkey; Tel.: +90-505-525-1603; Fax: +90-232-243-4848; E-mail: devrimdolek@gmail.com

ABSTRACT

We report a monosomy 18p syndrome in a male patient with polyglandular autoimmune syndrome (PAS) type IIIA. A 34-year-old mentally retarded diabetic male patient with short stature, wide earlaps, old-looking face, straight nasal bone, atrophic mouth, drooping cheeks, full teeth loss, and soft, weak and sparse white hair was admitted to the outpatient endocrinology clinic. Chromosome analysis of the patient revealed 46,XY,del(18)(p11.2). He was also diagnosed with autoimmune thyroiditis, primary hypothyroidism and diabetes mellitus type 1. We concluded that monosomy 18p syndrome may be associated with autoimmune diseases and if this is suspected, patients should be examined for an endocrine deficiency.

Keywords: Monosomy 18p; Type 1 diabetes and hypothyroidism; Growth hormone deficiency; Hypogo-nadotropic hypogonadism.

INTRODUCTION

Monosomy 18p refers to a chromosomal disorder resulting from the absence of all or part of the short arm of chromosome 18. Clinical features typically include mild-to-moderate mental retardation, short stature, round face with short protruding philtrum, palpebral ptosis and large ears with detached pinnae. Cytogenetic analysis is required for diagnosis. The

incidence of the disorder is about 1/50,000. More than 150 patients have been reported worldwide [1,2].

Polyglandular autoimmune syndrome (PAS) type IIIA includes autoimmune thyroiditis with immune-mediated diabetes mellitus. Although growth hormone (GH) deficiency, thyroiditis, juvenile diabetes and other autoimmune disorders have also been reported, there are only a few case reports in the literature about the association of monosomy 18p and PAS type IIIA [3,4].

A male patient with monosomy 18 p together with PAS type IIIA is reported here because of its rare occurrence. Polyglandular autoimmune syndrome type IIIA was diagnosed with features of insulin-dependent diabetes mellitus (IDDM), primary thyroiditis, GH deficiency and hypogonadotropic hypogonadism. The chromosome analysis of the patient revealed 46,XY,del(18)(p11.2).

CASE REPORT

A 34-year-old male patient, diagnosed with IDDM 20 years ago, was hospitalized. The patient had short stature and his face was dysmorphic; body height was 130 cm. The clearly mentally retarded patient was able to sit up when he was 2 and walked when he was 7 years old. The parents of the patient were not consanguineous. His parents looked healthy and their height was normal. Body height of the patient was less than -3 SD (standard deviation) from the mean and his bone age was 12. He had large earlaps and segregated earlobes, old-looking face, straight nasal bone, atrophic mouth and nose structure, drooping cheeks,

* Division of Endocrinology and Metabolism, Ataturk Training and Research Hospital, Izmir, Turkey

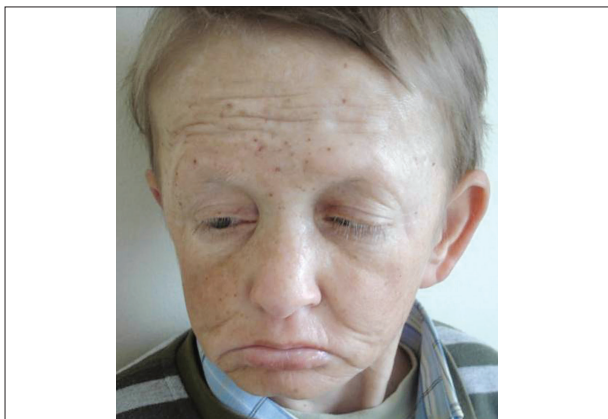


Figure 1. Large earlaps and segregated earlobes, aged looking face, straight nasal bone, atrophic mouth and nose structure, dropped cheeks, groove in upper lip, soft, weak and scarce white hair.

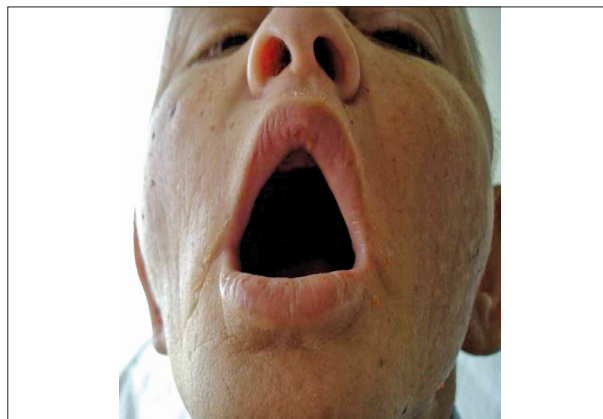


Figure 2. Intense teeth loss.

groove in upper lip, intense teeth loss, soft, weak and sparse white hair. Stage of male genital and pubic hair development, according to Marshall and Tanner, was G1 and P1, respectively. All characteristic findings of the patient are presented in Figures 1 and 2. With these findings, a genetic disorder was suspected and chromosomal analysis was performed. In addition to hypogonadotropic hypo-gonadism, GH deficiency, osteoporosis, primary hypothyroidism, thyroiditis and IDDM were also detected. Hb A_{1c} level was 11.0% (normal range 4.0-6.0%), islet cell antibodies 8, 38 IU/mL (normal range <10 IU/mL) and c-peptide 0, 12 ng/mL (normal range 1, 01-4, 08 ng/mL). Soma-tomedin C (IGF1) level was lower than 25 ng/mL (normal range 90-226 ng/mL). Luteinizing hormone-releasing hormone (LH-RH) test revealed low basal hormone levels and partial LH and follicle-stimulating hormone (FSH) response. The L-dopa and insulin tolerance test demonstrated a GH deficiency. Thyroid function tests were compatible with primary hypothyroidism and thyroid antibody levels were high. Thyroid-stimulating hormone (TSH) was 9.18 μ IU/mL (0, 4-4 μ IU/mL), free tri-iodothyronine (f-T₃) was 2, 12 pg/mL (normal range 1, 57-4, 71 pg/mL) and free-thyroxine (f-T₄) was 0, 71 ng/dL (normal range 0, 8-1, 9 ng/dL), anti thyroglobulin was >500 U/mL (normal range 0-60 U/mL) and anti thyroid peroxidase was >1300 U/mL (normal range 0-60 U/mL).

Bone X-ray did not display dysplasia. There was no significant malformation in prosencephalon structure on magnetic resonance imaging. However, the nose and mouth anomalies in the midportion of the face suggested mild forms of monosomy 18p. Chro-

mosome analysis was performed on standard phytohemagglutinin (PHA)-stimulated blood cultures and the result revealed the following 46,XY,del(18)(p11.2). With these findings, PAS type IIIA and monosomy 18p syndrome was diagnosed in the patient.

DISCUSSION

Monosomy 18 p syndrome is a rare disorder and some autoimmune diseases may accompany the disease. Insulin-dependent diabetes mellitus concomitant occurrence with monosomy 18p syndrome [1] is rarely reported. It can be said that the mechanism of the association between monosomy 18p and IDDM is quite difficult to explain. It has been widely accepted that IDDM is a multifactorial and polygenic disorder with a strong autoimmune basis. The strongest loci so far connected with IDDM are IDDM1 and IDDM2. When the possible relationship and association between these two disorders is considered, a gene(s) on chromosome 18 may also affect the autoimmune process. Dacou-Voutetakis C *et al.* [4] reported a 5-year-old male patient with IDDM and autoimmune thyroiditis and monosomy 18p and they also suggested the relationship between monosomy 18p and IDDM. Our patient has been suffering from IDDM for 20 years, c-peptide was 0.12 ng/mL and islet cell antibodies were 8.38 IU/mL (normal range <10 IU/mL) noted as borderline negative.

In PAS III, autoimmune thyroiditis occurs with another organ-specific autoimmune disease, but the syndrome cannot be classified as PAS I or II. Polyglandular autoimmune syndrome III can be further classi-

fied into three subcategories: one of these sub-groups is PAS IIIA, which includes autoimmune thyroiditis with immune-mediated diabetes mellitus. Polyglandular autoimmune syndrome type IIIA, which is also known as PAS type 3 variant, includes autoimmune thyroiditis with immune-mediated diabetes mellitus [3,4]. In our patient; PAS type IIIA was diagnosed because he had IDDM, primary thyroiditis, and GH deficiency and hypogonadotropic hypogonadism.

Furthermore, GH deficiency may occur together with the disorder. There are rare publications on autoimmune diseases, such as vitiligo and alopecia, accompanying the monosomy 18p mutation; Hashimoto thyroiditis was also very rarely reported [2-6]. In our case, autoimmune thyroiditis, IDDM, GH deficiency and hypogonadotropic hypogonadism were observed together with monosomy 18p syndrome. This genetic mutation, autoimmune thyroiditis and IDDM association was accepted as a noteworthy case regarding the possibility that autoimmune diseases may be accompanied by genetic diseases such as monosomy 18p. We could find a few reported cases with autoimmune PAS type IIIA accompanying monosomy 18p syndrome in the literature online (<http://www.ncbi.nlm.nih.gov>) (3,4). Therefore, this is probably one of the few cases that indicates the association of monosomy 18p and the PAS type IIIA variant. In conclusion, monosomy 18p syndrome may be associated with autoimmune diseases and if this is suspected, patients should also be examined for an endocrine deficiency.

REFERENCES

1. Faust J, Habedank M, Nieuwenhuijsen C. The 18 p-syndrome. Report of four cases. *Eur J Pediatr*. 1976; 123 (1): 59-66.
2. Turleau C. Monosomy 18p review. *Orphanet J Rare Dis*. 2008; 3: 4 doi: 10.1186/1750-1172-3-4.
3. Jain N, Reitnauer PJ, Rao KW, Aylsworth AS, Calikoglu AS. Autoimmune polyendocrinopathy associated with ring chromosome 18. *J Pediatr Endocrinol Metab*. 2011; 24(9-10): 847-850.
4. Dacou-Voutetakis C, Sertedaki A, Maniatis-Christidis M, Sarri C, Karadima G, Petersen MB, *et al*. Insulin dependent diabetes mellitus (IDDM) and autoimmune thyroiditis in a boy with a ring chromosome 18: additional evidence of autoimmunity or IDDM gene(s) on chromosome 18. *J Med Genet*. 1999; 36(2): 156-158.
5. Gluckman PD. Autoimmune thyroiditis in a case of 18p- syndrome. *Aust Paediatr J*. 1977; 13(2): 122-124.
6. Martinez-Mir A, Zlotogorski A, Gordon D, Petukhova L, Mo J, Gilliam TC, *et al*. Genome-wide scan for linkage reveals evidence of several susceptibility loci for alopecia areata. *Am J Hum Genet*. 2007; 80(2): 316-328.

