



Contents lists available at ScienceDirect

## Technical Innovations & Patient Support in Radiation Oncology

journal homepage: [www.sciencedirect.com/journal/technical-innovations-and-patient-support-in-radiation-oncology](http://www.sciencedirect.com/journal/technical-innovations-and-patient-support-in-radiation-oncology)



# Introduction of deep inspirational breath-hold and Butterfly-VMAT techniques into clinical practice for the treatment of mediastinal lymphoma – Lessons learned from an experienced centre

Katie S. Jones<sup>a,\*</sup>, Amanda Webster<sup>a,b</sup>, Georgios Ntentas<sup>c,d</sup>, Jessica L. Brady<sup>e</sup>, N. George Mikhaeel<sup>e</sup>

<sup>a</sup> Department of Radiotherapy, Guy's & St Thomas' NHS Foundation Trust, London, UK

<sup>b</sup> Radiotherapy and PBT, University College London Hospitals NHS Trust, London, UK

<sup>c</sup> Nuffield Department of Population Health, University of Oxford, Oxford UK

<sup>d</sup> Department of Medical Physics, Guy's & St Thomas' NHS Foundation Trust, London, UK

<sup>e</sup> Department of Clinical Oncology, Guy's & St Thomas' NHS Foundation Trust, London, UK

## ABSTRACT

Deep inspiration breath-hold, butterfly volumetric modulated arc therapy and daily imaging techniques for mediastinal lymphoma patients have been introduced in a single department. Whilst introducing these techniques, there were many practical lessons to be learned across the patient pathway, from pre-treatment through to treatment delivery. Therapeutic radiographers were key members of the multi-disciplinary team implementing these techniques. This work reflects on the experience of introducing these advanced techniques for mediastinal lymphoma patients and the lessons learnt.

## Introduction

Guy's Cancer Centre is a leading national centre for the treatment of mediastinal lymphoma. Although cure rates are high in this predominantly young population, these patients are at high risk of radiation-related heart disease and second primary cancers such as lung and breast cancer [1]. The risks are associated with the dose received by organs-at-risk (OAR), such as the heart, lungs and breasts [2]. Therefore, advanced radiotherapy techniques should be considered for these patients.

Deep inspiration breath-hold (DIBH) helps to reduce the dose to the heart and lungs by expanding the lungs and by moving the heart downwards within the mediastinum [3]. DIBH also minimises respiratory motion, permitting a reduction of the PTV margin [4]. Additionally, Butterfly- Volumetric Modulated Arc Therapy (B-VMAT) including partial arcs and an anterior non-coplanar arc over the patient's mediastinum helps avoid treatment through the breasts and lateral parts of the lungs compared to full arc VMAT [5,6]. B-VMAT was first described by Baues et al. [5] and the challenge to combine it with DIBH by Fiandra et al. [7]. Finally, daily cone-beam computed tomography (CBCT) assists the reduction of CTV-PTV margins [8].

This short communication describes a single centre experience in

introducing these techniques and the lessons learnt in the process, with particular focus on the role of the Therapy Radiographer (RTT). The planning and clinical aspects have been already reported by Starke et al. [6].

## Materials & Methods:

Three techniques were implemented consecutively over two years, the first step was introducing DIBH alone, the second step was to introduce B-VMAT in DIBH and finally daily CBCT was introduced to enable CTV to PTV margin reduction. To reflect on the implementation of these advanced techniques the MDT (Multi-disciplinary team) and RTT experience was gathered through informal non-structured interviews and focus groups.

## DIBH introduction

The implementation of DIBH was facilitated by the appointment of a clinical fellow who led the project. They introduced a clinical protocol, obtained clinical governance approval, developed patient-information documentation and assisted with patient selection and consent. DIBH was introduced using surface image guidance using AlignRT®. The

\* Corresponding author.

E-mail address: [katie.jones98@nhs.net](mailto:katie.jones98@nhs.net) (K.S. Jones).

<https://doi.org/10.1016/j.tipsro.2022.04.002>

Received 12 January 2022; Received in revised form 22 February 2022; Accepted 5 April 2022

2405-6324/© 2022 Published by Elsevier B.V. on behalf of European Society for Radiotherapy & Oncology. This is an open access article under the CC BY-NC-ND license (<http://creativecommons.org/licenses/by-nc-nd/4.0/>).

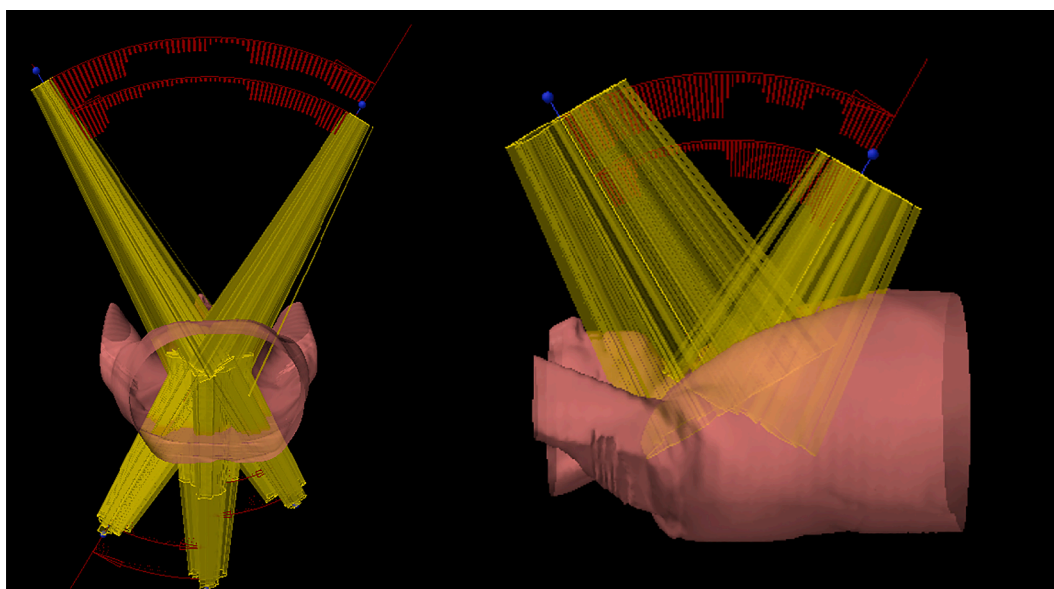


Fig. 1. Butterfly-VMAT beam arrangement of the 6 axial arcs (left panel) and the 2 cranio-caudal arcs (right) for a mediastina lymphoma patient.

technique was already being used for the treatment of left-sided breast cancer in the department, but was modified for mediastinal lymphoma, with the main difference in the definition of volume of interest (VOI). RTT training was provided, and the treatment was implemented.

Patients requiring curative mediastinal RT were considered for treatment in DIBH depending on disease distribution. In the initial phase, only patient with disease limited to the mediastinum and the lower neck were considered. The treatment was explained to patients by the consenting doctor in clinic and the information sheet was provided to them. Patients were advised to practise holding their breath at home. On the day of the treatment planning scan, patients were seen by pre-treatment RTTs; given a full consultation on the technique and then coached to hold their breath. Their ability to take a deep breath for 30 s and the reproducibility of the breathing trace was tested on the CT couch. The breath should be non-erratic, and the patient should breathe up to the same point every time, this point is marked on the chest in marker pen for reference with the set up laser. Initially patients were given a tablet in order to assist them in the coaching process for breath-hold. However, the tablet was removed as patients found it off-putting. Verbal coaching and support by the RTTs was preferred. If a consistent breathhold is achieved, this is tracked on treatment through the use of the AlignRT® surface guided system to ensure reproducibility. If the patients breathing trace was not reproducible or if the patient displayed signs of discomfort while holding their breath, i.e. pitch, roll or lifting of the shoulders, coaching was utilised. If issues could not be rectified with coaching, patients were not treated in DIBH.

With more experience, patient selection was extended also to those with upper neck disease involvement. Consequently, there was a need to explore more immobilisation options considering variability in tumour location. Thus, there are a variety of options for all patients including:

- o Thoracic board, arms up for mediastinal disease.
- o Three-point headshell with shoulder support for treatment to the mediastinum, axilla, and above the larynx.
- o Five-point head and shoulder thermoplastic shell for superior neck and mediastinal disease.
- o Breast board, arms down for female patients with larger breasts.

#### B-Vmat

The B-VMAT technique involves 8 partial arcs; 6 axial arcs (30 – 60°) and 2 cranio-caudal 60° arcs delivered with 90° couch rotation as shown

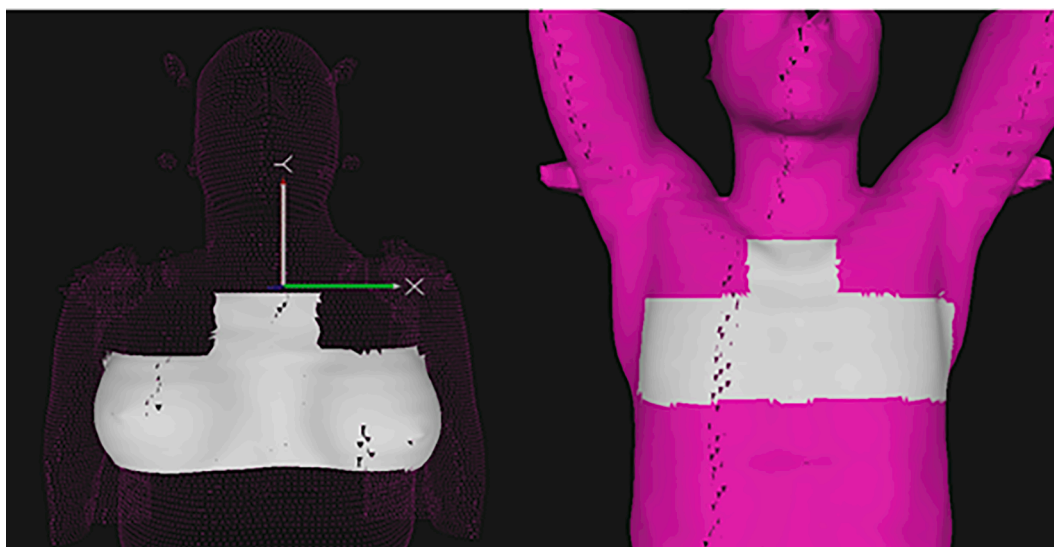
in Fig. 1. Each is delivered with a separate DIBH and checking of surface anatomy with AlignRT®. The possibility to shorten the delivery time using the automation TrueBeam function was assessed. This approach was only suitable and safe if the breath-hold system being utilised immediately stopped the treatment beam when the patient exhales. To do this, AlignRT® was upgraded to introduce the motion management interface (MMI), which enabled the surface guided system to halt the treatment beam if the tolerance threshold was broken. A 0.5 cm and 3-degree rotational tolerance was set, and if breached treatment was paused. This tolerance was defined by the 0.5 cm CTV to PTV margin utilised for patients in DIBH. The delivery of the non-coplanar cranio-caudal arcs of B-VMAT requires a couch angle of 90°. Thus, to prevent collision with the gantry a shorter hand pole was required for the thoracic board.

#### Daily CBCT

Initially, the treatment verification for mediastinal DIBH treatment was limited to kilovoltage (kV) orthogonal pair imaging, taken for the first three fractions, and once per week thereafter. This was in line with minimum IGRT guidelines [9]. With departmental experience in the use of CBCT for other treatment sites increasing, an updated imaging protocol for all radical patients was introduced utilising daily online CBCT imaging with all translational values applied, correction to zero.

In order to implement CBCT imaging, staff needed further training. For this tumour site, offline training consisted of a library of images with a variety of patient positions and internal anatomy changes. Initially, a core group of RTTs were asked to match images, discuss the issues presented to them, and how this would affect treatment delivery. Following a series of matched online images, RTTs were deemed competent. Image verification was deemed unnecessary after floor rotation, as the AlignRT® system was able to verify patient position after the couch was moved.

Additionally, when taking a full rotation CBCT, the view of the AlignRT® cameras are blocked at two points, so the software displays no reading. Thus, patients are monitored using in-room cameras, at these points. Patients are coached into breath-hold using AlignRT®, and the CBCT acquisition begins. During acquisition, RTTs are responsible for pausing the image at right angles, four times during image acquisition. This prevents blocking of the AlignRT® cameras by the gantry influencing the ability to know if the patient is in a sufficient breath-hold, as well as prevent patients from exceeding their maximum comfortable



**Fig. 2.** Region of interest (grey contour) on the AlignRT software highlighted for optimal gating during deep inspiration breath hold for mediastinal lymphoma patients.

breath-hold. The surface region of interest (ROI) on the AlignRT® system also needed adaptation for mediastinal lymphoma patients compared to breast DIBH patients in order to increase visibility during treatment arcs. This is shown in Fig. 2.

Another challenge was that patients with treatment volumes of >17 cm longitudinal length with a single isocentre required acquiring a multi-scan CBCT. Immobilisation for these patients can mean that the neck is completely immobilised with a headshell and breath-hold is used only for the mediastinum. The neck portion of the volume can often remain still throughout treatment; however, the need to breath-hold means there is often a positional discrepancy in the mediastinum. This can result in a translational discrepancy on AlignRT®. In this situation the internal anatomy position on the CBCT is taken as the gold-standard treatment position and the translational discrepancy on AlignRT® is accepted. Sometimes, the translational imaging values shown in the superior image can differ by >0.5 cm from the inferior scan match. The implications of this show that even with an ideal bone match for both scans, disease volume coverage may still be compromised. It was therefore decided that any patient with a treatment volume over 17.0 cm would receive a multi-scan, comprising of a superior scan of the head and neck, and an inferior scan of the mediastinum, on fraction one and a practical compromise had to be considered. The process is to match both scans and image displacement values from the inferior scan are applied to the superior scan and coverage is assessed. If there is a large discrepancy between the two scans (>0.5 cm) or a discrepancy in coverage an average of the two-match values is taken, and an assessment of both scans ensures coverage. These average values are applied. If this is required on fraction one, patients are multi-scanned daily to ensure adequate coverage at both ends of the volume. If there is a significant improvement in the values between the two scans during treatment, the patient's multi-scans are moved to weekly. The CBCT scanning parameters were optimised for both head and thoracic scans to reduce the imaging dose as low as reasonably possible.

Finally, it was noted that the position of the heart and mediastinum in breath-hold could differ from the patient's pre-treatment CT even without any significant change in their external contour. This was due to a variety of factors e.g., patients were more relaxed or taking a slightly deeper inhale on treatment which resulted in positional differences of internal anatomy. This was a common problem for patients who breathe through the abdomen, as their thoracic surface contour was not representative of their diaphragm position. These patients required more time and DIBH coaching to ensure the breath was taken through their chest.

The difference in internal anatomy is not evident on 2D imaging alone, therefore daily 3D imaging is recommended as it identified internal changes with breath-hold or disease regression.

#### Results & Discussion:

For the introduction of these advanced techniques, it was found that regardless of previous experience in DIBH for breast patients, extensive training, protocols and documentation were required. Specifically as described above, RTTs received advanced training on the techniques, patient coaching, standardised scanning and protocols and image guided RT. Thus, when undertaking advanced techniques training is required to implement DIBH. Additionally, using tight tolerances on AlignRT® of 0.5 cm and 3.0° has also ensured patients are not imaged multiple times per fraction. From using AlignRT® the patient's surface position is assessed before leaving the room, minimising the risk of the CBCT image being out of gross tolerance and the patient requiring additional set up and imaging [10].

Overall, it was found that there were many variables in the clinical procedures that needed to be adjusted to ensure the patient pathway was smooth and coordinated. Due to sequential implementation of multiple technologies, it was vital to examine the whole patient pathway from initial clinical review through to follow-up. The pathway development was only possible with communication between multiple members of the MDT who held an open line of communication from the patient's first appointment, enabling transparency in the service and a high standard of care. The commitment to continuous learning and adaptability from all members of the MDT was a vital component in the progression of the techniques and ensured that the standard of treatment delivered was always high, although ever-changing and progressing with technological advancements in RT.

By initiating these developments with a core staff group and a project lead, the integrity of the initial training was ensured, allowing for learning and reflections by senior staff before introducing more junior members of the team. The developments were also not introduced concurrently, allowing staff time to grow in confidence at each phase. The use of CBCT imaging has become an essential component for delivering the technique as it provides the ability to monitor internal anatomy changes in either organs at risk or disease to ensure PTV coverage and to escalate patients for further intervention if deemed necessary. Although the technique is complicated, it was possible to implement it within a busy department, providing insight on issues that

arose when doing so to further benefit other departments wishing to implement the same radiotherapy technique.

### Declaration of Competing Interest

The authors declare that they have no known competing financial interests or personal relationships that could have appeared to influence the work reported in this paper.

### References

- [1] Schaapveld M, Aleman BMP, van Eggermond AM, Janus CPM, Krol ADG, van der Maazen RWM, et al. Second Cancer Risk Up to 40 Years after Treatment for Hodgkin's Lymphoma. *N Engl J Med* 2015;373(26):2499–511.
- [2] van Nimwegen FA, Schaapveld M, Janus CPM, Krol ADG, Petersen EJ, Raemaekers JMM, et al. Cardiovascular Disease After Hodgkin Lymphoma Treatment 40-Year Disease Risk Original Investigation. *JAMA. Intern Med* 2015; 175(6):1007.
- [3] Aznar MC, Maraldo MV, Schut DA, Lundemann M, Brodin NP, Vogelius IR, et al. Minimizing late effects for patients with mediastinal Hodgkin lymphoma: Deep inspiration breath-hold, IMRT, or both? *Int J Radiat Oncol Biol Phys* 2015;92(1): 169–74.
- [4] Baues C, Marnitz S, Engert A, Baus W, Jablonska K, Fogliata A, et al. Proton versus photon deep inspiration breath hold technique in patients with hodgkin lymphoma and mediastinal radiation. *Radiat Oncol* 2018;13(1).
- [5] Voong KR, McSpadden K, Pinnix CC, Shihadeh F, Reed V, Salehpour MR, et al. Dosimetric advantages of a “butterfly” technique for intensity-modulated radiation therapy for young female patients with mediastinal Hodgkin's lymphoma. *Radiat Oncol* 2014;9(1).
- [6] Starke A, Bowden J, Lynn R, Hall K, Hudson K, Rato A, et al. Comparison of butterfly volumetric modulated arc therapy to full arc with or without deep inspiration breath hold for the treatment of mediastinal lymphoma. *Radiother Oncol* 2018 Dec 1;129(3):449–55.
- [7] Fiandra C, Filippi AR, Catuzzo P, Botticella A, Ciammella P, Franco P, et al. Different IMRT solutions vs. 3D-Conformal Radiotherapy in early stage Hodgkin's lymphoma: dosimetric comparison and clinical considerations. *Radiat Oncol* 2012; 7(1):1–9.
- [8] Mikhaeel NG, Brady JL, Brady J, Swarnkar P, Attallah H. Local tumor control after mediastinal radiotherapy with DIBH and small CTV-PTV margin ESTRO 2020 Abstract Book <https://user-swndwmf.cld.bz/8huStZo/284/>. *Radiother Oncol* 2020;152:S255.
- [9] The Royal College of Radiologists, Society and College of Radiographers I of P and E in M. On target : ensuring geometric accuracy in radiotherapy. London: The Royal College of Radiologists. 2008; Available from: [http://www.rcr.ac.uk/docs/oncology/pdf/BFCO\(08\)5\\_On\\_target.pdf](http://www.rcr.ac.uk/docs/oncology/pdf/BFCO(08)5_On_target.pdf).
- [10] Hamming VC, Visser C, Batin E, McDermott LN, Busz DM, Both S, et al. Evaluation of a 3D surface imaging system for deep inspiration breath-hold patient positioning and intra-fraction monitoring. *Radiat Oncol* 2019;14(1):4–11.