

# MOSAICPLASTY WITH PERIOSTEAL GRAFT FOR RESURFACING LOCAL FULL-THICKNESS CHONDRAL DEFECTS OF THE KNEE

Fernando Fonseca

## ABSTRACT

**Introduction and Objectives:** Clinical and functional assessment comparing cases of full-thickness chondral defects (OC) treated with mosaicplasty or mosaicplasty covered with periosteum (mosaicambium). **Methods:** 20 knees with chondral defect, (10 mosaicplasty/10 mosaicambium) were operated between 1999 and 2005. All patients were clinically assessed preoperatively using the ICRS scale, VAS scale, X-ray and MRI. During 2008, we reviewed patients using the same protocol. For statistical purposes, the patients were divided into two groups, according to the surgical technique. Statistical analysis was performed with EPI2000 program, using chi-squared test and Student's t test, with a significance level of 0.05. **Results:** Preoperatively, all patients were in group C

/D (ICRS scale). In 2008, 18 cases were in groups A and B according to the ICRS scale (12 in A). Between groups, there were no statistical differences. The X-ray study revealed no changes in 55% of cases. **Discussion:** With no differences, why mosaicambium option? Morbidity on graft donor zones is not negligible. Mosaicambium uses less chondral grafts, reducing the potential for morbidity at graft donor zones. **Conclusion:** The mosaicambium technique is an excellent alternative for chondral defects greater than 2 cm<sup>2</sup>.

*“...articular cartilage defects are a troublesome thing... they don't heal...”. William Hunter (1718-1783).*

**Keywords** – Cartilage; Osteochondral defect; mosaicplasty

## INTRODUCTION

There are several forms of treatment of symptomatic osteochondral defects, such as drilling<sup>(1)</sup>, microfractures<sup>(2)</sup>, covering with periosteum<sup>(3,4)</sup>, transposition of cartilage from areas of lower demand<sup>(5)</sup>, mosaicplasty<sup>(6)</sup>, or autologous chondrocytes<sup>(7,8)</sup>.

Since 1999, the author has been using a mixed technique utilizing mosaicplasty covered with periosteum (cambium layer) for osteochondral substance losses greater than 2 cm<sup>2</sup>. This paper aims to present the technique and evaluate the clinical results obtained.

## METHODS

Between 1999 and 2005, 20 patients with more than 2 cm<sup>2</sup> loss of osteochondral (OC) substance at the femoral condyles were treated in our clinic. In 10 patients we used the classical mosaicplasty technique described by Hangody et al.<sup>(9)</sup>. In the remaining 10, we used a technique developed by the author, the object of presentation in an international meeting<sup>(2)</sup>, called “mosaicambium”. Patients were only admitted for inclusion in this review if they had lost more than 2 cm<sup>2</sup> of OC substance in the knee, and whose opposite knee never had any symptoms and/or undergone any surgery. We excluded all bilateral cases, in order to use the opposite knee as the standard. The procedure to be adopted was chosen at random by procedure alternation (mosaicplasty/mosaicambium), according to the date of admission into the clinic.

Patients were operated under general or locoregional anesthesia. The protocol procedure presupposed prior arthroscopy to confirm the type and extent of the injury. Subsequently, reconstruction of the surface by mosaicambium or mosaicplasty was performed through mini-arthrotomy. Osteochondral autografts cylinders with diameters between 2.7 and 3.5 mm and a length of 20 mm were harvested for both

Assistant Professor, Coimbra School of Medicine.

Study conducted at the University Orthopedics Clinic, Coimbra School of Medicine.

Correspondence: Clínica Universitária de Ortopedia, Hospitais da Universidade de Coimbra, Praceta Mota Pinto – 3000 – Coimbra, Portugal. E-mail: pereirafonseca@clix.pt

We declare no conflict of interest in this article.

techniques, preferably in the medial femoral condyle in the intercondylar area of the same knee using the mosaicplasty system (Smith & Nephew Endoscopy). The harvested grafts were implanted in the area of the osteochondral defect following the precepts described by Hangody et al.<sup>(9)</sup>.

For the mosaicambium technique, the osteochondral cylinders were then covered with periosteal grafts harvested from the tibia, with the “cambium” side facing the implanted cylinders. The graft was fixed with resorbable sutures (Figure 1 and Figures 2A and 2B).

Postoperatively, the same protocol was used for all cases, the principles of which were exercises of joint mobilization and muscle strengthening. The rehabilitation program places special emphasis on gaining range of motion. Walking without weight-bearing is allowed as early as 48 hours, and walking bearing their full weight is allowed between the 7<sup>th</sup> and 10<sup>th</sup> weeks.

The preoperative evaluation protocol provides, besides history, an assessment of the range of motion, the presence/absence of intra-articular effusion, tender points, meniscal signals, and signs of ligament instability. Later, the protocol<sup>1</sup> of the International Cartilage Research Society (ICRS) is used, which includes information on the cause of the injury, the onset of symptoms, sports activities, the patient’s age at the time of trauma, subjective assessment of the functioning of the knee (as a percentage relative to the opposite knee) and level of physical activity. This classification shows good reliability and is accurate between its final result and the state of the cartilage observed in arthroscopy<sup>(10)</sup>. The depth and degree of impairment of the cartilage were also assessed on a scale of four grades<sup>(11)</sup>.

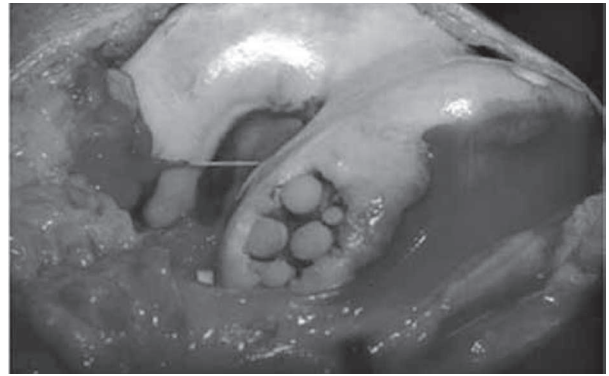


Figure 2A – Osteochondral grafts.

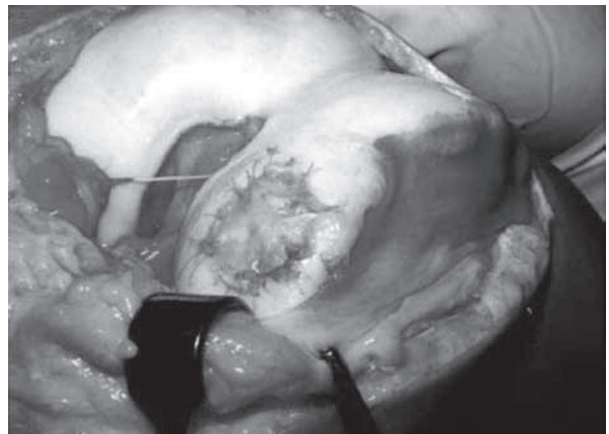


Figure 2B – Coating with periosteum.

The data collected allow us to group patients into four levels, with A being the best and D the worst. The final grade corresponds to the worst recording of all items assessed.

A visual analogue scale (VAS) for pain was adopted, giving the patient a ruler with 100 mm, marked from 0 to 10 in intervals of 10 mm, where 0 corresponded to no pain and 10 to unbearable pain. The patient was asked to indicate the exact point at which

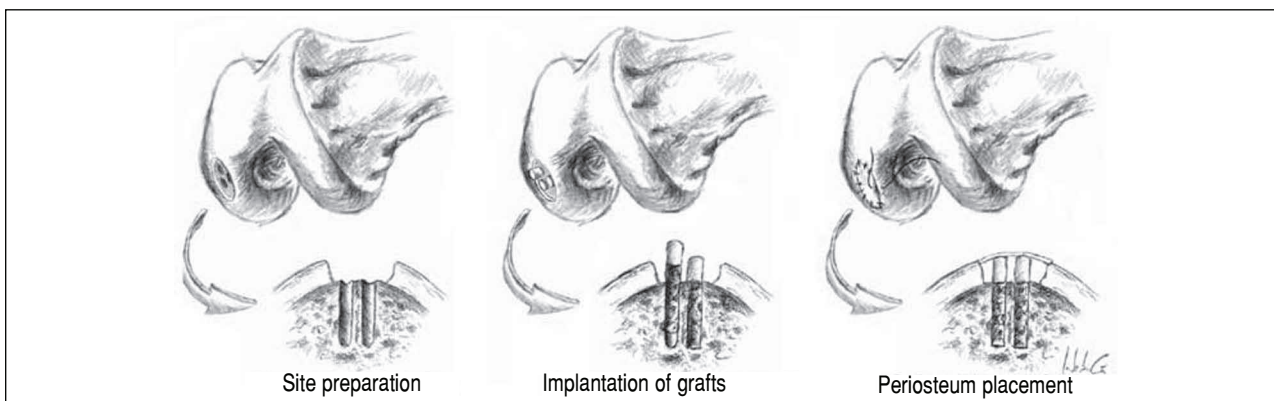


Figure 1 – Schematic of the technique.

they would consider their pain. The recorded value was measured in mm from the 0 point.

Radiography followed the clinic's usual protocol, including radiographs frontal and lateral to the knee, and axial to the hinges in 30° of flexion. The evaluation adopted the ICRS scale protocol using four grades according to existing degenerative changes (no change, femorotibial (FT) interline narrowing less than 50%, FT interline narrowing greater than 50%, narrowing of the interline with any other degenerative change present). This classification is particularly useful for evaluating the medium and long-term, particularly in the presence of degenerative changes.

The MRI evaluation was only performed routinely in the preoperative period from 2004 and in the revision evaluation.

When 12 months from surgery were completed, patients were asked in a non-compulsory manner, to undergo a second-look evaluation performed by arthroscopy. Only 10 patients accepted.

The null hypothesis ( $H_0$ ) was the absence of clinical differences between patients operated with mosaicplasty and patients operated with mosaicambium. The opposite knee was considered the standard.

The results were analyzed with the EPI2000 statistical program, using the chi-square test for categorical variables and Student's t-test for continuous variables. P values < 0.05 were considered significant.

## RESULTS

The profile of patients pertaining to the present study is described in Table 1.

There was a predominance of male patients (70%), with a mean age of  $26.5 \pm 5.5$  years at surgery. In the overwhelming majority of cases, the medial condyle was affected. The average size of the area of OC loss was  $2.59 \pm 0.2$  cm. When preoperatively evaluating the VAS, the mean value was  $80 \pm 15$  mm. In the total ICRS classification, nine patients were in class III and 11 were in class IV, with no statistically significant difference between the groups ( $p > 0.05$ ).

The number of cylinders used is described in Table 2, showing a statistically significant lower number of cylinders used in cases of mosaicambium ( $p = 0.001$ ). In the review conducted in 2008, the average follow-up

period was  $5.9 \pm 1.6$  years (minimum of three years and a maximum of nine years).

The detailed final evaluation of patients can be observed in Table 3. Despite the different distributions, the p value was not significant ( $p = 0.44$ ).

The intensity of pain in 2008 showed a mean of  $5.9 \pm 1.6$  on the VAS scale, a value much lower than the preoperative period, but still higher than that of the opposite knee, whose value was 0 in all cases. The comparison of data between the mosaicplasty group and the mosaicambium group showed no statistical difference.

Radiographically, nine patients (45.0%) showed degenerative changes, eight of which were in group II and one of which was in group III of the ICRS classification, without statistically significant differences between groups.

On MRI, 73.4% of patients showed changes, not only of cartilage irregularity, but also with the presence of signal changes at the OC cylinder donor site. However, in cases treated with mosaicambium, the joint line of the cartilage appeared more regular than in those undergoing simple mosaicplasty, as shown in Figure 3, which illustrates a case with four years of evolution.

With the second-look evaluation, changes in the cartilage were observed in all of the cases reviewed, but, similarly to the MRI, the presence of cartilage irregularities was lower in patients in whom the mosaicambium technique was used (Figures 4A and 4B).

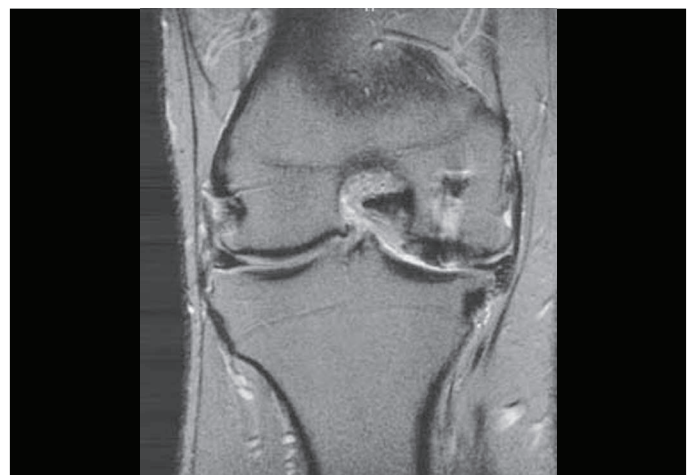

Figure 3 – Control with four years of evolution.

<sup>1</sup> The cartilage standard evaluation form/knee. ICRS Newsletter, Spring 1992.

**Table 1** – Profile of patients evaluated.

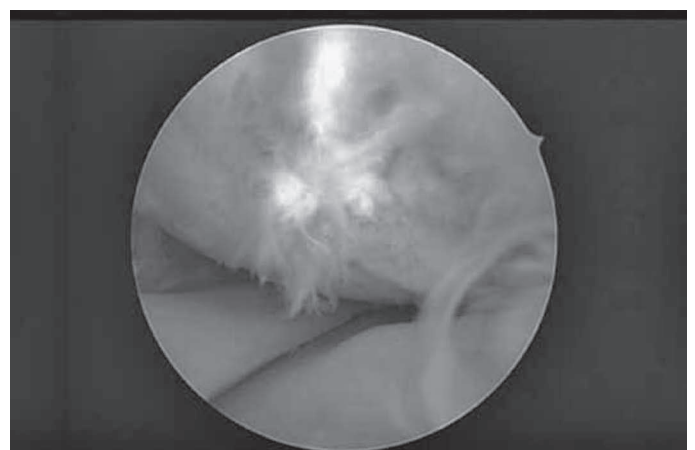
Case	Gender	Age	Condyle	Size (cm <sup>2</sup> )	Cause	Symptom onset	Pre-op ICRS	Surgical technique	X-rays – ICRS		Final ICRS
									Pre-op	Revision	
1	Male	31	Medial	2.5	ADL	Gradual	IV	Mosaicplasty	II	II	II
2	Male	18	Lateral	2.5	Sports	Gradual	III	Mosaicambium	I	I	I
3	Male	33	Medial	2	ADL	Acute	III	Mosaicplasty	I	II	I
4	Male	33	Medial	3	ADL	Gradual	IV	Mosaicambium	I	II	II
5	Male	37	Medial	2.5	ADL	Gradual	IV	Mosaicplasty	I	I	I
6	Male	18	Medial	2.5	Sports	Gradual	IV	Mosaicambium	I	I	I
7	Male	21	Medial	2.9	Sports	Acute	IV	Mosaicplasty	I	I	II
8	Male	23	Medial	2.9	ADL	Gradual	IV	Mosaicambium	I	II	IV
9	Male	21	Medial	2.8	ADL	Gradual	III	Mosaicplasty	I	I	II
10	Male	30	Medial	2.5	ADL	Gradual	III	Mosaicambium	I	II	I
11	Male	26	Lateral	2.5	ADL	Acute	III	Mosaicplasty	I	I	I
12	Male	25	Medial	2.5	ADL	Gradual	IV	Mosaicambium	I	I	I
13	Male	26	Medial	2.6	Sports	Acute	IV	Mosaicplasty	I	II	I
14	Male	28	Medial	2.6	ADL	Gradual	IV	Mosaicambium	I	I	II
15	Male	28	Medial	2.6	ADL	Gradual	IV	Mosaicplasty	II	II	II
16	Male	25	Medial	2.5	Sports	Acute	IV	Mosaicambium	I	II	I
17	Male	22	Medial	2.5	Sports	Acute	III	Mosaicplasty	I	I	I
18	Male	20	Medial	2.5	ADL	Gradual	III	Mosaicambium	II	III	III
19	Male	31	Medial	2.7	ADL	Gradual	III	Mosaicplasty	I	I	I
20	Male	33	Medial	2.7	ADL	Gradual	III	Mosaicambium	I	I	I

**Table 2** – Profile of patients evaluated<sup>(II)</sup>.

Case	Surgical technique	No. of cylinders
1	Mosaicplasty	3
2	Mosaicambium	2
3	Mosaicplasty	3
4	Mosaicambium	4
5	Mosaicplasty	3
6	Mosaicambium	2
7	Mosaicplasty	3
8	Mosaicambium	2
9	Mosaicplasty	3
10	Mosaicambium	2
11	Mosaicplasty	4
12	Mosaicambium	2
13	Mosaicplasty	4
14	Mosaicambium	2
15	Mosaicplasty	3
16	Mosaicambium	4
17	Mosaicplasty	3
18	Mosaicambium	3
19	Mosaicplasty	3
20	Mosaicambium	2

**Table 3** – Final evaluation according to the ICRS scale.

Final ICRS evaluation	Class I	Class II	Class III	Class IV
Mosaicplasty	6	4	–	–
Mosaicambium	6	2	1	1

**Figure 4A** – Arthroscopic control of a patient with mosaicambium.**Figure 4B** – Arthroscopic control of a patient with mosaicplasty.



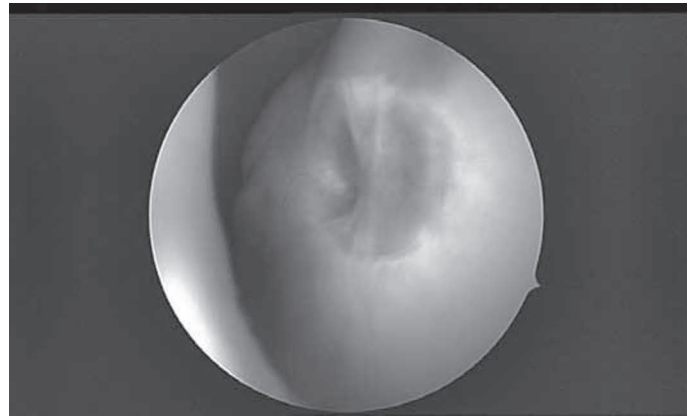
## DISCUSSION

There are many different causes of cartilage pathology. Isolated changes in cartilage, though often asymptomatic, are very common, often prompting an arthroscopic discovery<sup>(12)</sup>. The various treatment techniques available can be divided into three categories: techniques that stimulate fibrocartilage-forming bone marrow, cartilage regeneration techniques, osteochondral graft transposition or transplantation techniques.

In this last category are the techniques of periosteum grafts<sup>(3)</sup>, osteochondral auto- or allografts, mosaicplasty, or mosaicambium. Mosaicplasty has become a very popular option since its development and dissemination by Hangody et al.<sup>(13,14)</sup>, in which osteochondral cylinders are harvested from non-load-bearing areas<sup>(15)</sup> and placed in the site of the osteochondral defect, covering about 70% of the area<sup>(13,14)</sup>. This value is provided without any apparent scientific evidence to support it. Bussiere et al.<sup>(16)</sup> proposed a mathematical formula for calculating the area that should be replaced, but showed no clinical evidence of this formula being correct. Another issue raised in mosaicplasty is the type of cartilage that sits between the donor areas, which is often fibrocartilage<sup>(14,16)</sup>. Finally, it should be noted that in mosaicplasty there may be residual pain and functional impairment of the knee due to sequelae at the donor site, as reported by Bobic<sup>(15)</sup> and Ahmad et al.<sup>(17)</sup> (Figure 5).

In the area close to the bone, the periosteum has the so-called cambium layer, which has undifferentiated cells capable of differentiating, in an intra-articular medium, into chondrocytes to produce hyaline cartilage<sup>(3)</sup>. This ability has led some authors to use it as an important matrix in tissue engineering *in vitro* in the production of cartilage<sup>(18,19)</sup>. The use of periosteum in isolation has led to poor results<sup>(20)</sup> and was therefore abandoned. However, in cases of autologous chondrocyte transplantation, it is necessary to use the periosteum cambium layer as a means of restraining and stimulating the production of cartilage<sup>(7)</sup>.

Due to the recognition of the possible consequences of the mosaicplasty when a large number of cylinders is harvested, combined with the impossibility of using autologous chondrocyte transplantation in a hospital, we have developed and used a technique



**Figure 5** – Arthroscopic control at the osteochondral graft harvest site.

combining mosaicplasty covered with periosteum in cases of patients with osteochondral defects greater than 2 cm<sup>2</sup>. We can reduce the number of cylinders used with this technique, while we resort to the inner layer (cambium layer) of the periosteum with a source for the differentiation of chondrocytes. In addition to this advantage, the possibility of bringing a well-shaped layer on the surface of the condyle that closely resembles its original form could limit the irregularity of the articular surface that is commonly seen in cases of mosaicplasty.

In this study, clinical outcomes were not different from those obtained with mosaicplasty, with a clear improvement in the pre-surgical state. Using the opposite knee as the standard, in either case (mosaicambium or mosaicplasty), the results fell short of the normal standard, which is understood and accepted. The smaller number of osteochondral cylinders used is in accordance with one of the objectives of the mosaicambium technique, which a strong point to be highlighted.

In those cases that underwent an arthroscopic second-look, the fact that it was only conducted in cases that volunteered to do so, which were not all cases, creates a possible information bias. Notice, however, that the quality of the cartilage and regularity of the articular surface seen in arthroscopy seemed to be better in cases of mosaicambium (Figure 4A) than in the mosaicplasty (Figure 4B). However, the small number of cases evaluated does not permit any definitive conclusions; more consistent support is necessary. The fact that we are facing a more aggressive procedure poses ethical and deontological problems

that can only be solved when MRI assessment techniques present greater specificity than that observed today for similar situations<sup>(21)</sup>.

Why choose this new procedure, taking into account the existence of another that is well-studied and standardized? The main reason is the decrease in the number of cylinders required for filling in bone loss, reducing the potential morbidity of the donor areas<sup>(15)</sup> and avoiding the need to harvest a graft in other joints or near the patellofemoral joint, a site of proven residual morbidity, with presence of patellofemoral pain<sup>(17)</sup>. The present work demonstrates that the clinical results obtained with the mosaicambium technique were not inferior to the standard technique (mosaicplasty), confirming the hypothesis. Since fewer grafts are harvested with the mosaicambium technique than the standard technique, the likelihood

of reducing morbidity associated with donor sites is greater, wherein resides its principal advantage.

Assessing the quality of the cartilage obtained was not an objective of the work, taking into account the constraints mentioned. In the few cases of second-look evaluation, the cartilage had a hyaline appearance and the hypertrophy phenomena described in autologous chondrocyte transplantation were not observed<sup>(23)</sup>, although the small number of cases limits the quality of information.

In any case, the mosaicambium technique should be considered as an alternative with reliable clinical results.

## CONCLUSION

The mosaicambium technique is an option to consider whenever there is more than 2 cm<sup>2</sup> loss of OC substance, due to the lower number of grafts needed and the decreased morbidity related to the donor site.

## REFERENCES

- Fritz J, Janssen P, Gaissmaier C, Schewe B, Weise K. Articular cartilage defects in the knee- basics, therapies and results. *Injury*. 2008;39(Suppl 1):S50-7.
- Rodrigo JJ, Steadman JR, Silliman JF, Fulstone HA. Improvement of full-thickness chondral defect healing in the human knee after debridement and microfracture using continuous passive motion. *Am J Knee Surg*. 1994;7:109-16.
- O'Driscoll SW, Recklies AD, Poole AR. Chondrogenesis in periosteal explants. An organ culture model for in vitro study. *J Bone Joint Surg Am*. 1994;76(7):1042-51.
- Simon TM, Van Sickle DC, Kunishima DH, Jackson DW. Cambium cell stimulation from surgical release of the periosteum. *J Orthop Res*. 2003;21(3):470-80.
- Outerbridge HK, Outerbridge RE, Smith DE. Osteochondral defects in the knee. A treatment using lateral patella autografts. *Clin Orthop Relat Res*. 2000;(377):141-51.
- Hangody L, Kish G, Karpati Z, Szerb I, Udvarhelyi I. Arthroscopic autogenous osteochondral mosaicplasty for the treatment of femoral condylar articular defects. A preliminary report. *Knee Surg Sports Traumatol Arthrosc*. 1997;5(4):262-7.
- Brittberg M, Lindahl A, Nilsson A, Ohlsson C, Isaksson O, Peterson L. Treatment of deep cartilage defects in the knee with autologous chondrocyte transplantation. *N Engl J Med*. 1994;331(14):889-95.
- Rosenberger RE, Gomoll AH, Bryant T, Minas T. Repair of large chondral defects of the knee with autologous chondrocyte implantation in patients 45 years or older. *Am J Sports Med*. 2008;36(12):2336-44.
- Hangody L, Feczko P, Bartha L, Bodo G, Kish G. Mosaicplasty for the treatment of articular defects of the knee and ankle. *Clin Orthop Relat Res*. 2001;(391 Suppl):S328-36.
- Smith GD, Taylor J, Almqvist KF, Erggelet C, Knutsen G, Garcia Portabella M, et al. Arthroscopic assessment of cartilage repair: a validation study of 2 scoring systems. *Arthroscopy*. 2005;21(12):1462-7.
- Makino A, Muscolo DL, Puigdevall M, Costa-Paz M, Ayerza M. Arthroscopic fixation of osteochondritis dissecans of the knee: clinical, magnetic resonance imaging, and arthroscopic follow-up. *Am J Sports Med*. 2005;33(10):1499-504.
- Årøen A, Løken S, Heir S, Alvik E, Ekeland A, Granlund OG, et al. Articular cartilage lesions in 993 consecutive knee arthroscopies. *Am J Sports Med*. 2004;32(1):211-5.
- Hangody L, Feczko P, Bartha L, Bodo G, Kish G. Mosaicplasty for the treatment of articular defects of the knee and ankle. *Clin Orthop Relat Res*. 2001;(391 Suppl):S328-36.
- Hangody L, Kish G, Karpati Z, Udvarhelyi I, Szigeti I, Bely M. Mosaicplasty for the treatment of articular cartilage defects application in clinical practice. *Orthopaedics*. 1998;21(7):751-6.
- Bobic V. Arthroscopic osteochondral auto graft transplantation in anterior cruciate ligament reconstruction: a preliminary clinical study. *Knee Surg Sports Traumatol Arthrosc*. 1996;3(4):262-4.
- Bussiere C, Selmi TAS, Neyret PH, Francisco LNFL, Prado RK. Osteochondral mosaicplasty. Twenty-two clinical cases. *Rev Port Ortop Trauma*. 2006;14(2):1-21.
- Ahmad CS, Guiney WB, Drinkwater CJ. Evaluation of donor site intrinsic healing response in autologous osteochondral graft of the knee. *Arthroscopy*. 2002;18(1):95-8.
- Haasper C, Zeichen J, Meister R, Krettek C, Jagodzinski M. Tissue engineering of osteochondral constructs in vitro using bioreactors. *Injury*. 2008;39(Suppl 1):S66-76.
- Zhang X, Awad HA, O'Keefe RJ, Guldberg RE, Schwarz EM. A perspective: engineering periosteum for structural bone graft healing. *Clin Orthop Relat Res*. 2008;466(8):1777-87.
- Hunziker EB. Articular cartilage repair: basic science and clinical progress. A review of the current status and prospects. *Osteoarthritis Cartilage*. 2002;10(6):432-63.
- Ramappa AJ, Gill TJ, Bradford CH, Ho CP, Steadman JR. Magnetic resonance imaging to assess knee cartilage repair tissue after microfracture of chondral defects. *J Knee Surg*. 2007;20(3):228-34.
- Kreuz PC, Steinwachs M, Erggelet C, Krause SJ, Ossendorf C, Maier D, et al. Classification of graft hypertrophy after autologous chondrocyte implantation of full-thickness chondral defects in the knee. *Osteoarthritis Cartilage*. 2007;15(12):1339-47.