



ELSEVIER

Contents lists available at [ScienceDirect](https://www.sciencedirect.com)

# Trauma Case Reports

journal homepage: [www.elsevier.com/locate/tcr](http://www.elsevier.com/locate/tcr)

## Case Report

# CT image evaluation of one-screw fixation in the Latarjet procedure

Hiromichi Omae

Department of Orthopaedic Surgery, Matsuyama Red Cross Hospital, 1-Bunkyocho, Matsuyama, Ehime 790-8524, Japan

## ARTICLE INFO

### Keywords:

Anterior instability  
Latarjet procedure  
Bone union  
CT images  
One-screw fixation  
Bankart repair

## ABSTRACT

**Background:** In the Latarjet procedure, two screws are used for secure fixation. However, when the graft is small, two-screw fixation is technically difficult. The purpose of this study was to evaluate the bone union of one-screw fixation on CT images.

**Methods:** Ten shoulders with anterior recurrent dislocation underwent the open Latarjet procedure using one-screw fixation combined with arthroscopic Bankart repair. The bone union and the graft position were evaluated on CT images at 3, 6, and 12 months after the operation.

**Results:** Seven of 10 shoulders showed bone union at 3 months after the operation. In two shoulders, the removal of cortex was insufficient, and bone union was observed at 6 months. In one shoulder, the distal part of the graft was not in contact with the glenoid, and bone union was observed at 12 months. In one shoulder, the graft was healed in a 70-degree-rotated position. The average thickness of the graft was  $7.2 \pm 1.0$  mm.

**Conclusion:** One-screw fixation in the Latarjet procedure did not show non-union. Sufficient removal of the graft cortex and good contact were needed for early union.

## Introduction

In the Latarjet procedure for recurrent anterior shoulder dislocations, the graft is fixed using two screws. However, when the graft is small, two-screw fixation has the risk of graft breakage. One-screw fixation might be weaker than two-screw fixation and might have a risk of non-union or displacement of the graft after the operation. The purpose of this study was to evaluate bone union after one-screw fixation in the Latarjet procedure on CT images.

## Materials and methods

Ten shoulders of recurrent anterior dislocation were included in this study. The average age of the patients was 28 years (14–59 years). There were 8 males and 2 females. Preoperatively, all patients underwent a physical examination, and functional outcome was assessed with the Rowe score [1]. Postoperative functional outcome was assessed at the last follow-up.

In all cases, preoperative CT scans of bilateral shoulders were done. Using 3D-CT images, the length of the coracoid from the tip to the junction between the horizontal and vertical aspects was measured. The anterior bone loss was calculated using the maximum inferior diameter of the glenoid compared to the maximum inferior diameter of the uninjured contralateral glenoid [2].

The open Latarjet procedure using one screw combined with arthroscopic Bankart repair was performed. The detailed procedures

E-mail address: [omae@matsuyama.jrc.or.jp](mailto:omae@matsuyama.jrc.or.jp).

<https://doi.org/10.1016/j.tcr.2020.100372>

Accepted 1 November 2020

Available online 3 November 2020

2352-6440/© 2020 The Author.

Published by Elsevier Ltd.

This is an open access article under the CC BY-NC-ND license

(<http://creativecommons.org/licenses/by-nc-nd/4.0/>).

were as follows: The patient was placed in the beach-chair position under general anaesthesia. An ~6-cm skin incision was applied on the tip of the coracoid process. Using the anterior approach, the coracoid process was exposed and cut at 15–17 mm in length from the insertion of the conjoined tendon. The soft tissue on the distal aspect of the graft was removed, and the bone cortex was removed using a high-speed steel bar. The subscapularis muscle was divided at the middle part, and the anterior joint capsule was exposed. Then, the anterior capsule and the remaining labrum were detached from the glenoid arthroscopically. The anterior aspect of the glenoid was exposed by retracting the anterior capsule and the humeral head laterally and dividing the subscapularis muscle with the glenoid retractor. The bone cortex at the 3 o'clock to 5 o'clock positions of the anterior aspect of the glenoid was removed using a high-speed steel bar. The graft was fixed to the glenoid using one 4.5-mm partially threaded cannulated cancellous screw without a washer. The length of each screw was decided by the total length of each drill hole of the graft and the glenoid, measured directly using a depth gauge. Then, Bankart repair was performed arthroscopically using 3–5 soft anchors. The shoulder was immobilized for 4 weeks using a

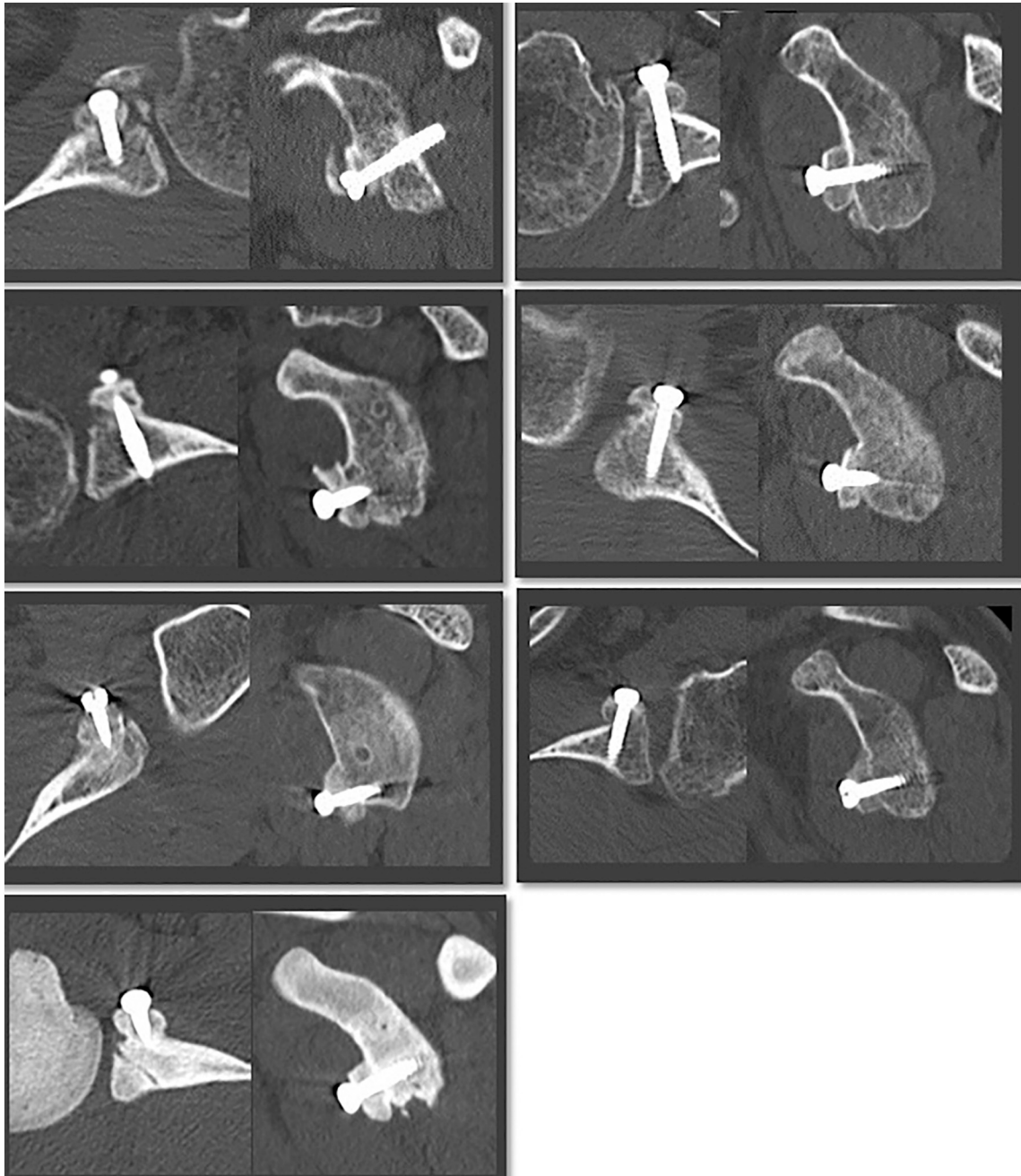


Fig. 1. CT images at 3 months: 7 shoulders showed bone union at 3 months.

soft brace.

The bone union was evaluated on CT images in the horizontal and oblique sagittal planes at 3, 6, and 12 months after the operation. On the 3D-CT images, the rotation of the graft and the resorption of the graft were also evaluated. The thickness of the graft was measured at the screw site using an imaging workstation (Ziostation, Ziosoft, Tokyo, Japan).

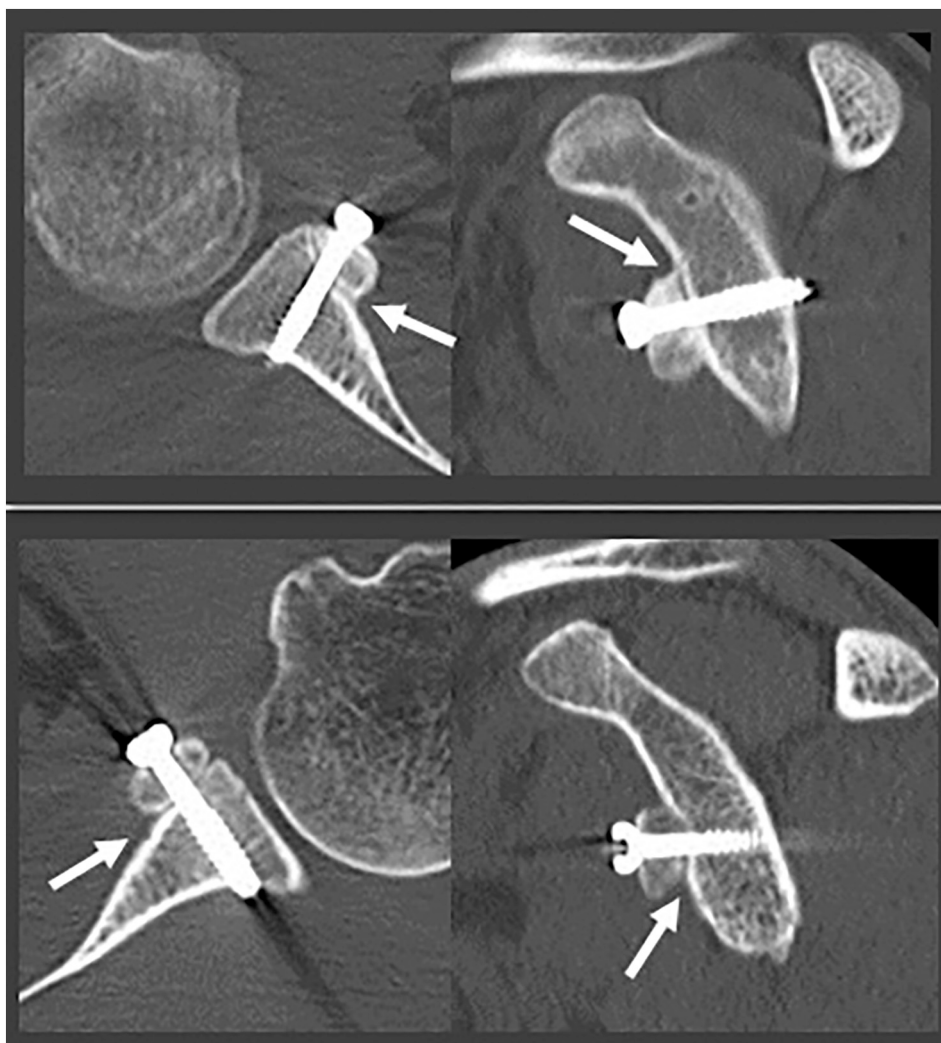
## Results

The mean follow-up was 21 months (12–35 months). The mean Rowe score increased from  $51.1 \pm 8.1$  preoperatively to  $92.8 \pm 5.8$  postoperatively. No recurrent subluxation or dislocation was observed at the last follow-up.

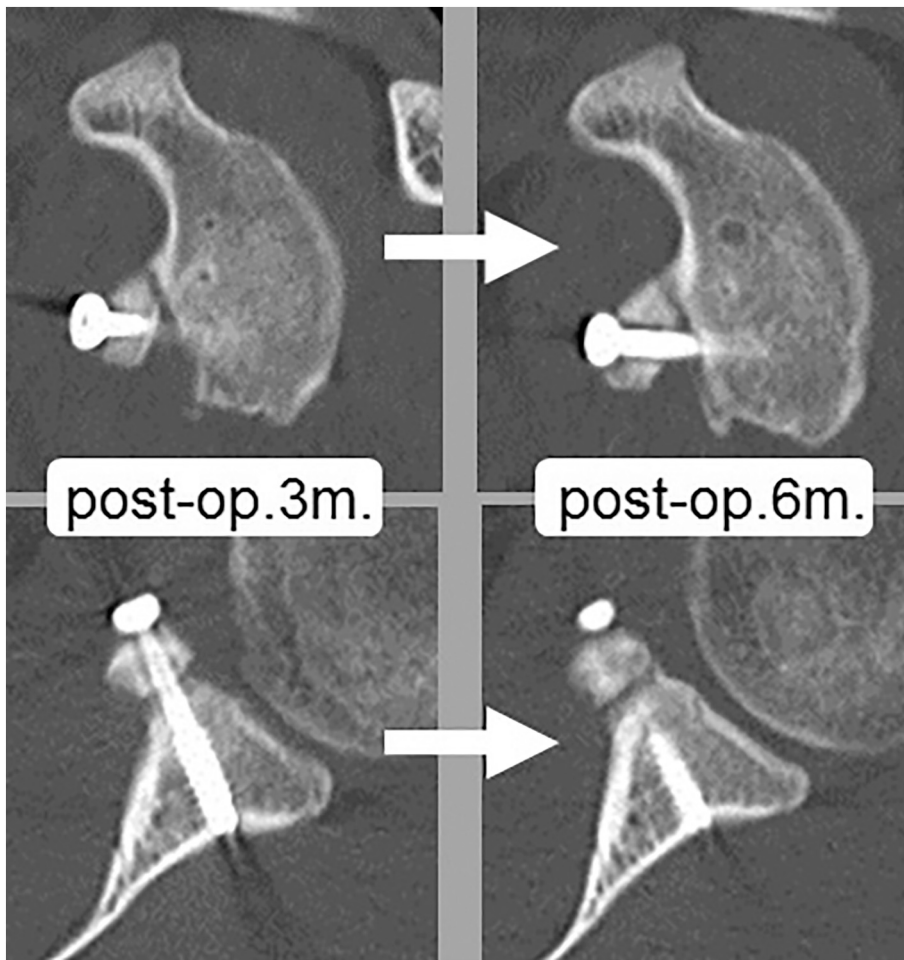
The average length of the coracoid from the tip to the junction between the horizontal and vertical aspect was  $18.3 \pm 1.4$  mm on the preoperative 3D-CT images. The anterior bone loss calculated using the maximum inferior diameter of the glenoid, compared to the maximum inferior diameter of the uninjured contralateral glenoid [2], was  $13.6 \pm 5.0\%$ .

The length of the screw varied from 28 mm to 34 mm in accordance with the measured lengths of the drill holes at the graft and the glenoid.

Seven of 10 shoulders showed bone union at 3 months after the operation (Fig. 1). In two shoulders, the removal of cortex was insufficient, and the bone union was not sufficient at 3 months (Fig. 2), though it was at 6 months. In one shoulder, the distal part of the graft was not in contact with the glenoid, the bone union was not sufficient at 6 months, but it was at 12 months (Fig. 3). In one shoulder, the graft healed in a 70-degree-rotated position, and global bone resorption was observed at 6 months (Fig. 4). In the other 9 shoulders, partial bone resorption was observed at the proximal end of the graft at 6 months, and the degree of resorption was small



**Fig. 2.** CT images at 3 months: 2 shoulders showed insufficient bone union at 3 months, due to insufficient removal of the bone cortex (white arrow).



**Fig. 3.** CT images at 3 and 6 months: 1 shoulder showed insufficient bone union at 6 months, due to the less contact.

(Fig. 5). Non-union or displacement of the graft was not observed. The average thickness of the graft was  $7.2 \pm 1.0$  mm (Fig. 6).

## Discussion

This is a retrospective study to evaluate bone healing after the Latarjet procedure using one-screw fixation. In the original Latarjet procedure published in 1954, the coracoid was fixed using a single screw. Since then, a number of adaptations to the original technique have been described [3]. In the Latarjet procedure, the coracoid is fixed in the “lying down” position, in which the inferior surface of the coracoid is in contact with the glenoid vault. Commonly, the coracoid is fixed using two screws [4].

In the ordinary procedure of the two-screw fixation described by G. Walch, an osteotomy of the coracoid is performed at the junction between the horizontal and vertical aspects. A 3.2-mm drill is used to create 2 holes in the graft, approximately 1 cm apart. The graft is fixed with two 4.5-mm cancellous screws 35 mm in length [5]. In this study, an osteotomy of the coracoid was performed at approximately 15–17 mm posterior to the tip of the coracoid, and the graft was fixed with one 4.5-mm cannulated cancellous screw. The length of the screw varied from 28 mm to 34 mm in accordance with the measured lengths of the drill holes at the graft and the glenoid.

In comparison with the two-screw technique, the one-screw fixation is simpler, with less risk of coracoid fracture. More cancellous bone is in contact with the scapular neck, allowing a better chance of consolidation.

Regarding the screw size and shape in the one-screw fixation compared with the two-screw fixation, one 4.5-mm partially threaded cannulated cancellous screw was used in this study. The more common screw fixation constructs used in the Latarjet procedure include 2 bicortical screws of the following types: fully threaded solid cortical screws, partially threaded solid cancellous screws, and cannulated partially threaded cancellous screws. In one biomechanical cadaveric study, neither screw type nor fixation method significantly influenced biomechanical performance after the Latarjet procedure [6]. The size of the screws is 3.5 mm or 4.0 mm in two-screw fixation and 4.0 mm or 4.5 mm in one-screw fixation. The use of 4.5-mm screws in two-screw fixation might increase the risk of coracoid fracture.



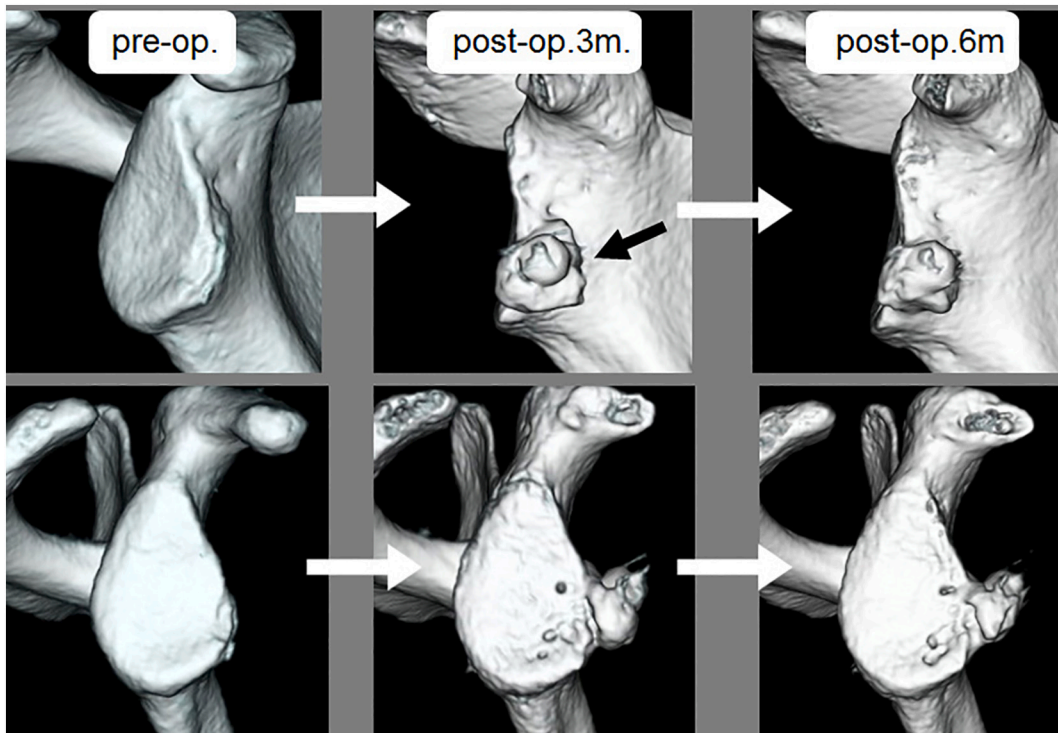

Fig. 4. 3D-CT images at pre-op., 3 and 6 months after op.: 1 shoulder showed the graft fixation at 70 degrees rotated position (black arrow), and the global bone resorption at 6 months.

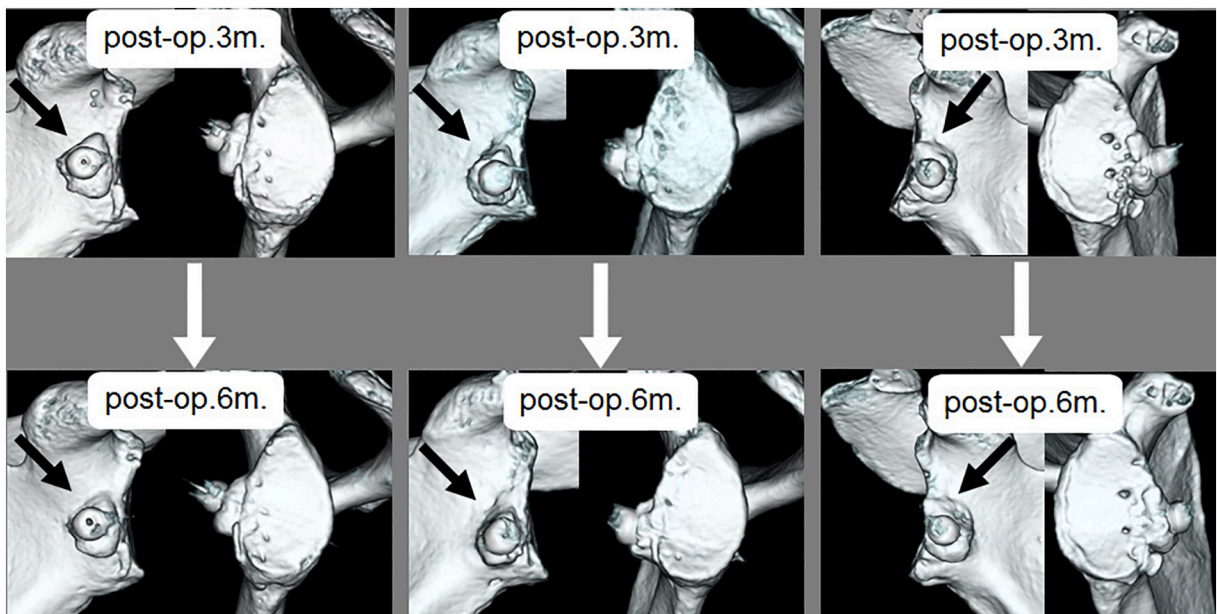


Fig. 5. 3D-CT images at 3 and 6 months: 9 shoulders showed the slight bone resorption at the proximal end of the graft at 6 months.

In the Latarjet procedure, resorption of the proximal part of the graft has been reported [7–9]. The sling effect is reported as the major factor in stabilization [10]. The best size of the graft in the Latarjet procedure seems to be unknown. In this study, the length of the graft was 15–17 mm, and the thickness of the graft was 7.2 mm on average. So far, no instability has been observed clinically.

In this study, 7 shoulders had bone union at 3 months, but 3 shoulders required 6–12 months for bone union. The removal of the

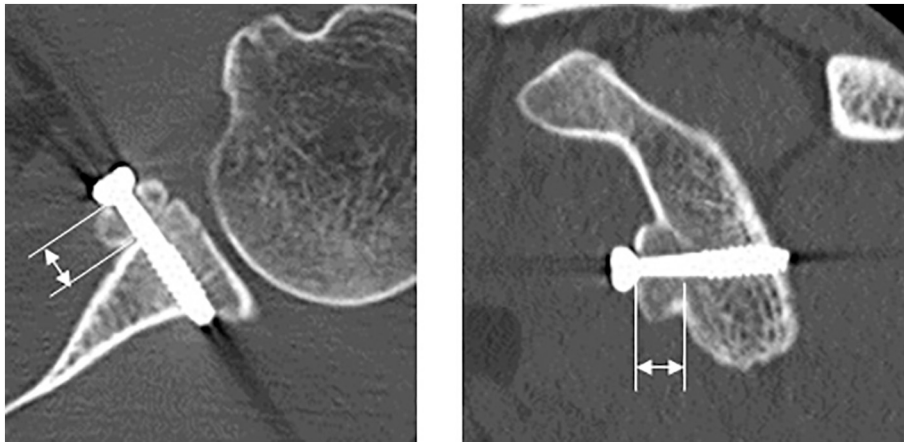


Fig. 6. The average thickness of the graft was  $7.2 \pm 1.0$  mm.

bone cortex from the aspect of the graft facing the glenoid was important for early healing. The adaptation of the graft to the glenoid was also important. In one shoulder, the graft was fixed at a 70-degree-rotated position. Holding the graft during fixation was crucial. In this rotated fixed graft, global resorption was observed. The reason for global resorption is unknown. In the other 9 shoulders, slight resorption was observed at the proximal end of the graft, probably due to the small size of the graft. Non-union or displacement of the graft was not observed, which indicated that the one-screw fixation in the Latarjet procedure might not cause severe problems with bone union.

## Conclusion

The one-screw fixation in the Latarjet procedure did not show the non-union. Sufficient removal of the graft cortex and good contact were needed for early union.

## Ethical committee approval

Not applicable.

## Declaration of competing interest

None.

## Acknowledgments

None.

## References

- [1] Ø. Skare, C.P. Schrøder, P. Mowinckel, O. Reikerås, J.I. Brox, Reliability, agreement and validity of the 1988 version of the Rowe Score, *J Shoulder Elbow Surg* 20 (2011) 1041–1049.
- [2] T.Y. Chuang, C.R. Adams, S.S. Burkhart, Use of preoperative three-dimensional computed tomography to quantify glenoid bone loss in shoulder instability, *Arthroscopy* 24 (2008) 376–382.
- [3] J.A. van der Linde, R. van Wijngaarden, M.P. Somford, D.F. van Deurzen, M.P. van den Bekerom, The Bristow-Latarjet procedure, a historical note on a technique in comeback, *Knee Surg Sports Traumatol Arthrosc* 24 (2016) 470–478.
- [4] P.D. Cowling, M.A. Akhtar, R.Y. Liow, What is a Bristow-Latarjet procedure? A review of the described operative techniques and outcomes, *Bone Joint J* 98-B (2016) 1208–1214.
- [5] N. Mizuno, P.J. Denard, P. Raiss, B. Melis, G. Walch, Long-term results of the Latarjet procedure for anterior instability of the shoulder, *J Shoulder Elbow Surg* 23 (2014) 1691–1699.
- [6] J.J. Shin, J.T. Hamamoto, T.S. Leroux, et al., Biomechanical analysis of Latarjet screw fixation: comparison of screw types and fixation methods, *Arthroscopy* 33 (2017) 1646–1653.
- [7] G. Di Giacomo, A. Costantini, N. de Gasperis, et al., Coracoid graft osteolysis after the latarjet procedure for anteroinferior shoulder instability: a computed tomography scan study of twenty-six patients, *J Shoulder Elbow Surg* 20 (2011) 989–995.
- [8] P. Domos, E. Lunini, G. Walch, Contraindications and complications of the latarjet procedure, *Shoulder Elbow* 10 (2018) 15–24.
- [9] D.L. Haeni, G. Opsomer, A. Sood, et al., Three-dimensional volume measurement of coracoid graft osteolysis after arthroscopic latarjet procedure, *J Shoulder Elbow Surg* 26 (2017) 484–489.
- [10] N. Yamamoto, T. Muraki, K.N. An, et al., The stabilizing mechanism of the latarjet procedure: a cadaveric study, *J Bone Joint Surg Am* 95 (2013) 1390–1397.