

Available online at [www.sciencedirect.com](http://www.sciencedirect.com)

ScienceDirect

journal homepage: [www.elsevier.com/locate/radcr](http://www.elsevier.com/locate/radcr)

## Case Report

# A case report of unusual recurrent bronchopneumonia infections in Mounier-Kuhn syndrome <sup>☆</sup>

Sara Rossi, MD<sup>a,\*</sup>, Federica Volpi, MD<sup>a</sup>, Roberto Castellana, MD<sup>b</sup>, Roberta Pancani, PhD<sup>c</sup>, Federico Dente, MD<sup>c</sup>, Roberta Gaeta, MD<sup>d</sup>, Laura Carrozzi, MD<sup>d</sup>, Emanuele Neri, MD<sup>a</sup>, Chiara Romei, PhD<sup>e</sup>

<sup>a</sup>Department of Translational Research, Academic Radiology, University of Pisa, Pisa, Italy

<sup>b</sup>Department of Radiology, Parini Hospital, Aosta, Italy

<sup>c</sup>Department of Surgery, Medical and Molecular Pathology and Critical Care, University of Pisa, Pisa, Italy

<sup>d</sup>Pneumology Unit, Pisa University Hospital, Pisa, Italy

<sup>e</sup>Department of Diagnostic Imaging, Radiology Unit, Pisa University Hospital, Pisa, Italy

## ARTICLE INFO

## Article history:

Received 20 November 2023

Revised 7 March 2024

Accepted 11 March 2024

## Keywords:

Mounier-Kuhn syndrome

Tracheobronchomegaly

Recurrent bronchopneumonia

Recurrent respiratory infections

## ABSTRACT

Mounier-Kuhn syndrome is a rare airway disease characterized by tracheal and bronchial dilatation, primarily affecting middle-aged men. We present a case of Mounier-Kuhn syndrome in a 40-year-old man with a history of recurrent respiratory infections since adolescence. The diagnostic journey involved a multidisciplinary approach incorporating clinical evaluation, radiological imaging, and bronchoscopy. Computed tomography findings, including maximum intensity projection reconstructions and 3D rendering, facilitated the diagnosis by revealing significant airway dilation and associated abnormalities. Treatment primarily focused on supportive measures, including antibiotic therapy and respiratory physiotherapy.

This case underscores the importance of considering Mounier-Kuhn syndrome in patients with recurrent respiratory infections and highlights the role of advanced imaging techniques in diagnosis.

© 2024 The Authors. Published by Elsevier Inc. on behalf of University of Washington.

This is an open access article under the CC BY-NC-ND license

(<http://creativecommons.org/licenses/by-nc-nd/4.0/>)

Abbreviation: CT, computed tomography; MIP, maximum intensity projection.

<sup>☆</sup> Competing Interests: The authors declare that they have no known competing financial interests or personal relationships that could have appeared to influence the work reported in this paper.

\* Corresponding author.

E-mail address: [s.rossi105@studenti.unipi.it](mailto:s.rossi105@studenti.unipi.it) (S. Rossi).

<https://doi.org/10.1016/j.radcr.2024.03.028>

1930-0433/© 2024 The Authors. Published by Elsevier Inc. on behalf of University of Washington. This is an open access article under the CC BY-NC-ND license (<http://creativecommons.org/licenses/by-nc-nd/4.0/>)

## Introduction

Mounier-Kuhn syndrome is a rare, chronic, and irreversible airway disease characterized by tracheal and bronchial dilatation, predominantly affecting middle-aged men [1].

The etiology remains unclear, but it may involve alterations in connective tissue and smooth muscle, resulting in defects in the tracheobronchial wall [2].

Some authors propose a genetic etiology because it is often associated with other autosomal recessive disorders like Ehlers-Danlos and Marfan's syndrome [3]. On the other hand, some other authors suggest an acquired nature related to pulmonary fibrosis, mechanical ventilation, especially for preterm neonates, and radiotherapy [4].

Clinical presentation varies, with symptoms ranging from absent or minimal with preserved lung function to severe respiratory failure. However, the most common presentation includes cough, dyspnea, and recurrent respiratory infections [4,5].

In symptomatic patients, therapy is supportive focusing on respiratory physiotherapy to clear secretions and antibiotic therapies use during infectious exacerbations [6].

We report a case of Mounier-Kuhn syndrome in a 40-year-old man with a history of recurrent respiratory infections since adolescence, with a particular emphasis on CT findings and reconstructions. Specifically, minimum intensity projection (MIP) and 3D rendering offer clearer and more accessible visualization of tracheal and bronchial dilation.

The article adheres to the CARE (CAse REport) guidelines [7] with the CARE checklist. Specifically, we subdivided this case report in these topics: title, keywords, abstract, introduction, patient information (underlining clinical findings, historical pathologies, and previous infections, diagnostic assessment, therapeutic intervention, outcomes) and case discussion.

## Case presentation

A 40-year-old man was admitted to our hospital respiratory department with a chief complaint of recurrent fever and pro-

ductive cough. He had a history of recurring respiratory infections since puberty, with more frequent episodes in the past 2 years.

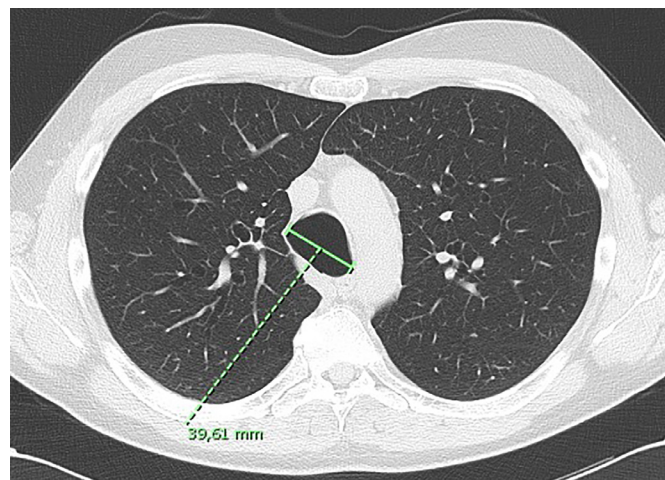
Specifically, in July 2022, he had a mild case of SARS-CoV-2 infection, presenting with fever and productive cough. In November 2022, he developed a worsening productive cough due to influenza A (H<sub>3</sub>N<sub>2</sub>) infection. In March 2023, due to fever and pharyngodynia, he underwent a throat swab that tested positive for *Streptococcus pneumoniae*. Following conservative treatment with antibiotics, he showed clinical improvement.

However, in April 2023, he experienced coughing and elevated inflammatory markers. After a few days, he developed a fever and diarrhea for a day, which resolved spontaneously, but the cough persisted. In mid-April, he experienced a recurrence of fever, prompting initiation of antibiotic therapy under medical advice. Despite an initial response, his fever persisted, reaching 39°C after a week and becoming unresponsive to paracetamol. He also experienced cough, chills, and night sweats prompting his admission to the hospital. Throat swab and sputum culture performed prior to antibiotic treatment yielded positive results for *S pneumoniae* and *Haemophilus influenzae*.

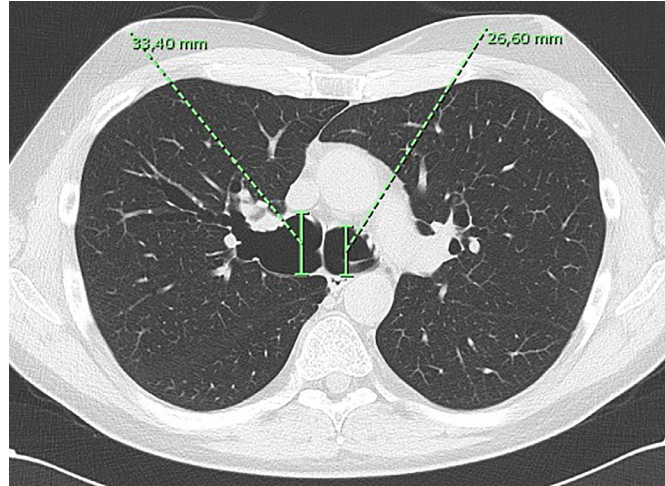
The patient did not have a diagnosis of asthma but was a former smoker with a previous smoking history of approximately 14 cigarettes per day for 10 years. His family history revealed that his mother had asthma. Additionally, he worked as an employee.

Laboratory data demonstrated elevated values of white blood cell count and C-reactive protein. CT scans revealed dilatation of the trachea and main bronchi (Fig. 1), with diameters of the trachea, right main bronchus, and left main bronchus measured at 40 mm, 33 mm, and 27 mm, respectively (Figs. 2-4). Associated findings included wall thickening, mucoid impaction, and consolidations (Fig. 7). The tracheal and bronchial dilatation was more evident on maximum intensity projection (MIP) reconstructions (Fig. 5). Additionally, a 3D reconstruction program was used to analyze the airway course for any possible diameter alterations or changes in the wall (Fig. 6).

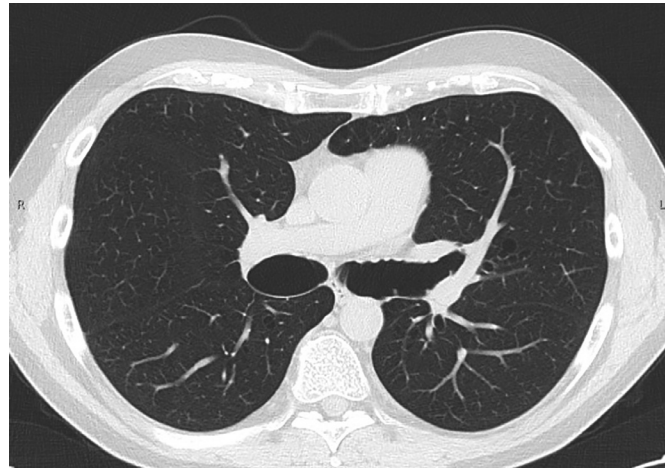
Based on CT findings, Mounier-Kuhn syndrome was suspected. Further assessment with bronchoscopy confirmed tra-



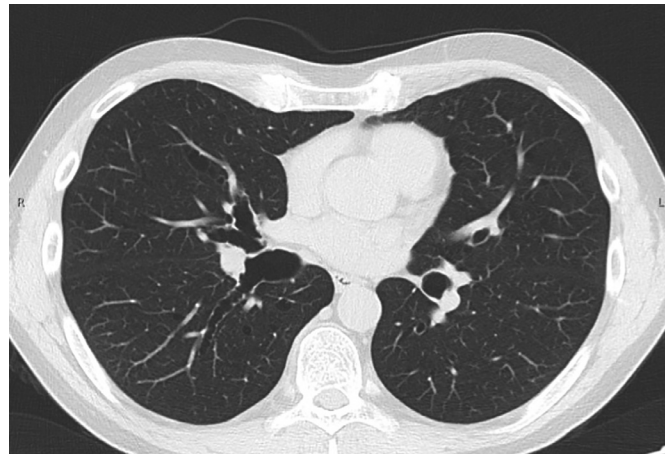
**Fig. 1 – Thoracic computed tomography (CT) demonstrates dilatation of the trachea, measuring about 40 mm.**



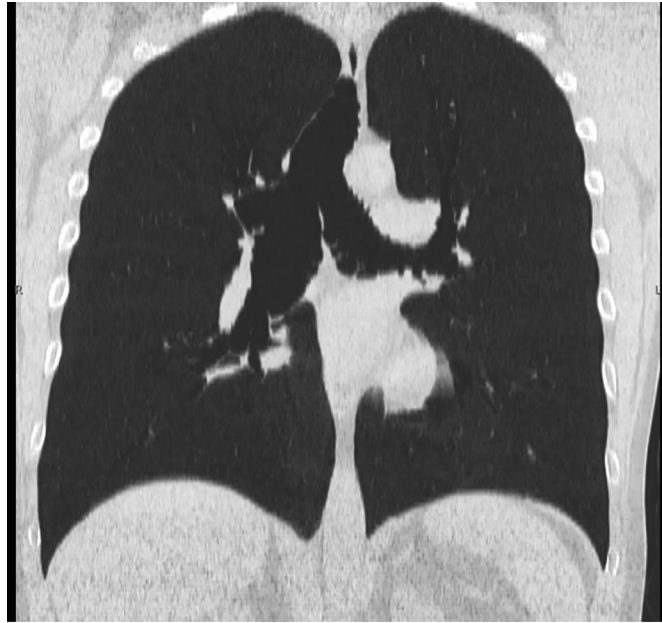
**Fig. 2 – Dilatation in the main bronchi: 33 mm of the right bronchus and about 27 mm in the left one.**



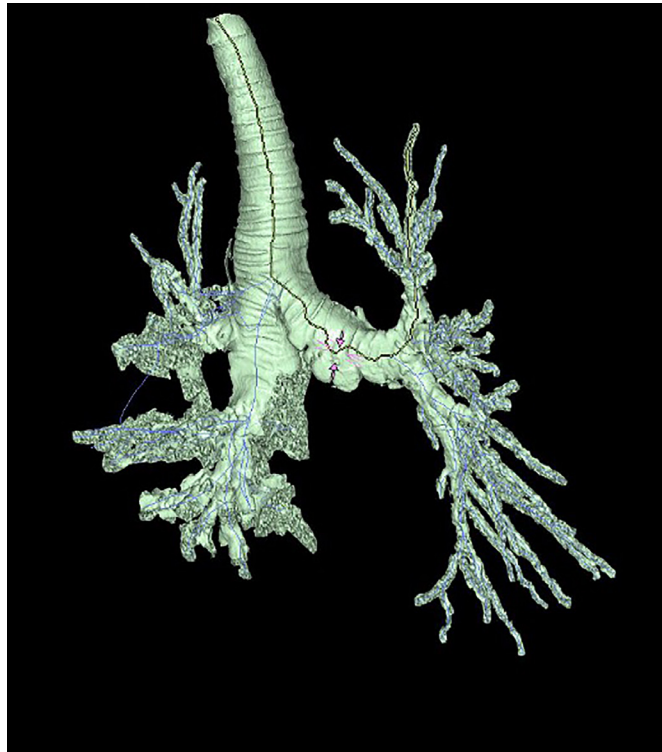
**Fig. 3 – Bronchial walls appear irregular and scalloped.**



**Fig. 4 – Bronchiectasis in the middle and lower lobe of the right lung.**

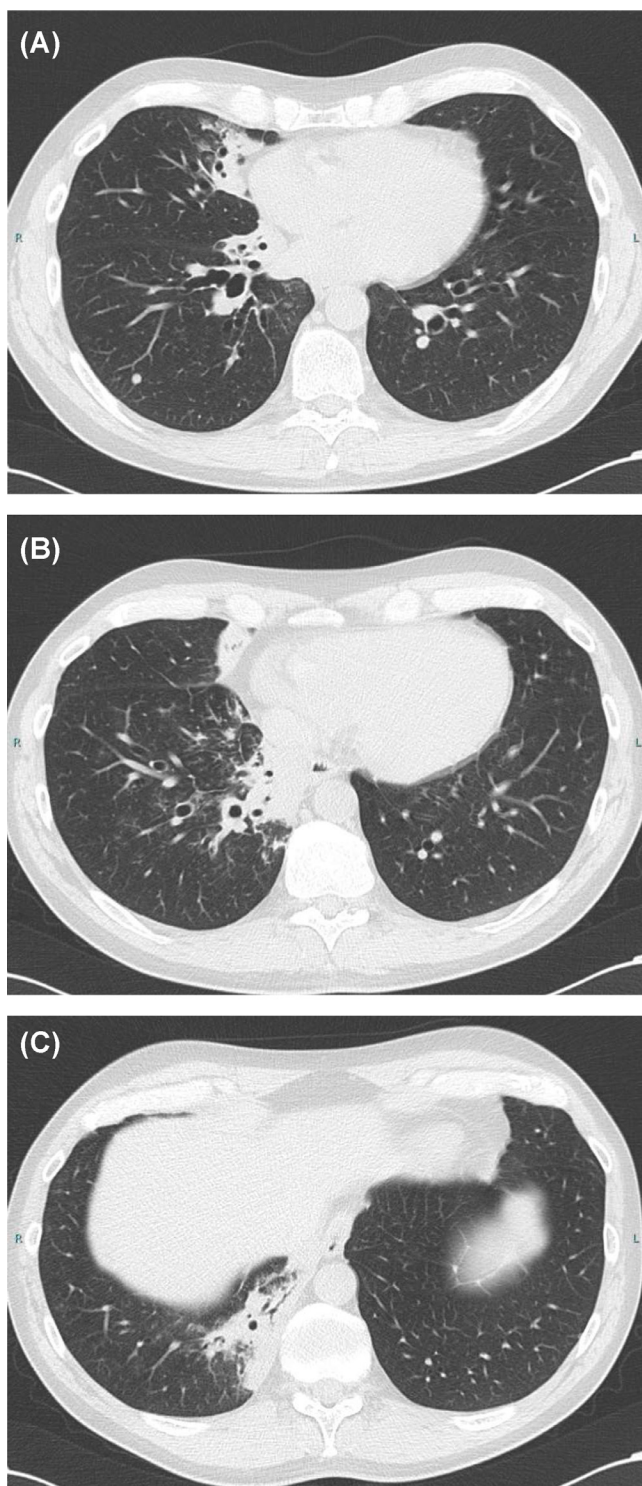


**Fig. 5 – Thoracic CT scan with minimum intensity projection shows multiple diverticula and dilatation of the trachea and bronchi.**



**Fig. 6 – 3D view/processing program evidences dilatation of the main bronchi and diverticula (pink arrows) of the wall of the left bronchus.**





**Fig. 7 – Multiple consolidations with air bronchogram sign in the middle lobe (A), and in the middle segment of right lower lobe (B and C).**

cheal and main bronchial dilatation and revealed mucosal atrophy, absence of a muscular layer, and copious yellowish secretions.

The diagnosis of Mounier-Kuhn syndrome was established based on radiological and endoscopic findings, along

with clinical symptoms and patient history. The patient's condition improved after conservative treatment, which consisted of a prolonged course of amoxicillin and clavulanic acid.

Recently, from December 30, 2024, to January 5, 2024, the patient experienced pneumonia caused by influenza A/H3 virus, which was treated with oseltamivir and antibiotics.

## Discussion

Munier-Kuhn syndrome is a rare and underdiagnosed disease initially identified at autopsy by Czyhlarz in 1897 but it was not until 1932 that Mounier-Kuhn associated the endoscopic and radiologic appearance of enlarged airways with recurrent respiratory infections [8]. Its prevalence remains unknown, with approximately 300 reported cases to date [9,10].

Symptoms of Mounier-Kuhn syndrome are not specific and may resemble those of chronic bronchitis and bronchiectasis, often manifesting as chronic, recurrent respiratory infections with productive cough, purulent sputum, dyspnea, and hemoptysis [4]. Some patients, as in our case report, describe experiencing recurrent respiratory infections since childhood or adolescence.

Spirometry may demonstrate normal findings, but more commonly reveals an obstructive ventilatory disorder with increased capacity of pulmonary function (CPT) and residual volume (RV) [11].

However, Mounier-Kuhn syndrome can be diagnosed and differentiated from chronic bronchitis through distinct radiological and bronchoscopy observations. Radiological diagnosis involves measuring the maximum diameter of trachea and main bronchi on a chest X-ray or CT. Tracheobronchomegaly is diagnosed in adults when the diameter of the trachea exceeds 3.0 cm, the right main bronchus exceeds 2.4 cm, or the left main bronchus exceeds 2.3 cm [11]. Their contour may appear irregular or scalloped with sacculation, resulting from defective respiratory wall integrity leading to diverticula and mucous stagnation. These conditions predispose to recurrent infections and bronchiectasis.

Mounier-Kuhn syndrome is classified in 3 subtypes. Type I presents with mild symmetrical dilatation of the trachea and/or the main bronchi. Type II exhibits evident dilatation and diverticula. Type III, involves diverticula extending to the distal bronchi [8].

CT reconstructions may be very useful for demonstrating tracheal and main bronchi dilatation, as seen in our case.

Additionally, chest X-ray or CT scans often reveal other lung abnormalities, including consolidations of lung parenchyma and radiolucent areas indicative of cystic/bronchiectasis changes.

Bronchoscopy typically confirms the diagnosis by demonstrating reduction or absence smooth muscle of tracheobronchial wall, along with airway secretions increased diameter of trachea and main bronchi. Treatment typically involves antibiotics and mucolytics to alleviate symptoms. vaccination is recommended to prevent infections and reduce acute exacerbations [12].

---

## Conclusion

Munier-Kuhn syndrome should be considered in patients with a history of recurrent respiratory infections since childhood or adolescence. Diagnosis relies heavily on imaging findings, with MIP reconstructions and 3D volume rendering of CT images being particularly valuable for highlighting tracheal and primary bronchial dilation.

---

## Patient consent

Patient gives consent for information about himself to appear in this journal article. Participation is completely voluntary. Consent is given in both written and oral modalities. Doctors explain him that every personal information will be published without his name and every attempt will be made to ensure anonymity.

---

## REFERENCES

- [1] William E B, Helms CA. *Fundamentals of diagnostic radiology*. Philadelphia, PA, USA: Lippincott Williams and Wilkins; 2007.
- [2] Rjimati M, Serraj M, Elbiaze M, Benjelloun MC, Amara B. Mounier-Kuhn syndrome (tracheobronchomegaly): radiological diagnosis. *Radiol Case Rep* 2021;16(9):2546–50. doi:10.1016/j.radcr.2021.06.021.
- [3] Johnston RF, Green RA. Tracheobronchiomegaly. Report of five cases and demonstration of familial occurrence. *Am Rev Respir Dis* 1965;91:35–50.
- [4] Krustins E, Kravale Z, Buls A. Mounier-Kuhn syndrome or congenital tracheobronchomegaly: a literature review. *Respir Med* 2013;107(12):1822–8 Epub September 6, 2013. doi:10.1016/j.rmed.2013.08.042.
- [5] Satia I, Dua B, Singh N, et al. Tracheobronchomegaly, cough and recurrent chest infection: Mounier-Kuhn syndrome. *ERJ Open Res* 2020;6(2):00138–2020. doi:10.1183/23120541.00138-2020.
- [6] Imzil A, Bounoua F, Amrani HN, Moubachir H, Serhane H. Tracheobronchomegaly (Mounier-Kuhn Syndrome) with CT and bronchoscopic correlation: a case report. *Radiol Case Rep* 2022;17(10):3611–15. doi:10.1016/j.radcr.2022.06.077.
- [7] Riley DS, Barber MS, Kienle GS, et al. CARE guidelines for case reports: explanation and elaboration document. *J Clin Epidemiol* 2017;89:218–35.
- [8] Shin MS, Jackson RM, Ho KJ. Tracheobronchomegaly (Mounier-Kuhn syndrome): CT diagnosis. *AJR Am J Roentgenol* 1988;150(4):777–9. doi:10.2214/ajr.150.4.777.
- [9] Orphanet: <https://www.orpha.net/en/disease/detail/3347>
- [10] Krustins E. Mounier-Kuhn syndrome: a systematic analysis of 128 cases published within last 25 years. *Clin Respir J* 2016;10(1):3–10 Epub August 26, 2014. doi:10.1111/crj.12192.
- [11] Quentin C, Lefevre N, Bodart E, Hanssens L. Mounier Kuhn syndrome presenting with recurrent atelectasis. *Acta Clin Belg* 2018;73(3):233–5.
- [12] Tanay J, Ashwin S, Shibani V, Bhupendra C, Ekjot G, Arun C. A rare case of Mounier-Kuhn syndrome with bronchial asthma. *Int J Med Res Health Sci* 2016;5(7):105–8.