

Sporadic Creutzfeldt–Jakob disease presenting as dizziness and cognitive decline

A case report

Yuhao Xu, MD^a, Jianhui Xu, MD^a, Jian Zhang, MD^a, Zhirong Cai, MD^a, Hong Wei, MD^a, Ming Yu, MD, PhD^{a,*}, Yuefeng Li, MD, PhD^{b,*}

Abstract

Rationale: Creutzfeldt–Jakob disease (CJD) is an infrequent and rapidly fatal neurodegenerative disease without effective cure. Common presentations of CJD include rapidly progressive cognitive decline, behavioral changes, cerebellar dysfunction, and visual disturbances. Since clinicians may see only very few cases during their professional career, it is important to be familiar with the clinical presentation and progression, and allow for quick diagnosis.

Patient concerns: We reported an elderly woman had recurrent attacks of dizziness in the preceding month. She began to suffer progression of memory disturbance half a month before admission and was admitted to our department in a coma.

Diagnosis: The accessory examinations of magnetic resonance imaging (MRI), electroencephalography (EEG), 14-3-3 protein in cerebrospinal fluid and S100 protein in serum support the diagnosis of sporadic CJD (sCJD). Combined with this evidence and clinical symptom, we made a clinical diagnosis of sCJD.

Interventions: Supportive treatment.

Outcomes: After 2 months of active treatment, the patient's condition had not improved, and the patient died 82 days after admission.

Lessons: Clinicians should attach importance to sCJD, which is significant for the prevention of transmission and treatment.

Abbreviations: CJD = Creutzfeldt–Jakob disease, sCJD = sporadic CJD, DWI = diffusion-weighted imaging, EEG = electroencephalography, CSF = cerebrospinal fluid.

Keywords: 14-3-3 protein, Creutzfeldt–Jakob disease, diffusion weighted imaging, electroencephalography, S100 protein

1. Introduction

Creutzfeldt–Jakob disease (CJD) is a fatal, degenerative disease of the central nervous system caused by mutated prion proteins, and

Editor: N/A.

All procedures performed in studies involving human participants were in accordance with the ethical standards of the institutional research committee and with the 1964 Helsinki declaration and its later amendments or comparable ethical standards. The Institutional Review Board of the Affiliated Hospital of Jiangsu University has approved the research protocol. Informed written consent was obtained from the patient's guardian for publication of this case report and accompanying images.

The authors declare that they have no conflict of interest.

^a Department of Neurology, ^b Department of Radiology, The Affiliated Hospital of Jiangsu University, Zhenjiang, Jiangsu, China.

* Correspondence: Ming Yu, Department of Neurology, The Affiliated Hospital of Jiangsu University, 438 Jiefang Road, Zhenjiang, Jiangsu, 212001, China (e-mail: yuming7251@163.com); Yuefeng Li, Department of Radiology, The Affiliated Hospital of Jiangsu University, 438 Jiefang Road, Zhenjiang, Jiangsu, 212001, China (e-mail: jiangdalyf@126.com).

Copyright © 2019 the Author(s). Published by Wolters Kluwer Health, Inc. This is an open access article distributed under the terms of the Creative Commons Attribution-Non Commercial-No Derivatives License 4.0 (CCBY-NC-ND), where it is permissible to download and share the work provided it is properly cited. The work cannot be changed in any way or used commercially without permission from the journal.

Medicine (2019) 98:24(e16002)

Received: 3 January 2019 / Received in final form: 23 April 2019 / Accepted: 17 May 2019

<http://dx.doi.org/10.1097/MD.00000000000016002>

it affects both humans and animals. Because of its mortality and infectivity, it has been given much attention in clinical setting. Common clinical manifestations of CJD include rapid and progressive cognitive decline, cerebellar dysfunction, behavioral changes, and visual disturbances.^[1] CJD can be easily misdiagnosed, and there is no current treatment. However, an early diagnosis can provide a time period for treatment and avoid unnecessary transmission in the hospital, and doctor-patient disputes.^[2] Here, we report an elderly woman with CJD who initially presented with dizziness and memory disturbance. The results of her auxiliary examination are typical and this could be a good case for clinical education about CJD.

2. Case Report

A previously healthy 68-year-old Chinese woman presented to our Department of Neurology in an unconsciousness state. The patient's family reported that she had a sudden onset of dizziness in the preceding month and recurrent attacks, but the patient did not pay attention to them. Half a month previously, her family noticed she suffered from memory disturbance, when she sometimes forgot to pull the key out of the door when leaving, forgot to close the refrigerator door, and complained of money being stolen. A week before admission, the patient's symptoms slowly and gradually worsened. Eight hours previously, the patient suddenly experienced a disturbance of consciousness; at first, the patient could communicate with her family with simple words but then fell into a coma within half an hour. Her past

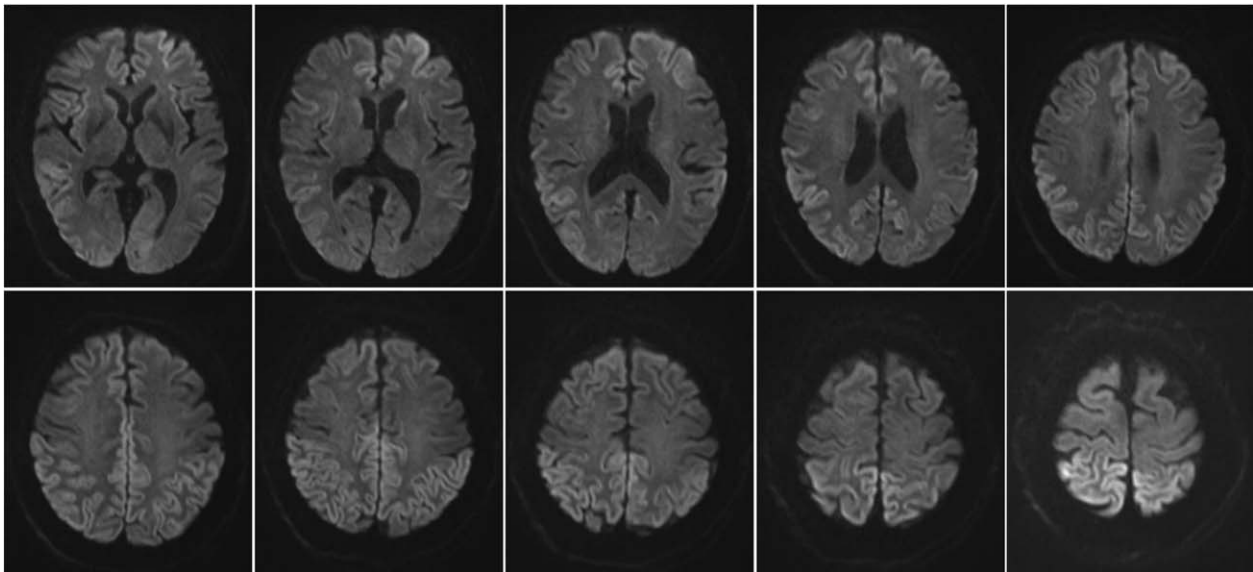


Figure 1. The DWI of the patient showed a slight increase in signal intensity in the bilateral parietal occipital and frontal lobes. DWI=diffusion weighted imaging.

medical history revealed she only had hypertension, and the patient regularly took antihypertensive drugs. She did not smoke tobacco. She did not have any other previous or current drug or alcohol use, which was corroborated by her family. She had no significant familial history.

The Glasgow Coma Scale was 6/15 (E1V1M4). Her blood pressure was normal (135/78 mmHg), with all other observations within a normal range. Respiratory, cardiovascular, and abdominal examinations were unremarkable. However, abnormalities were noticed on a neurological examination. She had abnormal eye movements with bilateral spontaneous horizontal nystagmus. A reflex system examination showed that the Hoffman sign was positive and limb tendon reflex was negative. Additionally, she sometimes had upper limb convulsions and lower limb clonus. During the initial admission, our preliminary diagnoses considered encephalitis, cerebrovascular disease, or metabolic encephalopathy.

Routine blood examination showed a slight increase in neutrophil granulocytes ($7.4 \times 10^9/L$), and C-reactive proteins (11.2 mg/L). Renal function examination indicated a mildly raised creatinine level of 10.31 mmol/L (reference range 3.5–8.1) and nitrogen level of 129.7 $\mu\text{mol/L}$ (reference range 46–98). Electrolyte examination showed that her blood sodium was 150 mmol/L (reference range 137–147). Plasma lactic acid was 3.7 mmol/L (reference range 0.7–2.7). Tests of liver and thyroid function, coagulation, glycosylated hemoglobin, index of tumors, and urine and stool routines were all within a normal range. An electrocardiogram and chest X-ray revealed no abnormalities. A computed tomography scan of her head showed encephalomalacia. The cranial magnetic resonance imaging (MRI) indicated a slight increase in signal intensity in the bilateral parietal-occipital and frontal lobes in diffusion-weighted imaging (DWI) (Fig. 1).

Based on the clinical symptoms and imaging manifestations, we considered the possibility of prion disease in this patient. To find more supporting evidence, we further examined the patient by electroencephalography (EEG), lumbar puncture and serum S100 protein. The EEG showed synchronous extensibility and high amplitude (2–2.3 Hz) of a triphasic sharp wave that

continued to appear under the background of diffuse low amplitude activity, which was symmetrical and could be observed bilaterally (Fig. 2). These abnormal EEG manifestations were reported as suggestive of bilateral cortical dysfunction with possible causes including prion disease, viral encephalitis, metabolic, and vascular diseases. Lumbar puncture was performed and showed routine, biochemistry, immunoglobulin G and bacteria culture in cerebrospinal fluid with no abnormalities. Meanwhile, a cerebrospinal fluid (CSF) sample was sent to detect the 14-3-3 protein, and the 14-3-3 protein was found positive in the CSF by Western blot (Fig. 3A). Furthermore, the serum S100 protein was 358 ng/mL which was higher than the normal reference range (32–267). Afterward, we monitored serum S100 protein once a week for 4 weeks and found that the serum S100 protein steadily increases (Fig. 3B). Thus, we clinically diagnosed this patient with Sporadic CJD (sCJD). After 2 months of active treatment, the patient's condition had not improved, and the patient died 82 days after admission.

3. Discussion

CJD is the most common form of prion diseases in humans.^[3] It is a fatal, neurodegenerative disease that typically results in subacute and progressive deterioration in cognitive, motor and behavioral function over a period of weeks to months.^[4] According to different causes of the disease, CJD can be divided into sporadic, variant, familial and iatrogenic forms, and genetic analysis of the prion protein gene can help identify the different forms.^[5] Although there is still no effective treatment, the early recognition and diagnosis of CJD have a significant effect on preventing its spread.

CJD has attracted more clinical attention due to its atypical clinical manifestations and the lack of early diagnostic methods and effective treatment.^[6,7] The classical clinical features of sCJD are rapid cognitive decline, ataxia, and myoclonus termination in an akinetic mute state, which accounts for almost 85% of cases.^[8] The diagnosis of CJD is dependent upon assessment of special investigations and clinical features. The patient we reported here

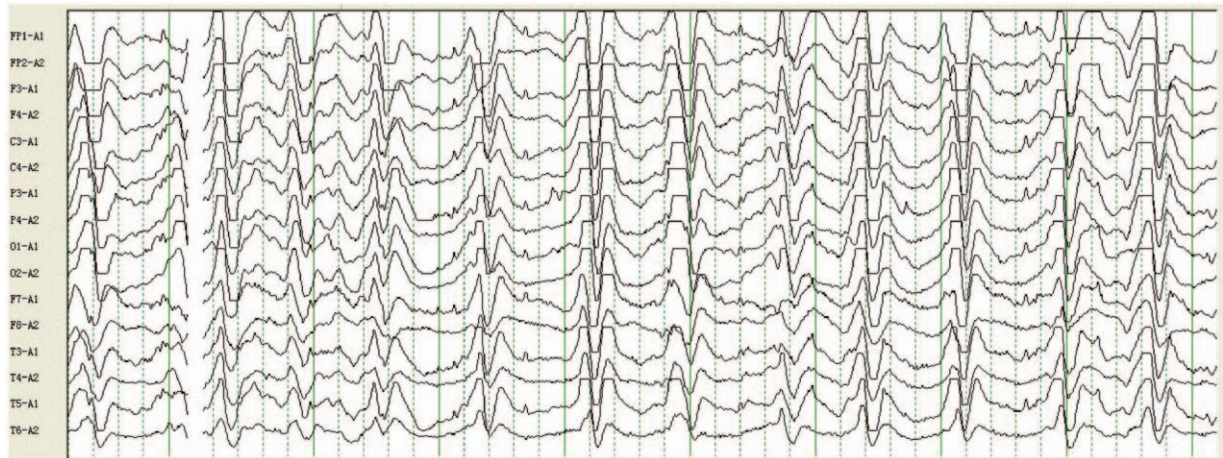

Figure 2. The EEG of the patient showed synchronous extensibility and high amplitude (2–2.3Hz) of a triphasic sharp wave that continued to appear under the background of diffuse low amplitude activity, which was symmetry and could be observed bilaterally. EEG = electroencephalography.

experienced recurrent dizziness as the initial symptom, which is atypical and easily misdiagnosed. After half of a month, the patient appeared progressive deterioration in cognitive abilities, which is the classical symptom of sCJD, and quickly fell into a coma before been transported to the hospital. After admission, we performed MRI and EEG tests. Based on the clinical manifestation and the results of the MRI and EEG tests, we have taken the possibility of sCJD into account. Therefore, for the diagnosis of CJD, a doctor’s awareness of this disease is of great significance.

The gold standard for diagnosis of CJD is pathological confirmation from a brain biopsy, which is difficult to achieve and has numerous problems regarding a high risk of transmission.^[7,9] Further diagnostic options are detection of characteristic MRI and EEG findings. MRI is the most useful assessment for sCJD, as it is highly sensitive and specific, relatively non-invasive and widely available.^[7] Classical MRI findings in sCJD, including high signal in the caudate, putamen, or cortex (or a combination of these) on DWI and fluid-attenuated inversion recovery sequences, are present in approximately 80% of cases.^[10]

DWI is more sensitive to detecting early cortical and subcortical changes.^[10] The DWI of this patient exhibited a lace-like slight increase in signal intensity in bilateral parietal-occipital and frontal lobes, which is consistent with many other reports of sCJD.^[11] The typical EEG appearances in sCJD are periodic, triphasic sharp wave complexes.^[10] The EEG of this patient displayed triphasic sharp wave that continued to appear and could be observed bilaterally, which were typical EEG manifestations and supported the diagnosis of sCJD. It is worth noting that these changes in the right clinical setting have a 90% specificity for CJD, but are also known to occur in other conditions, such as the final stages of Alzheimer’s disease, Lewy body dementia, and metabolic encephalopathies.^[12] Aside from the MRI and EEG, we also detected 14-3-3 protein in cerebrospinal fluid and S100 protein in serum, which are well-known highly specific markers of sCJD.^[13,14] Test results showed positive detection of 14-3-3 protein in cerebrospinal fluid and progressive elevation of S100 protein in serum, and these results provided more evidence to support the diagnosis of sCJD.

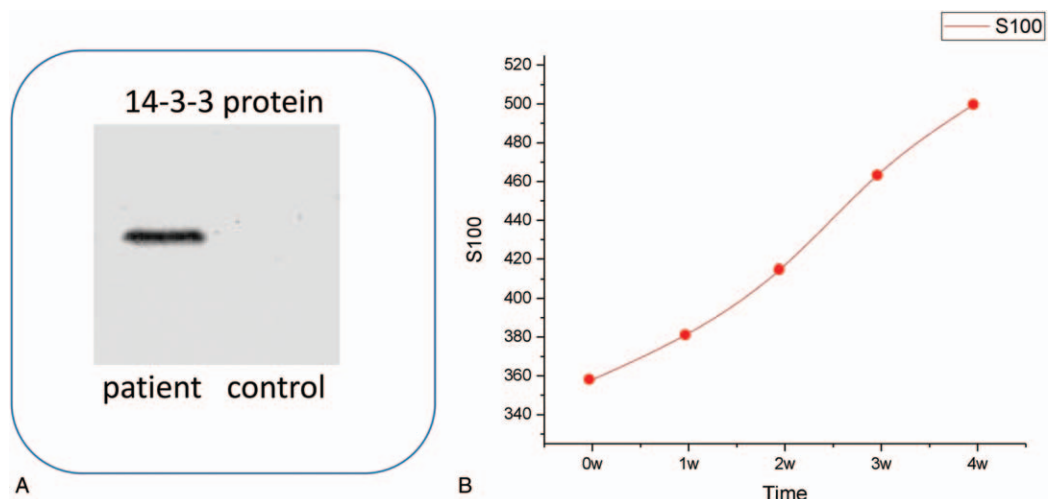


Figure 3. The 14-3-3 protein in CSF showed positive result (A) and the S100 protein in serum showed a sustained increase (B). CSF = cerebrospinal fluid.

sCJD is a fatal disease, and there is no effective cure. In this case report, the patient's symptoms of progressive deterioration in cognition and course of the disease were consistent with sCJD. The accessory examinations of MRI, EEG, 14-3-3 protein in cerebrospinal fluid and S100 protein in serum also support the diagnosis of sCJD. Combined with this evidence, we made a clinical diagnosis of sCJD despite the lack of the genetic testing and biopsy. Afterward, we quickly quarantined her and reported her to the Infectious Disease Agency. The clinical treatment of sCJD mainly includes symptomatic and supportive treatment and intensive care. In this study, the patients received treatment actively but soon died due to the lack of specific medications.

The diagnosis of CJD has improved in recent years with the advent of improved brain imaging, the development of specific CSF tests in sCJD, and the potential for diagnostic tests using serum in patients with CJD. Case reports such as this are vital in raising awareness of the clinical presentation and course of this rare neurodegenerative disorder.

Author contributions

Investigation: Yuhao Xu, Jianhui Xu.

Writing - Original Draft: Yuhao Xu.

Resources: Jianhui Xu.

Validation: Jianhui Xu.

Data curation: Jian Zhang, Zhirong Cai.

Software: Jian Zhang.

Methodology: Zhirong Cai, Hong Wei.

Formal analysis: Hong Wei.

Conceptualization: Ming Yu, Yuefeng Li.

Writing – review & editing: Ming Yu, Yuefeng Li.

References

- [1] Mackenzie G, Will R. Creutzfeldt–Jakob disease: recent developments. *F1000Res* 2017;6:2053.
- [2] Watts JC, Bourkas MEC, Arshad H. The function of the cellular prion protein in health and disease. *Acta Neuropathol* 2018;135:159–78.
- [3] Johnson RT. Prion diseases. *Lancet Neurol* 2005;4:635–42.
- [4] Atalay FO, Tolunay S, Ozgun G, et al. Creutzfeldt–Jakob disease: report of four cases and review of the literature. *Turk Patoloji Derg* 2015;31:148–52.
- [5] Burchell JT, Panegyres PK. Prion diseases: immunotargets and therapy. *Immunotargets Ther* 2016;5:57–68.
- [6] Lee J, Hyeon JW, Kim SY, et al. Review: laboratory diagnosis and surveillance of Creutzfeldt–Jakob disease. *J Med Virol* 2015;87:175–86.
- [7] Manix M, Kalakoti P, Henry M, et al. Creutzfeldt–Jakob disease: updated diagnostic criteria, treatment algorithm, and the utility of brain biopsy. *Neurosurg Focus* 2015;39:E2.
- [8] Loftus T, Chen D, Looby S, et al. CJD surveillance in the Republic of Ireland from 2005 to 2015: a suggested algorithm for referrals. *Clin Neuropathol* 2017;36:188–94.
- [9] Lopez FJG, Ruiz-Tovar M, Almazan-Isla J, et al. Risk of transmission of sporadic Creutzfeldt–Jakob disease by surgical procedures: systematic reviews and quality of evidence. *Euro Surveill* 2017;22:1–4.
- [10] Zerr I, Kallenberg K, Summers DM, et al. Updated clinical diagnostic criteria for sporadic Creutzfeldt–Jakob disease. *Brain* 2009;132(Pt 10):2659–68.
- [11] Mao-Draayer Y, Braff SP, Nagle KJ, et al. Emerging patterns of diffusion-weighted MR imaging in Creutzfeldt–Jakob disease: case report and review of the literature. *AJNR Am J Neuroradiol* 2002;23:550–6.
- [12] Budka H, Aguzzi A, Brown P, et al. Neuropathological diagnostic criteria for Creutzfeldt–Jakob disease (CJD) and other human spongiform encephalopathies (prion diseases). *Brain Pathol* 1995;5:459–66.
- [13] Fourier A, Dorey A, Perret-Liaudet A, et al. Detection of CSF 14-3-3 protein in sporadic Creutzfeldt–Jakob disease patients using a new automated capillary western assay. *Mol Neurobiol* 2018;55:3537–45.
- [14] Steinacker P, Weidehaas K, Ceppek L, et al. Influence of the blood-CSF-barrier function on S100B in neurodegenerative diseases. *Acta Neurol Scand* 2013;128:249–56.