



Systematic review of rectal foreign bodies in older men: humanistic care and a novel challenge for society

Zhenyu Yang^{#^}, Peiyuan Xin[#], Shuai Zhou[#], Chuxin Zhou[#], Xianli He, Guoqiang Bao

Department of General Surgery, Tangdu Hospital, Air Force Medical University, Xi'an, China

Contributions: (I) Conception and design: G Bao, X He; (II) Administrative support: X He; (III) Provision of study materials or patients: Z Yang; (IV) Collection and assembly of data: Z Yang, S Zhou; (V) Data analysis and interpretation: P Xin, C Zhou; (VI) Manuscript writing: All authors; (VII) Final approval of manuscript: All authors.

[#]These authors contributed equally to this work.

Correspondence to: Guoqiang Bao; Xianli He. Department of General Surgery, Tangdu Hospital, Air Force Medical University, No. 569 Xinsi Road, Xi'an 710038, China. Email: guoqiang@fmmu.edu.cn; wanghe@fmmu.edu.cn.

Background: In recent years, rectal foreign bodies have become a common proctological emergency in the male population, especially older Chinese men, often requiring surgical intervention due to associated complications. This review aimed to describe the epidemiology and clinical characteristics of rectal foreign bodies in older men and examine the possible challenges presented by the condition to clinicians and society.

Methods: A comprehensive search was conducted in English-language databases and Chinese databases from January 2000 to December 2020. Studies concerning rectal foreign bodies were considered for this review if they reported the reason for a foreign body being in the rectum and related treatment measures. Contemporaneous rectal foreign bodies case data from General Surgery Department of Tangdu Hospital were also analyzed. According to differences in ethnicity, the older male patients were divided into a Chinese group and a non-Chinese group, and the parameters of the two groups were analyzed using statistical methods.

Results: A total of 159 studies were retrieved in an initial database search using “rectal foreign body” as the search term. These included 86 Chinese studies and 73 English-language studies. Collectively, these studies included 582 older male patients, 276 of whom were Chinese, and 307 who were non-Chinese. According to their source, the rectal foreign bodies were classified into 3 categories. The most common reason for a foreign body in the rectum was insertion for erotic purposes, with everyday articles accounting for most foreign body types. Sexual articles were mainly found to have been used in the pursuit of pleasure. There were no significant differences in foreign body sources, sizes, types, treatment selections, and outcomes between the two groups.

Discussion: Emergency hospital visits by older men with rectal foreign bodies due to erotic and sexual needs and practices are increasing. Although the sources, sizes, and types of foreign bodies were different, and patients recovered well after active and appropriate clinical treatment, the sexual needs of older men are a social issue that requires attention. Acknowledging and dealing with sexual issues is a multidimensional task that requires a collaborative effort to ensure a more humanistic approach to older patients.

Keywords: Rectal foreign bodies; older men; erotic purposes; sexual behavior; treatment

Submitted Dec 13, 2021. Accepted for publication Feb 16, 2022.

doi: 10.21037/atm-22-103

View this article at: <https://dx.doi.org/10.21037/atm-22-103>

[^] ORCID: 0000-0003-1458-6834.

Introduction

Aging populations have become a social concern for countries worldwide. The global population, including that of China, a developing country with the largest population base, is experiencing a demographic shift, with the proportion of older adults (aged ≥ 60 years) growing faster than any other age group (1). Older men, in particular, have experienced changes in their societal and familial roles and often have to face changes in psychological cognition. Previous studies have often focused on empty-nesters, the widowed elderly, psychological problems, and service teams for the elderly, among other issues, while discussion about sexuality and intimacy, particularly in older adults, has been sparse (2).

Discussions about sexuality in health care have slowly increased in recent years, as has the degree of social openness and cultural tolerance. People can acquire greater knowledge about sex through the new media, which also cater to the specific sexual needs of some older men. While it is generally assumed that sexuality diminishes with age, studies suggest that sexual interest and activity last well into the eighth decade of life (3).

Older members of society who are financially secure and have met their basic survival needs do not need to worry about basic life issues and, consequently, have more time to think about other issues, such as sex. A previous study pointed out that some older men have sexual needs that are often ignored by society and that, in certain circumstances, are likely to lead to high-risk sexual behaviors (4). Some of them address their sexual needs by trying a variety of sexual behaviors. For example, some try to obtain physical and psychological pleasure by inserting foreign objects into the anus. There have also been a few reports of retained rectal foreign bodies in older patients (60–80 years old) who had attempted to self-treat fecal impaction or to give themselves a prostate massage (5,6), and some older men have been found to develop a sense of dependency after receiving prostate massage for chronic prostatitis (7). For these reasons, more and more elderly male patients are being admitted to hospitals for rectal foreign bodies that they cannot remove by themselves (8).

According to the literature, the incidence of masturbatory rectal foreign bodies has increased in recent years, and sexual gratification is now the most common cause of rectal foreign bodies (9), with 75% of the cases of rectal foreign bodies owing to a desire for erotic stimulation (8).

In light of the increasing numbers of hospital admissions for rectal foreign bodies in older men at Tangdu Hospital,

the following review was undertaken to summarize the relationship between rectal foreign bodies and the sexual needs of older male patients. We attempted to raise social awareness of this particular group of men by evaluating the differences between older Chinese and non-Chinese male patients with rectal foreign bodies and analyzing their sexual behavior and psychological characteristics.

We present the following article in accordance with the PRISMA reporting checklist (available at <https://atm.amegroups.com/article/view/10.21037/atm-22-103/rc>).

Methods

Search strategy

A comprehensive search was conducted in English-language databases (PubMed, Embase, Web of Science, the Cochrane Library) and Chinese databases (CNKI, Wanfang, VIP, the Chinese Biomedical Database) from January 2000 to December 2020. The following search terms used were: (“foreign bodies” OR “foreign matter”) AND (“rectum” OR “anus”). Clinical data from cases of rectal foreign bodies at Tangdu Hospital during the same period were also collected.

Study selection

For inclusion in this review, studies had to meet the following inclusion criteria: (I) the study was a case report or clinical study; (II) the study participants were male and over 60 years of age; (III) the study participants had complete medical records.

The exclusion criteria were as follows: (I) the study was a repeat study by the same authors; (II) the study was a meta-analysis of related articles; (III) the study included misdiagnoses of rectal foreign bodies, such as a rectal tumor being misdiagnosed as a rectal foreign body.

Data extraction and outcome indicators

The following data were extracted and recorded in a spreadsheet: (I) the first author, publication year, publication form, region, and number of cases; (II) the patient characteristics, foreign body sources, sizes, types, treatment selections, and outcomes.

Statistical analysis

The analysis was carried out using pair-wise comparison

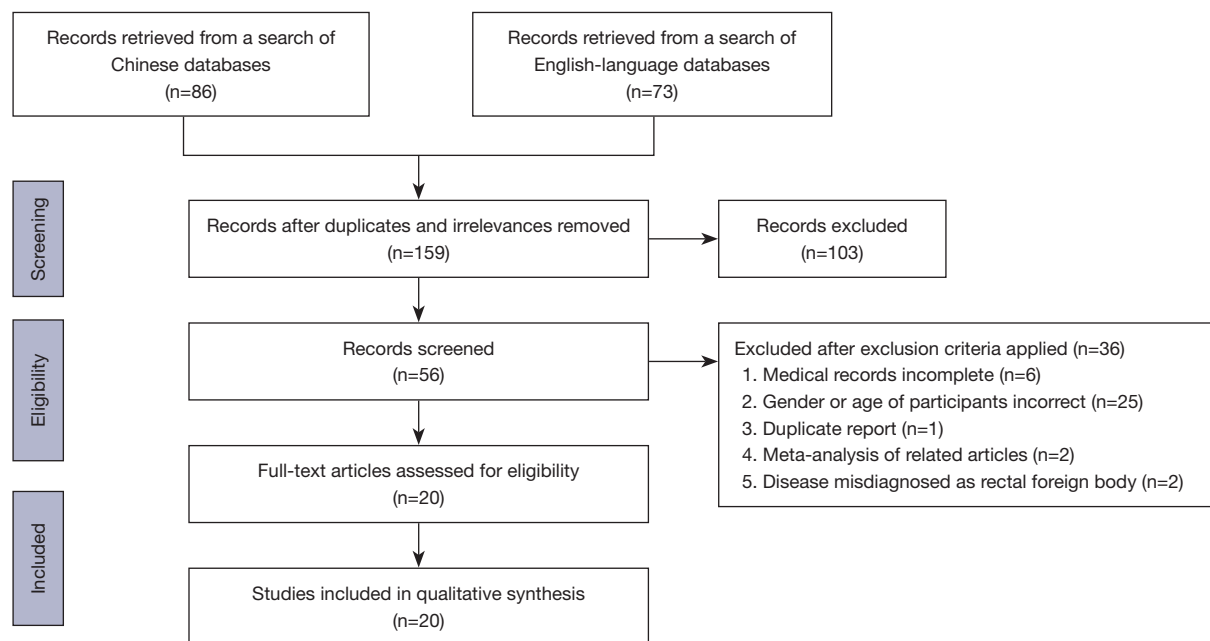


Figure 1 Flowchart of the study selection process.

between Chinese and non-Chinese arms. The general information of the patient, the characteristics of foreign body and the way of disposal were collected and presented in EXCEL. The Cochran's Q test (chi-square statistic; χ^2) was applied to evaluate the heterogeneity among studies and with a $P < 0.05$ signifying a significant difference between the Chinese group and non-Chinese group. Data statistical analysis was performed using Review Manager version 5.3 software.

Ethical statement

Written informed consent was obtained from all study participants. This study was approved by the Ethics Committee of the Tangdu Hospital of Air Force Medical University (No. K202009-03) and conducted according to the Declaration of Helsinki (as revised in 2013).

Results

Study selection and patient's characteristics

A total of 159 studies were retrieved in an initial literature search using "rectal foreign body" as the search term. These included 86 Chinese studies and 73 English-language studies. Collectively, these studies included a total of 737 patients. Of

these, 582 (79%) were male. The 737 patients were classified as Chinese ($n=276$), all of whom were males, and non-Chinese ($n=461$), of whom 307 were male, and 154 were female. The sources of foreign bodies were divided into three categories: those inserted through the anus (anal), those swallowed and then retained in the rectum (oral), and those caused by improper medical practices (medical). The first of these categories accounted for most rectal foreign bodies, while the second category was more common in children under 10 years old and older female patients. Only 1 case was iatrogenic.

The process for identifying and selecting the relevant studies according to the inclusion and exclusion criteria is shown in *Figure 1*. After screening the titles or abstracts and retrieving the full texts, 20 studies, including 15 Chinese studies (10-24) and 5 English-language studies (7,25-28), published between 2000 and 2020 met the inclusion criteria, and a total of 35 male patients were analyzed for this systematic review, including 20 Chinese patients with an age range of 70.70 ± 6.76 years, and 15 non-Chinese patients with and age range of 70.83 ± 7.14 years. The full text of all the included studies was available. The characteristics of the selected studies are shown in *Table 1*.

Types of rectal foreign bodies

The types of rectal foreign bodies were classified into the

Table 1 General characteristics of the patients, foreign bodies, extraction methods, and complications

Study	Year	Cases	Age (years)	Marital status	Cause	Medical history	Source	Foreign body	Size (cm)	Hours after insertion	Extraction method	Complications
Peng (10)	2011	1	68	NA	Erotic	Difficult	Anal	Bottle	12×6×6	36	SA/TA	No
Wang (11)	2000	3	72	Widowed	Erotic	Difficult	Anal	Light bulb	5×3	48	SA/TA	No
			68	Widowed	Erotic	Difficult	Anal	Bottle	5×2.5	72	SA/TA	No
			65	Widowed	Erotic	Difficult	Anal	Rolling pin	25×2.5	20	SA/TA	No
Xu (12)	2001	1	72	NA	Swallowed	Easy	Oral	Date pit	1	168	NOA/TA	No
Shen (13)	2006	1	68	NA	Treatment	NA	Anal	Bottle	4	4	SA/TA	No
Li (14)	2007	1	79	NA	NA	NA	Anal	Bottle	6	48	GA/LA	No
Zeng (15)	2013	1	83	NA	NA	Difficult	Anal	Bottle	NA	2	SA/TA	No
Ma (16)	2013	1	70	Married	Treatment	General	Anal	Prostate massager	NA	48	NOA/TA (CO)	No
Zhang (17)	2002	1	65	Widowed	Erotic	Difficult	Anal	Flashlight	9×3	24	NOA/TA	No
Yan (18)	2011	1	64	Married	Erotic	Difficult	Anal	Bottle	6×5	168	SA/TA	No
Deng (19)	2009	1	65	NA	NA	NA	Anal	Bottle	20×5	72	SA/TA	No
Guo (20)	2003	3	63	NA	Erotic	Difficult	Anal	Bottle caps	5×3	112	SA/TA	No
			84	NA	Erotic	Difficult	Anal	Bottle caps	5×4×3	10	SA/TA	No
			65	NA	Erotic	Difficult	Anal	Screwdriver	32×15×5	3	NOA/TA	No
Han (21)	2010	2	64	Single	Erotic	Difficult	Anal	Bottle	18×3	72	NOA/TA	No
			72	Single	Erotic	Difficult	Anal	Battery	3×1.5	48	NOA/TA	No
Guo (22)	2007	1	69	NA	Erotic	Difficult	Anal	Stick	28×3.5	72	NOA/TA (CO)	No
Li (23)	2011	1	74	NA	Swallowed	NA	Oral	Duck bone	3.5×1.8	168	SA/TA	No
Mao (24)	2020	1	72	NA	Swallowed	NA	Oral	Barb	3.5	96	SA/TA	No
Caliskan (7)	2011	10	65	NA	Erotic	NA	Anal	Bottle	8	NA	GA/LA	NA
			73	NA	Erotic	NA	Anal	Bottle	20	NA	GA/LA	NA
			79	NA	Erotic	NA	Anal	Chocolate box	3	NA	NOA/TA	NA
			60	NA	Erotic	NA	Anal	Bottle caps	8	NA	SA/TA	NA
			66	NA	Erotic	NA	Anal	Vibrators	4	NA	SA/TA	NA
			64	NA	Erotic	NA	Anal	Plastic pipe	5	NA	SA/TA	NA
			65	NA	Erotic	NA	Anal	Salt box	3	NA	GA/LA	NA
			65	NA	Erotic	NA	Anal	Toothpick box	5	NA	GA/LA	NA
79	NA	Erotic	NA	Anal	Eggplant	10	NA	Death	Death			
81	NA	Erotic	NA	Anal	Bottle	7	NA	NOA/TA	No			
Shimizu (25)	2014	1	74	NA	Swallow	NA	Oral	Barb	NA	720	GA/LA	Infection
Romera Barba (26)	2017	1	68	NA	NA	NA	Anal	Screwdriver	NA	NA	SA/TA	No
Kumar (27)	2001	1	69	Married	Treatment	NA	Medical	Toothbrush	NA	NA	NOA/TA	No
Cawich (28)	2017	2	83	NA	Medical	NA	Medical	Pen×3	NA	NA	GA/LA	No
			60	NA	Violence	NA	Anal	Bottle	NA	NA	NOA/TA	No

NA, not available; SA, with spinal anesthesia; NOA, no anesthesia; GA, general anesthesia; LA, laparotomy; TA, transanal; CO, colonoscopy.

following categories: everyday items, food, and sexual articles. The first category accounted for most rectal foreign bodies, inserted primarily in the pursuit of pleasure and partly for unexplained reasons. Sexual articles had been inserted primarily in the pursuit of pleasure. The largest rectal foreign body was a 77-cm long steel rod, and the smallest visible bodies were granuloma formations from dental and vegetable residues.

In the Chinese group of patients, there were 3 cases of rectal foreign bodies that had been swallowed, passed through the gastrointestinal tract, and held up in the rectum, including a jujube seed, a duck bone, and a fishbone. In addition, there were 17 cases of rectal foreign bodies inserted through the anus. Most of the rectal foreign bodies in this group were everyday items or sexual articles. No iatrogenic rectal foreign bodies were found. Among the non-Chinese group of patients, there was 1 case of a swallowed rectal foreign body and 14 cases of anally inserted rectal foreign bodies, most of which were household articles, including screwdrivers and various bottles. There were no significant differences in foreign body sources between the two groups ($P>0.05$) (Figure 2A). Further analysis of the sources of the rectal foreign bodies was carried out. We found that the oral rectal foreign bodies in both groups of patients were primarily sharp foodstuffs, such as fishbones, while the anally inserted rectal foreign bodies were primarily everyday items. Patients who had used sexual objects were mainly non-Chinese and those with a high degree of education.

Reason of rectal foreign bodies

The most common reason for a foreign body being in the rectum was for erotic purposes, although occasionally, there were involuntary insertions. It should be noted that a small number of drug runners were included in the cohort. Sharp foodstuffs were the most common oral rectal foreign bodies.

We found that in 60% of the Chinese cases and 66.7% of the non-Chinese cases, the foreign bodies had been inserted into the rectum for erotic stimulation and sexual gratification (Figure 2B). Analysis of the shape and texture of the rectal foreign bodies in the two groups showed that blunt foreign bodies and non-fragile foreign bodies accounted for a higher proportion of the rectal foreign bodies than their sharp or fragile counterparts (Figure 2C,2D).

Management of rectal foreign bodies

The methods used to retrieve the various rectal foreign

bodies were also analyzed, as were any associated complications. In the Chinese group of patients, transanal removal under local anesthesia was the primary retrieval method. Most rectal foreign bodies in the Chinese group of patients were successfully removed transanally with local anesthesia, with only a small proportion requiring general anesthesia and abdominal laparotomy. The differences between the Chinese and non-Chinese groups were statistically significant for anesthesia and surgery ($P=0.036$ and $P=0.028$, respectively) (Figure 2E,2F). However, although one non-Chinese patient died due to the necrosis of his intestinal mucosal tissue and a systemic infection caused by a lengthy treatment, there were no significant differences in the incidence of complications ($P=0.383$) (Figure 2G).

Clinical characteristics and management of rectal foreign body patients in Tangdu Hospital

In addition to the retrieved studies, data from 8 patients admitted to the Tangdu Hospital from 2010 to 2020, for whom complete data were available, are shown in Table 2. These 8 patients included 2 female and 6 male patients with a median age of 58 years. In 5 of the male patients, the reason for inserting a foreign body into the rectum was to stimulate erotic sensation. Of these, 2 had used vibrators (Figure 3A-3C), 1 had used the base of an electric toothbrush (Figure 3D,3E), 1 had used a ceramic drinking cup, and 1 had used a 30-cm long piece of bamboo (Figure 3F,3G). All these rectal foreign bodies were cylindrically shaped. Other objects that were encountered included a piece of date pit that was stuck to the rectum wall in the case of a 53-year-old female (Figure 3H), an intrauterine contraceptive device (IUCD) that had migrated to the rectouterine space in a 57-year-old female (Figure 3I), and a residual staple that had remained in a 34-year-old male after a hemorrhoidectomy.

In this group, the reasons for the foreign body being in the rectum were erotic purposes (5 of the male patients), migration of an intrauterine device (1 female patient), and accidental swallowing (1 female patient). All patients in the erotic-purposes group were male, and most of them were single or divorced.

In the 5 patients who had inserted foreign bodies into their rectums for erotic purposes, the diagnoses were verified by asking about their medical history, performing a rectal examination, and carrying out plain X-ray imaging. The patient who had a piece of date pit in her

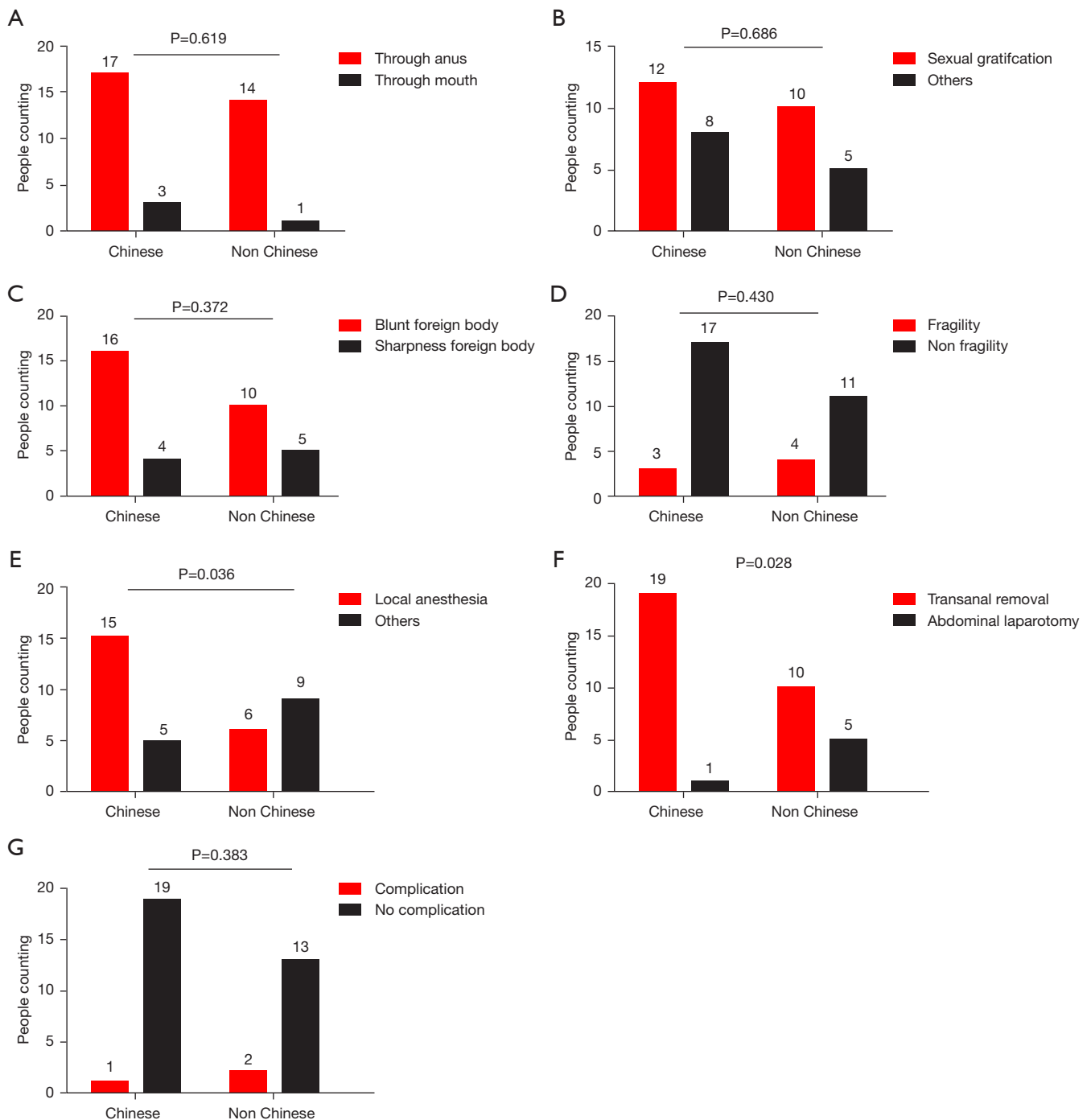


Figure 2 Comparison of the basic information between older Chinese and non-Chinese patients with rectal foreign bodies. (A) Comparison of the sources of rectal foreign bodies between the two groups; (B) comparison of the causes of rectal foreign body between the two groups; (C,D) comparison of the rectal foreign body characteristics between the two groups; (E,F) comparison of the extraction method for the foreign bodies between the two groups; (G) comparison of the postoperative complications between the two groups.

Table 2 Detailed information of rectal foreign body cases recorded at Tangdu Hospital

Case	Gender	Age (years)	Marital status	Cause	Medical history	Source	Foreign body	Size (cm)	Hours after insertion	Extraction method	Complications
1	Male	32	Married	Treatment	Easy	Medical	Staple	2×1	1 year after surgery	SA/TA (CO)	No
2	Male	64	Married	Erotic	Easy	Anal	Portable toothbrush	20×3.5	18 h	NOA/TA (CO)	No
3	Male	50	Married	Erotic	Easy	Anal	Ceramic cup	10	5 h	GA/LA	No
4	Female	53	Married	Eating	Easy	Oral	Date pit	2.5	2 years	GA/TA	No
5	Male	73	Married	Erotic	Easy	Anal	Bamboo	27×5	36 h	NOA/TA	No
6	Female	57	Married	Treatment	Easy	Medical	IUCD	3×2	20 years after surgery	GA/LA	No
7	Male	65	Married	Erotic	Easy	Anal	Vibrator	20×2	24 h	NOA/TA (CO)	No
8	Male	34	Divorced	Erotic	Easy	Anal	Vibrator	16×4	18 h	NOA/TA (CO)	No

SA, with spinal anesthesia; TA, transanal; CO, colonoscopy; NOA, no anesthesia; GA, general anesthesia; LA, laparotomy; IUCD, intrauterine contraceptive device.

rectum presented pelvic and perianal pain, exacerbated by defecation and diagnosed by a manual rectal examination. In the patient whose IUCD had migrated to her rectum, the diagnosis was confirmed by anamnesis and plain X-ray imaging. The patient with the residual staple presented with pain upon passing stools and was diagnosed during an anoscope examination.

In the clinical treatments, we successfully removed a piece of bamboo approximately 30 cm in length from the rectum of a patient who had inserted it for erotic purposes. The removal was carried out with surgical forceps while the patient applied increased abdominal pressure. In another case, the rectal foreign body used for erotic purposes could not be extracted even with a laparotomy and bimanual manipulation, and a colostomy was performed. The patient was followed up 3 months after the operation, and no complications were observed. For the other 3 patients who had inserted a foreign body for erotic purposes, a rectoscopy was performed, or the object was removed using surgical forceps under a spinal or general anesthesia in the general endoscopy room at Tangdu Hospital. Attempts to remove the rectal foreign bodies via colonoscopy were successful in the remaining 3 patients. All patients recovered without any complications after the aggressive clinical treatment.

Discussion

In the past, many studies have focused on the diagnosis, clinical diagnosis, and treatment of rectal foreign bodies (29-34), while few articles have studied the condition from the perspective of the psychological and sexual needs of older male patients. This paper reviewed studies on rectal foreign bodies and combined the analysis with cases of rectal foreign bodies at Tangdu Hospital. The case data were analyzed statistically according to the patients' general characteristics, the source, type, size, and purpose of the rectal foreign bodies, hours after insertion, treatment method, prognosis, and outcome. The patients' ethnicity (Chinese or non-Chinese) and the proportion of older male patients in the study population were also analyzed.

Based on a comprehensive analysis of the literature, we found that clinical treatment methods and prognosis differed according to the size, type, and source of foreign bodies, to their clinical manifestations, and their source. For example, oral rectal foreign bodies were primarily caused by improper eating, or overeating, resulting in the accumulation of foreign bodies in the ampullary of the rectum or by the ingestion of sharp foreign bodies which

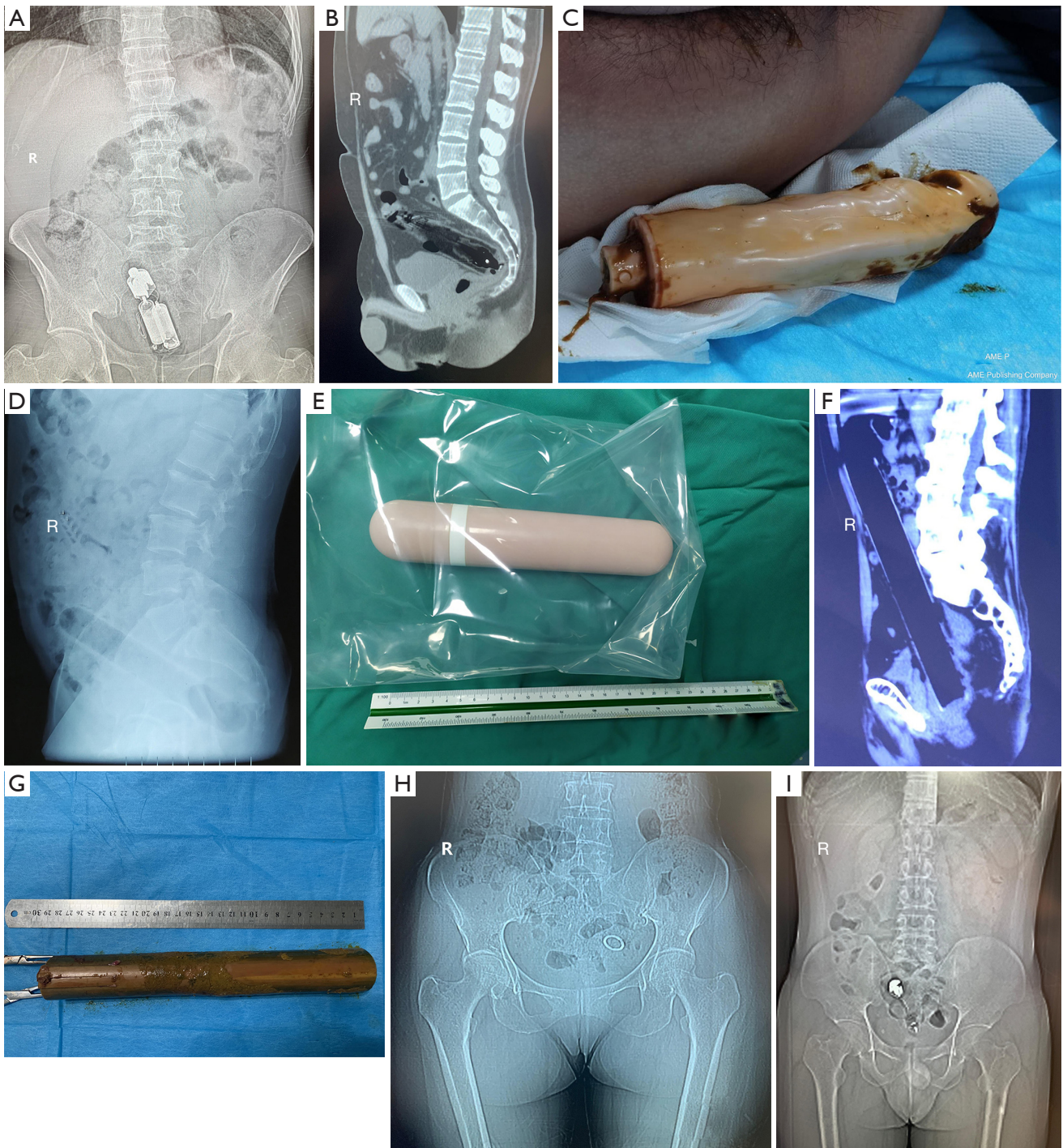

Figure 3 Rectal foreign bodies and imaging pictures. (A-C) Images of vibrators and the physical object in 2 cases; (D,E) image of an electric toothbrush and the physical object in 1 case; (F,G) image of a 30-cm long piece of bamboo and the physical object in 1 case; (H) a piece of date pit image that was stuck to the rectum wall in a 53-year-old female patient; (I) image of an IUCD that had migrated to the rectouterine space in a 57-year-old female patient. IUCD, intrauterine contraceptive device.

could not be discharged after piercing the rectum wall. The volume of this type of foreign body was generally small, and most oral foreign bodies were discharged through the anus after 4–5 days (35,36). However, in cases where the transoral rectal foreign body was ≥ 5 cm in circumference and ≥ 12 cm in length, hooked, barbed, sharp, polygonal, or small and abundant, it was not easy to discharge and often required surgical intervention (37). The most common source of rectal foreign bodies was anal insertion, primarily due to the patient's desire to relieve anorectal symptoms or masturbate. Some patients accidentally inserted an object and could not remove it, while others suffered an accidental injury, where the object was forcibly inserted through the anus. The volume of this type of foreign body was generally large, and most of the anal rectal foreign bodies caused abdominal pain, perianal pain, rectal bleeding, or intestinal obstruction (9). Many different types of objects were found in the rectum, including sex toys (such as vibrators), batteries, light bulbs, candles, glass cups, wine bottles, metal or wooden objects, fruit and vegetables (such as cucumbers), aerosol cans and their lids, illegal drugs, and unusually large objects, such as soda or beer bottles (37–39). Rectal foreign bodies often cause mucosal edema, tearing, and bleeding in the rectum and intestine wall. Patients who are not treated early often develop perforation and peritonitis, leading to septic shock.

Although the type of study and the number of patients included in this review were limited, we found that a large proportion of older male patients were sexually motivated and that this trend is increasing. We also found that the types of objects used in this way often provoked more serious clinical symptoms, creating challenges for the clinical diagnosis and treatment of these patients (40). As a result of our research, we believe that recognizing and providing for the sexual needs of older people, especially older men, is an issue that requires greater social awareness and wider attention.

This study has two levels of significance. The first is theoretical. To date, there have been few academic studies on the survival status and sexual psychoanalysis of older men from the perspective of their behavior and even fewer studies analyzing rectal foreign bodies from a sexual perspective. This review evaluated studies related to rectal foreign bodies in older men. Based on our analysis, summaries of these studies, and induction we understood the importance of acknowledging human sexual needs and learning about the sexual psychology of the elderly. We also identified research gaps, thus providing ideas for

further investigation (3). In addition, we found that types of rectal foreign object may be related, to some degree, to a person's level of education and socio-cultural environment. For example, we found that patients with sexual objects as rectal foreign bodies were usually those with a higher level of education or those who lived in an urban environment. In contrast, patients living in rural areas for a long time or those who were widowed or living alone tended to have everyday items as rectal foreign bodies.

The second level of the significance of this study is practical. Against the social backdrop of accelerated aging in China, the stereotypical image of the older generation differs from their actual needs. Older people not only need hobbies for leisure and physical maintenance, but they also need emotional comfort and social engagement. At present, there are more rural older people than urban in China. Rural areas tend to have a larger number of lonely older people with lower education levels than urban areas due to backward economic trends in rural areas. Older people in these areas do not have full access to social security and live under poorer material, spiritual, and cultural conditions than those in urban areas. Society pays less attention to the older generations, especially those in the less developed western areas of China. Finally, sexuality is a complex biopsychosocial and spiritual state of mind. Recognizing and dealing with sexual issues is a multidimensional task that should be implemented collaboratively between geriatric health services and the whole society (3).

Conclusions

In addition to their material and spiritual needs, the physiological needs, particularly the sexual psychological needs of older members of society, so often ignored by society, need greater attention from society and from the media.

Acknowledgments

The authors appreciate the contributions of the patients who participated in this study.

Funding: None.

Footnote

Reporting Checklist: The authors have completed the PRISMA reporting checklist. Available at <https://atm.amegroups.com/article/view/10.21037/atm-22-103/rc>

Data Sharing Statement: Available at <https://atm.amegroups.com/article/view/10.21037/atm-22-103/dss>

Conflicts of Interest: All authors have completed the ICMJE uniform disclosure form (available at <https://atm.amegroups.com/article/view/10.21037/atm-22-103/coif>). The authors have no conflicts of interest to declare.

Ethical Statement: The authors are accountable for all aspects of the work in ensuring that questions related to the accuracy or integrity of any part of the work are appropriately investigated and resolved. This study was approved by the Ethics Committee of the Tangdu Hospital of Air Force Medical University (No. K202009-03) and conducted according to the standards of the Declaration of Helsinki (as revised in 2013). Written informed consent was obtained from all study participants.

Open Access Statement: This is an Open Access article distributed in accordance with the Creative Commons Attribution-NonCommercial-NoDerivs 4.0 International License (CC BY-NC-ND 4.0), which permits the non-commercial replication and distribution of the article with the strict proviso that no changes or edits are made and the original work is properly cited (including links to both the formal publication through the relevant DOI and the license). See: <https://creativecommons.org/licenses/by-nc-nd/4.0/>.

References

- Partridge L, Deelen J, Slagboom PE. Facing up to the global challenges of ageing. *Nature* 2018;561:45-56.
- Katz A. The sounds of silence: sexuality information for cancer patients. *J Clin Oncol* 2005;23:238-41.
- Williams AC, Reckamp K, Freeman B, et al. Sexuality, lung cancer, and the older adult: an unlikely trio? *J Adv Pract Oncol* 2013;4:331-40.
- Dhar HL. Gender, aging, health and society. *J Assoc Physicians India* 2001;49:1012-20.
- Goldberg JE, Steele SR. Rectal foreign bodies. *Surg Clin North Am* 2010;90:173-84, Table of Contents.
- Rodríguez-Hermosa JI, Codina-Cazador A, Ruiz B, et al. Management of foreign bodies in the rectum. *Colorectal Dis* 2007;9:543-8.
- Caliskan C, Makay O, Firat O, et al. Foreign bodies in the rectum: an analysis of 30 patients. *Surg Today* 2011;41:795-800.
- Ayantunde AA. Approach to the diagnosis and management of retained rectal foreign bodies: clinical update. *Tech Coloproctol* 2013;17:13-20.
- Robertson WJ. 'Believe it or not': the medical framing of rectal foreign bodies. *Cult Health Sex* 2017;19:815-28.
- Peng Y. Experience in diagnosis and treatment of vitreous rectal foreign bodies caused by adult sexual masturbation. *Shanxi Med J* 2011;40:374-5.
- Wang S, Jian Y, Sujian N. Adult sexual masturbation causes rectal foreign body. *Zhonghua Nan Ke Xue* 2000;16:206-7.
- Xu R, Li W. Removal of foreign bodies in anal canal and rectum: report of 2 cases. *Occupation and Health* 2001;17:118.
- Shen Q. A case of rare rectal foreign body. *Chinese Journal of Modern Medicine* 2006;8:49.
- Li S, Chen E. Diagnosis and Management of Colorectal Foreign Bodies. *Medical Recapitulate* 2007;13:380-2.
- Zeng W, Li S, Cao Z, et al. One case of rectal foreign body in the elderly. *Chinese Journal of Ethnopharmacology and Ethnopharmacy* 2013;2:62-3.
- Ma S, Lu Y. Rectal foreign body caused by prostatic massage in chronic nonbacterial prostatitis: a case report. *China Medicine and Pharmacy* 2013;3:168-9.
- Zhang R. 3 cases of rectal foreign body caused by sexual masturbation. *Journal of Chinese Physician* 2002;4:1134.
- Yan I, Huang J, Xu W, et al. Experience in diagnosis and treatment of rectal foreign body incarceration caused by sexual masturbation (report of 4 cases). *Zhonghua Nan Ke Xue* 2011;17:849-51.
- Deng L, Ma D, Chen B, et al. Large foreign body in rectum in 2 cases. *Colorectal and Anal Surgery* 2009;15:427.
- Guo Y, Li Y, Zhou Y. Foreign body in rectum: report of 10 cases. *Chinese Journal of Medical Doctors* 2003;1:169-70.
- Han L. Rectal foreign body in 3 cases. *Hebei Medical Journal* 2010;32:1663.
- Guo F, Ding X. Rectal foreign body: report of 3 cases. *Ningxia Medical Journal* 2007;29:111.
- Li K. Diagnosis and treatment of rectal foreign body in 21 cases. *Chinese Medical Engineering* 2011;19:132.
- Mao L, Huang X. Experience in diagnosis and treatment of high perianal abscess caused by rectal foreign body. *Medical Diet and Health* 2020;11:103-5.
- Shimizu T, Harada K, Akazawa S, et al. Identification of the cause of severe skin infection by Fournier transform infrared spectroscopy: a case of Fournier's gangrene caused by fish bone. *J Dermatol* 2014;41:547-50.
- Romera Barba E, González-Costea Martínez R, Navarro

- García MI, et al. Foreign body of the rectum. *Cir Esp* 2017;95:169.
27. Kumar M. Don't forget your toothbrush! *Br Dent J* 2001;191:27-8.
 28. Cawich SO, Thomas DA, Mohammed F, et al. A Management Algorithm for Retained Rectal Foreign Bodies. *Am J Mens Health* 2017;11:684-92.
 29. Wu JH, Zhang HY, Xia Y, et al. A novel technique for minimally invasive removal of a foreign body in the rectal wall. *Tech Coloproctol* 2018;22:313-7.
 30. Bakheit IA, Elhasan GAB, Salih MA. A case of impacted foreign body in the rectum that was extracted using size 24 Foley catheter. *Int J Surg Case Rep* 2020;66:146-8.
 31. Bulte JP, Clermonts SHEMA, Zimmerman DDE. Antegrade impalement of the rectum by a foreign body: a case report of a successful transanal extraction using the transanal single port (TAMIS) technique. *Tech Coloproctol* 2019;23:175-8.
 32. Gajjar RA, Gupta PB. Foreign body in the rectum: A challenge for the emergency physician. *J Family Med Prim Care* 2016;5:495-7.
 33. Gentile M, Cestaro G, Di Filippo G, et al. Successful transanal removal of unusual foreign body self-inserted in the rectum A case report and review of literature. *Ann Ital Chir* 2019;90:88-92.
 34. Jung EJ, Ryu CG, Kim G, et al. Impaction of a foreign body in the rectum by improper use of a (electronic) massager: a case report. *J Korean Soc Coloproctol* 2010;26:298-301.
 35. Sajjad H, Paish LM. Rectum Foreign Body Removal. StatPearls. Treasure Island (FL); 2020.
 36. Tatar C, Karşıdağ T, Hut A. Successful endoscopic removal of a foreign body in the rectum. *Turk J Gastroenterol* 2014;25:442-3.
 37. Ye H, Huang S, Zhou Q, et al. Migration of a foreign body to the rectum: A case report and literature review. *Medicine (Baltimore)* 2018;97:e11512.
 38. Narjis Y, Rabbani K, Hakkou K, et al. Foreign body of the rectum: An unusual case. *J Emerg Trauma Shock* 2010;3:306.
 39. Rodrigues GS, Lobo DN. A foreign body in the rectum. *Indian J Surg* 2010;72:74.
 40. Vahdati SS, Shahri SA, Habibollahi P, et al. Medical image. Anal pain: think about foreign body in the rectum. *N Z Med J* 2012;125:96-9.
- (English Language Editor: L. Roberts)

Cite this article as: Yang Z, Xin P, Zhou S, Zhou C, He X, Bao G. Systematic review of rectal foreign bodies in older men: humanistic care and a novel challenge for society. *Ann Transl Med* 2022;10(4):164. doi: 10.21037/atm-22-103