



# Multimodality Treatment of Trigeminal Neuralgia: An Institutional Experience

Nemi Chand Poonia<sup>1</sup> Surendra Jain<sup>2</sup> Hardika Poonia<sup>3</sup>

<sup>1</sup>Department of Neurosurgery, Neuro Care Hospital & Research Centre Pvt. Ltd., Jaipur, Rajasthan, India

<sup>2</sup>Department of Neurosurgery, Sawai Man Singh Medical College, Jaipur, Rajasthan, India

<sup>3</sup>Jaipur National University, Jaipur, Rajasthan, India

Address for correspondence Surendra Jain, MCh Neurosurgery, Assistant Professor, Department of Neurosurgery, Sawai Man Singh Medical College, Jaipur, Rajasthan 302004, India (e-mail: simplesogani@gmail.com).

Asian J Neurosurg 2024;19:395–401.

## Abstract

**Object** Trigeminal neuralgia (TN) consists of excruciating paroxysmal pain, which lasts for seconds to minutes, in the distribution of fifth cranial nerve. TN is not life-threatening, but life became miserable because of high intensity of pain. This study aimed to assess the overall success rates of different treatments, considering pain relief, recurrence rates, and potential side effects.

**Material and Methods** A total of 203 patients of TN treated in the period of last 10 years, that is, 2013 to 2022, were included. Medial management was in 103, radiofrequency ablation in 17, neurectomy in 9, tumor excision in 6, and microvascular decompression (MVD) was done in 68 patients. Magnetic resonance imaging brain with fast imaging employing steady-state acquisition was the basic investigation to decide the etiology of disease.

**Results** Preliminary findings from our institutional experience indicate that a multidisciplinary approach, combining medical, surgical, and noninvasive treatments, yielded the most favorable results in managing TN. The majority of patients achieved significant pain reduction and improved quality of life with these selected therapies. However, certain subgroups of patients exhibited a higher propensity for treatment resistance, necessitating further investigation into personalized treatment strategies.

**Conclusion** Our study concludes that there is no definitive treatment modality (either medical or surgical) available for patients with TN. As the etiology of TN is varied, management of TN also varied, that is, multidisciplinary approach. Every type of treatment has pros and cons but when the cause of TN is vascular compression and patient's general condition permits for surgery, in such cases MVD should be preferred over the ablative procedures.

## Keywords

- ▶ treatment options
- ▶ trigeminal neuralgia
- ▶ microvascular decompression

article published online  
June 18, 2024

DOI <https://doi.org/10.1055/s-0044-1787087>.  
ISSN 2248-9614.

© 2024. Asian Congress of Neurological Surgeons. All rights reserved.

This is an open access article published by Thieme under the terms of the Creative Commons Attribution-NonDerivative-NonCommercial-License, permitting copying and reproduction so long as the original work is given appropriate credit. Contents may not be used for commercial purposes, or adapted, remixed, transformed or built upon. (<https://creativecommons.org/licenses/by-nc-nd/4.0/>)

Thieme Medical and Scientific Publishers Pvt. Ltd., A-12, 2nd Floor, Sector 2, Noida-201301 UP, India

## Introduction

The symptoms of trigeminal neuralgia (TN) include recurrent, unilateral, short, electric shock-like pains that are produced by various stimuli, localized to the distribution of one or more trigeminal nerve divisions, abrupt in onset and termination, and lasting from seconds to minutes, as per the third edition of the International Classification of Headache Disorders.<sup>1</sup> The discomfort is triggered by trivial stimuli like eating, talking, cleaning face, and brushing teeth.

The total annual incidence of TN varies from 12.6/100,000 to 27/100,000 individuals, and the incidence rises with age.<sup>2</sup>

The mechanism of TN is defined as mechanical compression (vascular or tumorous) or inflammatory demyelination (multiple sclerosis) that causes hyperexcitability of trigeminal root fibers around the entry zone into the pons. Nearly 95% of TN patients have vascular compression of the trigeminal nerve root, which is more prevalent.<sup>3</sup>

There are two types of TN: classical (essential or idiopathic) TN (CTN) and symptomatic (atypical) TN (STN). STN is due to structural lesion other than vascular compression, while diagnosis of CTN requires the absence of a clinically evident neurological deficit.

CTN	STN
Attacks are paroxysmal and associated with triggered mechanical stimuli. Diagnosis is confirmed by magnetic resonance imaging (MRI) (mostly neurovascular compression)	Triggered by extraneous stimuli and associated with cerebellopontine angle lesion and multiple sclerosis. MRI does not show any neurovascular compression

## Pathogenesis

Although the precise cause of TN is uncertain, the breakdown of myelin surrounding the trigeminal nerve is the main contributing factor. This might happen as a result of compression from a blood vessel at the root entry zone, which is close to the foramen ovale. Usually, it is the superior cerebellar artery. The superior cerebellar artery can press on or groove the nerve root, resulting in focal demyelination and hyperexcitability of nerve fibers. These conditions cause the nerve fibers to activate in response to gentle contact, producing brief but acute pain episodes. Multiple sclerosis, stroke, trauma, tumors, and arteriovenous malformations are among the other causes.

## Hypotheses

### Ignition Theory:

In 80 to 90% of cases, compression of the trigeminal nerve pathway results in pain. This is found inside the nervous system. It implies that anomalies in the afferent neurons of the trigeminal root or ganglion are the cause of TN.

## The Bioresonance Hypothesis:

This novel theory suggests that the trigeminal nerve will resonate if a structure next to it experiences vibrations at a frequency that approaches its inherent frequency. This may result in pain and irregular transmission.<sup>4</sup>

## Material and Method

This is a retrospective, single-center study involving 203 patients who underwent management for TN at the Neuro Care Hospital, Jaipur, Rajasthan, India between 2013 and 2022. The diagnosis of TN was essentially clinical and visual analog scale (VAS) was used for pain assessment. MRI brain and its sequences (constructive interference in steady-state sequence) help to detect changes in trigeminal root and any neurovascular conflict, and to rule out secondary pathology.

The following treatment modalities were used for TN: medical management, radiofrequency ablation (RFA), neurectomy, tumor decompression, and microvascular decompression (MVD). The patient's history and VAS were used to determine the outcome at the time of discharge, which was at 1 and 5 years.

## Results

### Demographic

A total of 203 patients were enrolled in our study, 84 of whom were men and 119 of them were women. The male patient who was the youngest was 37 years old, while the oldest was 76 years old. With a mean age of 55.7 years, the majority of individuals present symptoms in their sixth and seventh decades.

There were 84 (41.37%) male patients and 119 (58.63%) female patients, indicating a higher incidence rate among female patients (F:M: 1.4:1; ►Table 1).

### Dermatomal Involvement

Pain is restricted to the fifth cranial nerve's branches (►Fig. 1). The most often affected branches individually are V2 ( $n=42$ ), followed by V3 ( $n=16$ ) and V1 ( $n=6$ ). V1V2 dermatomes are more commonly affected overall. Farooq et al's<sup>5</sup> study of 72 patients with idiopathic TN found that V3 was implicated in 62.5% of the patients, either by

**Table 1** Demographic Details

	Male	Female	Total
Patients enrolled	84	119	203
Age of presentation (y)			
30–39 y	12	16	28
40–49 y	20	24	44
50–59 y	26	34	60
More than 60 y	26	45	71

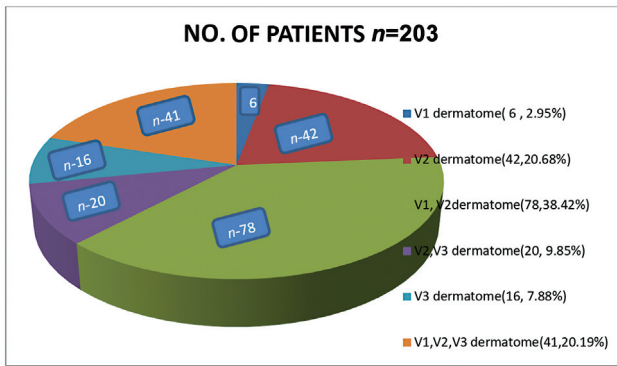


Fig. 1 Frequency of dermatomal involvement.

itself or in conjunction with V2. According to Shankland,<sup>6</sup> one-third of the patients in their study had both V2 and V3 affected.

**Site Involvement**

Ninety-seven patients (47.94%) reported pain on the left side of their faces, whereas 126 patients (62.06%) reported discomfort on the right. This implied that discomfort was more

prevalent on the right side. The ratio of the right to left side is 1.3:1.

According to the Loh et al study,<sup>7</sup> the peak age at which TN begins is after the fourth decade of life, with a minor preference for females that ranges from 2:1 to 3:2. The right side of the face is typically affected by the illness. In our study, we found nearly identical results with a variation in the peak age of onset, which was more common in the sixth and seventh decades.

**Length of Symptoms**

The pretreatment phase of symptoms lasts anywhere from 3 to 10 months. In other words, people were not receiving any kind of treatment, even medical treatment.

**Treatment Modalities**

We employed medical management, RFA, neurectomy, tumor decompression, and MVD among the various treatment modalities available. Prior to beginning treatment, every patient underwent evaluations that included a thorough medical history, a neurological and general examination, and a pain assessment using the VAS. All patients were initially treated with either 600 to 1,200 mg of

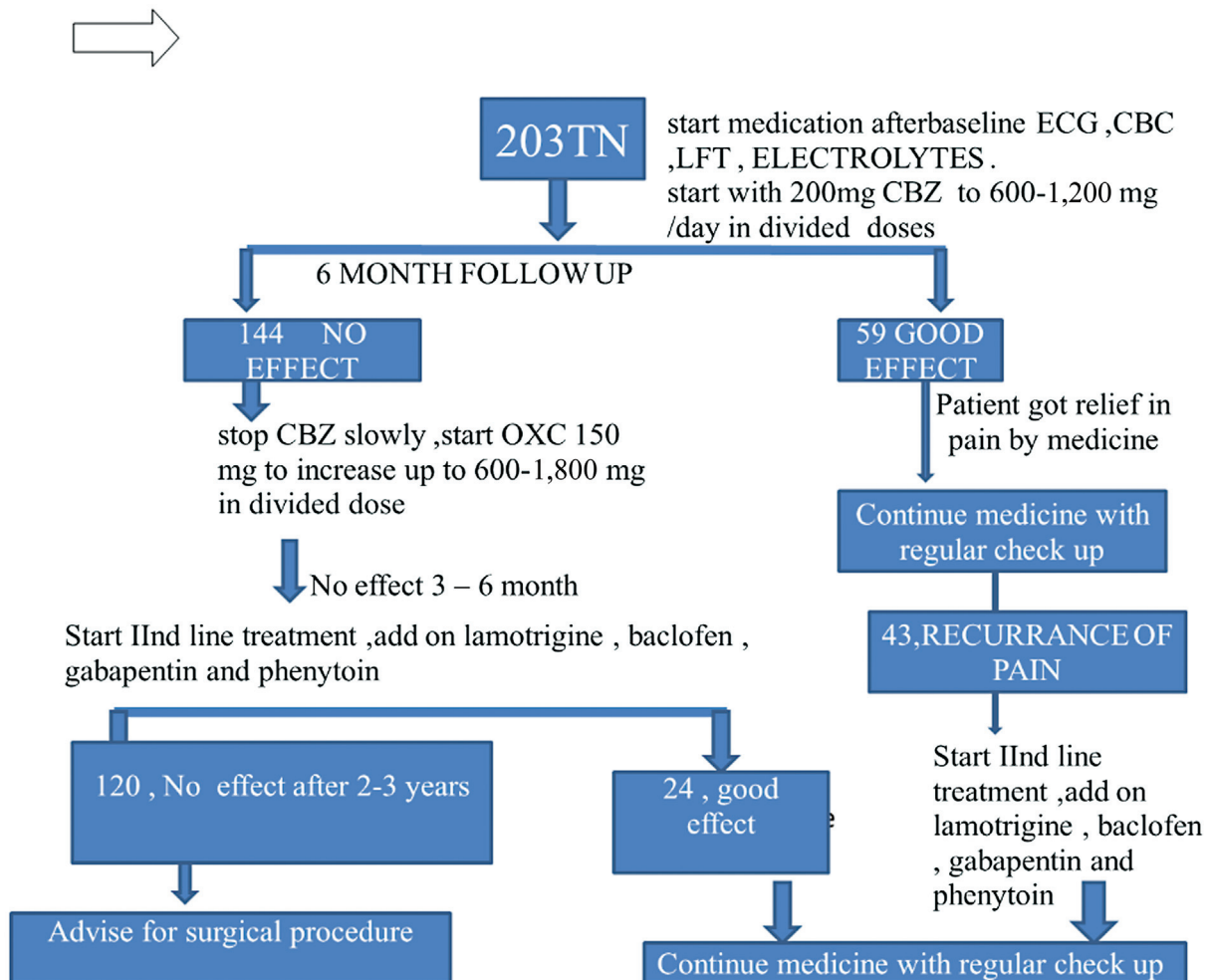


Fig. 2 Algorithm of study.

carbamazepine (CBZ) or 600 to 1,800 mg of oxcarbazepine. For an average of 1 to 3 years, it was used either constantly or intermittently, sometimes alone and other times in combination with others medications to treat the condition.

Flowchart of our study is given in ►Figs. 2 and 3.

### Medical Management

For most TN patients, medical management was the initial course of treatment, which was continued until side effects appeared or the patient's pain was no longer effectively controlled after 2 to 3 years. Oxcarbazepine (600–1,800 mg/day) and CBZ (200–1,200 mg/day) were the first-line treatments. The safety profile of oxcarbazepine is superior.<sup>8</sup>

Add a second line of medication, such as lamotrigine, baclofen, gabapentin, phenytoin, etc., if patients are not getting better. Lamotrigine stabilizes neuronal membranes, blocks the release of excitatory neurotransmitters, and works at voltage-sensitive sodium channels. In a randomized controlled trial including 14 patients with TN who were not responding to CBZ, it was found to be more effective than a placebo.<sup>9</sup> The initial dose of 25 mg/day is slowly increased to a target dose of 200 to 400 mg/day divided between two doses.

Baclofen is an agonist at the beta subunit of the GABA receptor and depresses excitatory neurotransmission and effective at doses of 10 to 60 mg/day.

Starting at 300 mg per day, gabapentin can be raised by 300 mg every 2 to 3 days if tolerated. The relatively mild adverse effects of gabapentin, which can include headache, nausea, dizziness, somnolence, and disorientation, are not associated with any medication interactions. Gabapentin is an anticonvulsant, which was designed to mimic the neurotransmitter GABA.<sup>10,11</sup>

Additionally used as an adjunctive treatment, phenytoin reduces the rate of repeated firing by blocking voltage-dependent membrane sodium channels that are responsible for amplifying action potentials. But significant side effects of ataxia, dysarthria, nystagmus, and a significant incidence of recurrence of the neuralgia despite its continuance, the authors did not use it commonly.

### Result

As seen in ►Figs. 2 and 3, all patients were first given monotherapy, or only one prescription regimen. Nevertheless, several individuals had pain flare-ups after 6 to 12 months. Then, these patients were switched to a

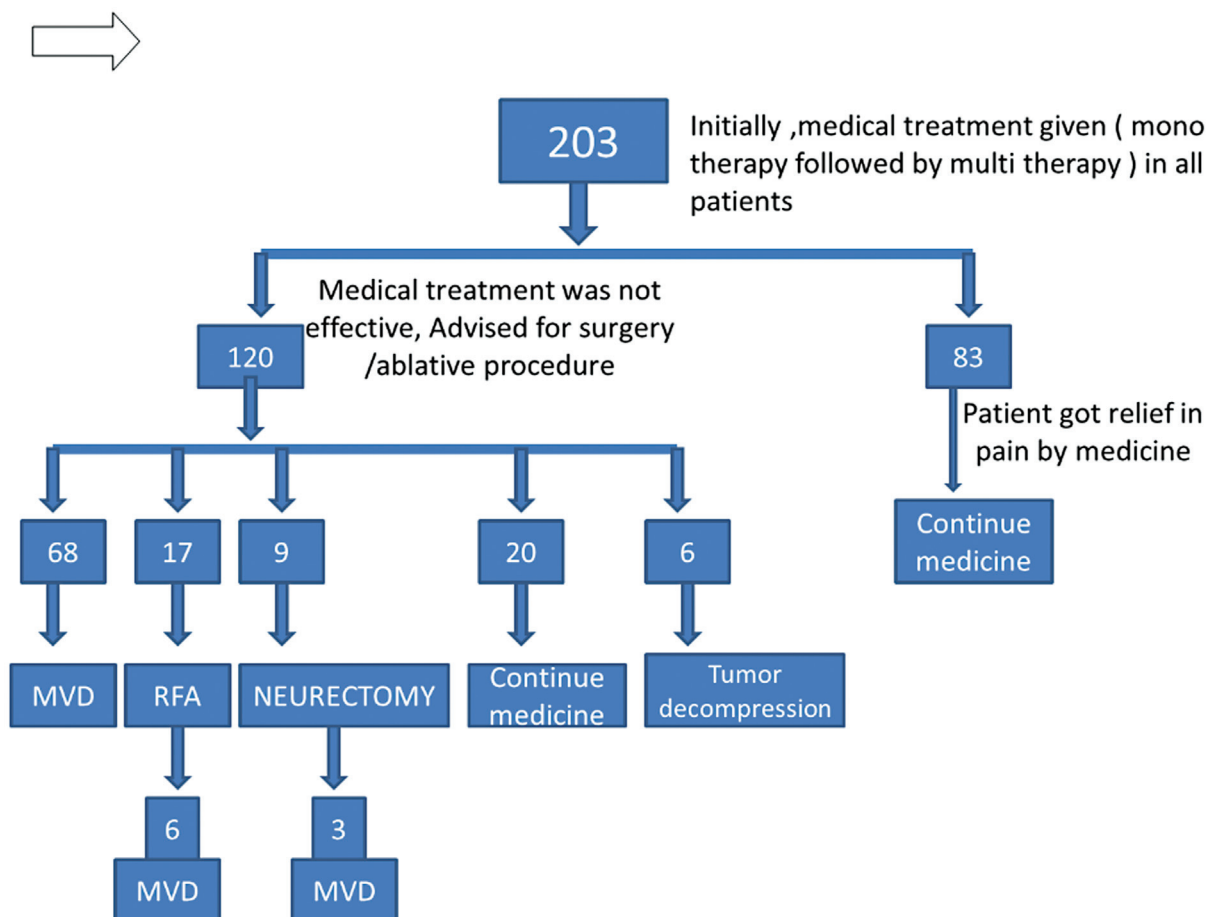


Fig. 3 Algorithm of study.

**Table 2** Comparison with other study

Study	Immediate pain relief	Improved pain symptoms	Recurrent at 1 year	Recurrent at 2 year
Wu et al <sup>12</sup>	79%	18%	11%	25%
Kanpolat et al <sup>13</sup>	97.6 %	Not mentioned	7.7 %	17.4 %
Our study	64.70%	35.30%	23.52%	35%

multidrug regimen known as polytherapy. After a 3- to 5-year follow-up, 83 patients reported being able to manage their pain with medicine and sticking to their recommended course of action. Nevertheless, some patients chose surgery despite their medication-induced pain alleviation because of adverse effects.

After starting monotherapy medication, all patients' pain was initially alleviated; but, over time, discomfort recurred. Patients' regimens were changed from monotherapy to polytherapy as a result. A polytherapy program yields superior results in terms of pain relief (► **Table 3**).

**Table 3** Summary of different modalities

	RFA	Neurectomy	Only medicine	MVD	TN associated with tumor
Total number of patients	17	9	103 (83 + 20)	68	6
Age group					
30–39 y	0	0	13	14	1
40–49 y	4	1	13	24	2
50–59 y	5	3	34	18	0
More than 60 y	8	5	43	12	3
Sex					
Male	6	3	39	32	4
Female	11	6	64	36	2
Side of the face involved					
Right	9	5	68	40	4
Left	8	4	55	28	2
Divisions of the trigeminal nerve involved					
V1 only	0	0	2	4	0
V2 only	8	6	10	16	2
V3 only	0	0	10	6	0
V1V2 only	3	3	53	16	0
V2V3 only	0	0	8	12	0
V1V2V3	6	0	17	14	4
Duration of symptoms pretreatment	2–3 y	2–3 y	3–10 mo	4–10 y	2–3 y
Outcome	Immediate pain relief 64.70% - Improved pain symptoms 30.35% - Recurrent at 1 year 23.52% - Recurrent at 2 years 35%	Pain relief 77–88%	40.88% of patient got relief by polytherapy	Success rate of 93% at 1 year and 91% at 3 to 5 years	No recurrence

Abbreviations: MVD, microvascular decompression; RFA, radiofrequency ablation; TN, trigeminal neuralgia.

### Radiofrequency Ablation

In our study, 17 patients with CTN were treated by RFA. It can relieve pain by destroying the part of the nerve that causes pain and suppressing the pain signal to the brain:

- indication—older than 70 years
- medical treatment failed
- refuse for surgery

### Method

A 22-G, 10-cm length, and 5-mm exposed tip needle placement is done and is verified with fluoroscopy. The needle obturator is removed, and the electrode is introduced. Sensory stimulation is typically achieved at 0.1 to 0.5 V (50 Hz) and motor stimulation achieved at 0.1 to 0.5 V (2 Hz). Lesions are made at 60°C to 80°C for 60 seconds. Electrode and cannula are then removed.

### Result

Eleven patients (64.70%) who had immediate good pain relief and six patients (35.30%) who experienced improved pain symptoms had RFA employed in our study. Four patients (23.52%) experienced pain recurrence within a year, while two more patients (11.76%) experienced pain recurrence after 3 years. Note that 64.70% of the patients are still pain free. These six patients were treated by MVD (►Table 2).

The most common side effects are sensory loss (35%) followed by dysesthesias (12%) and anesthesia dolorosa (6%).

### Peripheral Neurectomy

Nine TN patients were treated with peripheral neurectomy in our study. Patients in the study included those who have become intolerant to medication side effects, or resistant to medical treatment, or are too old or comorbid to have surgery.

For infraorbital neurectomy, the standard intraoral technique is employed. A U-shaped Caldwell-Luc incision is made in the vestibule above the buccal area. All of the peripheral branches are grasped and avulsed intraorally from the skin's surface after the nerve is exposed. A cut made in the upper forehead allowed access to the supraorbital nerve while under local anesthetic.

### Result

In our study, pain reduction following neurectomies ranged from 77 to over 88%, which is similar to others studies (►Table 3). Initial rates of pain relief for peripheral neurectomies range from 70 to over 90%.<sup>14-18</sup> Three patients out of 9 experienced pain recurrence over 12 to 24 months. Recurrent pain was treated with MVD.

### Trigeminal Neuralgia Associated with Tumor

It is uncommon for TN to appear as a symptom of intracranial tumors. A tumor squeezing the nerve itself, an inflammatory reaction to the epidermoid tumor, or vascular compression of the nerve can all result in trigeminal pain. Six participants in our research had TN linked to a tumor (five epidermoid and one meningioma).

Following complete tumor removal, TN fully resolved. Two of the individuals experienced transient facial paralysis. After the tumor was surgically removed, the patients experienced 4 to 6 months of pain relief and they did not require medication to stay pain free.

### Microvascular Decompression

MVD is a surgical procedure that involves a suboccipital craniectomy and decompression of trigeminal nerve by identification of causative factor and separation of nerve from offending artery by using Teflon or gelfoam pledget. In cases where a vein is causing trigeminal compression, bipolar cautery is used to divide the vein.

MVD is only prescribed to those with severe pain who have not responded to at least three appropriate medication trials, including CBZ at a high enough dosage for at least 2 to 3 years and other unsuccessful ablative techniques.

MVD was used to treat 68 patients in our study

Outcome—outcomes following MVD are favorable in our study, more than (72 patients) 93% patients were pain free within 1 year of surgery (►Table 3).

Complication—two patients had cerebrospinal fluid otorrhea who were reoperated and mastoid air cells obliterated by muscles and fascia graft. Postoperatively, they also did well.

Three to 5 years after surgery, 91% (70 patients) of the patients were pain free and did not require any medication for pain control. An additional 5% had occasional pain but did not require to continue medication. Recurrence of pain occurred in the rest ( $n=3$ ) 4% patients and they are on medication.

Various studies suggest that MVD for pain relief has a high success rate, over 90% of patients were pain free at initial stage.<sup>19-23</sup> However, more recent estimate indicates a lower rate of success in the long term, that is, 80% were pain free at 1 year, 75% at 3 years, and 73% at 5 years.<sup>20,21,24-27</sup> Our study aligns with the results, which found success rate of 93% at 1 year and 91% at 3 to 5 years.

### Conclusion

Based on our study, it is not possible to determine a single, universally successful medical or surgical therapy option for patients with TN. Every treatment plan has advantages and disadvantages. The various treatment options include surgery, peripheral blocks, and conventional medical treatments.

Medical therapy continues to be the first-line treatment for TN because of its lengthy history of usage and manageable side effects. Patients may benefit from extended durations of pain relief with polytherapy, which is noticeably more successful than monotherapy in this regard. Patients have a variety of surgical choices when medical therapy fails.

Patients who are unable to tolerate general anesthesia or have other comorbidity conditions may benefit from percutaneous RFA, neurectomy, and other ablative procedure. These ablative procedures provide short- to medium-term pain relief.



When the cause of TN is vascular compression and patient's general condition permits for surgery, in such cases MVD should be preferred over the ablative procedures.

#### Conflict of Interest

None declared.

#### References

- Headache Classification Committee of the International Headache Society (IHS) The International Classification of Headache Disorders, 3rd edition (beta version). *Cephalalgia* 2013;33(09): 629–808
- Montano N, Conforti G, Di Bonaventura R, Meglio M, Fernandez E, Papacci F. Advances in diagnosis and treatment of trigeminal neuralgia. *Ther Clin Risk Manag* 2015;11(11):289–299
- Zakrzewska JM, Linskey ME. Trigeminal neuralgia. *BMJ* 2014;348(348):g474
- Jia DZ, Li G. Bioresonance hypothesis: a new mechanism on the pathogenesis of trigeminal neuralgia. *Med Hypotheses* 2010;74(03):505–507
- Farooq S, Shah A, Hamid R. Idiopathic trigeminal neuralgia: A study of 72 cases. *Int J Appl Dent Sci* 2018;4:282–285
- Shankland WE II. Trigeminal neuralgia: typical or atypical? *Cranio* 1993;11(02):108–112
- Loh HS, Ling SY, Shanmugasantharam P, Zain R, Yeo JF, Khoo SP. Trigeminal neuralgia. A retrospective survey of a sample of patients in Singapore and Malaysia. *Aust Dent J* 1998;43(03):188–191
- Beydoun A. Safety and efficacy of oxcarbazepine: results of randomized, double-blind trials. *Pharmacotherapy* 2000;20(8 Pt 2):152S–158S
- Zakrzewska JM, Chaudhry Z, Nurmikko TJ, Patton DW, Mullens LE. Lamotrigine (lamictal) in refractory trigeminal neuralgia: results from a double-blind placebo controlled crossover trial. *Pain* 1997;73(02):223–230
- Zhang M, Gao CX, Ma KT, et al. A meta-analysis of therapeutic efficacy and safety of gabapentin in the treatment of postherpetic neuralgia from randomized controlled trials. *BioMed Res Int* 2018;2018:7474207
- Ta PCP, Dinh HQ, Nguyen K, Lin S, Ong YL, Ariyawardana A. Efficacy of gabapentin in the treatment of trigeminal neuralgia: a systematic review of randomized controlled trials. *J Investig Clin Dent* 2019;10(04):e12448
- Wu CY, Meng FG, Xu SJ, Liu YG, Wang HW. Selective percutaneous radiofrequency thermocoagulation in the treatment of trigeminal neuralgia: report on 1860 cases. *Chin Med J (Engl)* 2004;117(03): 467–470
- Kanpolat Y, Savas A, Bekar A, Berk C. Percutaneous controlled radiofrequency trigeminal rhizotomy for the treatment of idiopathic trigeminal neuralgia: 25-year experience with 1,600 patients. *Neurosurgery* 2001;48(03):524–532
- Agrawal SM, Kambalimath DH. Peripheral neurectomy: a minimally invasive treatment for trigeminal neuralgia. A retrospective study. *J Maxillofac Oral Surg* 2011;10(03):195–198
- Ali FM, Prasant M, Pai D, Aher VA, Kar S, Safiya T. Peripheral neurectomies: a treatment option for trigeminal neuralgia in rural practice. *J Neurosci Rural Pract* 2012;3(02):152–157
- Yuvaraj V, Krishnan B, Therese BA, Balaji TS. Efficacy of neurectomy of peripheral branches of the trigeminal nerve in trigeminal neuralgia: a critical review of the literature. *J Maxillofac Oral Surg* 2019;18(01):15–22
- Zhu S, Rong Q, Chen S, Li X. Pterygopalatine fossa segment neurectomy of maxillary nerve through maxillary sinus route in treating trigeminal neuralgia. *J Craniomaxillofac Surg* 2013;41(07):652–656
- Murali R, Rovit RL. Are peripheral neurectomies of value in the treatment of trigeminal neuralgia? An analysis of new cases and cases involving previous radiofrequency Gasserian thermocoagulation. *J Neurosurg* 1996;85(03):435–437
- Resnick DK, Levy EI, Jannetta PJ. Microvascular decompression for pediatric onset trigeminal neuralgia. *Neurosurgery* 1998;43(04): 804–807, discussion 807–808
- Sanchez-Mejia RO, Limbo M, Cheng JS, Camara J, Ward MM, Barbaro NM. Recurrent or refractory trigeminal neuralgia after microvascular decompression, radiofrequency ablation, or radiosurgery. *Neurosurg Focus* 2005;18(05):e12
- Sharma R, Phalak M, Katiyar V, Borkar S, Kale SS, Mahapatra AK. Microvascular decompression versus stereotactic radiosurgery as primary treatment modality for trigeminal neuralgia: a systematic review and meta-analysis of prospective comparative trials. *Neurol India* 2018;66(03):688–694
- Liu J, Chen Z, Feng T, Jiang B, Yuan Y, Yu Y. Biomedical glue sling technique in microvascular decompression for trigeminal neuralgia caused by atherosclerotic vertebrobasilar artery: a description of operative technique and clinical outcomes. *World Neurosurg* 2019;128:e74–e80
- Barker FG II, Jannetta PJ, Bissonette DJ, Larkins MV, Jho HD. The long-term outcome of microvascular decompression for trigeminal neuralgia. *N Engl J Med* 1996;334(17):1077–1083
- Sekula RF Jr, Frederickson AM, Jannetta PJ, Quigley MR, Aziz KM, Arnone GD. Microvascular decompression for elderly patients with trigeminal neuralgia: a prospective study and systematic review with meta-analysis. *J Neurosurg* 2011;114(01):172–179
- Tomasello F, Esposito F, Abbritti RV, et al. Microvascular decompression for trigeminal neuralgia: technical refinement for complication avoidance. *World Neurosurg* 2016;94:26–31
- Zakrzewska JM, Lopez BC, Kim SE, Coakham HB. Patient reports of satisfaction after microvascular decompression and partial sensory rhizotomy for trigeminal neuralgia. *Neurosurgery* 2005;56(06):1304–1311, discussion 1311–1312
- Obermann M. Treatment options in trigeminal neuralgia. *Ther Adv Neurol Disord* 2010;3(02):107–115