

Lip reposition surgery: A new call in periodontics

TEJAL SHETH, SHILPI SHAH, MIHIR SHAH, EKTA SHAH

Abstract

“Gummy smile” is a major concern for a large number of patients visiting the dentist. Esthetics has now become an integral part of periodontal treatment plan. This article presents a case of a gummy smile in which esthetic correction was achieved through periodontal plastic surgical procedure wherein a 10-12 mm of partial-thickness flap was dissected apical to mucogingival junction followed by approximation of the flaps. This novel technique gave excellent post-operative results with enormous patient satisfaction. This surgical chair-side procedure being one of its kinds with outstanding results is very rarely performed by Periodontists. Thus, a lot of clinical work and literature review with this surgical technique is required. To make it a routine surgical procedure this technique can be incorporated as a part of periodontal plastic surgery in the text. Hence, we have put forward experience of a case with critical analysis of the surgical technique including the limitations of the technique.

Keywords: Gummy smile, lip repositioning, periodontal plastic surgery

Introduction

Excessive gingival display is one of the major causes of patient embarrassment. An imbalance in the gingiva-tooth ratio results in dominance of gingival appearance often referred to as “gummy smile.” To improve the smile, the balance and harmony between all the three components of smile: Lips, teeth and gingivae are integral. A normal gingival display between the inferior border of the upper lip and the gingival margin of the central incisors during a normal smile is 1-2 mm. In contrast, an excessive gingivae-to-lip distance of 4 mm or more is classified as unattractive.^[1] The lip line, assessed when the patient is in full smile, can be classified as: Classification of the “smile line” upper lip-interdental and marginal gingiva [Table 1].^[2]

The possible etiologies for excessive gingival display would be delayed eruption where the gingiva fails to migrate apically and attain its position 1 mm coronal to cemento-enamel junction, vertical maxillary excess in which there is an enlarged vertical dimension of the midface and incompetent

Table 1: Classification of smile line

Class	Type: Description	Evaluation
Score 0	“Low smile line”	IDG: <25% visible M: Not visible, teeth masked
Score 1	“Average/ideal smile line”	IDG: 25-75% visible M: Visible on individual teeth
Score 2	“High smile line”	IDG: >75% visible M: <3 mm visible (overall)
Score 3	“Very high smile line”	IDG: Completely visible M: >3 mm wide maxillary band of gingiva visible beyond the mucogingival line “gummy smile”

IDG: Interdental gingiva; M: Gingival margin

lips, compensatory eruption of the maxillary teeth with concomitant coronal migration of the attachment apparatus that includes gingival margins.^[3,4]

Another possible etiology can be movement of the upper lip in apical direction when the patient smiles exposing the dentition and excessive gingivae. In this condition, surgical lip repositioning treatment can be performed to reduce the labial retraction of the elevator smile muscles and minimize excessive gingival display. The procedure was first described in the literature of plastic surgery in 1973 by Rubinstein AM. There is still paucity of work and literature regarding lip reposition surgeries with only cases being published by Rosenblatt and Simon (2006)^[5] and Gupta *et al.* (2010).^[6] This technique can also be used as an additional treatment modality in patients with lip hypermobility.

The objective of lip repositioning surgery is surgical correction of unesthetic gummy smile by limiting the retraction of the elevator smile muscles (zygomaticus minor, levator anguli, orbicularis oris and levator labii superioris) resulting in a narrow vestibule and restricted muscle pull thereby reducing

Department of Periodontics and Oral Implantology, Ahmedabad Dental College and Hospital, Gandhinagar, Gujarat, India

Correspondence: Dr. Tejal Sheth, 402, Ratnakar Flat, Opp. Amrapali III, Judges Bungalow Road, Bodakdev Ahmedabad - 380 015, Gujarat, India.
E-mail: tejal.sheth123@gmail.com

Access this article online	
Quick Response Code:	Website: www.contempclindent.org
	DOI: 10.4103/0976-237X.118353

gingival display during smiling.^[5] This article presents a case report of showing the surgical outcome through this periodontal plastic procedure.

Case Report

A 35-year-old female patient reported to the outpatient department of Periodontics and Oral Implantology, Ahmedabad Dental College and Hospital with the chief complaint of excessive gingival display. The patient was apparently asymptomatic except the embarrassment of going in public due to gummy smile. On examination, she had an excessive gingival display of around 8-10 mm extending from maxillary right first molar (16) to maxillary left first molar (26). Furthermore, marginal gingival discrepancy was reported in relation to maxillary right central incisor (11) and maxillary left central incisor (21) along with short clinical crowns. The patient's medical history was non-contributory and there was no contraindication to surgical treatment.

The treatment suggested and performed were:

- Surgical crown lengthening^[3] in relation to maxillary right lateral incisor (12) to maxillary left lateral incisor (22)
- Surgical lip repositioning procedure for correction of a gummy smile.

Surgical procedure for lip repositioning

Surgical technique was performed after following complete aseptic precautions. Standard skin preparation was carried out by 10% povidone-iodine solution and temporary draping was done. Local infiltration was done using local anesthetic solution Lignox® (2% Lignocaine with 1:200,000 Adrenaline) in the vestibular mucosa and lip extending from right first molar to left first molar.

The surgical area was outlined using an indelible pencil. The procedure was initiated with a 15 no Bard-Parker blade by giving a partial-thickness incision following the mucogingival junction extending from right first premolar (14) to left first premolar (24). Followed by the first incision, another second horizontal incision parallel to first was made in the labial mucosa 10-12 mm apical to mucogingival junction. These two incisions were connected at each end by creating an elliptical pattern [Figure 1]. The partial-thickness flap was excised leaving the underlying connective tissue exposed to the oral cavity [Figures 2]. It is noteworthy that the amount of partial-thickness flap excised should be either double the amount of gingival display that needs to be reduced or a maximum of 10-12 mm tissue excision in order to prevent the involvement of labial minor salivary glands severing of which may lead to the formation of mucocoele.

Complete hemostasis should be attained by pressure pack. Henceforth, parallel incised margins were approximated with an interrupted stabilization suture using Vicryl® 5-0 at the midline to ensure proper alignment of the midline of the lip

with that of the teeth [Figure 3]. Multiple interrupted sutures at a distance of 1 mm were taken on either side of the midline suture to approximate the flap margins.

Non-steroidal anti-inflammatory drugs (Tablet Ibuprofen 400 mg 4 times a day for 3 days) along with oral antibiotics (Capsule Amoxicillin 500 mg 3 times a day for 7 days) were prescribed post-operatively. Patient was instructed to use ice packs immediate post-operatively for few hours with intermittent application on the upper lip and to minimize lip movement while smiling and talking. Patient was recalled for follow-up after a week.

Post-operative symptoms included mild pain and swelling with feeling of tension on the upper lip while smiling. Sutures were removed after 2 weeks. The site healed uneventfully with scar formation at the suture line, which was concealed under the lip and was not apparent when the patient smiled.

This esthetic procedure is safe and has minimal side-effects. The patient was recalled after every 3 months for follow-up. The patient was highly pleased and satisfied with the esthetic outcome [Figures 4-6].

Discussion

The addition of "optimal esthetics" to the goal of periodontal therapy parallels a paradigm shift in all of dentistry. The search for beauty can be traced to the earliest civilizations. Dental art has long been a part of the quest to enhance the esthetics of the teeth and mouth. What constitutes a pleasing dentogingival appearance depends on the extent of gingival exposure. When a person smiles, the entire crown of the maxillary central incisors and 1 mm of pink attached gingiva will be evident. Greater amount of exposed gingiva (2-3 mm) can be cosmetically acceptable as long as the gingiva is not unduly conspicuous such as "Gummy smile" appearance, where more than 3 mm of gingiva is displayed during a relaxed smile. This correction of esthetics should be done under the boundaries of "cosmetic zone." In an esthetic evaluation of dentogingival complex, the midline of the face, the position of the incisal edges and the gingival line are important landmarks.

In most patients, the lower edge of the upper lip assumes a "gumwing" profile, which limits the amount of gingiva that is exposed when a person smiles.^[6] The case described above with score 3 lip line was treated by lip repositioning technique with successful clinical outcome. This procedure was most commonly used as a plastic surgical procedure and rarely as a dental procedure. Previous literatures and case series related to such clinical conditions advocated severing smile muscle attachment to prevent the relapse of smile muscle into its original position and this may also minimize the flap tension during suturing.^[5] Another method to prevent reattachment

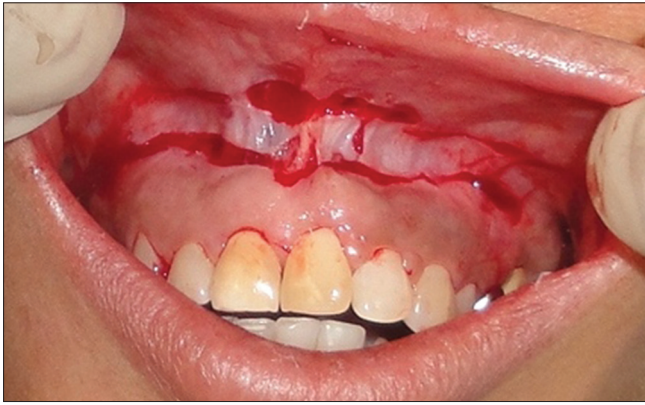

Figure 1: Partial thickness incision given

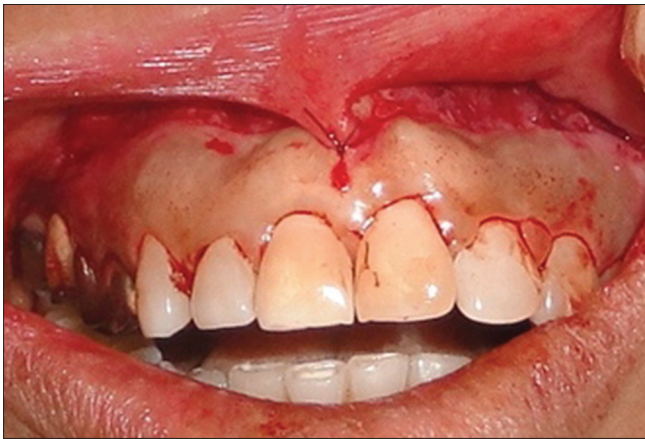

Figure 3: Stabilizing suture in the midline

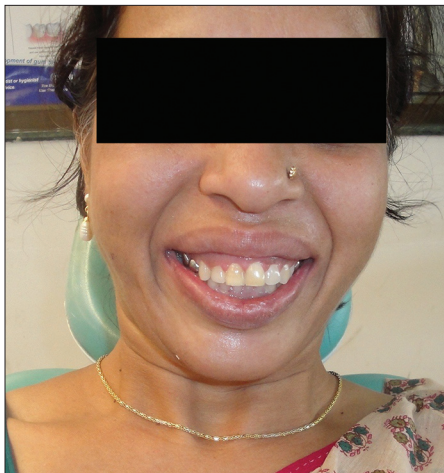

Figure 5: Post-operative view (frontal)

of the smile muscles is to use an alloplastic or autogenous separator, which is placed using nasal approach between the elevator muscles of the lip and the anterior nasal spine thus preventing the superior displacement of the repositioned lip. This procedure with nasal approach is taken up only in conjunction with rhinoplasty.^[5]

The case previously described in the literature has shown successful outcome of this technique for the correction of

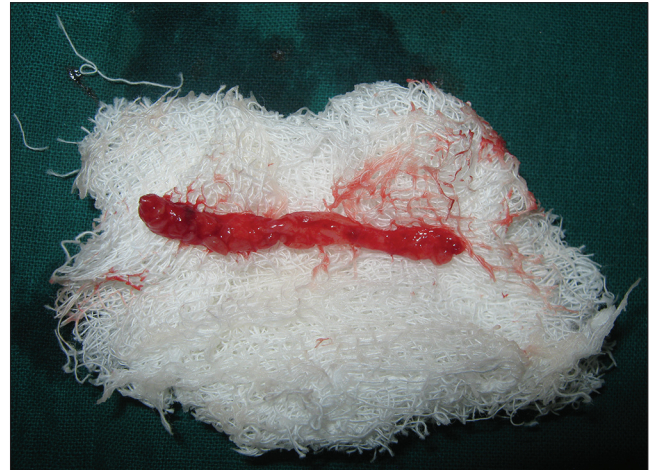


Figure 2: Excised portion of flap

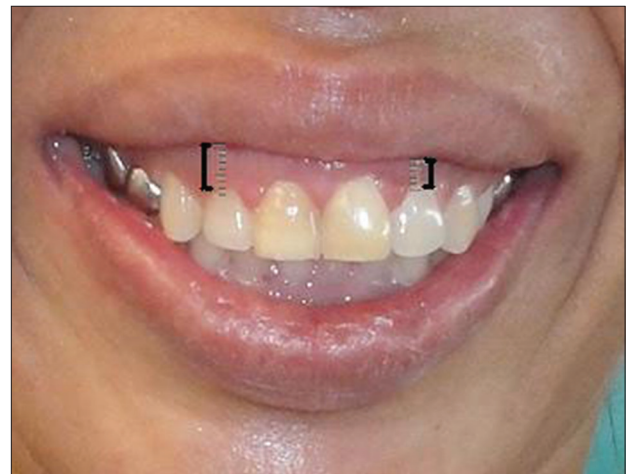


Figure 4: Three months post-operative view of reduced gingival display to 4-6 mm on extended smile

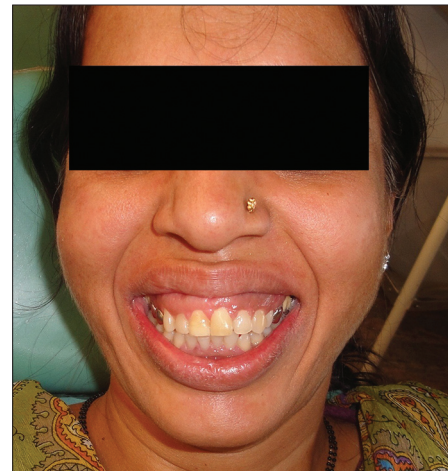

Figure 6: Pre-operative view (frontal)

excessive gingival display.^[5,6] We feel that lip repositioning technique over other treatments not only improves patient compliance (cost-effective, least time consuming), but also gives good healing results. Furthermore, we feel that this technique has an edge over other techniques

because it's simple, effective, minimal instrumentation, less time consuming, less invasive (compared with few techniques), cost-effective and easy to perform with excellent post-operative results, faster healing and patient satisfaction.

The limitations of this surgical technique include patients with inadequate attached gingiva and patients with severe skeletal deformities and severe vertical maxillary excess that has to be treated with orthognathic surgeries.^[7]

Conclusion

The current case report highlights the treatment of “a gummy smile” through a periodontal plastic procedure called lip repositioning with enormous patient motivation and satisfaction by improvement of esthetics. This technique holds importance that dental esthetic procedure has taken Periodontics to a different level other than hard-core Periodontics. Esthetics has now become an integral part of periodontal treatment plan with Periodontist playing a key role to combat the patient's embarrassment.

References

1. Kokich VO Jr, Kiyak HA, Shapiro PA. Comparing the perception of dentists and lay people to altered dental esthetics. *J Esthet Dent* 1999;11:311-24.
2. Jensen J, Joss A, Lang NP. The smile line of different ethnic groups in relation to age and gender. *Acta Med Dent Helv* 1999;4:38-46.
3. Lee EA. Aesthetic crown lengthening: Classification, biologic rationale, and treatment planning considerations. *Pract Proced Aesthet Dent* 2004;16:769-78; quiz 780.
4. Chu SJ, Karabin S, Mistry S. Short tooth syndrome: Diagnosis, etiology, and treatment management. *J Calif Dent Assoc* 2004;32:143-52.
5. Rosenblatt A, Simon Z. Lip repositioning for reduction of excessive gingival display: A clinical report. *Int J Periodontics Restorative Dent* 2006;26:433-37.
6. Gupta KK, Srivastava A, Singhal R, Srivastava S. An innovative cosmetic technique called lip repositioning. *J Indian Soc Periodontol* 2010;14:266-69.
7. Ezquerro F, Berrazueta MJ, Ruiz-Capillas A, Arregui JS. New approach to the gummy smile. *Plast Reconstr Surg* 1999;104:1143-50.

How to cite this article: Sheth T, Shah S, Shah M, Shah E. Lip reposition surgery: A new call in periodontics. *Contemp Clin Dent* 2013;4:378-81.

Source of Support: Nil. **Conflict of Interest:** None declared.

Announcement

Android App



Download
**Android
application**

FREE

A free application to browse and search the journal's content is now available for Android based mobiles and devices. The application provides “Table of Contents” of the latest issues, which are stored on the device for future offline browsing. Internet connection is required to access the back issues and search facility. The application is compatible with all the versions of Android. The application can be downloaded from <https://market.android.com/details?id=comm.app.medknow>. For suggestions and comments do write back to us.