

O172

### Gray matter reduction in high-risk subjects, recently diagnosed and chronic patients with schizophrenia: A revised coordinate-based meta-analysis

C. Brasso<sup>1\*</sup>, D. Liloia<sup>2</sup>, F. Cauda<sup>2</sup>, L. Mancuso<sup>2</sup>, A. Nani<sup>2</sup>, J. Manuello<sup>2</sup>, T. Costa<sup>2</sup>, S. Duca<sup>3</sup> and P. Rocca<sup>1</sup>

<sup>1</sup>Department Of Neuroscience, University of Turin, Torino, Italy;

<sup>2</sup>Department Of Psychology, University of Turin, TORINO, Italy and

<sup>3</sup>Neuroradiology, Koelliker Hospital, Torino, Italy

\*Corresponding author.

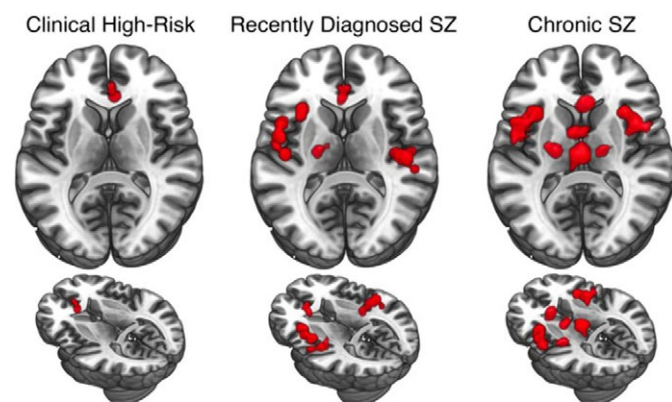
doi: 10.1192/j.eurpsy.2021.360

**Introduction:** Characterizing neuroanatomical markers of different stages of schizophrenia (SZ) to assess of how the disorder develops is extremely important for the clinical practice. It still remains uncertain how abnormalities are formed as SZ progresses.

**Objectives:** We reviewed and analyzed 113 voxel based morphometry studies on people at risk of or with schizophrenia to assess GM alterations at different stages of the disorder and to functionally characterize these GM variations.

**Methods:** We performed a meta-analysis of voxel-based morphometry studies of genetic and clinical high-risk subjects (g-/c-HR), recently diagnosed (RDSZ) and chronic SZ patients (ChSZ). We quantified gray matter (GM) changes associated with these four conditions and compared them with contrast and conjunctural data. We performed the behavioral analysis and networks decomposition of alterations to obtain their functional characterization.

**Results:** Compared to previous investigations, results reveal a robust cortical-subcortical, left-to-right homotopic progression of GM loss. The right anterior cingulate is the only altered region in all



a coordinate-based meta-analysis of different stages of schizophrenia highlights a clear progression of the grey matter damage

conditions. Contrast analyses show left-lateralized insular, amygdalar and parahippocampal GM reduction in RDSZ, which appears bilateral in ChSZ. An overlap between RDSZ and ChSZ is observed in the left insula, amygdala, precentral and inferior frontal gyri. Functional decomposition shows involvement of the salience network, with an enlargement of the sensorimotor network in RDSZ and the thalamus-basal nuclei network in ChSZ.

**Conclusions:** These results can help the research on diagnostic and neuroimaging biomarkers of SZ staging, as well as on the identification of new therapeutics neuroanatomic targets that could be addressed with focused magnetic or non-invasive electric stimulation.

**Disclosure:** No significant relationships.

**Keywords:** voxel-based morphometry; behavioral analysis; salience network; psychosis

O173

### Chronotopic encoding of emotional dimensions in the human brain assessed by fMRI

G. Lettieri<sup>1\*</sup>, G. Handjaras<sup>1</sup>, E. Ricciardi<sup>2</sup>, P. Pietrini<sup>2</sup> and L. Cecchetti<sup>1</sup>

<sup>1</sup>Momilab - Sane Group, IMT School for Advanced Studies Lucca, Lucca, Italy and <sup>2</sup>Momilab, IMT School for Advanced Studies, Lucca, Italy

\*Corresponding author.

doi: 10.1192/j.eurpsy.2021.361

**Introduction:** Affective experiences vary as function of context, motivations and the unfolding of events. This temporal fundamental aspect of emotional processes is often disrupted in psychiatric conditions.

**Objectives:** To investigate how the brain represents the association between affect and time, we combined fMRI and behavioral ratings during movie watching.

**Methods:** Participants watched 'Forrest Gump' in the fMRI scanner (n=14, 6F). Data were preprocessed (see 10.1101/2020.06.06.137851v1) and average brain activity from 1000 regions was extracted. Independent subjects (n=12, 5F) provided continuous ratings of the intensity of their affective state while watching the same movie. Using PCA, we derived the first 3 affective dimensions (polarity, complexity, intensity; 10.1038/s41467-019-13599-z) and computed their time-varying correlation in windows from 5-1000tps. We identified the window size with the maximum between-subjects accordance and computed the inter-subject functional connectivity (10.1038/ncomms12141). For each region, we obtained connectivity strength and its association in time with changes in affective dimensions ( $p_{\text{Bonf}} < 0.05$ ).

**Results:** Fluctuations in connectivity strength of the right rMFG, precuneus, pSTS/TPJ, dmPFC, aINS and left pMTG were associated to polarity. Also, connectivity of the right IPS/SPL, SFG, dpreCS, IFGpOrb, OFC, precuneus, vpreCS and pSTS/TPJ followed the timecourse of perceived intensity of affect.

**Conclusions:** Connectivity strength of default mode represents the pleasantness of the experience, whereas attention and control networks encode its intensity. Emotional descriptions converge in right temporoparietal and fronto-polar cortex, where the stream of affect is encoded in a chronotopic manner. These results expand our understanding of the neural correlates of emotional processing, a function severely affected by mental disorders.

**Disclosure:** No significant relationships.

**Keywords:** affective timecourse; naturalistic stimulation; emotions; fMRI