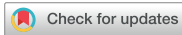

Images in This Issue  
Neuroscience



# Acute Spinal Subdural Hematoma in a Patient Taking Rivaroxaban

Woo-Seok Bang ,<sup>1</sup> Kyoung-Tae Kim ,<sup>1</sup> Man-Kyu Park ,<sup>1</sup> Joo-Kyung Sung ,<sup>1</sup> Hoseok Lee ,<sup>2</sup> and Dae-Chul Cho <sup>1</sup>

<sup>1</sup>Department of Neurosurgery, Kyungpook National University Hospital, Daegu, Korea

<sup>2</sup>Department of Radiology, Kyungpook National University Hospital, Daegu, Korea



Received: Aug 7, 2017

Accepted: Oct 28, 2017

Address for Correspondence:

Dae-Chul Cho, MD, PhD

Department of Neurosurgery, Kyungpook National University Hospital, 130 Dongdeok-ro, Jung-gu, Daegu 41944, Republic of Korea.  
E-mail: dccho@knu.ac.kr

© 2018 The Korean Academy of Medical Sciences.

This is an Open Access article distributed under the terms of the Creative Commons Attribution Non-Commercial License (<https://creativecommons.org/licenses/by-nc/4.0/>) which permits unrestricted non-commercial use, distribution, and reproduction in any medium, provided the original work is properly cited.

ORCID iDs

Woo-Seok Bang

<https://orcid.org/0000-0002-2806-6488>

Kyoung-Tae Kim

<https://orcid.org/0000-0003-4867-6854>

Man-Kyu Park

<https://orcid.org/0000-0001-7620-207X>

Joo-Kyung Sung

<https://orcid.org/0000-0001-5489-2866>

Hoseok Lee

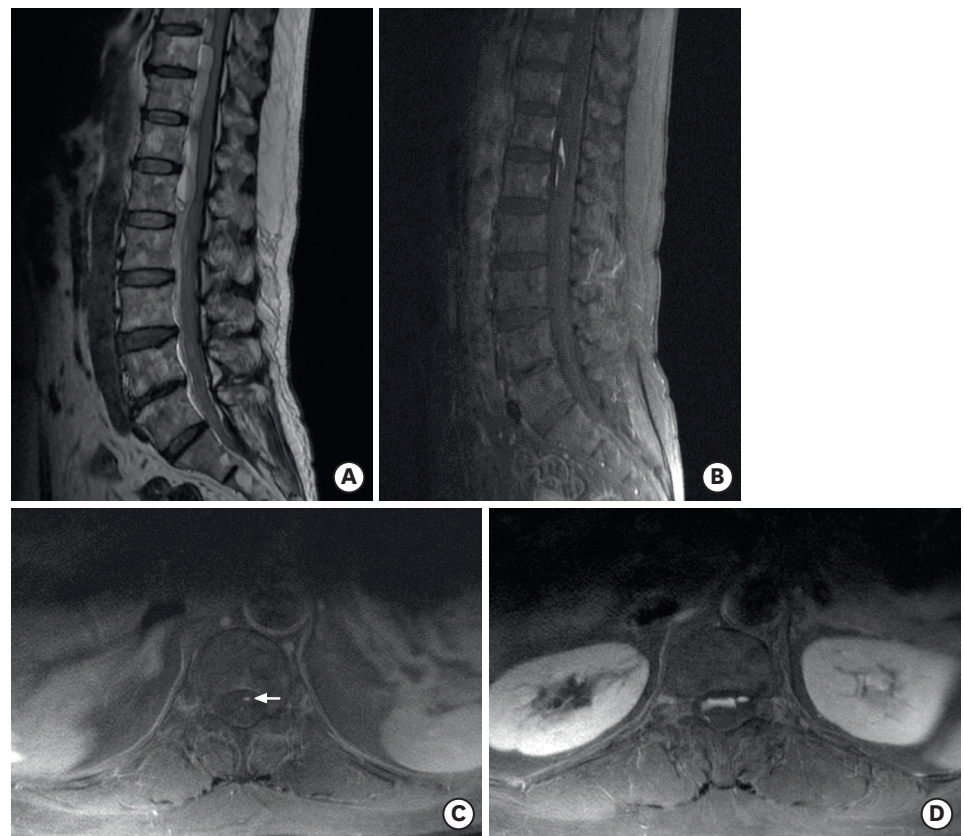
<https://orcid.org/0000-0003-3670-0693>

Dae-Chul Cho

<https://orcid.org/0000-0002-2899-8015>

Disclosure

The authors have no potential conflicts of interest to disclose.



**Fig. 1.** Initial MRI images. (A) The T2-weighted sagittal image of the low thoracic-lumbar spine shows the hyperacute-to-acute stage of hematoma, with fluid-fluid levels in the ventral aspect of the conus medullaris and cauda equine, from T9 to L2 with craniocaudal extension. (B) GdE fat-suppressed T1-weighted sagittal image shows a slit-like vivid enhancing lesion suggesting contrast extravasation at the T12–L1 levels. (C) GdE fat-suppressed T1-weighted axial image at T11 level shows the spot-like enhancing structure (white arrow) which looks like a vessel at the midline of ventral aspect of cord. (D) GdE fat-suppressed T1-weighted axial image at T12 level shows contrast extravasation at the ventral aspect of the cord which has continuity from above. MRI = magnetic resonance imaging, GdE = gadolinium-enhanced.

We report a case of a middle-aged woman who took rivaroxaban and exhibited a dramatic deterioration in lower extremity motor function after being assaulted, during which she sustained injury to her face but not to her back or other areas of her body. She had atrial flutter and had been taking rivaroxaban for 3 years, but denied history of coagulopathy and spinal vascular malformation.

**Author Contributions**

Conceptualization: Cho DC. Data curation: Kim KT, Park MK, Lee H. Writing - original draft: Bang WS. Writing - review & editing: Sung JK.

Preoperative lumbar spine magnetic resonance imaging demonstrated a massive spinal subdural hematoma (SDH), extending from the lower thoracic to the upper lumbar spine (**Fig. 1**). Gadolinium-enhanced T1-weighted imaging showed a region of contrast extravasation on the ventral aspect of the spinal cord, suggesting a rupture of an anterior spinal artery. Emergent total laminectomy was performed to decompress the affected spinal cord region, but the patient showed no improvement of her paraplegia.

According to a commonly recognized theory proposed by Rader,<sup>1</sup> the occurrence of spinal SDH is presumed to occur due to the rupture of a spinal vessel. The mechanism proposed by this theory is that a sudden increase of pressure in the thorax or abdomen results in an increase in pressure in a spinal vessel fed by the radiculomedullary artery, and that this pressure increase leads to vessel rupture, resulting in spinal SDH. To the best of our knowledge, the present case is the first to suggest the feasibility of Rader's theory<sup>1</sup> by showing compatible radiological findings. Additional concerns in the context of the present case are the hazards of chronic rivaroxaban therapy. There are only 3 cases of spontaneous rivaroxaban-associated spinal SDH reported in the literature.<sup>2-4</sup> This report suggests the possibility that severe spinal SDH can occur through physical trauma to non-spinal areas of the body, due to rupture of an anterior spinal artery, possibly caused by an abrupt increase in intra-abdominal pressure, in patients using an anticoagulant medication like rivaroxaban.

**REFERENCES**

1. Rader JP. Chronic subdural hematoma of the spinal cord: report of a case. *N Engl J Med* 1955;253(9):374-6. [PUBMED](#) | [CROSSREF](#)
2. Zaarour M, Hassan S, Thumallapally N, Dai Q. Rivaroxaban-induced nontraumatic spinal subdural hematoma: an uncommon yet life-threatening complication. *Case Rep Hematol* 2015;2015:275380. [PUBMED](#) | [CROSSREF](#)
3. Castillo JM, Afanador HF, Manjarrez E, Morales XA. Non-traumatic spontaneous spinal subdural hematoma in a patient with non-valvular atrial fibrillation during treatment with rivaroxaban. *Am J Case Rep* 2015;16:377-81. [PUBMED](#) | [CROSSREF](#)
4. Dargazanli C, Lonjon N, Gras-Combe G. Nontraumatic spinal subdural hematoma complicating direct factor Xa inhibitor treatment (rivaroxaban): a challenging management. *Eur Spine J* 2016;25 Suppl 1:100-3. [PUBMED](#) | [CROSSREF](#)