

NEUROIMAGING

Small vessel disease lesion type and brain atrophy: The role of co-occurring amyloid

Rutger Heinen¹ | Onno N. Groeneveld¹ | Frederik Barkhof^{2,3} | Jeroen de Bresser⁴ |
Lieza G. Exalto¹ | Hugo J. Kuijf⁵ | Niels D. Prins^{6,7} | Philip Scheltens^{6,7} |
Wiesje M. van der Flier⁶ | Geert Jan Biessels¹ | On behalf of the TRACE-VCI study group[#]

¹ Department of Neurology and Neurosurgery, UMC Utrecht Brain Center, Utrecht University, Utrecht, the Netherlands

² Department of Radiology and Nuclear Medicine, Amsterdam Neuroscience, Vrije Universiteit Amsterdam, Amsterdam, the Netherlands

³ Institutes of Neurology & Healthcare Engineering, University College London (UCL), London, UK

⁴ Department of Radiology, Leiden University Medical Center, Leiden, the Netherlands

⁵ Image Sciences Institute, University Medical Center Utrecht, Utrecht, the Netherlands

⁶ Alzheimer Center & Department of Neurology, Vrije Universiteit Amsterdam, Amsterdam, the Netherlands

⁷ Brain Research Center, Amsterdam, the Netherlands

Correspondence

Rutger Heinen, Department of Neurology and Neurosurgery, UMC Utrecht Brain Center, G03.232, P.O. Box 85500, 3508 GA Utrecht, the Netherlands.
Email: R.Heinen-2@umcutrecht.nl

[#]Members of TRACE-VCI study group are mentioned in the acknowledgements.

Abstract

Introduction: It is unknown whether different types of small vessel disease (SVD), differentially relate to brain atrophy and if co-occurring Alzheimer's disease pathology affects this relation.

Methods: In 725 memory clinic patients with SVD (mean age 67 ± 8 years, 48% female) we compared brain volumes of those with moderate/severe white matter hyperintensities (WMHs; $n = 326$), lacunes ($n = 132$) and cerebral microbleeds ($n = 321$) to a reference group with mild WMHs ($n = 197$), also considering cerebrospinal fluid (CSF) amyloid status in a subset of patients ($n = 488$).

Results: WMHs and lacunes, but not cerebral microbleeds, were associated with smaller gray matter (GM) volumes. In analyses stratified by CSF amyloid status, WMHs and lacunes were associated with smaller total brain and GM volumes only in amyloid-negative patients. SVD-related atrophy was most evident in frontal (cortical) GM, again predominantly in amyloid-negative patients.

Discussion: Amyloid status modifies the differential relation between SVD lesion type and brain atrophy in memory clinic patients.

KEYWORDS

Alzheimer's disease, brain atrophy, cerebral microbleeds, cerebral small vessel disease, lacunes, magnetic resonance imaging, vascular cognitive impairment, white matter hyperintensities

1 | INTRODUCTION

Brain atrophy is common in memory clinic patients and is related to cognitive decline,^{1,2} yet understanding of the etiology of brain atrophy in these patients is incomplete. Evidently, Alzheimer's disease (AD) and other neurodegenerative pathologies are key contributors to atrophy,

but a role of vascular brain injury, in particular cerebral small vessel disease (SVD), is also increasingly recognized.³⁻⁵

SVD is an etiological heterogeneous construct. The most common forms are arteriolosclerosis and cerebral amyloid angiopathy.⁶ Different forms of SVD manifest themselves in different types of vascular brain lesions, which can be seen on magnetic resonance imaging (MRI):

This is an open access article under the terms of the [Creative Commons Attribution-NonCommercial-NoDerivs](https://creativecommons.org/licenses/by-nc-nd/4.0/) License, which permits use and distribution in any medium, provided the original work is properly cited, the use is non-commercial and no modifications or adaptations are made.

© 2020 The Authors. *Alzheimer's & Dementia: Diagnosis, Assessment & Disease Monitoring* published by Wiley Periodicals, Inc. on behalf of Alzheimer's Association

white matter hyperintensities of presumed vascular origin (WMHs), lacunes, and cerebral microbleeds.³ It is unclear whether different MRI manifestations of SVD differentially relate to brain atrophy. Previous studies have mostly focused on a single lesion type, in particular WMHs, without directly comparing different lesion types. Yet different lesion types can reflect different disease processes in different parts of the brain, potentially with different relationships with gray matter (GM) degeneration.⁷ Evaluation of such potential differences may provide further leads on disease processes underlying atrophy.

A substantial proportion of memory clinic patients with SVD will also have AD,^{8,9} but insight into the interplay between vascular brain injury and AD pathological processes is incomplete. Large studies assessing both processes in relation to brain atrophy are needed, as was recently stressed.^{4,10} We therefore investigated the relation between different SVD lesion types on MRI and brain atrophy (in terms of severity and pattern) in a large population of memory clinic patients and determined whether this relation was modified by cerebrospinal fluid (CSF) amyloid biomarker status.

2 | MATERIALS AND METHODS

2.1 | Study population

Patients were included from the TRACE-VCI study cohort, which consists of 860 memory clinic patients from two Dutch tertiary outpatient clinics (Amsterdam University Medical Center and University Medical Center Utrecht). For the TRACE-VCI study, patients were eligible if their MRI showed at least a minimal burden of vascular brain injury, including:

- mild WMHs (Fazekas scale grade 1¹¹) and presence of ≥ 2 vascular risk factors (hypertension, hypercholesterolemia, diabetes mellitus, obesity, current smoking, or a reported history of a vascular event other than stroke);
- moderate/severe WMHs (Fazekas ≥ 2);
- ≥ 1 lacune(s);
- ≥ 1 (sub)cortical infarct(s);
- ≥ 1 cerebral microbleed(s);
- ≥ 1 intracerebral hemorrhage(s).¹²

Patients were included regardless of severity of their cognitive deficit, including patients with no objective cognitive impairment, mild cognitive impairment (MCI), and dementia. Patients with a primary non-vascular and non-neurodegenerative etiology (eg, brain tumor, hydrocephalus, or excessive alcohol consumption) were excluded. For the current study on SVD, we excluded patients with non-lacunar (sub)cortical infarcts ($n = 96$) and intracerebral hemorrhages ($n = 11$), because presence of these lesions can substantially affect brain volumes. Of the remaining 753 patients, brain volume measurements could be generated in 725 patients, which comprise the current study population (see Appendix B, Figure SB1 in supporting information).

The study was approved by the institutional review boards of the Amsterdam University Medical Center and the University Medical Center Utrecht. All subjects provided written informed consent prior to any research-related procedures.

2.2 | Image acquisition

Patients were scanned on one of six different MRI scanners: four at the Amsterdam University Medical Center and two at the University Medical Center Utrecht. MRI vendors were either General Electric (GE) or Philips. All patients were scanned using an MRI protocol that included a 3D T1-weighted, fluid-attenuated inversion recovery (FLAIR) and T2*-weighted/susceptibility-weighted imaging sequence ([12]; for details see Appendix A.1 in supporting information).

2.3 | Cerebral SVD lesion types on MRI

Presence of WMHs (using the Fazekas scale for deep WMHs, ranging from 0 to 3¹¹), lacunes, and cerebral microbleeds was rated on FLAIR and T2*/susceptibility weighted images by a resident neurology (RH, 4 years of experience) and a neuroradiologist (in training; JdB, 11 years of experience), using the STRIVE (standards for reporting vascular changes in neuroimaging) criteria.³

2.4 | WMH and brain volume measurements

We specifically used segmentation tools known to be relatively insensitive to interscanner differences and a high burden of pathology.¹³ A semi-automated processing pipeline was used to obtain WMH and brain volumes (for details see Appendix A.2 in supporting information). This pipeline consisted of (1) automatic WMH segmentation using k-nearest neighbor classification with tissue type priors; (2) lesion filling using the SLF-toolbox; (3) automatic segmentation of lesion-filled images using the Computational Anatomic Toolbox (CAT12). Lacunes, non-lacunar infarcts, intracerebral hemorrhages, and incidental findings were segmented manually using an in-house developed MeVisLab (MeVis Medical Solutions AG, Bremen, Germany) tool.¹⁴⁻¹⁶

Total brain volume (TBV) was defined as the sum of GM and white matter (WM) volumes (including the volume of pathology). Regional GM, WM, and CSF volumes were obtained using the Hammers atlas in CAT12, dividing the brain into 68 regions of interest: 32 per hemisphere and four infratentorial regions (<http://brain-development.org>).¹⁷⁻²⁰ To compensate for variability in head size, all brain volumes were normalized using the "residual normalization method."²¹

2.5 | Cerebrospinal fluid testing

CSF concentrations of amyloid beta₄₂ (or A β ₄₂), tau, and/or total tau phosphorylated at threonine 181 (or p-tau) were measured using

commercially available enzyme-linked immunosorbent assays (ELISAs) at a central laboratory for clinics at the Department of Clinical Chemistry of the Amsterdam University Medical Center²² (for details see Appendix A.3 in supporting information). Patients with a low CSF concentration of A β ₄₂ (< 640 ng/L) were assumed to have a high brain amyloid load, and hence were considered amyloid positive.²³ For the present study, CSF data were available for 488 patients (67%).

2.6 | Statistical analysis

All analyses were performed using IBM SPSS version 25 unless specified (for details see Appendix A.4 in supporting information).

2.6.1 | Relation between lesion type and brain atrophy

The relation between lesion type and brain atrophy was explored with linear regression analyses (to obtain an indication of effect sizes) as well as with Bayesian network analyses (to investigate independent relations between different lesion types and brain atrophy). In the linear regression analysis, TBV, GM, and WM volumes (normalized for head size) were compared between each lesion type and a reference group with only Fazekas score 1 and ≥ 2 vascular risk factors (but no other lesions). To limit the effect of using different MR scanners on brain volume measurements, we included a model term for scanner type (using effect coding). We also adjusted for age, sex, and additionally for clinical diagnosis (no objective cognitive impairment, MCI, or dementia) and the number of vascular risk factors. We also used log-transformed WMH volume as a continuous variable.

Bayesian network analyses (bnlearn R package²⁴; for settings see Duering et al.²⁵) were used to assess the conditional dependencies between each lesion type, age, and sex (potential determinants) and brain volumes (outcome). In Bayesian network analyses, variables with a deterministic influence on the outcome (conditionally independent variables) are identified and separated from others with only an indirect influence on the outcome. Networks are produced in which direct determinants are connected directly to the outcome, while conditionally independent variables are connected only indirectly, via other variables. Normalized brain volumes were used as outcome (standardized into z-scores using the mean and standard deviation [SD] of the whole study sample and corrected for scanner effect). The strength of the connections between direct determinants and outcome was assessed by 100 bootstrap replications.²⁶ Only connections that were strong enough (> 40% replications) were shown in the final network.

For WMH, which proved to be the strongest determinant of atrophy, we also assessed if it was associated with atrophy in specific brain regions. Normalized regional brain volumes were standardized into z-scores using the mean and SD of the whole study sample and corrected for age, sex, and scanner effect. We compared the relationship between log WMH volume and regional brain volumes for all 68

TABLE 1 Baseline characteristics of the total study population

	Number of patients, n total = 725
Demographics	
Age, years	67 \pm 8
Sex, female	346 (48)
Years of education	12 [10-14]
Vascular risk factors	
Hypertension	610 (84)
Hypercholesterolemia	304 (42)
Diabetes mellitus	132 (18)
Current smoker	140 (19)
Obesity, body mass index ≥ 30	149 (21)
History of stroke	32 (4)
History of reported vascular events other than stroke	66 (9)
Number of vascular risk factors	2 [1-3]
Clinical diagnosis	
No objective cognitive impairment	176 (24)
Mild cognitive impairment	175 (24)
Dementia	374 (52)
<i>Vascular</i>	21 (3)
<i>Neurodegenerative</i>	329 (45)
Alzheimer's disease	254 (35)
Frontotemporal disease	23 (3)
Lewy body dementia	17 (2)
Others ^a	35 (5)
<i>Unknown etiology</i> ^b	24 (3)

Notes: Data are presented as mean \pm standard deviation, number of patients (percentage of total study population) or median [interquartile range]. For years of education data were present in 720 patients. For vascular risk factors, current smoker and obesity data were present in 718 and 713 patients, respectively. ^aSuch as primary progressive aphasia, cortical basal syndrome, and progressive supranuclear palsy. ^bDementia of unknown origin, further examination needed to state diagnosis.

regions using linear regression analyses (with Bonferroni correction for multiple testing, adjusting for age, sex, and scanner effect).

2.6.2 | Modification by co-occurring amyloid pathology

To investigate whether the relation between lesion type and brain atrophy was modified by co-occurring amyloid pathology, we assessed possible interactions between each lesion type and CSF amyloid status in relation to brain atrophy. We also performed post-hoc analyses stratified for CSF amyloid status. Normalized brain volumes were standardized in the same manner as described before, but using the mean and SD of the CSF subgroup, amyloid-negative or amyloid-positive subgroup depending on the specific analysis.

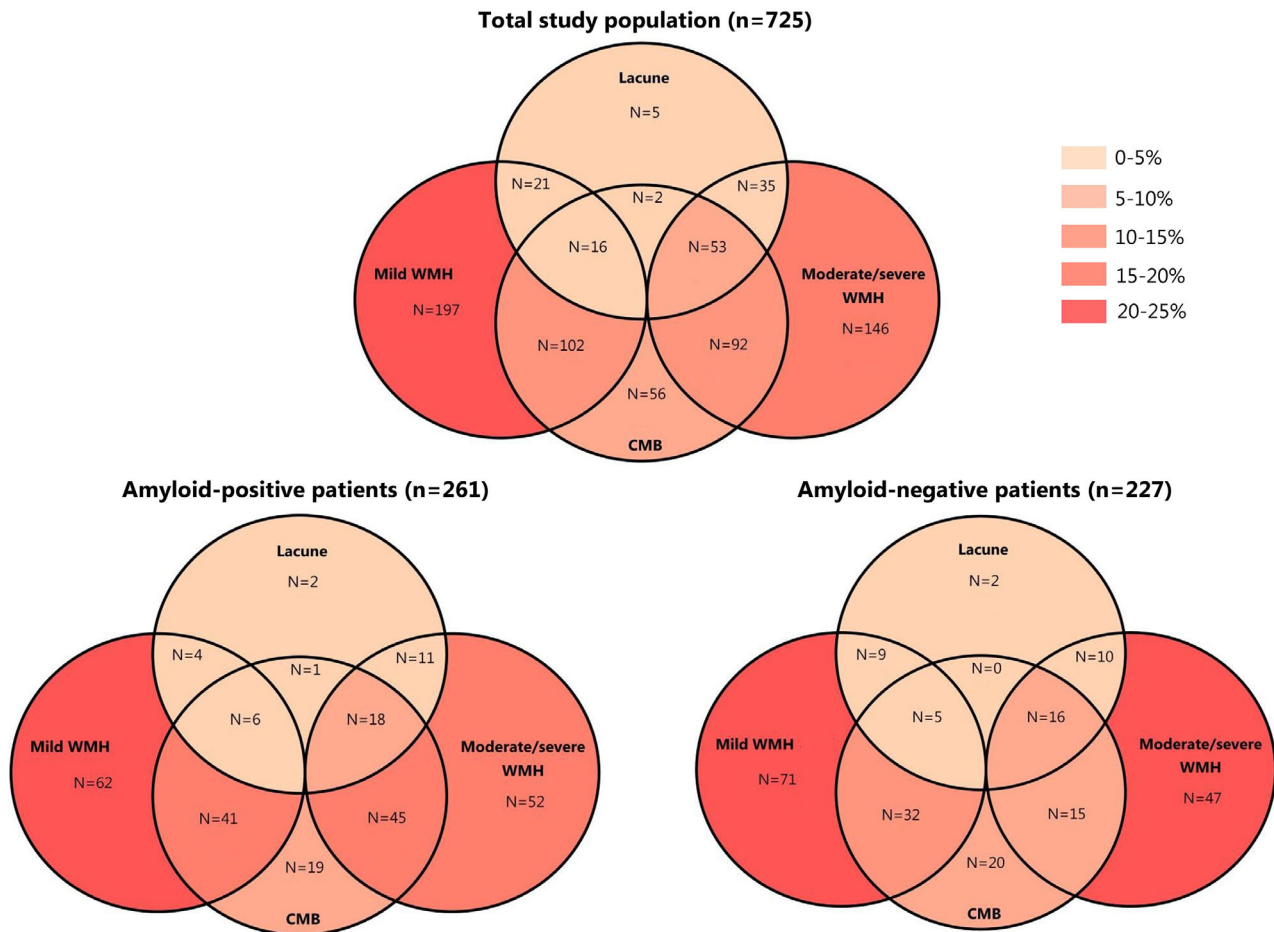


FIGURE 1 Occurrence of lesion types. Venn diagram showing the occurrence of lesion types in the entire study population ($n = 725$) as well as in the cerebrospinal fluid (CSF) amyloid-positive ($n = 261$) and amyloid-negative ($n = 227$) patients in the CSF subgroup. In 719 patients (99%), information regarding presence/absence of cerebral microbleeds (CMBs) was present. The number of patients with a certain lesion type (alone or in combination with another lesion type) is shown. The colors represent the percentage of the respective patient group, illustrating which (combination of) lesion types were observed. The majority of patients only had mild white matter hyperintensities (WMHs; Fazekas score of 1) or moderate/severe WMHs (Fazekas score 2 or 3) but no other lesions. Multiple lesion types occurred in 321 patients (44%) of the entire study population. Of 382 patients (53%) with either cerebral microbleeds/lacunae, 242 (63%) had multiple cerebral microbleeds/lacunae; 71 patients (10%) had multiple lacunae (max: 30). 171 patients (24%) had multiple cerebral microbleeds (CMBs; max: ~500). Of the patients with CMBs, 37 patients (12%) had only deep CMBs, 212 patients (66%) had only lobar CMBs, and 70 patients (22%) both had deep and lobar CMBs. In two patients, no information regarding CMB location was available

2.7 | Data availability

The data that support the findings of this study are available from the corresponding author, upon reasonable request.

3 | RESULTS

3.1 | Baseline characteristics

The 725 patients had a mean (\pm SD) age of 67 (\pm 8) years and 348 (48%) were female. Baseline characteristics are shown in Table 1. A total of one thousand seventy six patients (24%) had no objective cognitive impairment, 175 (24%) MCI, and 374 (52%) dementia. Baseline characteristics of patients with available CSF ($n = 488$, 67%) are

shown in Appendix C, Table CS1 in supporting information. Patients with available CSF were younger ($t = 2.8$, $P = .006$), less often had hypertension ($\chi^2 = 8.6$, $P = .003$) or hypercholesterolemia ($\chi^2 = 5.7$, $P = .017$), and were less often obese ($\chi^2 = 4.2$, $P = .04$) compared to those without available CSF. In the CSF subgroup, amyloid-negative patients were younger ($t = -4.9$, $P < .001$) and more often obese ($\chi^2 = 8.9$, $P = .003$) than amyloid-positive patients. Amyloid-negative patients more often had no objective cognitive impairment ($\chi^2 = 72.3$, $P < .001$) and were less often demented ($\chi^2 = 52.9$, $P < .001$) than amyloid-positive patients.

The occurrence of each lesion type (and the overlap between lesion types) is shown in Figure 1. A total of three thousand twenty one patients (44%) had multiple lesion types. Moderate/severe WMHs (Fazekas score 2 or 3) were present in 326 patients (45%), lacunes in 132 patients (18%), and cerebral microbleeds in 321 patients (44%),

TABLE 2 Relationship between lesion type and brain volumes for total study population and stratified for CSF amyloid biomarker status

	Total brain volume	Gray matter volume	White matter volume
Total study population (n = 725)			
Mild WMHs and ≥ 2 VRF (reference; n = 197)	—	—	—
Moderate/severe WMHs (n = 326)	-0.02 [-0.10;0.05]	-0.07 [-0.14;-0.002] [*]	0.05 [-0.03;0.13]
Lacunes (n = 132)	-0.06 [-0.15;0.03]	-0.08 [-0.17;0.004]	0.0001 [-0.10;0.10]
Cerebral microbleeds (n = 321)	-0.02 [-0.09;0.06]	-0.05 [-0.12;0.03]	0.03 [-0.05;0.11]
CSF amyloid negative (n = 227)			
Mild WMHs and ≥ 2 VRF (reference, n = 71)	—	—	—
Moderate/severe WMHs (n = 88)	-0.10 [-0.24;0.04]	-0.14 [-0.27;-0.01] [*]	-0.002 [-0.15;0.14]
Lacunes (n = 42)	-0.22 [-0.37;-0.07] [*]	-0.22 [-0.37;-0.08] [*]	-0.10 [-0.27;0.07]
Cerebral microbleeds (n = 88)	-0.09 [-0.23;0.05]	-0.07 [-0.21;0.06]	-0.06 [-0.21;0.08]
CSF amyloid positive (n = 261)			
Mild WMHs and ≥ 2 VRF (reference; n = 62)	—	—	—
Moderate/severe WMHs (n = 126)	0.08 [-0.05;0.22]	0.05 [-0.08;0.18]	0.08 [-0.06;0.22]
Lacunes (n = 42)	0.08 [-0.10;0.26]	0.07 [-0.10;0.25]	0.04 [-0.14;0.23]
Cerebral microbleeds (n = 130)	0.12 [-0.02;0.25]	0.10 [-0.03;0.23]	0.08 [-0.06;0.21]

Notes: Data are presented as standardized beta coefficients with 95% confidence intervals after correction for age, sex, and scanner effect. All brain volumes were corrected for variations in head size using the total intracranial volume.

Abbreviations: CSF, cerebrospinal fluid; VRF, vascular risk factors; WMH, white matter hyperintensities.

^{*} $P < .05$.

of which 37 (12%) had only deep, 212 (66%), only lobar and 70 patients (22%) both deep and lobar cerebral microbleeds (CMBs). (In two patients, information on CMB presence/location was missing). The reference group of only Fazekas score 1 and ≥ 2 vascular risk factors (but no other lesions) consisted of 197 patients (27%). In the CSF subgroup, amyloid-positive patients more often had moderate/severe WMHs compared to amyloid-negative patients ($\chi^2 = 4.5$, $P = .04$). Occurrence of lacunes and cerebral microbleeds did not differ between amyloid-negative and amyloid-positive patients (see Figure 1).

In the entire study population, mean TBV (normalized for head size, in mL) was 1042 ± 60 mL, mean GM volume 565 ± 44 mL, and mean WM volume 477 ± 33 mL. Median WMH volume was 6 mL (range 0.05 to 166 mL). In the CSF subgroup, amyloid-positive patients had a smaller TBV (amyloid positive: 1035 ± 24 mL; amyloid negative: 1064 ± 30 mL; standardized β coefficient [95% CI], adjusted for age, sex, and scanner effect: $-0.19 [-0.27;-0.11]$, $P < .001$) and GM volume (amyloid positive: 558 ± 20 mL; amyloid negative: 585 ± 23 mL; β : $-0.26 [-0.33;-0.18]$, $P < .001$), but similar WM volume (amyloid positive: 476 ± 14 mL; amyloid negative: 479 ± 15 mL; β : $-0.01 [-0.09;0.08]$, $P = .86$) compared to the amyloid-negative patients.

3.2 | WMHs relate to GM atrophy

WMHs, in particular, were related to brain atrophy: compared to the reference group (Fazekas score 1), patients with moderate/severe WMHs (Fazekas score 2–3) had smaller GM volume (standardized β coefficient [95% confidence interval (CI)]: $-0.07 [-0.14;-0.002]$, $P = .045$; additionally adjusted for clinical diagnosis:

$-0.06 [-0.12;0.005]$, $P = .07$), but TBV and WM volumes did not differ significantly (Table 2). When WMH volume was entered as a continuous variable, it was also significantly associated with TBV ($-0.16 [-0.22;-0.09]$, $P < .001$; additionally adjusted for clinical diagnosis: $-0.09 [-0.15;-0.03]$, $P = .003$) as well as GM volume ($-0.24 [-0.30;-0.17]$, $P < .001$; additionally adjusted for clinical diagnosis: $-0.17 [-0.22;-0.11]$, $P < .001$), but not WM volume. Patients with lacunes had no significant differences in brain volumes compared to the reference group, although a trend with smaller GM volume was observed ($-0.08 [-0.17;0.004]$, $P = .06$; additionally adjusted for clinical diagnosis: $-0.08 [-0.16;-0.007]$, $P = .03$). Patients with cerebral microbleeds had no significant differences in brain volumes compared to the reference group. This was also the case for patients with multiple (≥ 5), lobar (pure or any), or deep microbleeds. Adjusting for the number of vascular risk factors did not change any of the previous results. There was no significant interaction between clinical diagnosis and moderate/severe WMHs, lacunes, or microbleeds in relation to TBV, GM, or WM volume (interaction terms all $P > .05$).

The Bayesian network analyses integrating all lesion types confirmed the relation between WMHs and GM volume (see Figure 2). These analyses showed WMHs directly determined GM volume, independent of lacunes and cerebral microbleeds.

3.2.1 | Pattern of SVD-related brain atrophy

Brain atrophy in relation to WMHs occurred in specific brain regions (see Figure 3). Differences were most evident in frontotemporal cortical regions, but also the postcentral gyrus, thalamus, and anterior

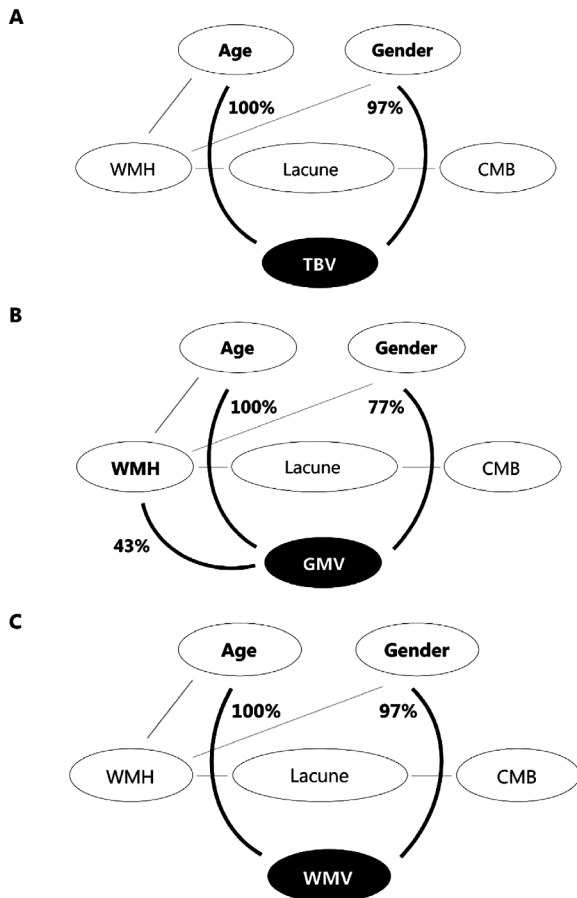


FIGURE 2 Bayesian networks. Bayesian networks for total brain volume (TBV, panel A), gray matter volume (GMV, panel B), and white matter volume (WMV, panel C). Variables that are directly connected to one of the cognitive domains are identified as direct determinants. Variables that are connected indirectly to the cognitive domains (via other variables) are conditionally independent. As such, this method separates determinants with a direct deterministic influence on the outcome variable from other determinants that, although showing a univariate correlation with the outcome variable, have only an indirect influence when taking the direct determinants into account. Percentages indicate the confidence level of the arcs toward brain volumes determined by 100 bootstrap replications. These analyses showed white matter hyperintensities (WMHs) directly determined gray matter volume, independent of lacunes and cerebral microbleeds. CMB, presence of cerebral microbleed(s); WMH, moderate/severe WMHs (Fazekas score 2 or 3)

and posterior cingulate gyrus (see Appendix C, Table CS2 in supporting information). In the superior parietal gyrus, patients with low WMH burden had smaller GM volumes compared to patients with high WMH burden, albeit not significant (Figure 3).

3.3 | Relation between WMHs and GM atrophy is modified by amyloid status

Analyses in patients with available CSF ($n = 488$) showed that the relation between lesion type and brain atrophy was influenced by co-

occurring amyloid pathology (Table 2). There was a significant inverse interaction between CSF amyloid status and lesion type in relation to brain atrophy (interaction term WMH burden \times CSF amyloid status for TBV: $P = .012$; GM volume: $P = .006$), lacunes (TBV: $P = .012$; GM volume: $P = .006$), and cerebral microbleeds (TBV: $P = .01$; GM volume: $P = .02$). In amyloid-negative patients, moderate/severe WMHs were associated with smaller GM volume ($-0.14 [-0.27; -0.01]$, $P = .035$) and lacunes with smaller TBV ($-0.22 [-0.37; -0.07]$, $P = .004$) and GM volume ($-0.22 [-0.37; -0.08]$, $P = .003$) compared to the reference group. By contrast, in amyloid-positive patients, none of the small vessel lesion types was associated with brain atrophy (Table 2). Vice versa, the effect size of the reduction in TBV and GM volume associated with a positive compared to negative CSF amyloid status was almost twice as large in patients with a low WMH burden relative to patients with a high WMH burden (Appendix C, Table CS3 in supporting information). The same was observed for the relation between the CSF amyloid status and TBV and GM volume in the absence versus the presence of lacunes.

The Bayesian network analyses confirmed the relation between lesion type and brain atrophy in amyloid-negative patients (data not shown), with lacunes directly determining GM volume. Additionally, WMHs had an indirect effect (via lacunes) on GM volume (data not shown).

The pattern of SVD-related brain atrophy also differed depending on CSF amyloid status (Figure 4). In amyloid-negative patients, right mid frontal gyrus, left and right thalamus, and right precentral gyrus, GM volumes were significantly smaller in patients with high WMH burden compared to patients with low WMH burden (Bonferroni-corrected $P < .05$, see Appendix C, Table CS4 in supporting information). In amyloid-positive patients, only left superior temporal gyrus GM volumes were significantly smaller in patients with high WMH burden compared to patients with low WMH burden (Bonferroni-corrected $P < .05$, Appendix C, Table CS4 in supporting information). No significant interaction between WMH burden and CSF amyloid status was found after correcting for multiple testing (Bonferroni-corrected $P > .05$). Regional brain volume analyses were not performed for patients with and without lacunes, due to a lack of power.

4 | DISCUSSION

This study demonstrates that different manifestations of SVD differentially relate to brain atrophy in memory clinic patients, especially in the absence of concurrent amyloid pathology. In particular WMHs and lacunes were related to brain atrophy. WMH associated brain atrophy was most pronounced in frontal cortical GM regions.

4.1 | SVD-related brain atrophy

SVD burden has previously been shown to be related to brain atrophy in memory clinic patients.⁵ While it is a trend in SVD research to use a SVD burden score to capture multiple types of SVD-related brain

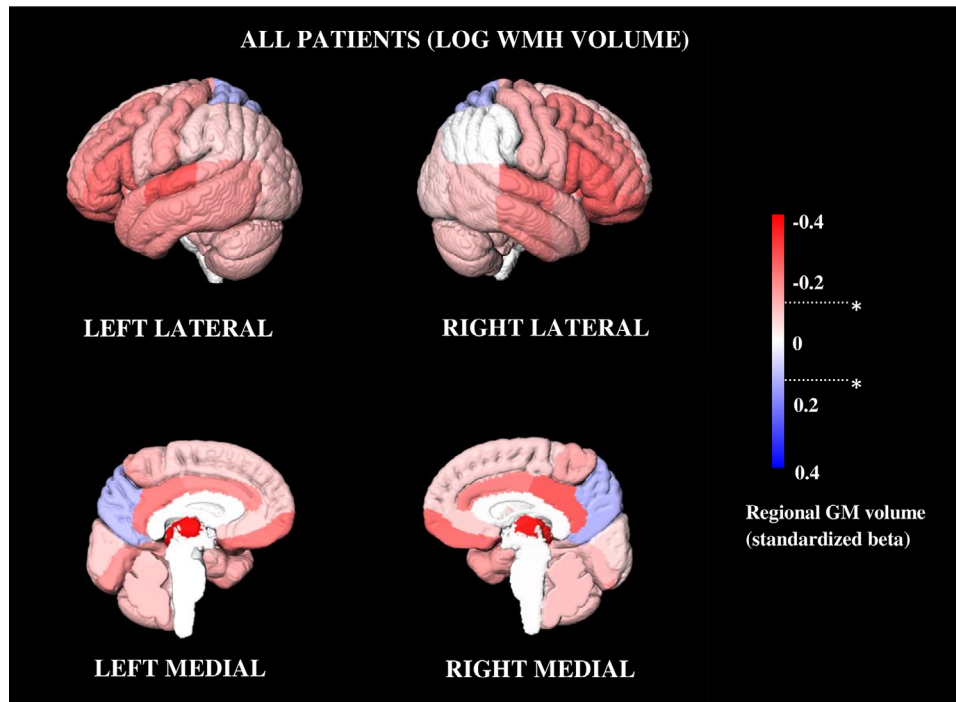


FIGURE 3 Regional brain volume analysis. Effect size map showing the relation between log white matter hyperintensity (WMH) volume and regional gray matter (GM) volume using standardized beta coefficients (red: GM volume smaller in patients with higher log WMH volume; blue: GM volume smaller in patients with lower log WMH volume) in all patients ($n = 725$). Across all patients higher log WMH volume was associated with smaller GM volume in several (predominantly frontotemporal) brain regions. * Bonferroni-corrected $P < .05$

injury in a single measure,²⁷ the effects of different lesion types are of interest because different lesion types can reflect different underlying pathological processes.^{7,28–31} Previous studies investigating the relation between SVD and brain atrophy have often focused on a single lesion type, without directly comparing different lesion types. Most of the research has been done on WMHs,^{32–37} showing that WMHs were related to brain atrophy. For lacunes, results have been conflicting, with most studies finding a relation with brain atrophy,^{35,38–40} while others do not.³⁶ We are aware of only one study that investigated the relation between cerebral microbleeds and brain atrophy and found no association.³⁷ We now directly compared different lesion types in relation to brain atrophy in a large cohort of memory clinic patients and indeed observed WMHs and lacunes, but not cerebral microbleeds, were related to brain atrophy.

4.2 | Pattern of SVD-related brain atrophy

Previous studies that investigated the pattern of SVD-related brain atrophy found a relation between WMHs and predominantly cortical GM atrophy.^{34–36,38–40} Regarding lacunes, most studies also found a relation with cortical GM atrophy,^{35,38–40} while one study also found an association with subcortical GM atrophy.⁴⁰

Only three of the previous studies^{34,35,39} have specifically investigated the regional pattern of cortical GM atrophy. Two studies^{34,39} were done in patients with symptomatic lacunes with moderate/severe WMHs, while the other³⁵ used memory clinic patients with a history

of stroke due to SVD or a lacune on MRI. All three studies found a rather global pattern of cortical GM atrophy in relation to WMHs, with relative sparing of hippocampal and medial temporal regions. In the present study, investigating a large cohort of memory clinic patients with SVD, GM atrophy in relation to WMHs was predominantly seen in frontotemporal, but not parietal-occipital, regions.

4.3 | Modification by amyloid pathology

The interplay between SVD and AD pathological processes has gained increasing attention in the past decade.⁴¹ While many studies have investigated the interaction between amyloid and WMHs in relation to cognition and prognosis, with variable results (see Roseborough et al.⁴²), brain atrophy as an outcome has hardly been studied.^{43,44} We now show that there is indeed an interaction between WMHs and CSF amyloid status in relation to brain atrophy. WMHs and lacunes were related to atrophy, but primarily in amyloid-negative patients. Vice versa, the relation between CSF amyloid status and brain atrophy was much stronger in patients with a low burden of WMH or lacunes.

There is thus converging evidence that both SVD and AD pathological processes contribute to brain atrophy in memory clinic patients, but for each this is most evident in the absence of the other. This could perhaps be explained by a ceiling effect, possibly linked to disease stage. Longitudinal studies could give more insight into the combined effects of WMHs and amyloid beta on brain atrophy over time and reveal the temporality of both disease processes.

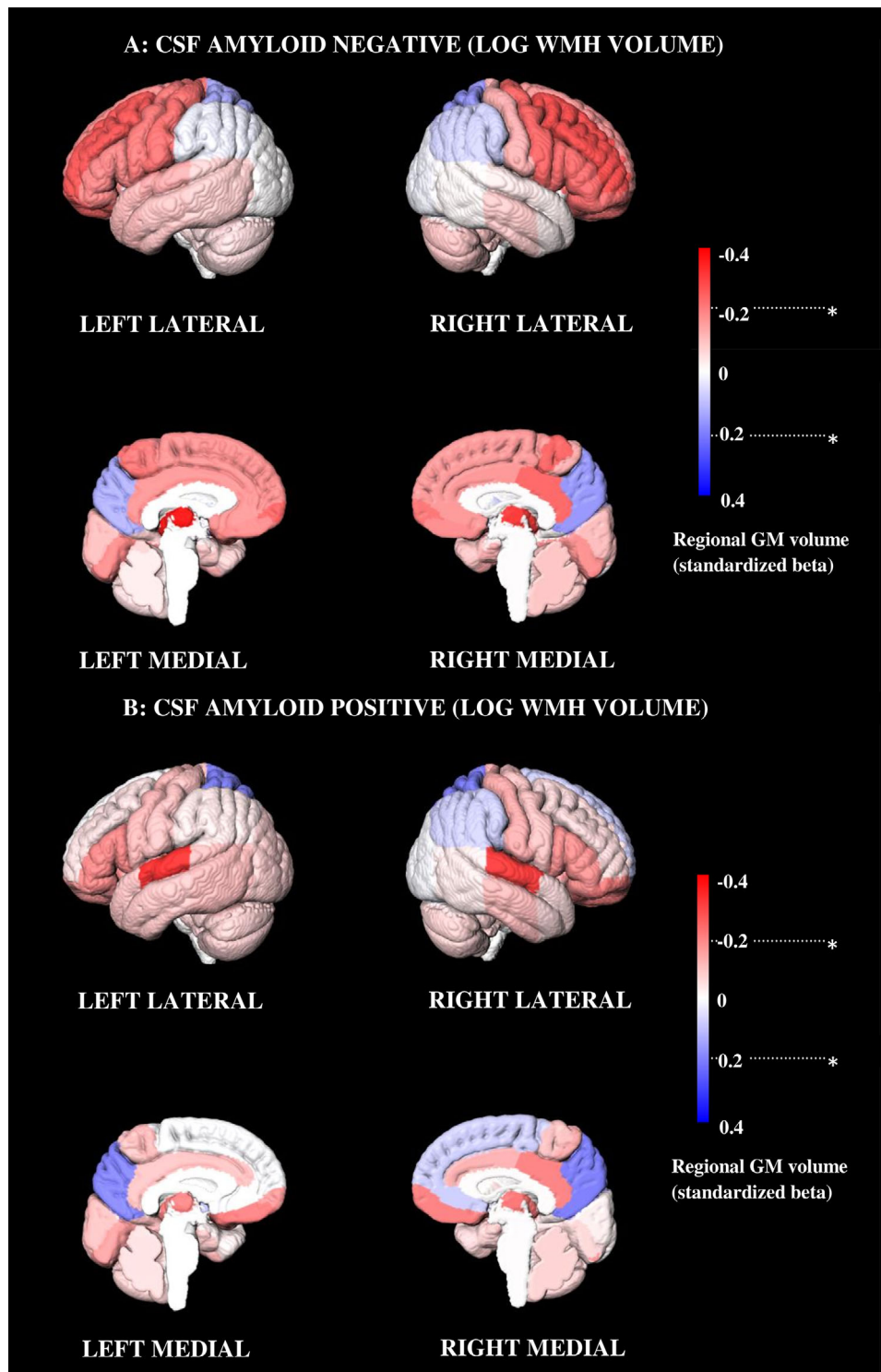


FIGURE 4 Regional brain volume analysis in cerebrospinal fluid (CSF) subgroup. Effect size map showing the relation between log white matter hyperintensity (WMH) volume and regional gray matter (GM) volume using standardized beta coefficients (Red: GM volume smaller in patients with higher log WMH volume; blue: GM volume smaller in patients with lower log WMH volume). A, CSF amyloid-negative patients ($n = 261$); (B) CSF amyloid-positive patients ($n = 227$). The stratified analyses show that the effect is highly dependent on CSF amyloid status. While amyloid-positive patients have a lower GM volume than amyloid-negative patients, the association between higher log WMH volume and more GM atrophy was more pronounced in several brain regions for amyloid-negative patients only. * Bonferroni-corrected $P < .05$

4.4 | “Distant” effects of SVD

The exact mechanism by which SVD contributes to brain atrophy is not yet clear. It has been suggested SVD can lead to secondary degeneration: a process in which cortical GM atrophy occurs as a result of disconnection of WM tracts.^{33,36,40,45–47} This “disconnection phenomenon” has been demonstrated in patients with cerebral autosomal dominant arteriopathy with subcortical infarcts and leukoencephalopathy and ischemic stroke.^{47,48} The underlying cellular mechanisms behind this process are not clear yet.⁴⁹ Our results showed primarily subcortical lesions (WMHs and lacunes) were related with predominantly frontal cortical GM atrophy. This “distant” cortical atrophy in relation to these subcortical vascular lesions may indeed reflect secondary neurodegeneration through disconnection. The predominant involvement of frontal brain regions may be explained by increased susceptibility of axons in frontal regions to impaired cerebral perfusion and vascular injury, leading to partial frontal lobe disconnection.⁵⁰

4.5 | Strengths and limitations

Strengths of our study include the large sample size, and detailed information on brain volumes and all SVD lesion types. Furthermore, CSF was available in a substantial subset of patients, allowing us to assess the impact of SVD both in the absence and presence of biomarker evidence of concomitant amyloid pathology.

Some limitations need to be addressed. First, selection bias could play a role because patients were included at a tertiary memory clinic and not all patients underwent a lumbar puncture. Second, all patients in the present study had some degree of vascular brain injury (as this was part of the inclusion criteria for the TRACE-VCI study), which could have led to an underestimation of the observed effects. Nevertheless, there was a great variability in the burden of vascular brain injury, which should have allowed us to detect relevant effects. Fourth, we used multicenter MRI data from different scanners. However, we used a high-quality, semi-automatic segmentation pipeline (including lesion filling) and corrected for scanner effect in our analyses. Both amyloid-positive and -negative patients were scanned using the same variety of MRI scanners instead of a single (different) scanner for each subgroup. Therefore the differences found in these patients cannot be explained by a scanner effect. Finally, the cross-sectional design of the present study does not allow us to infer causality regarding SVD and brain atrophy.

5 | CONCLUSION

In this study, we demonstrate that different manifestations of SVD related differentially to brain atrophy in memory clinic patients. In particular WMHs and lacunes were related to brain atrophy, but mainly in the absence of concurrent amyloid pathology. Vice versa, the relation of AD pathological processes and brain atrophy is most evident when

the burden of SVD is low. These findings show that the most common types of brain pathologies in people attending a memory clinic, SVD and AD pathological processes contribute to atrophy, likely through different pathways.

ACKNOWLEDGMENTS

Members of the TRACE-VCI study group (in alphabetical order, per department):

University Medical Center Utrecht, Utrecht University, Utrecht, the Netherlands:

1) Department of Neurology: E. van den Berg, G.J. Biessels, J.M.F. Boomsma, L.G. Exalto, D.A. Ferro, C.J.M. Frijns, O.N. Groeneveld, R. Heinen, N.M. van Kalsbeek, J.H. Verwer;

2) Department of Radiology: J. de Bresser;

3) Image Sciences Institute: H.J. Kuijff;

4) Department of Geriatrics: M.E. Emmelot-Vonk, H.L. Koek.

Amsterdam UMC, Amsterdam, the Netherlands:

1) Alzheimer Center and Department of Neurology: M.R. Benedictus, J. Bremer, W.M. van der Flier, A.E. Leeuwis, J. Leijenaar, N.D. Prins, P. Scheltens, B.M. Tijms;

2) Department of Radiology and Nuclear Medicine: F. Barkhof, M.P. Wattjes;

3) Department of Clinical Chemistry: C.E. Teunissen;

4) Department of Medical Psychology: T. Koene.

Onze Lieve Vrouwe Gasthuis West, Amsterdam, the Netherlands:

1) Department of Neurology: J.M.F. Boomsma, H.C. Weinstein.

Hospital Diaconessenhuis, Zeist, the Netherlands:

M. Hamaker, R. Faaij, M. Pleizier, M. Prins, E. Vriens.

FUNDING

The TRACE-VCI study is supported by Vidi grant 91711384 and Vici grant 91816616 from ZonMw, the Netherlands, Organisation for Health Research to Geert Jan Biessels and Development and grant 2010T073 from the Dutch Heart Foundation to Geert Jan Biessels. Research of the Amsterdam UMC Alzheimer Center is part of the neurodegeneration research program of the Neuroscience Campus Amsterdam. The Amsterdam UMC Alzheimer Center is supported by Stichting Alzheimer Nederland and Stichting VUMC fonds. FB is supported by the NIHR UCLH biomedical research center.

CONFLICTS OF INTEREST

There are no conflicts of interest for any of the authors.

REFERENCES

1. Jokinen H, Lipsanen J, Schmidt R, et al. Brain atrophy accelerates cognitive decline in cerebral small vessel disease the LADIS study. *Neurology*. 2012;78:1785-1792.
2. Jack CR, Shiung MM, Weigand SD, et al. Brain atrophy rates predict subsequent clinical conversion in normal elderly and amnesic MCI. *Neurology*. 2005;65:1227-1231.
3. Wardlaw JM, Smith EE, Biessels GJ, et al. Neuroimaging standards for research into small vessel disease and its contribution to ageing and neurodegeneration. *Lancet Neurol*. 2013;12:822-838.
4. De Guio F, Duering M, Fazekas F, et al. Brain atrophy in cerebral small vessel diseases: extent, consequences, technical limitations

- and perspectives: the HARNESS initiative. *J Cereb Blood Flow Metab.* 2020;40(2):231-245.
5. Banerjee G, Jang H, Kim HJ, et al. Total MRI small vessel disease burden correlates with cognitive performance, cortical atrophy, and network measures in a memory clinic population. *J Alzheimer's Dis.* 2018;63:1485-1497.
 6. Pantoni L. Cerebral small vessel disease: from pathogenesis and clinical characteristics to therapeutic challenges. *Lancet Neurol.* 2010;9:689-701.
 7. Gouw AA, Seewann A, Van Der Flier WM, et al. Heterogeneity of small vessel disease: a systematic review of MRI and histopathology correlations. *J Neurol Neurosurg Psychiatry.* 2011;82:126-135.
 8. Toledo JB, Arnold SE, Raible K, et al. Contribution of cerebrovascular disease in autopsy confirmed neurodegenerative disease cases in the National Alzheimer's Coordinating Centre. *Brain.* 2013;136:2697-2706.
 9. Jack CR, Bennett DA, Blennow K, et al. NIA-AA Research Framework: toward a biological definition of Alzheimer's disease. *Alzheimer's Dement.* 2018;14:535-562.
 10. Peres R, De Guio F, Chabriat H, Jouvent E. Alterations of the cerebral cortex in sporadic small vessel disease: a systematic review of in vivo MRI data. *J Cereb Blood Flow Metab.* 2015;36:681-695.
 11. Fazekas F, Chawluk JB, Alavi A. MR signal abnormalities at 1.5 T in Alzheimer's dementia and normal aging. *Am J Neuroradiol.* 1987;8:421-426.
 12. Boomsma JMF, Exalto LG, Barkhof F, et al. Vascular cognitive impairment in a memory clinic population: rationale and design of the "Utrecht-Amsterdam clinical features and prognosis in vascular cognitive impairment" (TRACE-VCI) study. *JMIR Res Protoc.* 2017;6(4):e60.
 13. Heinen R, Steenwijk MD, Barkhof F, et al. Performance of five automated white matter hyperintensity segmentation methods in a multi-center dataset. *Sci Rep.* 2019;9(1):16742.
 14. Biesbroek JM, Weaver NA, Hilal S, et al. Impact of strategically located white matter hyperintensities on cognition in memory clinic patients with small vessel disease. *PLoS One.* 2016;11:e0166261. <https://doi.org/10.1371/journal.pone.0166261>.
 15. Kuijff HJ. Image processing techniques for quantification and assessment of brain MRI. *Diss Utr Univ.* 2013.
 16. Ritter F, Boskamp T, Homeyer A, et al. Medical image analysis. *IEEE Pulse.* 2011;2:60-70.
 17. Hammers A, Allom R, Koeppe MJ, et al. Three-dimensional maximum probability atlas of the human brain, with particular reference to the temporal lobe. *Hum Brain Mapp.* 2003;19:224-247.
 18. Gousias IS, Rueckert D, Heckemann RA, et al. Automatic segmentation of brain MRIs of 2-year-olds into 83 regions of interest. *Neuroimage.* 2008;40:672-684.
 19. Heckemann RA, Hajnal J V, Aljabar P, Rueckert D, Hammers A. Automatic anatomical brain MRI segmentation combining label propagation and decision fusion. *Neuroimage.* 2006;33:115-126.
 20. Heckemann RA, Keihaninejad S, Aljabar P, Rueckert D, Hajnal J V, Hammers A. Improving intersubject image registration using tissue-class information benefits robustness and accuracy of multi-atlas based anatomical segmentation. *Neuroimage.* 2010;51:221-227.
 21. Voevodskaya O. The effects of intracranial volume adjustment approaches on multiple regional MRI volumes in healthy aging and Alzheimer's disease. *Front Aging Neurosci.* 2014;6:264.
 22. Mulder C, Verwey NA, van der Flier WM, et al. Amyloid-beta(1-42), total tau, and phosphorylated tau as cerebrospinal fluid biomarkers for the diagnosis of Alzheimer disease. *Clin Chem.* 2010;56:248-253.
 23. Zwan M, van Harten A, Ossenkoppele R, et al. Concordance between cerebrospinal fluid biomarkers and [11C]PIB PET in a memory clinic cohort. *J Alzheimer's Dis.* 2014;41:801-807.
 24. Scutari M. Learning bayesian networks with the bnlearn R package. *J Stat Softw.* 2010;35:1-22.
 25. Duering M, Gesierich B, Seiler S, et al. Strategic white matter tracts for processing speed deficits in age-related small vessel disease. *Neurology.* 2014;82:1946-1950.
 26. Biesbroek JM, Leemans A, Den Bakker H, et al. Microstructure of strategic white matter tracts and cognition in memory clinic patients with vascular brain injury. *Dement Geriatr Cogn Disord.* 2018;44:268-282.
 27. Staals J, Booth T, Morris Z, et al. Total MRI load of cerebral small vessel disease and cognitive ability in older people. *Neurobiol Aging.* 2015;36:2806-2811.
 28. Lammie GA, Brannan F, Wardlaw JM. Incomplete lacunar infarction (type Ib lacunes). *Acta Neuropathol.* 1998;96:163-171.
 29. Shoamanesh A, Kwok CS, Benavente O. Cerebral microbleeds: histopathological correlation of neuroimaging. *Cerebrovasc Dis.* 2011;32:528-534.
 30. Van Veluw SJ, Biessels GJ, Klijn CJM, Rozemuller AJM. Heterogeneous histopathology of cortical microbleeds in cerebral amyloid angiopathy. *Neurology.* 2016;86:867-871.
 31. Ghaznawi R, Geerlings MI, Jaarsma-Coes MG, et al. The association between lacunes and white matter hyperintensity features on MRI: the SMART-MR study. *J Cereb Blood Flow Metab.* 2018;39(12):2486-2496.
 32. Reid AT, Van Norden AGW, De Laat KF, et al. Patterns of cortical degeneration in an elderly cohort with cerebral small vessel disease. *Hum Brain Mapp.* 2010;31:1983-1992.
 33. Tuladhar AM, Reid AT, Shumskaya E, et al. Relationship between white matter hyperintensities, cortical thickness, and cognition. *Stroke.* 2014;46:425-432.
 34. Lambert C, Sam Narean J, Benjamin P, Zeestraten E, Barrick TR, Markus HS. Characterising the grey matter correlates of leukoaraiosis in cerebral small vessel disease. *NeuroImage Clin.* 2015;9:194-205.
 35. Fein G, Di Sclafani V, Tanabe J, et al. Hippocampal and cortical atrophy predict dementia in subcortical ischemic vascular disease. *Neurology.* 2000;55:1626-1635.
 36. Du A-T, Schuff N, Chao LL, et al. White matter lesions are associated with cortical atrophy more than entorhinal and hippocampal atrophy. *Neurobiol Aging.* 2005;26:553-559.
 37. Smith EE, O'Donnell M, Dagenais G, et al. Early cerebral small vessel disease and brain volume, cognition, and gait. *Ann Neurol.* 2015;77:251-261.
 38. Kloppenborg RP, Nederkoorn PJ, Grool AM, et al. Cerebral small-vessel disease and progression of brain atrophy: the SMART-MR study. *Neurology.* 2012;79:2029-2036.
 39. Lambert C, Benjamin P, Zeestraten E, Lawrence AJ, Barrick TR, Markus HS. Longitudinal patterns of leukoaraiosis and brain atrophy in symptomatic small vessel disease. *Brain.* 2016;139:1136-1151.
 40. Appelman APA, Vincken KL, Van Der Graaf Y, et al. White matter lesions and lacunar infarcts are independently and differently associated with brain atrophy: the SMART-MR study. *Cerebrovasc Dis.* 2009;29:28-35.
 41. Koncz R, Sachdev PS. Are the brain's vascular and Alzheimer pathologies additive or interactive?. *Curr Opin Psychiatry.* 2018;31:147-152.
 42. Roseborough A, Ramirez J, Black SE, Edwards JD. Associations between amyloid β and white matter hyperintensities: a systematic review. *Alzheimer's Dement.* 2017;13:1154-1167.
 43. Barnes J, Carmichael OT, Leung KK, et al. Vascular and Alzheimer's disease markers independently predict brain atrophy rate in Alzheimer's disease neuroimaging initiative controls. *Neurobiol Aging.* 2013;34:1996-2002.
 44. Freeze WM, Jacobs HIL, Gronenschild EH, et al. White matter hyperintensities potentiate hippocampal volume reduction in nondemented older individuals with abnormal amyloid- β . *J Alzheimer's Dis.* 2016;55:333-342.

45. Seo SW, Ahn J, Yoon U, et al. Cortical thinning in vascular mild cognitive impairment and vascular dementia of subcortical type. *J Neuroimaging*. 2010;20:37-45.
46. Kim HJ, Im K, Kwon H, et al. Clinical effect of white matter network disruption related to amyloid and small vessel disease. *Neurology*. 2015;85:63-70.
47. Duering M, Righart R, Csanadi E, et al. Incident subcortical infarcts induce focal thinning in connected cortical regions. *Neurology*. 2012;79:2025-2028.
48. Duering M, Righart R, Wollenweber FA, Zietemann V, Gesierich B, Dichgans M. Acute infarcts cause focal thinning in remote cortex via degeneration of connecting fiber tracts. *Neurology*. 2015;84:1685-1692.
49. Siffrin V, Vogt J, Radbruch H, Nitsch R, Zipp F. Multiple sclerosis—candidate mechanisms underlying CNS atrophy. *Trends Neurosci*. 2010;33:202-210.
50. Craggs LJJ, Yamamoto Y, Ihara M, et al. White matter pathology and disconnection in the frontal lobe in cerebral autosomal dominant arteriopathy with subcortical infarcts and leukoencephalopathy (CADASIL). *Neuropathol Appl Neurobiol*. 2014;40(5):591-602.

SUPPORTING INFORMATION

Additional supporting information may be found online in the Supporting Information section at the end of the article.

How to cite this article: Heinen R, Groeneveld ON, Barkhof F, et al. Small vessel disease lesion type and brain atrophy: The role of co-occurring amyloid. *Alzheimer's Dement*. 2020;12:e12060. <https://doi.org/10.1002/dad2.12060>