


Article

Morphological and Morphometrical Aspects of the Auditory Ossicles in the European Badger (*Meles Meles*)

Cristian Martonos ¹, Alexandru Gudea ^{1,*}, Călin Lațiu ², Milos Blagojevic ³ and Florin Stan ¹

¹ Faculty of Veterinary Medicine, University of Agricultural Sciences and Veterinary Medicine Cluj-Napoca, Calea Mănăștur 3-5, 400372 Cluj-Napoca, Romania

² Faculty of Animal Breeding and Biotechnologies, University of Agricultural Sciences and Veterinary Medicine Cluj-Napoca, Calea Mănăștur 3-5, 400372 Cluj-Napoca, Romania

³ Faculty of Veterinary Medicine, University of Belgrade, 1 Studentski Trg, 11000 Belgrade, Serbia

* Correspondence: alexandru.gudea@usamvcluj.ro

Simple Summary: The little-described morphology of the ear ossicles in the badger provides some interesting morphological features alongside some metrical data. For the malleus, we notice the standard framing into the known shape, with the mentioned presence at the level of the column of all three processes (lateral, rostral and medial), from which the rostral one is the most developed. The malleal manubrium is long and triangularly shaped on a cross-section. For the incus we notice the overall shape of a biradicular molar with the existence of the two crura in acute angulation, while the long crus is continuing with the lenticular process. The presence of a bony blade that links to the lenticular process is also noted. For the stapes, the almost equal two crura and the quite round intercrural foramen is described.

Abstract: Given the scarce morphological data regarding the middle ear anatomy of this species, the paper attempts to describe the morphological and morphometrical data of the auditory ossicles in the badger. The study was performed using the standard morphological investigations and provides a complete morphological description of the ossicular assembly (malleus, incus and stapes) with some comparative features and attempts to provide a complete set of standardized metrical data for each ossicle. A more-detailed attempt to compare some functional aspects in the light of combined metrical ratios is also implied.

Keywords: middle ear; ear ossicles; badger; morphometry; malleus; incus; stapes



Citation: Martonos, C.; Gudea, A.; Lațiu, C.; Blagojevic, M.; Stan, F. Morphological and Morphometrical Aspects of the Auditory Ossicles in the European Badger (*Meles Meles*). *Vet. Sci.* **2022**, *9*, 483. <https://doi.org/10.3390/vetsci9090483>

Received: 4 August 2022

Accepted: 7 September 2022

Published: 8 September 2022

Publisher's Note: MDPI stays neutral with regard to jurisdictional claims in published maps and institutional affiliations.



Copyright: © 2022 by the authors. Licensee MDPI, Basel, Switzerland. This article is an open access article distributed under the terms and conditions of the Creative Commons Attribution (CC BY) license (<https://creativecommons.org/licenses/by/4.0/>).

1. Introduction

Taxonomically the badger belongs to Mammalia class, order Carnivora and the Mustelidae family [1].

Studies point to the existence of four subfamilies—Melinae, Mellivorinae, Taxidiinae and Hellictidinae within this larger family. The European badger is framed into the Melinae family, close to the hog badger (*Arctonyx collaris*), which is listed as a species in extinction. The Mellivorinae subfamily includes the melivore badger (*Mellivora capensis*), the Taxidiinae includes the American badger (*Taxidea taxus*) and the Hellictidinae includes three *Melogale species* [2].

According to literature sources, the Mustelidae family is the most representative, as far as the number of species is concerned, the family of the Carnivora order, including 67 species spread all over the world, except for Australia and Antarctica [3]. In Europe, the badger is spread over all areas, from forested regions to intensely urbanized areas [4,5]. In regards to their interaction with other species, the European badger is considered a reservoir for *Mycobacterium bovis* in the UK, Ireland, Spain and France [6] and they can play a role as a host for the *Trichinella* species [3] or *Thelazia callipaeda* [7].

The tympanic cavity is described as an air-filled osseous cavity carved into the temporal bone placed between the external ear and the internal ear [8,9]. Available studies on the ear of the badger focus mainly on the anatomy of the cavity of the middle ear and the appearance of the bulla tympanica or other cranial aspects related to its morphology [10].

The tympanic cavity or the middle ear (*Auris media*) is laterally delimited by the tympanic membrane to the oval window medially (*Fenestra vestibuli*). The auditory ossicles are related to this segment as they link the aforementioned parts in an articulated fashion, playing an important role in the transmission and modulation of soundwaves, as described by all morphology sources: the malleus, the incus and the stapes [8,9,11–13].

In most mammals, the auditory ossicles appear as individualized pieces, unlike some rodents where the malleus and incus is fused, forming an maleo-incal complex [8,12,14–17], as in some birds there is only one single bony piece described—*Collumela auris*—that is the equivalent of the stapes in mammals [11,18,19]. For carnivores, a relatively reduced number of species have been studied in this respect, such as the wolf [18], the dog [19,20], the cat and the fox [20,21].

The present study aims to provide a series of morphological and morphometrical data concerning the auditory ossicles in the badger (*Meles meles*) that might be helpful for researchers and clinicians. Some attention is paid to some mechanical and physical elements of the anatomy of the middle ear, specifically pointing at explanatory elements regarding the involvement and correlations of the metrical features of the ear ossicles to the specificity of sound transmission for this wild species, given the importance of this so-called “transitional type” of the ear, situated between the freely mobile and the malleus-incus microtype [22].

The data that support the findings of this study are available from the corresponding author, A.G, upon reasonable request.

2. Materials and Methods

The biological material was represented by 5 badger crania originating mainly from road casualties presented in our Emergency Clinic or Pathology Department. The cephalic extremities were subjected to a mechanical cleaning process, after a careful inspection of the temporal bone part, by means of a warm maceration procedure for 3–5 days. After another cleaning procedure, the tympanic bulla was assessed, and several fragmentation actions were performed for the removal of the auditory ossicles from the tympanic cavity. The pieces were carefully identified, cleaned, and assessed from a morphological and morphometrical perspective in the Anatomy Lab of the Faculty of Veterinary Medicine. Usual anatomical and surgical tools were used (tweezers, scalpel and bone rongeur). Digital images were collected (Olympos MTX stereomicroscope and camera) while images were further processed with a Wacom Intuos tablet, Corel Painter Essentials 5 suite. For the measurements of the ossicles, a scaled surface was placed under the specimens before image capturing. ImageJ was the software solution used for the measurements and further numerical processing.

Measurements on the auditory ossicles were made following data suggested by a series of authors [14,18,23–25], with some adaptations, as some of the reference points suggested by the available literature were not applicable to our specimens.

The following measurements were performed:

- LM—length of malleus
- WHM—width of head of malleus
- LhM—length of the handle of malleus
- Li—length of incus
- LSC—length of short crus of incus
- LLC—length of long crus of incus
- HBI—height of the body of incudis
- WBI—width of the body of incudis
- LS—length of stapes

- WHS—width of head of stapes
- WBS—width of base of stapes
- LCC—length of caudal crus of stapes
- LRC—length of rostral crus of stapes
- APd—antero-posterior diameter of obturator foramen of stapes
- DVd—dorso-ventral diameter of obturator foramen of stapes

Depending on the availability of measurements on the digitally collected images for our available biological samples, we tried to establish a minimum number of 6–10 measurements for each item, ensuring statistical representativity. Statistical interpretation was conducted using the basic statistical features of Google sheets formulas (counting, average and standard deviation).

3. Results

In the cavity of the middle ear, we identified the assembly of the auditory ossicles represented by the malleus (*Malleus*), incus (*Incus*) and the stapes (*Stapes*).

The most-developed piece is the malleus (Figures 1 and 2). Laterally placed, in contact with the tympanic membrane, it appears slightly curved piece that has three distinctive anatomical parts: the head of malleus (*Caput mallei*), the neck of malleus (*Collum mallei*) and the handle (*Manubrium mallei*).

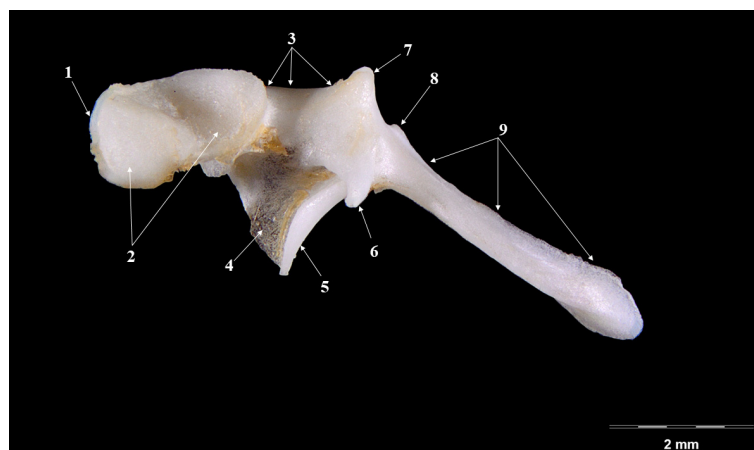


Figure 1. Malleus-Medial perspective. 1. Caput mallei; 2. Processus articularis; 3. Collum mallei; 4. Ossicular lamina; 5. Process rostral; 6. Processus muscularis; 7. Processus lateralis—the upper section; 8. Processus lateralis—the lower section; 9. Manubrium mallei.

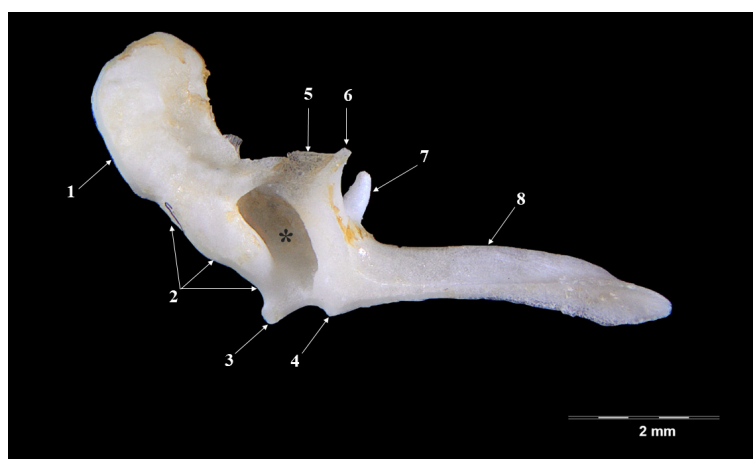


Figure 2. Malleus-lateral perspective. 1. Caput mallei; 2. Collum mallei; 3. Processus lateralis—upper segment; 4. Processus lateralis, lower segment; 5. Lamina; 6. Processus rostralis; 7. Processus muscularis; 8. Manubrium mallei; *—innominate fossa.

The head of malleus is slightly ovoidal in shape and it presents two parts—a lateral one (oval, slightly irregular as surface) and a medial one (with the articular surface for the incus). The articular incal surface with a medio-caudal orientation displays two portions: a dorsal and a ventral one, forming an obtuse angle.

The neck of the malleus continues in an oral-ventral direction to the head of the ossicle. This segment seems quite short, with a series of processes placed very closely, one to another. A rostral process (*Processus rostralis*), the most developed one, detaches from the oral-ventral part of the neck, and appears as an almost-cylindrical pointed bone piece linked to the ventral part of the neck by a fine osseous blade. The muscular process (*Processus muscularis*) is a long piece (Table 1) that detaches from the medio-caudal part of the neck. This process serves as insertion point for the tensor muscle of the tympanic membrane (*M. tensor tympani*). The lateral process (*Processus lateralis*) appears as two small tuberosities separated by a depression onto the dorsal part of the neck, close to the junction of the neck (*collum*) with the handle (*manubrium*).

Table 1. Metrical data for the auditory ossicles in the badger (*Meles meles*).

Measurement	Average Value (mm)	No of Measurements
Malleus		
LM	8.142 ± 0.14	9
LHM	2.264 ± 0.014	8
WHD (not to include the bony lamellae)	1.57 ± 0.06	7
LhM	4.854 ± 0.15	8
Incus		
LI	2.72 ± 0.12	5
LSC	1.995 ± 0.1	6
LLC	2.69 ± 0.21	8
HBI	1.48	3
WBI	2.075 ± 0.14	5
Stapes		
WBS	2.16	3
LCC	2.095 ± 0.2	5
LRC	1.95 ± 0.11	6
WHS	0.79 ± 0.13	6
LS	2.3 ± 0.08	7
Apd	0.91	2
DVd	0.81	2

The handle of malleus continues the neck as a ventral projection towards the tympanic membrane. It is an elongated (Table 1), triangular in transversal section piece, showing a lateral basal part and a tip medially. In its distal part, the manubrium becomes flattered and curves medio-laterally. An overall observation indicates a relatively reduced angulation for the manubrium and neck of the malleus, a fact that makes it comparable to the overall aspect of a hockey stick.

The incus (Figures 3 and 4), smaller than the malleus (Table 1), continues from the malleus and has the overall aspect of a biradicular molar. Onto its surface, a series of morphological segments can be described and identified: the body (*Corpus incudis*), the short crus (*Crus breve*) and the long crus (*Crus longum*).

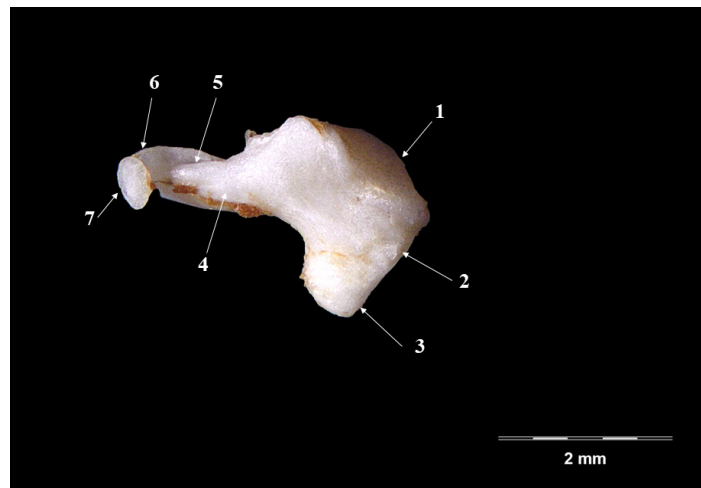


Figure 3. Incus-medial perspective. 1. Incundomallearis articular surface, 2. Corpus incundis; 3. Crus breve; 4. Crus longum; 5. Junction point- crus-blade; 6. Bony blade; 7. Processus lenticularis.

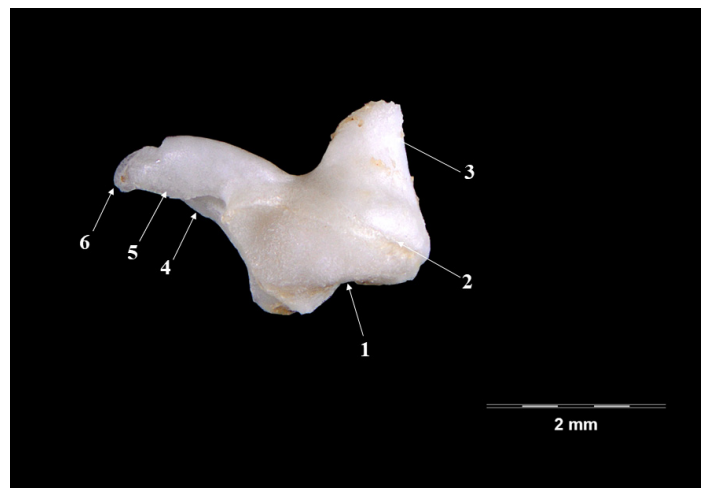


Figure 4. Incus-lateral perspective. 1. Incundomallearis articular surface; 2. Corpus incundis; 3. Crus breve; 4. Crus longum; 5. Bony blade; 6. Processus lenticularis.

The body of the incus appears as a well-developed piece, wider than long, with an evident articular malleal surface (*articulatio incundomallearis*) on its anterior extremity. From its caudal part, the two crura projects as slightly divergent processes, giving the extremity the shape of V letter. The short crus (*crus breve*), shorter and tronconic-shaped, continues to the dorsal margin of the ossicle in a dorso-caudal direction. The long crus, in a more-acute angle, continues to the ventral margin of the ossicle, with a long, pointed or effilated shape (see Table 1).

This terminal part of the process shows, in all investigated specimens, the presence of a quite well-individualized bony blade that continues with the so-called lenticulate process (*Processus lenticularis*). This piece ensures the junction with the third ossicle, the stapes. Based on the relatively good separation of this last part, we can state the fact that in this case, we can describe a really distinct lenticulate piece.

The stapes (Figure 5) is the smallest of the auditory ossicles (Table 1) placed between the lenticular piece and the oval window (*Fenestra vestibuli*). The overall shape of the ossicle is almost triangular, with an oblique, medio-caudal placement. The ossicle has a head (*Caput stapedis*), an rostral crus (*Crus rostrale*), a posterior crus (*Crus caudale*) and a base (*Basis stapedis*). The smallest of the parts is the head of the stapes. On its proximal part, the presence of the articular surface for the lenticulate piece is visible (*articulatio*

incundostapedialis) while not far from its caudal part another rough surface was visible—the insertion point for the stapedial muscle (*m.stapedius*).




Figure 5. Stapes-Ventral perspective. 1. Articulatio incundomallearis; 2. Caput stapedis; 3. Tuberositas *m.stapedius*; 4. Crus rostrale; 5. Crus caudale; 6. Intercrural foramen; 7. Basis stapedis; 8. Facies interna basis stapedis.

Distally, the ossicle continues with the two crura that link to the basal part (*Basis stapedis*). The rostral crus appear thinner and almost straight, while the caudal one is thicker at its base and slightly curved. The boundary of the almost circular intercrural orifice (*foramen intercrurale*) is the space between the two crura. The base of the stapes has an elliptical shape, with a quite accentuated convexity that fits the oval window (*fenestra vestibuli*).

4. Discussion

Otology studies rely greatly on animal models. One of the most-frequently used animal models is represented by small rodents but other mammalian species are often referred to as interesting species due to their resemblance with the ossicular assembly (functional and morphological) in primates and humans [25–30]. The middle ear, in its morphology, can be regarded as a pressure amplifier. The ossicular arrangement, its joints, ligaments and muscles do nothing but change the efficiency of the sound transmission [28,31–34] and generate a mechanical advantage, from the tympanic membrane to the oval window towards the cochlear system.

As in most mammals, the ossicular auditory assembly is comprised of the standard three sets of entities: the malleus, the incus and the stapes. In some exceptional cases, literature sources name the fourth ossicular component—the lenticular bone—as a separate, individualized bone piece [35–38] in some donkey, Indian mongoose and human individuals.

In some rodents, there is another peculiar situation that points to a certain physiological degree of fusion for the first two ossicles, forming the maleo-incal complex, such as in the Guinea pig [39,40], paca [16], degu [41], the hamster [12] or chinchilla [8,14]. In some other situations, the fusion of these ossicles (ossicular fixation) is cited as correlating with a loss of hearing, such as in humans and mice [42–44].

The overall shape of the head of the malleus in the badger (*Meles meles*) (Figures 1 and 2) seems similar to the description in other mammals [11,45]. In some caviomorph rodents, the head of malleus is described as “bullet-shaped” [41]. The neck of the malleus displays three processes: the rostral one, the lateral one and the muscular one. In the small Indian mongoose (*Herpetes Javanicus*), the muscular process, unlike some other carnivores, detaches from the internal margin of the handle of the malleus [36]. A well-developed muscular process is cited in donkeys, foxes and cats [20,22,23]. In badgers, the rostral process is the most-developed, similar to that of domestic goats and leporids [11,12], while for some

rodent species this process is very reduced or even absent [46]. The handle of the malleus (Table 1) in the badger has a triangular shape on a cross-section, similar to that reported in the goat. In other species, such as the buffalo, cow and sheep, this section is almost quadrilateral [13]. A special note is made for the small Indian mongoose, where the authors described at the base of the handle of malleus a visible transversal groove that supports the passage of the chorda tympany nervous branch [36].

The incus (Figures 3 and 4) in the badger has the well-known aspect of a biradicular molar [11,13,20]. The two divergent processes of the ossicle seem to be placed in a more acute angulation when compared with that described in the rabbit and the hamster [24], where these processes seem almost perpendicular to one another. As far as their size is concerned (Table 1), the long crus is much longer than the short one, which is similar to that described in other carnivores [36]. The relatively similar length of the two processes is cited in a series of small [11,47] or large ruminants [13].

The direct continuation of the long crus with the lenticulate process has been cited in many mammalian species. For the badger, the existence of a bony blade that links to the lenticulate piece to the articular surface with the incus makes the statement about the lenticular piece being an individualized piece quite valid. The same stands for the situation encountered in the case of the *Herpetes Javanicus* (small asian mongoose) or the cat [36,48] or even for some young mouse and hamster individuals or humans [8,39,40]. In contrast, the lack of this piece in the case of sheep fetuses has to be cited [45].

The anatomo-topographical disposition of the stapes (Figure 5) in the badger follows the literature data for many species. The triangular-trapezoidal overall shape of the piece has been cited in the wolf [18], domestic goat [11], guinea pig [49], chinchilla [50] and the hamster [51]. Different morphological aspects were cited in some ruminant species, where the incus is framed into a rectangular shape [11,13,20,47] or an irregular round shape (as in the rat [49]). The presence of the insertion surface for the stapedia muscle has been noted in humans [52,53] and sheep fetuses [45], while in other species, only a small tubercle is mentioned, such as in the wolf [18], dog [19], or the buffalo [13]. The overall length for the two processes of the stapes seems equal (Table 1), similar to the one described in swine [45,54], camels and donkeys [35]. The intercrural foramen maintains the overall round shape, while in the chinchilla, this space is more elliptic due to its longer diameter.

One of the most-frequent relations established for the theories of sound transmission in many studies is the isometric relationship between the eardrum area (tympanic area) and the oval window area (A1:A2 ratio) and the ratios of the malleus and incus, mainly the lever arm lengths I1 and I2 for the malleus and incus that are important in the transformer ratios of the middle ear [20,55]. The malleus and the incus can be regarded as a type 1 lever that has a counter-clock rotational movement as the tympanic membrane moves inward, pressing then against the internal crus of the stapes onto the oval window, with a cited ratio up to 19:1 effective tympanum to oval window [33,56–58]. Overall, the middle ear seems to play a highly complex role in sound modulation, dependent not only on these aforementioned factors, the air volumes, stiffness of the tympanic membrane and ossicular system alongside some other non-ossicular sound conduction influences being other secondary factors that make the understanding of the phenomena even more complex [58].

In this perspective, a slightly simpler comparison of the main metrical data for the ossicular assembly (as part of the main transmission system) of the some of the available metrical data pointing to middle ear ossicles can be easily illustrative for the adaptative changes in ear morphology, but not minimizing the importance of the other physical properties mentioned earlier.

This series of ratios were calculated based on the available literature data [20,22,25] between different lengths of the ossicular assembly in carnivores, ruminants and non-ruminants and some rodents [8,11,20,50,51,55,59].

The simple graphical representations (Figure 6) point to some expected morphological aspects: the overall dimensions for such differently sized species places the large species

in the most upper part of the graph (horse). On the other hand, in the upper and middle registry, the dimensions for humans alongside the ones for small ruminants seems to be somehow grouped, while the small-sized species (the rodents) occupy the lower registry of the graph. When the graph (Figure 7) takes into consideration the index calculated as fractions of the angle length vs. the overall length of the malleus, one can see the placement of the carnivores in the lowest part of the graph, with the data from humans and some rodents in the uppermost part of the registry. Once the same ratio of the main malleal dimensions are represented as a bar chart, based on the value represented by the proportion of the length of the manubrium from the greatest length of the malleus, an interesting placement appears (Figure 8).

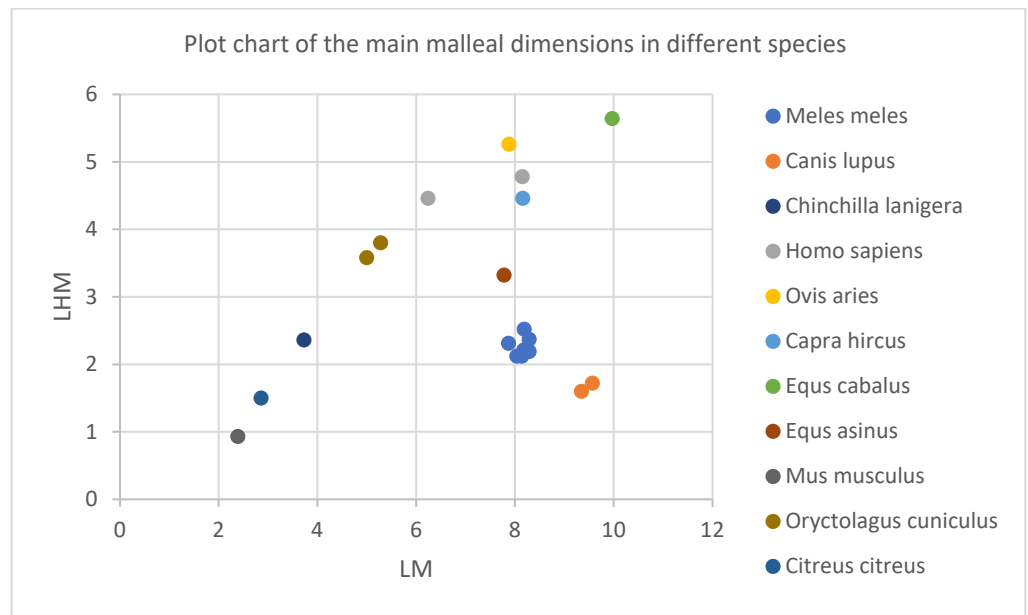


Figure 6. Graphical representation of the malleal ratios for different species.

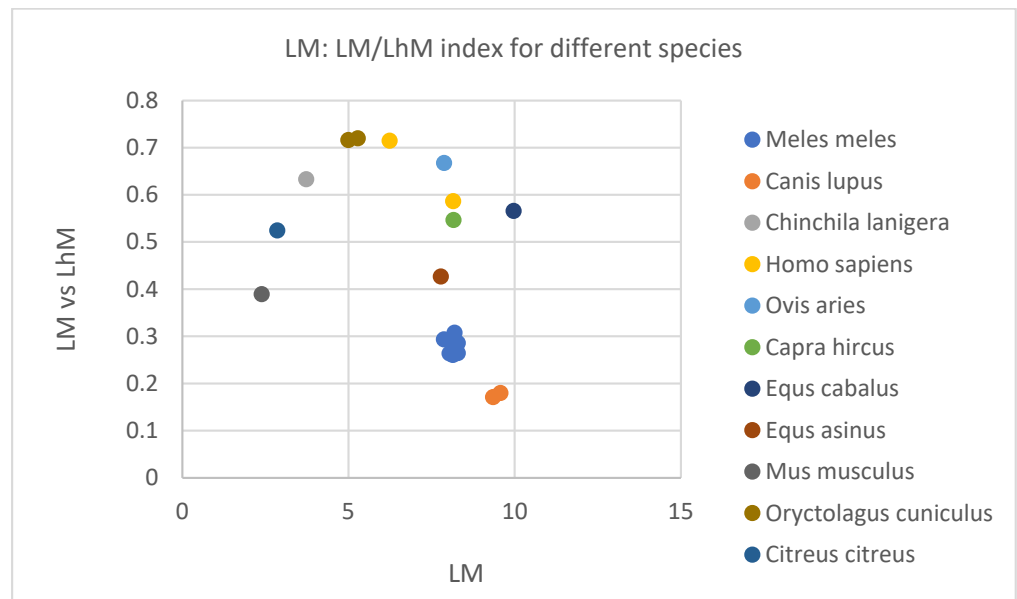


Figure 7. Graphical representation of the malleal length vs. the index calculated as a fraction of LM from LhM for different species.

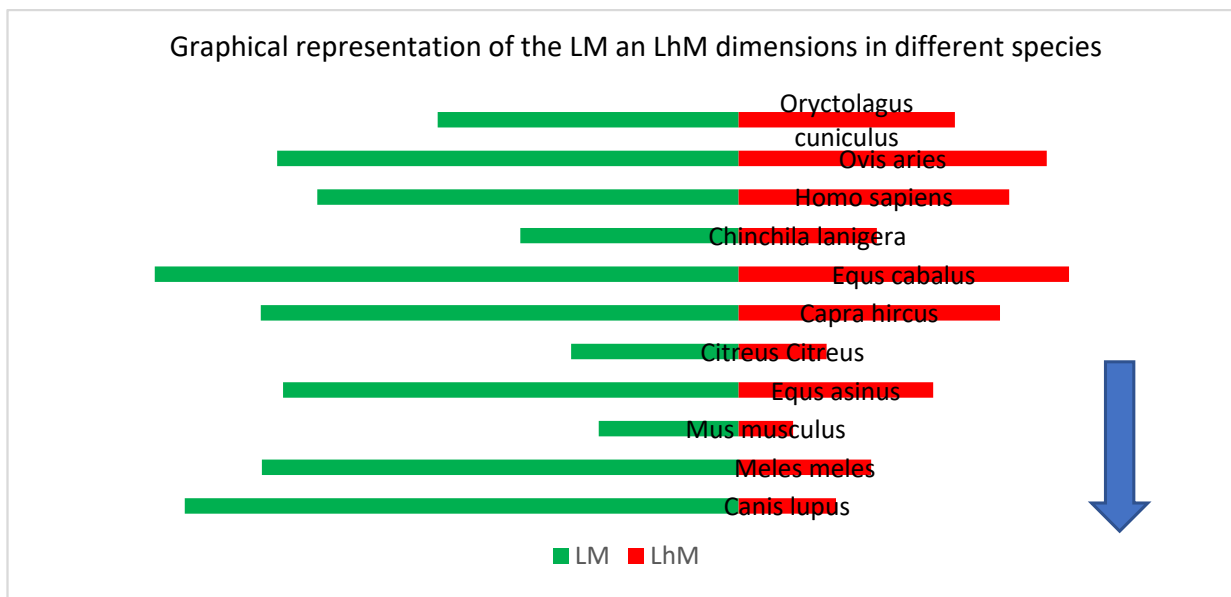


Figure 8. Representation of the malleal proportions in order of the LM:LhM ratio (descending).

This representation places on the upper part of the chart values for the malleus of some rodents along with those of humans, small ruminants and equids, while the ones from carnivores (wolf and badger) are placed in the lower part of this chart. Such a situation may suggest some kind of correlation with the facts linked to the frequency ranges that are associated with different species’ audible spectrum [60] that points to a higher frequency for mice (up to 91,000 Hz), carnivores (up to 64,000 Hz) and much lower ones for ruminants (sheep) or non-ruminants (horse) (up to 30,000 Hz) or even chinchillas and humans (20,000–22,000 Hz).

The widely used ratio of malleus:incus length ratio for the same series of species (Figure 9) reveals another interesting situation.

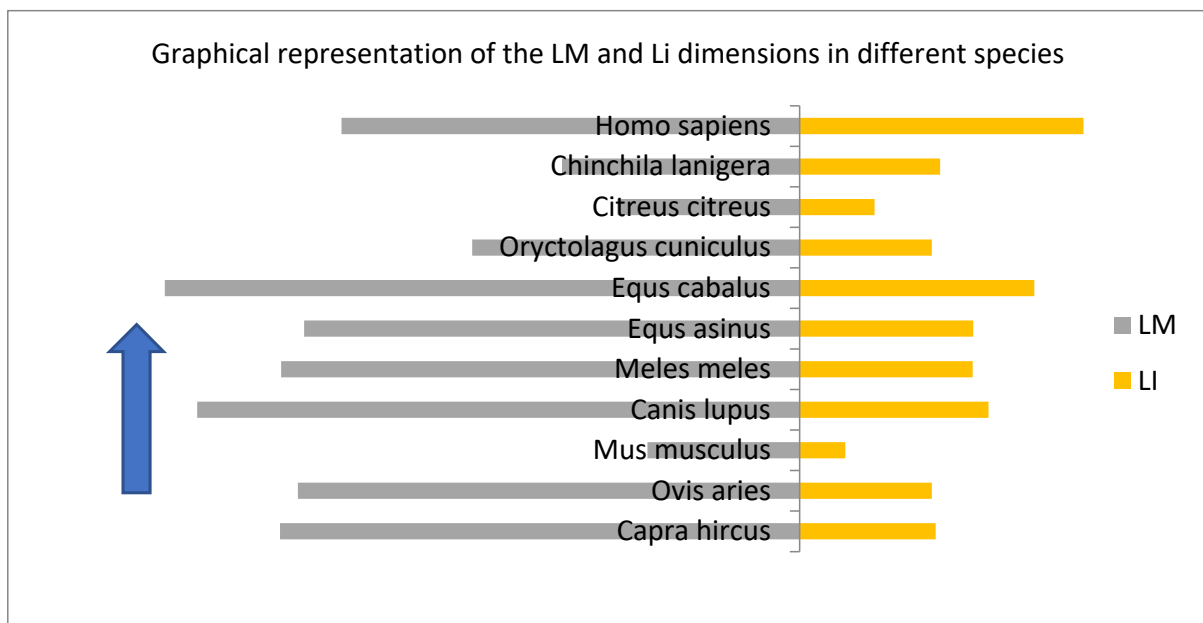


Figure 9. Representation of the malleus:incus proportions (ascending).

One can state a series of similar figures for all species (Table 2) for the proportions of the malleus (ratio lever:malleus), while for the calculations that imply incus dimensions, figures

for humans stand aside from those calculated in carnivores (ratio malleus:incus). Similar asymmetry can be observed in case of ratios malleus:stapes and the short crural length vs. the stapes dimensions, where the humans seem to have another value, slightly different to the ones of carnivores. These data may serve again as a differential adaptative difference among those species, with a direct connection to physiological adaptative changes related to environmental factors and evolution.

Table 2. Comparison of combined numerical data for the badger, wolf and humans.

	<i>Meles meles</i>	<i>Canis lupus</i>	<i>Homo sapiens</i>	<i>Ovis aries</i>	<i>Capra hircus</i>
Ratio lever/malleus	1:0.59	1:0.74	1:0.586	1:0.667	1:0.5465
Ratio maleus/incus	1:0.334	1:0.309	1:0.662	1:0.305	1:0.262
Ratio maleus/stapes	1:0.278	1:0.272	1:0.402		
Ratio L lc/H stapes	1:1.18	1:1.07	1:1.6		

5. Conclusions

The present study, to the best of our knowledge, brings into light some new elements of the middle ear anatomy, with respect to the ossicular anatomy, for a species relatively little-studied. This is the main purpose of the study—the complete morphological description of the ear ossicles in the badger, alongside some morphometrical data. These, combined with some graphical elements, are meant to serve as a useful didactical tool in the study of the comparative morphology of the middle ear and to point to some new directions in this study.

Author Contributions: Conceptualization, C.M. and A.G.; methodology, C.M. and A.G.; software A.G. and C.L.; validation, C.M., A.G., M.B. and F.S.; formal analysis, C.M., A.G. and F.S.; investigation, C.M. and A.G.; resources, C.M., M.B. and A.G.; data curation, A.G.; writing—original draft preparation, A.G. and C.M.; writing—review and editing, A.G., C.M. and F.S.; visualization, C.M., A.G., M.B. and F.S.; supervision, C.M. and A.G.; project administration, A.G.; funding acquisition, C.M. and A.G. All authors have read and agreed to the published version of the manuscript.

Funding: The publication was supported by funds from the National Research Development Projects to finance excellence (PFE)-14 (ID 546) granted by the Romanian Ministry of Research, Innovation and Digitalization.

Institutional Review Board Statement: This study was performed in line with the principles of the Declaration of Helsinki. It was approved by the Committee of Bioethics and Research Ethics from the University of Agricultural Sciences and Veterinary Medicine Cluj-Napoca, Romania (188/04.12.2019).

Informed Consent Statement: This study did not involve human subjects or usage of biological material from humans. As the biological material was represented by game specimens placed in an osteological collection, consent from the owner was not necessary.

Data Availability Statement: Not applicable.

Conflicts of Interest: The authors declare no conflict of interest.

References

1. Sapundzhiev, E.; Chervenkov, M.; Hristakiev, L. Histological Gastric Structure of Badger (*Meles meles*). *Pathol. Anthropol. Museum Bulg. Anat. Soc. Acta Morphol. Anthropol.* **2019**, *26*, 3–4.
2. Rose, J.; Moore, A.; Russell, A.; Butcher, M. Functional osteology of the forelimb digging apparatus of badgers. *J. Mammal.* **2014**, *95*, 543–558. [[CrossRef](#)]
3. Boros, Z.; Ionică, A.M.; Deak, G.; Mihalca, A.D.; Chisamera, G.B.; Györke, A.; Gherman, C.M.; Cozma, V. The European badger, *Meles meles*, as a new host for *Trichinella britovi* in Romania. *Vet. Parasitol.* **2020**, *288*, 109301. [[CrossRef](#)] [[PubMed](#)]
4. Mysłajek, R.W.; Nowak, S.; Rožen, A.; Kurek, K.; Figura, M.; Jędrzejewska, B. Ecology of the European badger (*Meles meles*) in the Western Carpathian mountains: A review. *Wildl. Biol. Pract.* **2016**, *12*, 36–50. [[CrossRef](#)]
5. Biancardi, C.M.; Marassi, M. Use of Eurasian badger (*Meles meles*) setts and latrines in an area of the Italian Prealps (Lombardy, Italy). *Small Carniv. Conserv.* **2002**, *26*, 17–19.

6. George, S.C.; Smith, T.E.; Mac Cana, P.S.S.; Coleman, R.; Montgomery, W.I. Physiological stress in the Eurasian badger (*Meles meles*): Effects of host, disease and environment. *Gen. Comp. Endocrinol.* **2014**, *200*, 54–60. [[CrossRef](#)]
7. Ionică, A.M.; Deak, G.; D'Amico, G.; Stan, G.F.; Chieamera, G.B.; Constantinescu, I.C.; Adam, C.; Lefkaditis, M.; Gherman, C.M.; Mihalca, A.D. *Thelazia callipaeda* in mustelids from Romania with the European badger, *Meles meles*, as a new host for this parasite. *Parasit. Vectors* **2019**, *12*, 370. [[CrossRef](#)]
8. Martonos, C.; Damian, A.; Gudea, A.I.; Bud, I.; Stan, G.F. Morphological and morphometrical study of the auditory ossicles in chinchilla. *J. Vet. Med. Ser. C Anat. Histol. Embryol.* **2019**, *48*, 340–345. [[CrossRef](#)]
9. Barone, R. *Anatomie Comparée des Mammifères Domestiques, Tome 1, Ostéologie, 3rd ed.*; Vigot: Paris, France, 1966; ISBN 9782711404100.
10. Rozen-Rechels, D.; Peigné, S.; Germain, D.; Ladevèze, S. Intraspecific Morphological Variation of the Middle Ear in the European Badger, *Meles meles* (Carnivora: Mustelidae). *Biol. J. Linn. Soc.* **2016**, *119*, 106–116. [[CrossRef](#)]
11. Martonos, C.; Gudea, A.; Damian, A.; Lăcătuș, R.; Purdoi, R.; Cocan, D.; Stan, F.G. Morphological and morphometrical aspects of the auditory ossicles in goat (*Capra hircus*). *J. Vet. Med. Ser. C Anat. Histol. Embryol.* **2021**, *50*, 184–191. [[CrossRef](#)]
12. Guan, M.; Zhang, J.; Jia, Y.; Cao, X.; Lou, X.; Li, Y.; Gao, X. Middle ear structure and transcanal approach appropriate for middle ear surgery in rabbits. *Exp. Ther. Med.* **2019**, *17*, 1248–1255. [[CrossRef](#)] [[PubMed](#)]
13. Nourinezhad, J.; Abedini, M.; Shamsi, M.M.; Dabbaghi, A.; Janeczek, M. Evaluation of the middle ear in water buffaloes (*Bubalus bubalis*) by gross anatomy and cone-beam computed tomography. *Folia Morphol. (Warsz)*. **2021**, *80*, 177–185. [[CrossRef](#)] [[PubMed](#)]
14. Wang, X.; Gan, R.Z. 3D finite element model of the chinchilla ear for characterizing middle ear functions. *Biomech. Model. Mechanobiol.* **2016**, *15*, 1263–1277. [[CrossRef](#)] [[PubMed](#)]
15. Carrasco, M.L.; Maass O, J.C.; Dentone S, L.; Miranda G, G.; Kukuljan P, M. Estudio morfológico del oído medio e interno de la Chinchilla laniger. *Rev. Otorrinolaringol. y Cirugía Cabeza y Cuello* **2008**, *68*, 263–274. [[CrossRef](#)]
16. Martins, L.L.; Almeida-Silva, I.; Rossato, M.; Murashima, A.A.B.; Hyppolito, M.A.; Machado, M.R.F. Macroscopic description of the external and middle ear of paca (*Cuniculus paca* Linnaeus, 1766). *Pesqui. Vet. Bras.* **2015**, *35*, 583–589. [[CrossRef](#)]
17. Mason, M.J. Structure and function of the mammalian middle ear. II: Inferring function from structure. *J. Anat.* **2016**, *228*, 300–312. [[CrossRef](#)]
18. Gürbüz, İ.; Demiraslan, Y.; Orhun Dayan, M.; Aslan, K. Morphometric and macroanatomic examination of auditory ossicles in male wolves (*Canis lupus*). *Folia Morphol.* **2019**, *78*, 600–605. [[CrossRef](#)]
19. Berghes, C.; Parvu, M.; Cucoanes, M.; Cuca, D. Anatomic Considerations on the Middle Ear in Dog. *Sci. Pap. Anim. Sci. Biotechnol.* **2010**, *43*, 450–452.
20. Malkemper, E.P.; Mason, M.J.; Burda, H. Functional anatomy of the middle and inner ears of the red fox, in comparison to domestic dogs and cats. *J. Anat.* **2020**, *236*, 980. [[CrossRef](#)]
21. Girgis, I.H.; Maurice, M. The ossicular system of cats. *J. Laryngol. Otol.* **1982**, *96*, 195–204. [[CrossRef](#)]
22. Péus, D.; Dobrev, I.; Pfiffner, F.; Sim, J.H. Comparison of sheep and human middle-ear ossicles: Anatomy and inertial properties. *J. Comp. Physiol. A* **2020**, *206*, 683–700. [[CrossRef](#)] [[PubMed](#)]
23. Vrettakos, P.A.; Dear, S.P.; Saunders, J.C. Middle Ear Structure in the Chinchilla: A Quantitative Study. *Am. J. Otolaryngol.* **1988**, *9*, 58–67. [[CrossRef](#)]
24. Kurtul, I.; Cevik, A.; Bozkurt, E.U.; Dursun, N. A detailed subgross morphometric study on the auditory ossicles of the New Zealand rabbit. *J. Vet. Med. Ser. C Anat. Histol. Embryol.* **2003**, *32*, 249–252. [[CrossRef](#)] [[PubMed](#)]
25. Arensburg, B.; Harell, M.; Nathan, H. The human middle ear ossicles: Morphometry, and taxonomic implications. *J. Hum. Evol.* **1981**, *10*, 199–205. [[CrossRef](#)]
26. Uziel, A.; Marot, M.; Pujol, R. The Gunn Rat: An Experimental Model for Central Deafness. *Acta Oto-Laryngol.* **2009**, *95*, 651–656. [[CrossRef](#)]
27. Pujol, R. Imaging the cochlea: Milestones of the last decades. *Audiol. Med.* **2010**, *8*, 45–49. [[CrossRef](#)]
28. Mason, M.J.; Farr, M.R.B. Flexibility within the middle ears of vertebrates. *J. Laryngol. Otol.* **2013**, *127*, 2–14. [[CrossRef](#)]
29. Harvey, R. A Review of Recent Developments in Veterinary Otology. *Vet. Sci.* **2022**, *9*, 161. [[CrossRef](#)]
30. Chen, H.; Okumura, T.; Emura, S.; Shoumura, S. Scanning electron microscopic study of the human auditory ossicles. *Ann. Anat.-Anat. Anzeiger* **2008**, *190*, 53–58. [[CrossRef](#)]
31. Chhan, D.; Bowers, P.; McKinnon, M.L.; Rosowski, J.J. Middle-ear and inner-ear contribution to bone conduction in chinchilla: The development of Carhart's notch. *Hear. Res.* **2016**, *340*, 144–152. [[CrossRef](#)]
32. Huttenbrink, K.B. The mechanics and the function of the middle-ear. Part 1: Normal ossicular chain and middle-ear muscles. *Laryngorhinootologie* **1992**, *71*, 545–551. [[PubMed](#)]
33. Guelke, R.; Keen, J.A. A study of the movements of the auditory ossicles under stroboscopic illumination. *J. Physiol.* **1952**, *116*, 175. [[CrossRef](#)] [[PubMed](#)]
34. Fleischer, G. Evolutionary principles of the mammalian middle ear. *Adv. Anat. Embryol. Cell Biol.* **1978**, *55*, 7–50. [[CrossRef](#)]
35. Nazih, A.M. Anatomical Study on the Middle Ear of Donkey (*Equus acinus*). *Int. J. Adv. Res. Biol. Sci.* **2017**, *4*, 110–121. [[CrossRef](#)]
36. Kamali, Y.; Gholami, S.; Ahrari-Khafi, M.S.; Rasouli, B.; Shayegh, H. The architecture of the middle ear in the small Indian mongoose (*Herpestes javanicus*). *Folia Morphol.* **2015**, *74*, 340–345. [[CrossRef](#)] [[PubMed](#)]
37. Graboyes, E.M.; Hullar, T.E.; Chole, R.A. The Lenticular Process of the Incus. *Otol. Neurotol.* **2011**, *32*, 1600. [[CrossRef](#)]
38. Chien, W.; Northrop, C.; Levine, S.; Pilch, B.Z.; Peake, W.T.; Rosowski, J.J.; Merchant, S.N. Anatomy of the distal incus in humans. *JARO-J. Assoc. Res. Otolaryngol.* **2009**, *10*, 485–496. [[CrossRef](#)]

39. Bellmer, E.H. The Time of Embryonic Fusion of the Malleus and Incus of the Guinea Pig. *Am. Midl. Nat.* **1963**, *69*, 426. [[CrossRef](#)]
40. Sim, J.H.; Rööösl, C.; Chatzimichalis, M.; Eiber, A.; Huber, A.M. Characterization of Stapes Anatomy: Investigation of Human and Guinea Pig. *JARO J. Assoc. Res. Otolaryngol.* **2013**, *14*, 159. [[CrossRef](#)]
41. Argyle, E.C.; Mason, M.J. Middle Ear Structures of *Octodon degus* (Rodentia: Octodontidae), in Comparison with Those of Subterranean Caviomorphs. *J. Mammal.* **2008**, *89*, 1447–1455. [[CrossRef](#)]
42. Mukherjee, S.; Kesser, B.W.; Raghavan, P. The “Boomerang” Malleus-Incus Complex in Congenital Aural Atresia. *AJNR Am. J. Neuroradiol.* **2014**, *35*, 2181. [[CrossRef](#)] [[PubMed](#)]
43. Honeder, C.; Ahmadi, N.; Kramer, A.M.; Zhu, C.; Saidov, N.; Arnoldner, C. Cochlear implantation in the Guinea pig. *J. Vis. Exp.* **2018**, *2018*, 56829. [[CrossRef](#)] [[PubMed](#)]
44. Motegi, M.; Yamamoto, Y.; Akutsu, T.; Tada, T.; Kurihara, S.; Takahashi, M.; Sampei, S.; Morino, T.; Yamamoto, K.; Sakurai, Y.; et al. Radiological and Audiological Prediction for Ossicular Fixation in Chronic Otitis Media and Tympanic Membrane Perforation. *Otol. Neurotol.* **2022**, *43*, 80–89. [[CrossRef](#)]
45. Simaei, N.; Soltanilinejad, F.; Najafi, G.; Shalizer Jalali, A. Anatomical and Morphometrical Study of Middle Ear Ossicles in 2 to 3-Month-old Makouei Sheep Fetuses. *Vet. Res. Forum Int. Q. J.* **2017**, *8*, 237–241.
46. Kerber, L.; Sánchez-Villagra, M.R. Morphology of the Middle Ear Ossicles in the Rodent Perimys (Neopiblemidae) and a Comprehensive Anatomical and Morphometric Study of the Phylogenetic Transformations of these Structures in Caviomorphs. *J. Mamm. Evol.* **2019**, *26*, 407–422. [[CrossRef](#)]
47. Ayres Seibel, V.A.; Lavinsky, L.; Preto De Oliveira, J.A. Morphometric study of the external and middle ear anatomy in sheep: A possible model for ear experiments. *Clin. Anat.* **2006**, *19*, 503–509. [[CrossRef](#)]
48. Funnell, W.R.J.; Heng Siah, T.; McKee, M.D.; Daniel, S.J.; Decraemer, W.F. On the coupling between the incus and the stapes in the cat. *JARO—J. Assoc. Res. Otolaryngol.* **2005**, *6*, 9–18. [[CrossRef](#)]
49. Albuquerque, A.A.S.; Rossato, M.; De Oliveira, J.A.A.; Hyppolito, M.A. Conhecimento da anatomia da orelha de cobaias e ratos e sua aplicação na pesquisa otológica básica. *Braz. J. Otorhinolaryngol.* **2009**, *75*, 43–49. [[CrossRef](#)]
50. Martonos, C.O.; Gudea, A.I.; Damian, A.; Miclăuş, V.; Rus, V.; Stan, F.G. Some segmental morphological and morphometrical features of the intima and media of the aortic wall in *Chinchilla lanigera*. *Folia Morphol.* **2019**, *78*, 729–737. [[CrossRef](#)]
51. Mohammadpour, A.A. Morphology and Morphometrical Study of Hamster Middle Ear Bones. *Iran. J. Vet. Res.* **2011**, *12*, 121–126. [[CrossRef](#)]
52. Wadhwa, S.; Kaul, J.; Agarwal, A.K. Morphometric study of stapes and its clinical implications. *J. Anat. Soc. India* **2005**, *54*, 1–9.
53. Isaacson, G. Endoscopic Anatomy of the Pediatric Middle Ear. *Otolaryngol. Neck Surg.* **2014**, *150*, 6–15. [[CrossRef](#)] [[PubMed](#)]
54. Pracy, J.P.; White, A.; Mustafa, Y.; Smith, D.; Perry, M.E. The Comparative Anatomy of the Pig Middle Ear Cavity: A Model for Middle Ear Inflammation in the Human? *J. Anat.* **1998**, *192*, 359–368. [[CrossRef](#)] [[PubMed](#)]
55. Hemilä, S.; Nummela, S.; Reuter, T. What middle ear parameters tell about impedance matching and high frequency hearing. *Hear. Res.* **1995**, *85*, 31–44. [[CrossRef](#)]
56. Pujol, R. Anatomie et physiologie de la cochlée. *Arch. Physiol. Biochem.* **1989**, *97*, 51–78. [[CrossRef](#)]
57. Lynch, T.J.; Peake, W.T.; Rosowski, J.J. Measurements of the acoustic input impedance of cat ears: 10 Hz to 20 kHz. *J. Acoust. Soc. Am.* **1998**, *96*, 2184. [[CrossRef](#)]
58. Rosowski, J.J. Outer and Middle Ears. In *Springer Handbook of Auditory Research Vol 4*; Springer: New York, NY, USA, 1994; pp. 172–247.
59. Mohammadpour, A.A. Morphological study of auditory ossicles in the mouse. *J. Appl. Anim. Res.* **2010**, *37*, 269–271. [[CrossRef](#)]
60. Fay, R.R. *Hearing in Vertebrates: A Psychophysics Databook*; Hill-Fay Associates: Winnetka, IL, USA, 1988; ISBN 9780961855901.