

# Knemidocoptic Mange in Wild Golden Eagles, California, USA

Asli Mete, Nicole Stephenson, Krysta Rogers,  
Michelle G. Hawkins, Miranda Sadar,  
David Sanchez-Migallon Guzman,  
Douglas A. Bell, Kenneth S. Smallwood,  
Amy Wells, Jessica Shipman, and Janet Foley

During 2012–2013 in California, USA, 3 wild golden eagles were found with severe skin disease; 2 died. The cause was a rare mite, most closely related to *Knemidocoptes derooi* mites. Cautionary monitoring of eagle populations, habitats, and diseases is warranted.

**K**nemidocoptidae are mange mites that cause alopecia, acanthosis, hyperkeratosis, pruritus, feather damage, inappetence, and sometimes death in birds (1,2). Infestation is typically worse in older, injured, sick, stressed, or malnourished birds (3). Most reports describe *Knemidocoptes mutans* and *K. gallinae* mites as affecting gallinaceous birds and *K. pilae* and *K. jamaicensis* mites as affecting pet or exotic birds in captivity (1,2). Although rarely fatal, epizootics among wild birds have been described; most affected raptors have been in captivity or rehabilitation centers (2,4,5). We describe the pathology caused by a rare species of mange mite in 1 of 3 wild golden eagles (*Aquila chrysaetos*) during an outbreak of knemidocoptosis.

## The Cases

During December 2012, eagle 1 was found in Hollister, California, after being struck by a car. The 3.5-kg bird was admitted to the SPCA for Monterey County, Salinas, California; it was prostrate from head trauma and died overnight. Examination revealed feather loss and scabbing on the head, neck, legs, and near the cloaca; microscopic examination of a skin scraping revealed mites.

Author affiliations: California Animal Health and Food Safety Laboratory, Davis, California, USA (A. Mete); University of California, Davis (N. Stephenson, M.G. Hawkins, M. Sadar, D. Sanchez-Migallon Guzman, J. Foley); California Department of Fish and Wildlife, Rancho Cordova, California, USA (K. Rogers); East Bay Regional Park District, Oakland, California, USA (D.A. Bell); Researcher and Ecologist, Davis (K.S. Smallwood); Avian and Exotic Clinic of the Monterey Peninsula, Del Rey Oaks, California, USA (A. Wells); and SPCA for Monterey County, Salinas, California, USA (J. Shipman)

DOI: <http://dx.doi.org/10.3201/eid2010.140504>

During July 2013, eagle 2 was live-trapped in the Altamont Pass Wind Resource Area near Livermore, California. This subadult (6) female had skin lesions similar to those of eagle 1. After mites were detected, she received treatment at the Veterinary Medical Teaching Hospital, University of California, Davis, and underwent rehabilitation at the California Raptor Center. Skin scrapings with crusts were collected and stored at  $-20^{\circ}\text{C}$ .

During August 2013, eagle 3 was found grounded in King City, California, and admitted to the SPCA for Monterey County. This 2.7-kg subadult male exhibited severe dehydration, weak and raspy respiration, and poor quality feathers. Mites and lesions similar to those on eagles 1 and 2 were found. Because of a poor prognosis, eagle 3 was euthanized and the carcass was stored at  $-20^{\circ}\text{C}$ .

On August 15, 2013, a necropsy of eagle 3 was performed at the California Animal Health and Food Safety Laboratory System, Davis, California. The bird was thin and the skin of the head, neck, vent region, and legs (except feet) had rough, firm, thick, dry, scaly, gray-brown crusts (Figure 1, panel A). The skin thickness was up to 1 cm; the left eye and both ears were completely encrusted (Figure 1, panel B). Stereoscopy revealed white-to-transparent milium bosselations beneath and within severely thickened keratin and a few crawling mites (Figure 1, panel C). The liver had disseminated pinpoint pale foci; lungs were heavy, wet, and dark red. Ancillary tests included aerobic bacterial culture of liver, spleen, and lung tissue and real-time PCR for *Salmonella* spp. in intestinal contents, for avian influenza virus and avian paramyxovirus-1 on an oropharyngeal swab sample, and for West Nile virus in kidney tissue. The femur was screened for chronic lead exposure, and liver tissue was screened for selenium, lead, manganese, cadmium, copper, iron, zinc, molybdenum, arsenic, mercury, and anticoagulant rodenticides. Bacteria and viruses were not detected, and all toxicants were either not detected or within acceptable range (except 2.1 ppm lead in bone and 0.01 ppm brodifacoum in liver).

Organ samples were fixed in formalin, embedded in paraffin, sectioned, and stained with hematoxylin and eosin. Histopathologic examination revealed generalized loss of feather follicles and numerous intracorneal mites. The epidermis was diffusely scalloped and covered by dense orthokeratotic lamellae, which formed serially aligned pouches within the stratum corneum; pouches contained developing and adult mites and eggs, mostly stacked and forming a honeycomb appearance. Subjacent epidermis was atrophied; acanthotic septae and papillary projections were overlain by orthokeratotic spires separating pouches. Coccoid bacteria and plant fragments were often associated with crusts. Throughout the dermis, small perivascular to interstitial heterophilic and pleocellular infiltrates were present. Acute necrotizing foci stippled with karyorrhexis

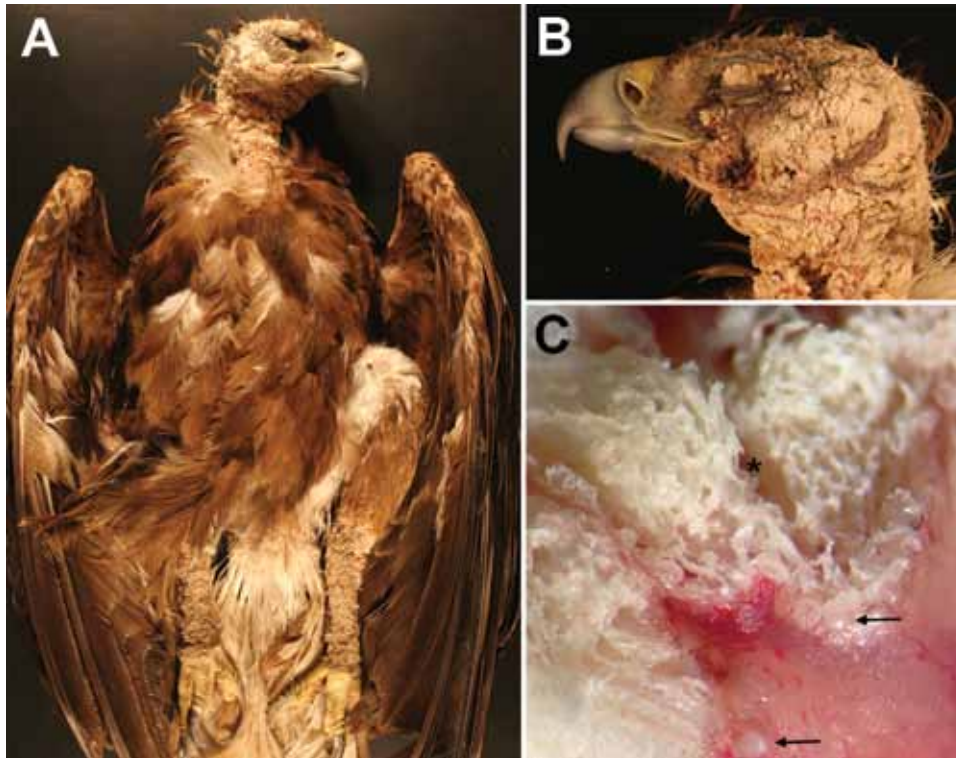


Figure 1. Golden eagle found grounded in King City, California, USA, during August 2013 (eagle 3). A) Photograph of diffuse crusting and thickening of the head, neck, and legs. B) Photograph showing severe obliteration of the skin over the eyelid and ear. C) Dissecting microscopic cross-section of the affected skin, showing thick trabeculae of keratin deposition (\*) and white to transparent mites (arrows). Original magnification  $\times$ .

and fibrin exudates and small plasmacytic infiltrates were found in myocardium, peripheral nerves and perineural tissues, liver, spleen, and lungs. Abundant protozoa were seen in lungs and heart; intense immunoreactivity to *Sarcocystis falcatula* protozoa was found in vessels, lungs, heart, and perineural tissues; occasional immunoreactivity was found in dermis and brain endothelium.

Frozen skin specimens from eagles 2 and 3 were submitted for parasite identification by electron microscopy and PCR. Mites were fixed with Karnovsky fixative in 0.1 mol/L Sorenson sodium phosphate buffer, washed with sodium phosphate, dehydrated in increasing ethanol to 100%, and dried in a Tousimis Research Corporation 931.GL Autosamdry Critical Point dryer (Rockville, MD, USA). The mites were mounted on aluminum stubs, sputter-coated with gold, and viewed on an FEI XL30 TMP scanning electron microscope (Eindhoven, the Netherlands). The mites closely resembled *K. derooi* mites on the basis of the dorsal striation pattern, relative size of the propodosoma, dorsoterminal location of the anus, and dorsal positioning of the anterior legs and ventral positioning of the posterior legs (Figure 2) (7).

DNA was extracted from 2 pools of 5–10 mites from eagles 2 and 3 by using a QIAGEN Tissue Kit (Valencia, CA, USA). Modified PCR amplification (8) of a fragment of the *cytochrome oxidase* subunit I gene included 12.5 mL of GoTaq Green Master Mix (Promega, Madison, WI, USA), 1.0 mol/L of each primer, 2.5 mL of water, and 5 mL

of DNA. Bands of 715 bp were cleaned with a QIAGEN gel extraction kit before DNA sequencing (Davis Sequencing, Davis, CA, USA). A BLAST search was conducted to match the DNA sequences with those in GenBank. Sequence homology was 100% between the pools from both eagles and 88% to *K. jamaicensis* (JQ037816.1), the only *Knemidocoptes* mite in the database. The GenBank accession number for the golden eagle mites is KJ787640.

## Conclusions

The severity and diffuse distribution of skin lesions of these eagles suggest a possible serious, unique outbreak. Most knemidocoptic mites affect the face and cere, or legs and feet (called scaly face and scaly leg mites) (1,2). With such severe feather loss and crusting over the eyes and ears, irritation and limited thermoregulation probably decreased the ability of these eagles to feed and exacerbated clinical disease. The morphologic features of the mites were consistent with those of *K. derooi* mites, a species rarely reported and, to our knowledge, not reported in North America or on raptors (7). Although raptors sometimes have skin mites, such debilitating disease in otherwise healthy animals is highly atypical (1–3). Disease or exposure to contaminants might induce immunosuppression or toxicosis. Eagle 3 showed evidence of prior exposure to lead; although use of lead bullets has been banned in some areas of California since 2008, ingestion of spent lead ammunition in hunter-killed carcasses or viscera remains a




Figure 2. Electron microscopic image of mite, showing features consistent with *Knemidocoptes derooi* mites.

threat to wildlife throughout much of the western United States (9). Brodifacoum, a second-generation anticoagulant rodenticide also identified in this eagle, has been found in golden eagles (10) and could induce sublethal effects and immunosuppression. The respiratory disease probably resulted from *S. falcatula* infection, which can produce fatal systemic disease in wild eagles (11).

The effects of environmental and climate change on bird–mite relationships might be a factor in the emergence of mange. Because *Knemidocoptes* spp. mites are transmitted by contact, stress induced by crowding, toxicosis, and concurrent pathogens might account for the severe disease among birds in close proximity, or these cases might reflect the emergence of a highly virulent mite (2,3). The density of golden eagles near the Altamont Pass Wind Resource Area is notably high (12), and this outbreak might reflect habitat changes bringing individuals into closer contact or increasing stress. Consistent multidisciplinary data collection is needed for identification of the mite's host species range, ecology, and pathogenicity and for enhanced understanding of this possibly emerging fatal disease.

#### Acknowledgments

We thank Terry Wildman, Pat Kysar, Joy Worth, Alan Mendoza, Juliette Dumazet, Robin Houston, and Stella McMillin for their contributions to this work; Brian Latta for his trapping expertise; and the US Fish and Wildlife Service and the California Department of Fish and Wildlife for trapping authorization.

Dr Mete is an assistant professor of veterinary pathology at the California Animal Health and Food Safety Laboratory, University of California, Davis. Her interests are spontaneous diseases with emphasis on avian pathology, and her research areas are iron storage disease in captive birds and diseases of backyard chickens.

#### References

- Dabert J, Mihalca AD, Sándor AD. The first report of *Knemidocoptes intermedius* Fain et Macfarlane, 1967 (Acari: Astigmata) in naturally infected European birds. *Parasitol Res*. 2011;109:237–40. <http://dx.doi.org/10.1007/s00436-011-2390-8>
- Pence D. Acariasis. In: Atkinson, CT, Thomas, NJ, Hunter D, editors. *Parasitic diseases of wild birds*. Ames (IA): Wiley-Blackwell; 2008. p. 527–36.
- Willette M, Ponder J, Cruz-Martinez L, Arent L, Bueno Padilla I, de Francisco ON, et al. Management of select bacterial and parasitic conditions of raptors. *Vet Clin North Am Exot Anim Pract*. 2009;12:491–517.
- Philips J. A review and checklist of the parasitic mites (Acarina) of Falconiformes and Strigiformes. *Journal of Raptor Research*. 2000;34:210–31.
- Miller DS, Taton-Allen GF, Campbell TW. *Knemidocoptes* in a Swainson's hawk, *Buteo swainsoni*. *J Zoo Wildl Med*. 2004;35:400–2. <http://dx.doi.org/10.1638/03-043>
- Bloom P, Clark W. Molt sequence of plumages of golden eagles and a technique for in-hand ageing. *North American Bird Bander*. 2002;6:97–116.
- Fain A. A new species of *Knemidocoptes* producing mange in the Palm-Swift. *Rev Zool Bot Afr*. 1970;81:220–4.
- Dabert J, Ehrnsberger R, Dabert M. *Glaucalgae tytonis* sp. n. (Analgidae, Xolalgidae) from the barn owl *Tyto alba* (Strigiformes, Tytonidae): compiling morphology with DNA barcode data for taxonomic descriptions in mites (Acari). *Zootaxa*. 2008;1719:41–52.
- Kelly TR, Bloom PH, Torres SG, Hernandez YZ, Poppenga RH, Boyce WM, et al. Impact of the California lead ammunition ban on reducing lead exposure in golden eagles and turkey vultures. *PLoS ONE*. 2011;6:e17656. <http://dx.doi.org/10.1371/journal.pone.0017656>
- Hosea R. Exposure of non-target wildlife to anticoagulant rodenticides in California. In: *Proceedings of the 19th Vertebrate Pest Conference*; 2000 Mar 6–9; San Diego, CA. 2000. p. 236–44.
- Wünschmann A, Rejmanek D, Conrad P, Hall N, Cruz-Martinez L, Vaughn SB, et al. Natural fatal *Sarcocystis falcatula* infections in free-ranging eagles in North America. *J Vet Diagn Invest*. 2010;22:282–9. <http://dx.doi.org/10.1177/104063871002200222>
- Hunt WG, Jackman RE, Brown TL, Gilardi JG, Driscoll DE, Culp L. A pilot golden eagle population study in the Altamont Pass Wind Resource Area, California. 1995 May [cited 2014 Jan 2]. <http://www.nrel.gov/wind/pdfs/7821.pdf>

Address for correspondence: Asli Mete, CAHFS, UC Davis, 620 West Health Sciences Dr, Davis CA 95616, USA; email: amete@ucdavis.edu

**EMERGING  
INFECTIOUS DISEASES®**

**Conference summaries and other  
reports available online**

<http://wwwnc.cdc.gov/eid/articles/conference-summaries/volume-20>