

Received: 2020.12.28  
Accepted: 2021.02.25  
Available online: 2021.03.02  
Published: 2021.03.13

# Mid-Term Outcomes of Cementless Total Hip Arthroplasty in Adult Patients with Childhood Hip Infection

Authors' Contribution:  
Study Design A  
Data Collection B  
Statistical Analysis C  
Data Interpretation D  
Manuscript Preparation E  
Literature Search F  
Funds Collection G

ABCDEF **Zhenhao Qian**  
ABG **Askar Mamtimin**  
ABD **Xiaogang Zhang**  
BDE **Boyong Xu**  
CEF **Wenbo Mu**  
ABDEG **Li Cao**

Department of Orthopedics, First Affiliated Hospital of Xinjiang Medical University, Urumqi, Xinjiang, P.R. China

**Corresponding Author:** Li Cao, e-mail: [xjbone@sina.com](mailto:xjbone@sina.com)  
**Source of support:** Departmental source

**Background:** Patients with hip joint infections in childhood often have many aftereffects of different degrees, regardless of the kind of treatment or natural course. Total hip arthroplasty is currently the most effective treatment for sequelae of childhood hip septic or tuberculous infection. This is a mid-term follow-up study of treatment results of patients who had undergone total hip arthroplasty (THA) with cementless prostheses.





**Material/Methods:** We retrospectively analyzed and followed 45 patients (45 hips) who underwent THA with cementless prostheses between 2010 and 2017. There were 45 patients, including 17 men and 28 women. The average age of the patients was 46 years (range, 18-67 years). All hip infections occurred in early childhood or adolescence, and the mean interval between initial infection and THA was 38.2 years (range, 15-60 years). The mean follow-up was 6.1 years (range, 2.7-9.5 years).

**Results:** Two patients underwent revision surgery because of loosening of the prosthesis, and 1 patient underwent revision surgery because of a new infection with no relationship with childhood infection during the follow-up. The average Harris hip scores significantly increased from 43.1 to 86.4 ( $P<0.01$ ), and the average visual analog scale significantly increased from 4.6 to 1.7 ( $P<0.01$ ). The hip dysfunction and osteoarthritis outcome scores were also significantly changed ( $P<0.01$ ) at the final follow-up. There were 2 cases of transient sciatic nerve palsy and intraoperative periprosthetic fractures in 3 cases. During follow-up, single revision was performed after 6 years of primary arthroplasty because of aseptic loosening in 2 cases and prosthesis infection in 1 case, which was not related to childhood pathogens.

**Conclusions:** THA for patients with sequelae of hip joint infection has a satisfactory effect that can effectively relieve joint pain and improve hip function. The recurrence rate of infection after either pyogenic infection or tuberculous is very low. The mid-term outcomes of THA in this setting were satisfactory, with high prosthesis survivorship and hip function scores.

**Keywords:** **Arthritis, Reactive • Arthroplasty, Replacement, Hip • Osteoarthritis, Hip**

Full-text PDF: <https://www.medscimonit.com/abstract/index/idArt/930760>

 2918  2  4  37



## Background

Infectious arthritis of the hip remains a common disease in children in developing countries, and the prevalence of common septic arthritis alone is 1: 20 000 [1]. Patients with hip joint infections in childhood or adolescence often experience sequelae of various degrees regardless of the kind of treatment or natural course [2]. Histopathologic changes include anatomical changes in soft tissue and bone, especially acetabular dysplasia, femoral canal deformity, unequal length of the legs, altered organs of neurovascular structures, and the possibility of reinfection [3]. Although the majority of these patients are young, they also have a long abnormal development period after the onset in childhood and adolescence, malformed joint structure development, severe soft-tissue contracture, shortening of the affected side resulting in an unequal length of the lower limbs, and low quality of life [4]. Therefore, total hip arthroplasty in such patients is challenging for orthopedic surgeons due to the high contracture of the skin and soft tissues, especially the abductor and adductor muscles. Weakness or even absence of abductor muscles may lead to unsatisfactory postoperative function. Preoperative soft-tissue contracture can be severe, and proximal femoral osteotomy would be more complex than in patients with developmental dysplasia of the hips. Patients have relatively high rates of intraoperative complications, including possible femoral fractures, neurovascular injuries, and reinfection [5]. Severe secondary contracture of soft tissue, acetabulum, and femur deformity need various soft tissue release and surgical exposure for these patients. Compared to the anterior approach, the posterior/posterior lateral approach can maximize the release of soft tissue around the joint, maximize the exposure of acetabulum and femur, and reduce intraoperative fracture risk. The major objectives of THA are improved function, pain relief, and reinfection prevention. The present study retrospectively analyzed the mid-term results after THA treatment in patients who had sequelae of childhood hip infection and, we propose a new classification concept of the sequelae of hip infection. THA plays a significant role in improving the quality of life in patients with hip disease. We also assessed the effectiveness of THA in the treatment of sequelae of childhood hip infection.

## Material and Method

### Patient Selection

We retrospectively studied 45 consecutive patients with sequelae of hip joint infection secondary to suppurative hip infection and tuberculous infection sequelae who underwent cementless total hip arthroplasty between December 2010 to October 2017 in the First Affiliated Hospital of Xinjiang Medical University (Table 1). These patients were selected based on

**Table 1.** Preoperative demographic and clinical data.

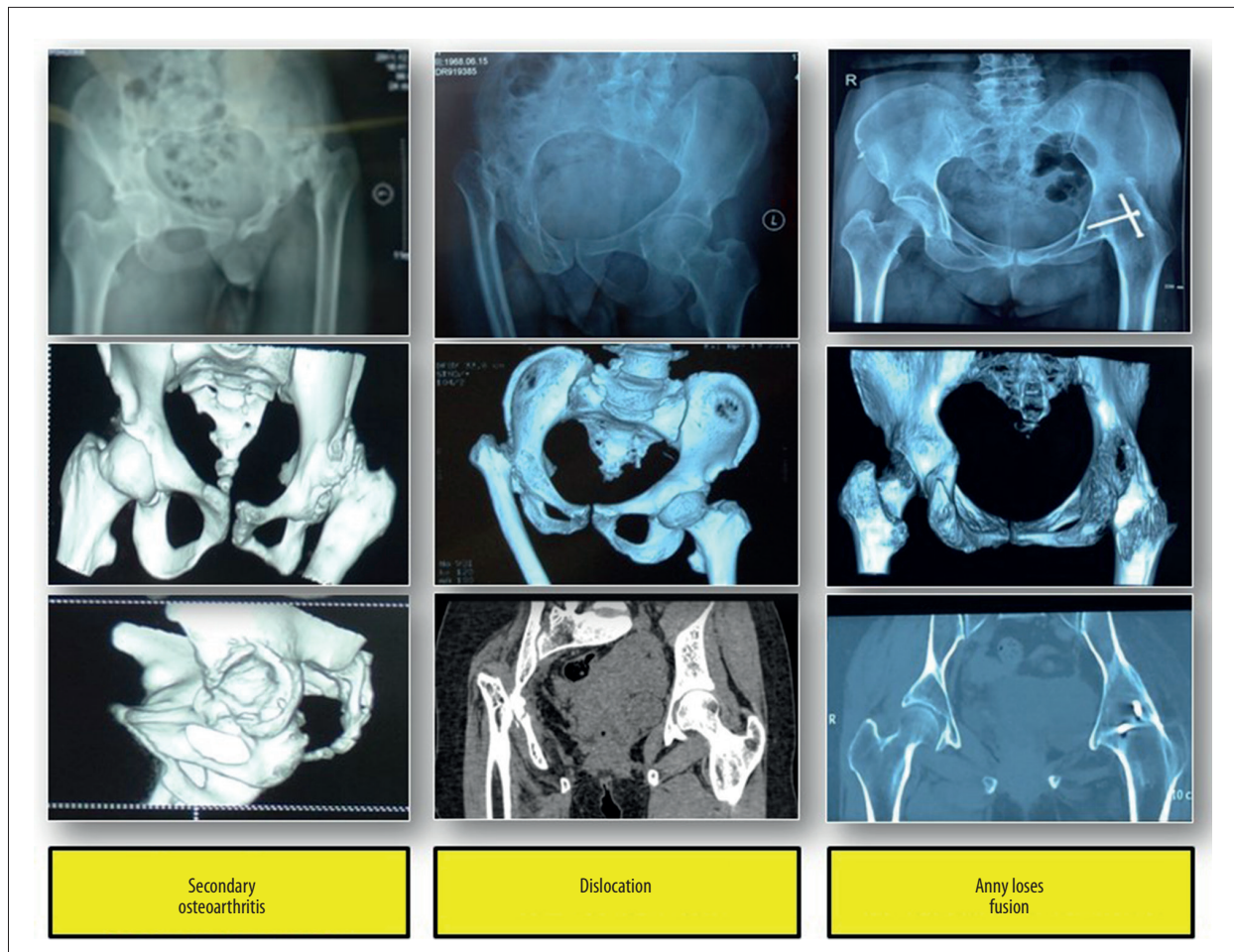
Variable	Demographics
Age (years)	46.1 (range, 18-67; SD, 10.23)
Sex (Male/Female)	17/28
Weight (kg)	64.1 (range, 52-82; SD, 11.03)
BMI (kg/m <sup>2</sup> )	23.4 (range, 21-33; SD, 3.72)
Mean duration between infection and THA (y)	38.2 (range, 15-60)
Secondary osteoarthritis	11
Dislocation	17
Ankyloses Fusion	17

BMI – body mass index; SD – standard deviation.

past medical histories and previous examinations. The inclusion conditions were as follows: hip osteoarthritis and a decided childhood history of septic and tuberculous infections of the hip joint. The exclusion conditions were as follows: osteoarthritis because of fungal infection (difficult to cure) and trauma. These types of pathogens included 14 hip joints *Staphylococcus aureus* infection, 5 hip joints of *Streptococcus* infection, 17 hip joints of tubercle bacillus infection, and 9 hips of unknown types of pathogens. The mean duration between infection and THA was 38.2 years. All of these patients were selected into this study (Table 1). All patients had single arthroplasties. The qualified patients included 17 men and 28 women with a mean age of 46 years (range, 18-67; SD, 10.23) at the time of the index operation. The mean body mass index was 23.4 kg/m<sup>2</sup> (range, 17-33 kg/m<sup>2</sup>). Eleven hips had a Secondary Osteoarthritis Type, 17 hips had a dislocation type and 17 hips had a Ankyloses Fusion Type. This study was approved by the local Institutional Review Board of First Affiliated Hospital of Xinjiang medical University (No. 20200519-01). All patients in this study supplied informed consent.

### Patient Evaluation

Pre- and postoperative medical data, imaging results, and surgical data of patients were recorded. Medical assessments were recorded at the 2<sup>nd</sup> week, 3<sup>rd</sup> month, 6<sup>th</sup> month, and annually after total hip replacement. At the medical assessment, patients were measured by the Harris hip score [6], hip dysfunction and osteoarthritis outcome score (HOOS) [7], hip pain visual analog scale (VAS) [8], and limb length discrepancy (LLD) [9]. These scores are based on the evaluation of pain, function, deformity, range of motion, and quality of life. The LLD (function) is calculated from the mid-position of the lesser trochanter on both sides of the pelvis teardrop line.



**Figure 1.** Adult patients with sequelae of childhood hip infection on the basis of anatomic classification.

### Bacteriological Evaluations

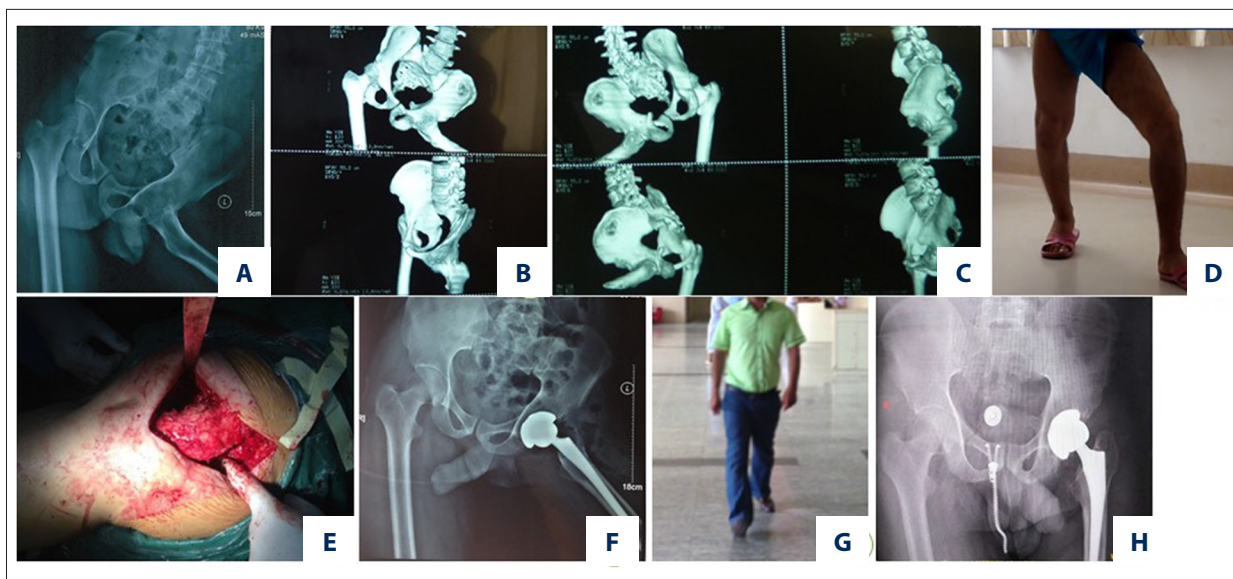
We agree with the view of previous studies that THA must be performed in infected hips that had remained quiescent for more than 10 years to prevent a higher risk of reinfection of previous pyogenic infections after THA [1,10]. Thus, we performed preoperative assessments to exclude evidence of persistent infection. Physical examinations were performed to observe skin condition, chronic pain, skin temperature, and phyma. The measurements of routine blood tests, C-reactive protein (CRP) levels, erythrocyte sedimentation rate (ESR), and culture of aspirated bacteria to exclude persistent pyogenic infection have a significant impact on the outcome after replacement [11,12]. Preoperative invasive tests that increase the risk of infection are not recommended. Intraoperatively, joint aspirates, smears, soft tissues, and excised specimens were used for the culture of aerobic bacilli, anaerobic bacilli, and tubercle bacilli. Frozen-section biopsies were performed in suspicious areas for evaluation of continuous infection.

### Patient Classification

According to our past experience, the sequelae of pyogenic infection and tuberculous were divided into 3 types based on the anatomical structure (**Figure 1**): I) secondary osteoarthritis, type II) dislocation type, and III) ankylose fusion type (pathological fusion or surgical fusion).

### Surgical Technique

Single-stage cementless THA was performed in all types of patients. All patients received general anesthesia, and all 3 types of patients were treated with a posterior or posterolateral incision to better manage soft-tissue contracture. Due to the disease's long course, these 3 types of hips have different degrees of a limited range of motion, scar tissues, and osteophytes. Therefore, osteophytes and excess scar tissue should be removed first. In type I patients, the goal of increasing the range of motion and improving reduction can be achieved by strengthening the release of soft tissue because the anatomical structure is similar to that of ordinary patients with



**Figure 2.** A 28-year-old man with left sequelae of childhood hip infection (ankylosis fusion type). (A-C) Preoperative X-ray and CT 3D reconstruction show the hip joint has abduction-extorsion deformity and ankylosis. (D) Preoperative gait, he cannot even walk normally. (E) Intraoperatively, we used the strategy of “single incision, double approaches”, posterolateral incision, femoral neck osteotomy by anterior and posterior approach. (F) Postoperative X-ray. The hip was reconstructed at the level of the anatomic hip center with cementless acetabular. (G) Normal gait was restored and the hip deformity returned to normal 1 year after the operation. (H) Seven years after the surgery, the femoral prosthesis is stable in a satisfactory position and the position of the acetabular prosthesis was also stable and acceptable.

osteoarthritis. In type II patients, we pursue placing the acetabular prosthesis in the true acetabular position. If there is no history of debridement surgery, the patient’s condition can be considered developmental dislocation of the hip. In general, femoral osteotomy may not be required after the selective release of the iliopsoas, iliotibial tract, and adductor muscle during surgery. If the patient had a history of childhood debridement surgery, the scar tissue significantly increased with the contracture of soft tissue is seriously inelastic. Meanwhile, a shorter osteotomy under the lesser trochanter was used, the length of the osteotomy was generally 2-5 cm, and the length was adjusted with the intraoperative operation. There was a significant difference in the leg length in type III patients, and we also tried to place the acetabular prosthesis in the true acetabular position. Meanwhile, for the treatment of femoral neck osteotomy, we used the strategy of “single incision, double approaches” (Figure 2), which is effective for the abduction-extorsion ankylosed hip. The femoral neck was exposed through the posterolateral incision, and an incomplete osteotomy was performed at the posterior femoral neck to avoid injury of the anterior vascular nerves. In the same incision, we gradually exposed the anterior femoral neck along the anterior intertrochanter, and the complete femoral neck osteotomy was performed to protect the vascular nerves. After the femoral neck was truncated and fully exposed by internal rotation of the hip joint, an osteotomy was performed to correct the femoral neck length. This strategy allows femoral neck osteotomy

to be performed safely and effectively, with better acetabular exposure in patients with severe adhesions. All patients were treated with oral rivaroxaban and use of mobile compression devices to prevent venous thromboembolism after the operation, and patients were encouraged to engage in limb functional exercise as early as possible after surgery.

### Radiographic Evaluation

All patients performed consecutive anteroposterior and lateral hip radiographs and the lower-extremities full-length views at every follow-up visit. All patients had comprehensive peri-operation imagological examination for assessment. The lengths of the lower limbs were measured. Thirty-one patients underwent preoperative 3D-CT reconstruction and image processing to fully evaluate the geometric features of the pelvis. In terms of postoperative imaging findings, when the inserted acetabular prosthesis is surrounded by a  $>2$  mm radiolucent line, any change in position or displacement of the prosthesis will be considered as loosening [13]. The acetabular cup angle was measured using the Widmer method [14]. DeLee and Charnley reported use of the three-zone system around the acetabulum to evaluate the stability of the bone-cup interface [15]. The bone healing at osteotomy position, heterotopic ossification, and prosthesis subsidence were also determined using the postoperative imaging result, using the Mason method [16]. The degree of stem prosthesis loosening was assessed using the Engh method [17].

## Statistical Analysis

SPSS 10.0 statistical software package was used for analysis. The data were analyzed using two-sided paired *t* tests with unequal variance, and Fisher's exact tests were used to analyze preoperative and postoperative continuous and categorical variables, including Harris hip score [6], HOSS [7], VAS score, and improvement in length of both lower limbs. A *P* value <0.05 was considered statistically significant. The data are presented as a range of averages or numbers and percentages. The Kaplan-Meier method makes full use of the incomplete information provided by the censored data in the process of calculating the survival rate. Although we do not know when this patient will have an endpoint event, we do know that there is no endpoint event during the follow-up period. Therefore, it was used to analyze the survival of the prosthesis undergoing revision for any reason.

## Results

### Clinical Assessment

At the final follow-up view, the mean position of the acetabular prosthesis was satisfactory, and the average bony coverage of the acetabular was more than 90%. Two cups were associated with evidence of mild osteolysis but did not require surgery. Three acetabular cups and 2 femur stems revealed >2 mm radiolucent lines. Two acetabular prostheses were in poor position but had no dislocation history. The remaining prostheses had strong imaging proof of fixation in an acceptable position. The mean LLD decreased from 4.5 cm preoperatively to 1.3 cm postoperatively.

### Radiographic Results

At the final follow-up view, the mean position of the acetabular prosthesis was satisfactory, and the average bony coverage of the acetabular was more than 90%. Two cups were associated with evidence of mild osteolysis but no need for surgery. Three acetabular cups and 2 femur stems revealed >2 mm radiolucent lines. Two acetabular prostheses were in poor position but had no dislocation history. The remaining prostheses had imaging proof of strong fixation in acceptable position. The mean LLD decreased from 4.5 cm preoperatively to 1.3 cm postoperatively.

### Complications

Intraoperative periprosthetic fractures were reported in 3 cases: 1 fracture of the greater trochanter and 2 femoral fractures that were fixed with wire cerclage and cured completely without evidence of prosthesis loosening. Two patients had

transient sciatic nerve palsy and recovered within less than 4 months after neurotrophic therapy and rehabilitation training, without further sequelae. No injuries to the gluteus medius occurred during the operation. Deep venous thrombosis occurred in 1 case before discharge, and oral rivaroxaban was given until venous thrombosis disappeared after 1 month of follow-up. A single revision was performed more than 6 years after the primary arthroplasty because of aseptic loosening in 2 cases and a single revision because of prosthesis infection in 1 case, which was not related to childhood pathogens (Table 2).

### Survival analysis

The Kaplan-Meier survival with no revision for any cause was 84.1% (95% CI 69-99) at 7 years after the operation (Figure 3).

## Discussion

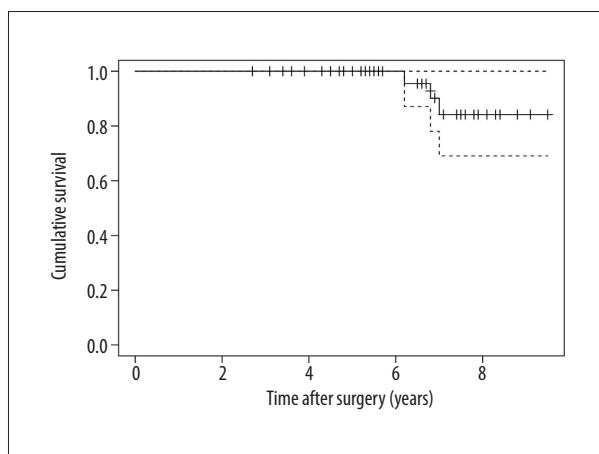
It is technically challenging to perform THA for patients with hip infection sequelae because of hip and femoral deformities in abnormal bony structure, soft-tissue contracture around the hip joint and structural abnormalities, pelvic tilt rotation deformity, scoliosis, and a series of other challenges [18-21]. Contracture of the skin and soft tissue, especially the abductor and adductor muscles, were weak or even absent. Therefore, for these patients, preoperative CT 3D reconstruction is very important for the evaluation of local anatomic abnormalities. In our study, we found that cementless THA achieved satisfactory clinical results in all patients, with a complication rate that was significantly lower than expected (Figure 4). These patients had sequelae of hip infection. We are inspired by some previous studies [22-24], and we are not entirely in agreement with using the Crowe classification [25] alone, as it does not fully cover all deformities. For instance, in our study, the patients with type III and type I can only be classified as the same type in Crowe classification, but the anatomical structure of these 2 types are dissimilar. Compared with the Crowe classification, which evaluates the degree of soft-tissue contracture by the degree of dislocation, we further classify the non-dislocation patients whose classification is only unified to achieve a more detailed assessment of soft-tissue contractures and deformities of various patients. Our classification based on the anatomical structure helped us evaluate the joint soft-tissue contracture, acetabular condition, and the length of both lower limbs before surgery; moreover, it also improves the intraoperative preparation.

The current consensus on pyogenic infection is that it is safe after 10 years of quiescent pyogenic infection [1,9,26]. Meanwhile, taking into consideration active tuberculosis, most previous studies recommend that arthroplasty can be performed in the quiescent stage [27,28]. However, we agree with recent articles

**Table 2.** Clinical and function outcomes.

Variable	Preoperative	Final follow-up	P value
HARRIS score(points) mean±SD	43.1±7.1	86.4±4.2	<0.01
Grading (hips number)			
Well (>90 points)	0	19	
Normal (80-90 points)	0	26	
Unacceptable (<80 points)	45	0	
VAS (points) mean±SD	4.6±1.8	1.7±0.5	<0.01
Range of motion (angle of degrees)			
Flexion mean±SD	78.2±15.5	109±6.8	<0.01
Permanent flexion mean±SD	11.2±4.7	0±0	<0.01
Limb length discrepancy (cm)			
Function mean±SD	4.5±1.8	1.3±0.2	<0.01
HOOS (point) mean±SD			
Symptoms	8.3±2.4	15.4±2.1	<0.01
Pain	11.8±4.3	28.9±8.7	<0.01
Daily living	29.1±7.6	61±14.5	<0.01
Sports and recreation activities	4.7±1.6	12.1±3.9	<0.01
Quality of life	4.7±1.8	13.3±4.6	<0.01

SD – standard deviation.

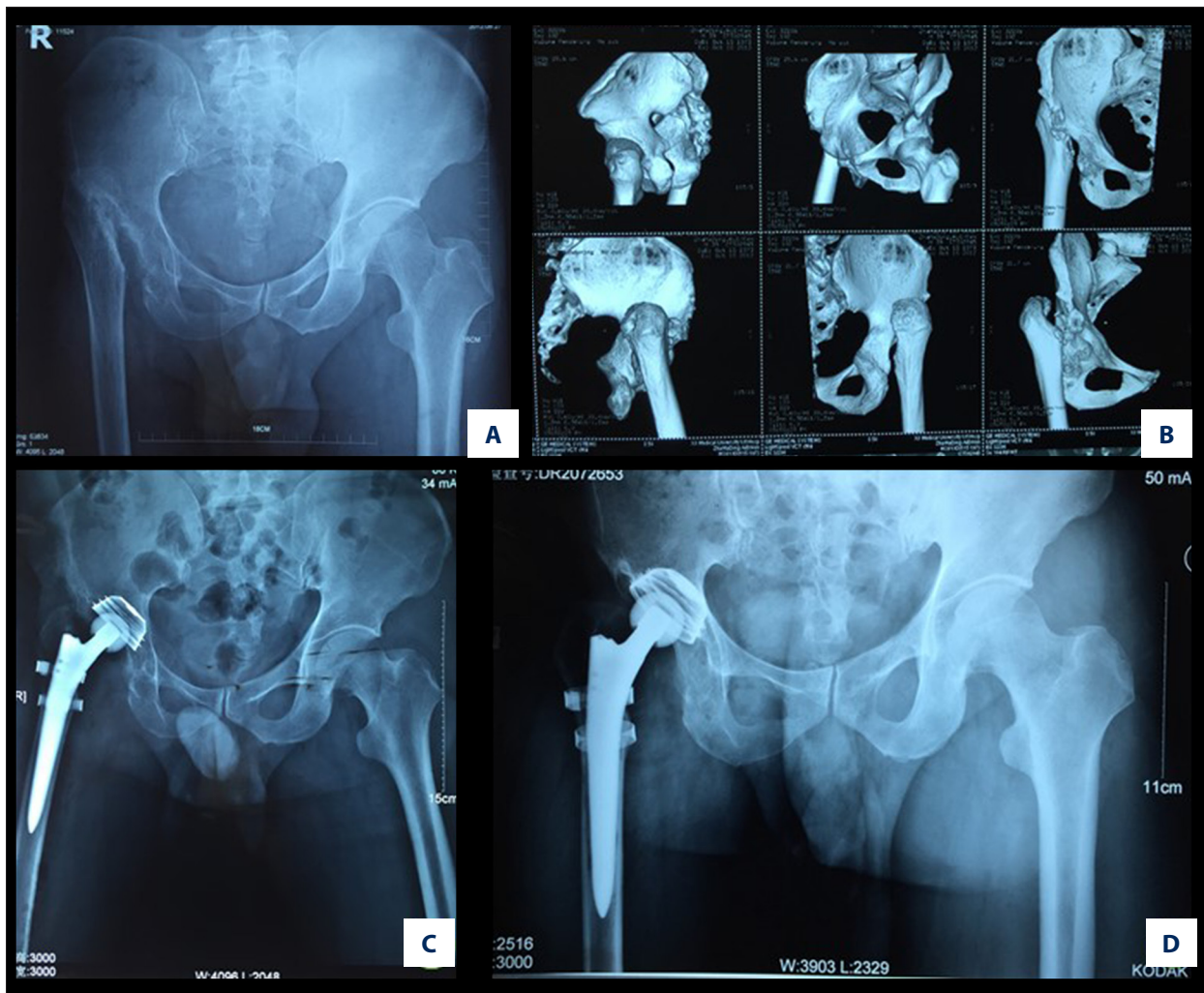


**Figure 3.** Kaplan-Meier survivorship curve with revision for any cause defined as the end point according to the Delphi consensus.

that reported that it is possible to perform surgery even in the presence of active tuberculous arthritis [29,30]. In our study, although 4 patients’ preoperative and intraoperative tests were positive for proof of reactivation tuberculosis infection, through intraoperative debridement and implantation of the prosthesis, no infection recurred in these 4 cases at each follow-up examination. There was 1 patient with quiescent pyogenic infection history of 16 years with the infection that recurred 7 years after THA, but the type of infecting organism

was different from the childhood organism. A large number of previous studies [31-33] showed that anatomic reduction of the acetabulum could effectively improve postoperative clinical outcome. Compared with patients with type I, acetabular reconstruction in patients with type II and III is more challenging. For these 2 types of patients, we also aim to find the position of the acetabulum and place the prosthesis as far as possible to lengthen the affected limb after surgery and effectively improve the function of the abductor muscles. Some type II patients have dysplastic acetabula and femurs, which are mainly irregular acetabula and femoral neck stumps. To ensure coverage of the acetabulum, reconstruction may require structural autografts (11 cases), porous tantalum augments (3 cases), tantalum cups (1 case), or special prostheses. For this type of acetabulum, attention needs to be paid to avoid wearing out the bottom of the acetabulum. Previous studies have shown that coverage is closely connected with the initial firmness of the acetabulum cup [34].

The proximal femur of patients with sequelae of hip infection is severely deformed with a narrow femoral canal; thus, to select the appropriate size of the prosthesis, CT 3D reconstruction should be performed before the operation to understand the shape of the canal. Intraoperatively, we used the “single incision, double approaches” strategy to perform soft-tissue release sequentially through the 2 approaches to maximize the incidence of intraoperative femoral fractures and nerve



**Figure 4.** A 39-year-old man with left sequelae of childhood hip infection (dislocation type). (A, B) Preoperative X-ray and CT 3D reconstruction show the high dislocation hip deformity and the narrow femoral canal deformity. (C) Postoperative X-ray. The cup was placed in the true position of the acetabulum and 2 cerclage bands around the femur were used to prevent intraoperative fractures. (D) Four years after the surgery, the femoral and acetabulum prosthesis are stable in satisfactory position.

injuries. However, cementless stems insert the slender canal to be stable through the press-fit technique probably led to femur fracture. In our study, we had 2 cases of femur fractures that were fixed by cerclage wire and cured completely with no symbol of prosthesis loosening. Some articles suggested a preventive setting of cerclage band before inserting stem [35]. Patients with a high degree of dislocation may not have enough reduction through extensive soft-tissue release and joint capsule after excision, requiring proximal femoral osteotomy. Acetabular prosthesis placed in the anatomic position probably led to nerve damage because of the long duration and severe soft-tissue release. In our study, 2 patients had transient sciatic nerve palsy. Therefore, nerve damage may occur if the limb is lengthened more than 4 cm [36,37]. In our study, 2 patients had transient sciatic nerve palsy and recovered within

less than 4 months after neurotrophic therapy and rehabilitation training, without further sequelae. Component survivorship is also an important consideration because these patients are young and vigorous. Three patients underwent revision THA because of aseptic loosening and infection.

There are some limitations to this study that need to be noted. First, this was a retrospective study with an internal possibility for inexact patient data and information bias. Second, this study was a single-center study without control patients, and these patients' medical history and diagnosis were limited by past medical capacity. Third, 3 different senior surgeons performed these operations, which may influence the validity of our study, but the surgical techniques of osteotomy and fixation can be traced to the same origin.

## Conclusions

Total hip arthroplasty for sequelae of hip joint infection patients has a satisfactory effect that can effectively relieve joint pain and improve hip function. Although the complication incidence rate is high, they can be treated successfully. Meanwhile, in our study, the recurrence rate of infection after either pyogenic infection or tuberculous was very low. The mid-term outcomes of THA in this setting were satisfactory, with high prosthesis survivorship and hip function scores. In addition to our new classification, a more comprehensive disease classification based on the anatomical structure will help us better prepare for surgery, determine intraoperative methods, and predict postoperative improvement in patient hip function.

## References:

- Luo Y, Yang Z, Yeersheng R, et al. Clinical outcomes and quality of life after total hip arthroplasty in adult patients with a history of infection of the hip in childhood: A mid-term follow-up study. *J Orthop Surg Res.* 2019;14(1):38
- Mathews CJ, Weston VC, Jones A, et al. Bacterial septic arthritis in adults. *Lancet.* 2010;375(9717):846-55
- Ross JJ. Septic arthritis of native joints. *Infect Dis Clin North Am.* 2017;31(2):203-18
- Castellazzi L, Mantero M, Esposito S. Update on the management of pediatric acute osteomyelitis and septic arthritis. *Int J Mol Sci.* 2016;17(6):855
- Papanna MC, Chebbout R, Buckley S, et al. Infection and failure rates following total hip arthroplasty for septic arthritis: A case-controlled study. *Hip Int.* 2018;28:63-67
- Harris WH. Traumatic arthritis of the hip after dislocation and acetabular fractures: Treatment by mold arthroplasty. An end-result study using a new method of result evaluation. *J Bone Joint Surg.* 1969;51:737
- Jacobs CA, Peabody MR, Duncan ST, et al. Development of the HOOS global to assess patient-reported outcomes in patients undergoing hip preservation procedures. *Am J Sports Med.* 2018;46(4):940-46
- Danoff JR, Goel R, Sutton R, et al. How much pain is significant? Defining the minimal clinically important difference for the visual analog scale for pain after total joint arthroplasty. *J Arthroplasty.* 2018;33(7S):S71-75
- Vogt B, Gosheger G, Wirth T, et al. Leg length discrepancy - treatment indications and strategies. *Dtsch Arztebl Int.* 2020;117(24):405-11
- Jeyanthi JC, Yi KM, Allen JC, et al. Epidemiology and outcome of septic arthritis in childhood: A 16-year experience and a review of literature. *Singapore Med J.* 2020 [Online ahead of print]
- Yang Y, Yu QP, Wang SL, et al. Outcomes after total hip arthroplasty using a cementless S-ROM modular stem for patients with high hip dislocation secondary to hip pyogenic arthritis. *Orthop Surg.* 2019;11(3):460-66
- Refakis CA, Arkader A, Baldwin KD, et al. Predicting periarticular infection in children with septic arthritis of the hip: Regionally derived criteria may not apply to all populations. *J Pediatr Orthop.* 2019;39(5):268-74
- Komiyama K, Fukushi JI, Motomura G, et al. Does high hip centre affect dislocation after total hip arthroplasty for developmental dysplasia of the hip? *Int Orthop.* 2019 Sep;43(9):2057-63
- Widmer KH. A simplified method to determine acetabular cup anteversion from plain radiographs *J Arthroplasty.* 2004;19:387-90
- Delee JG, Charnley J. Radiological demarcation of cemented sockets in total hip. *Clin Orthop Relat Res.* 1976;121:20-32
- Masonis JL, Patel JV, Miu A, et al. Subtrochanteric shortening and derotational osteotomy in primary total hip arthroplasty for patients with severe hip dysplasia: 5-year follow-up. *J Arthroplasty.* 2003;18(3 Suppl. 1): 68-73
- Engh CA, Massin P, Suthers KE. Roentgenographic assessment of the biological fixation of porous-surfaced femoral components. *Clin Orthop Relat Res.* 1990;257:107-28
- Agarwal A, Aggarwal AN. Bone and joint infections in children: Septic arthritis. *Indian J Pediatr.* 2016;83(8):825-33
- Zeng WN, Wang FY, Chen C, et al. Investigation of association between hip morphology and prevalence of osteoarthritis. *Sci Rep.* 2016;6:23477
- Wang D, Zeng WN, Qin YZ, et al. Long-term results of cementless total hip arthroplasty for patients with high hip dislocation after childhood pyogenic infection. *J Arthroplasty.* 2019;34(10):2420-26
- Murphy RF, Plumblee L, Barfield WB, et al. Septic arthritis of the hip-risk factors associated with secondary surgery. *J Am Acad Orthop Surg.* 2019;27(9):321-26
- Hunka L, Said SE, Mackenzie DA, et al. Classification and surgical management of the severe sequelae of septic hips in children. *Clin Orthop Relat Res.* 1982;171:30-36
- Choi IH, Pizzutillo PD, Bowen JR, et al. Sequelae and reconstruction after septic arthritis of the hip in infants. *J Bone Joint Surg Am.* 1990;72(8):1150-65
- Kim YH. Total hip arthroplasty in adult patients who had childhood infection of the hip. *J Bone Joint Surg Am.* 2003;85:198
- Crowe JF, Mani VJ, Ranawat CS. Total hip replacement in congenital dislocation and dysplasia of the hip. *J Bone Joint Surg Am.* 1979;61(1):15-23
- Cho YJ, Patel D, Chun YS, et al. Novel antibiotic-loaded cement femoral head spacer for the treatment of advanced pyogenic arthritis in adult hip. *J Arthroplasty.* 2018;33(6):1899-903
- Zeng M, Hu Y, Leng Y, et al. Cementless total hip arthroplasty in advanced tuberculosis of the hip. *Int Orthop.* 2015;39(11):2103-7
- Sultan AA, Dalton SE, Umpierrez E, et al. Total hip arthroplasty in the setting of tuberculosis infection of the hip: A systematic analysis of the current evidence. *Expert Rev Med Devices.* 2019;16(5):363-37
- Tiwari A, Karkhur Y, Maini L. Total hip replacement in tuberculosis of hip: A systematic review. *J Clin Orthop Trauma.* 2018;9(1):54-57
- Luo Y, Yang Z, Yeersheng R, et al. Clinical outcomes and quality of life after total hip arthroplasty in adult patients with a history of infection of the hip in childhood: A mid-term follow-up study. *J Orthop Surg Res.* 2019;14(1):38
- Shi XT, Li CF, Han Y, et al. Total hip arthroplasty for crowe type IV hip dysplasia: Surgical techniques and postoperative complications. *Orthop Surg.* 2019;11(6):966-73
- Ross JJ. Septic arthritis of native joints. *Infect Dis Clin North Am.* 2017;31(2):203-18
- Castellazzi L, Mantero M, Esposito S. Update on the management of pediatric acute osteomyelitis and septic arthritis. *Int J Mol Sci.* 2016;17(6):855
- Papanna MC, Chebbout R, Buckley S, et al. Infection and failure rates following total hip arthroplasty for septic arthritis: A case-controlled study. *Hip Int.* 2018;28:63-67
- Harris WH. Traumatic arthritis of the hip after dislocation and acetabular fractures: Treatment by mold arthroplasty. An end-result study using a new method of result evaluation. *J Bone Joint Surg.* 1969;51:737
- Jacobs CA, Peabody MR, Duncan ST, et al. Development of the HOOS global to assess patient-reported outcomes in patients undergoing hip preservation procedures. *Am J Sports Med.* 2018;46(4):940-46
- Greber EM, Pelt CE, Gililand JM, et al. Challenges in total hip arthroplasty in the setting of developmental dysplasia of the hip. *J Arthroplasty.* 2017;32(9S):S38-S44

## Conflict of Interest

None.