

CASE REPORT

Alveolar Osteonecrosis and Tooth Exfoliation in Herpes Zoster: A Rare Pediatric Case Report and Review of Literature

Garima Singh¹, Ankit Mehrotra², Kriti Garg³, Rahul Katyayan⁴

ABSTRACT

Varicella-zoster virus (VZV) is an envelope, spherical, 150–200 nm in diameter virus, with the single, linear, double-stranded DNA molecule, 125,000 nt long. It belongs to the genus *Varicellovirus*, family.

Keywords: Acyclovir, Child, Herpes Zoster, Hutchinson's sign, Prosthetic rehabilitation, Tooth exfoliation, Trigeminal nerve.

International Journal of Clinical Pediatric Dentistry (2020): 10.5005/jp-journals-10005-1837

INTRODUCTION

Before the late 19th century, varicella (chickenpox) has not been consistently differentiated from smallpox. Since ancient times herpes zoster (HZ) (shingles) has been known and identified in the early medical literature. Clinical findings of the varicella-HZ interaction were reported by Von Bokay in the year 1888, as sensitive children developed varicella following contact with HZ. In 1954, Weller isolated vesicular fluid from the varicella virus (VZV) from both chickenpox and zoster lesions in cell culture.¹

Varicella-zoster virus (VZV) can be the origin of a duo yet separate clinical entities: Varicella as well as HZ. Chickenpox is a highly transmissible and potentially lethal omnipresent condition; normally, a childhood disorder distinguished by an exanthematous vesicular rash and is a benign condition. The virus inside the skin spreads the sensory receptors during the initial varicella infection to become permanent in the sensory ganglia. With the reactivation of inactive VZV, HZ constitutes in the region of innervations by the infected sensory nerve as a cutaneous vesicular blowing up, often linked with extreme torment.²⁻⁵

An intense viral illness that impacts the trigeminal nerve (CN V) is the acute HZ (shingles). Reactivation could be due to immunosuppression, or it could be connected to age. It is the result of the VZV retrieval that remained dormant in the trigeminal ganglion upon exposure or clinical manifestation of chickenpox.⁶ Trigeminal (V cranial) nerve HZ targeting the ophthalmic (V1), maxillary (V2), or mandibular (V3) segment is a significant diagnostic source for oral and maxillofacial-related clinicians. Odontalgia, trigeminal neuralgia, could even create misinterpretations throughout painful stages. In the year 1908, Rose first described osseous specifics of HZ infection, which was later attributed to Gonnert et al. in 1922, being the first to draw awareness toward alveolar bone necrosis and tooth exfoliation in correlated to HZ.^{2,7} Acute pulpitis and the complications described in the literature, such as tooth resorption, periapical lesions, periodontal damage, exfoliation of the dents, osteomyelitis as well as jaw osteonecrosis promoting the dentist's involvement in the patient's management and therapy.⁸

Implicating trigeminal nerve divisions may contribute to disorders that appear on the face, mouth, eye, or tongue. When the mandibular or maxillary section of the trigeminal nerve becomes impaired, oral manifestations of HZ grow. However, the most

^{1,2,5}Department of Pedodontics and Preventive Dentistry, Rama Dental College and Research Centre, Kanpur, Uttar Pradesh, India

³Department of Prosthodontics, Rama Dental College and Research Centre, Kanpur, Uttar Pradesh, India

⁴Department of Oral Medicine Diagnosis and Radiology, Rama Dental College and Research Centre, Kanpur, Uttar Pradesh, India

Corresponding Author: Garima Singh, Department of Pedodontics and Preventive Dentistry, Rama Dental College and Research Centre, Kanpur, Uttar Pradesh, India, Phone: +91 8576888444, e-mail: drgarima.pedodontia@gmail.com

How to cite this article: Singh G, Mehrotra A, Garg K, *et al.* Alveolar Osteonecrosis and Tooth Exfoliation in Herpes Zoster: A Rare Pediatric Case Report and Review of Literature. *Int J Clin Pediatr Dent* 2020;13(S-1):S106–S109.

Source of support: Nil

Conflict of interest: None

frequent trigeminal nerve disease (50% of all trigeminal incidences) is eye involvement, it is important to note that the Hutchinson's sign (cutaneous zoster projections on each side of the tip of the nose) is pathognomonic for branch involvement with V2 (maxillary).⁹

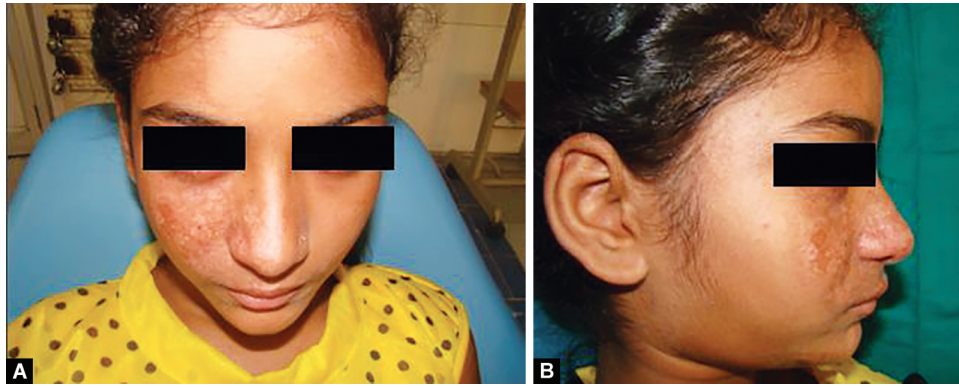CASE DESCRIPTION

A 13-year-old adolescent girl patient who had previously been diagnosed with HZ registered to the Department of Pedodontics and Preventive Dentistry, Rama University, Faculty of Dental Sciences, with an avulsed 11 (maxillary right central incisor) main complaint and pain, mobility in the lateral and canine maxillary right incisors.

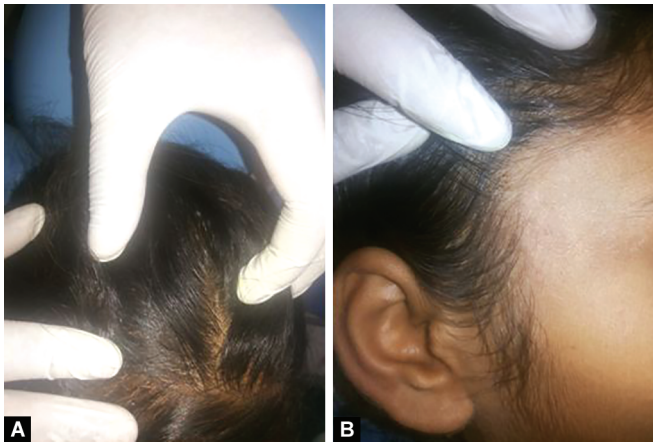Her history included a description of unilateral (right side) eruptions with HZ infection about 15–20 days ago, along with itching and burning sensation on the face and head region which was accompanied by spontaneous exfoliation of a tooth.

Extraoral examination revealed persistent scarring and pigmentation to the right half of the face (cheek area and nose) with features on the same side of the scalp, giving it a characteristic Hutchinson's HZ sign (Figs 1 and 2).

On intraoral examination, it was found that 11 was avulsed, while 12 and 13 presented grade I mobility, gingival recession, and alveolar bone exposed in the first quadrant in the maxillary



Figs 1A and B: Profile photograph showing facial scarring and hyperpigmentation, post-herpes zoster involving V2 dermatome



Figs 2A and B: Scarring and itching in the right side of the scalp

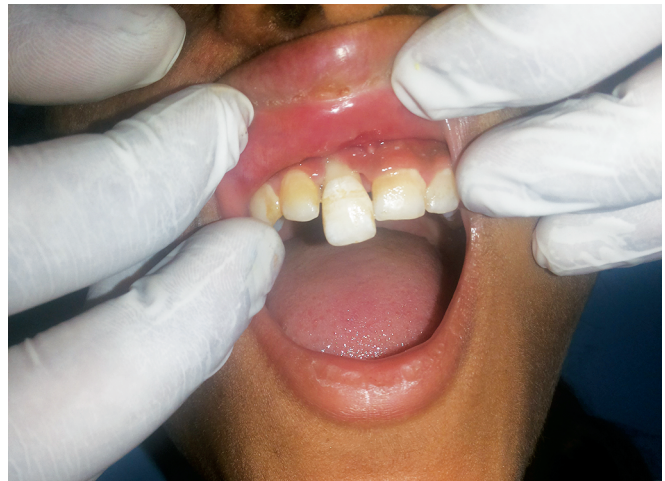

Fig. 3: Intraoral photograph showing completely detached maxillary right central incisor tooth and grade I mobility in 12 (maxillary right lateral incisor) and 13 (maxillary right canine)

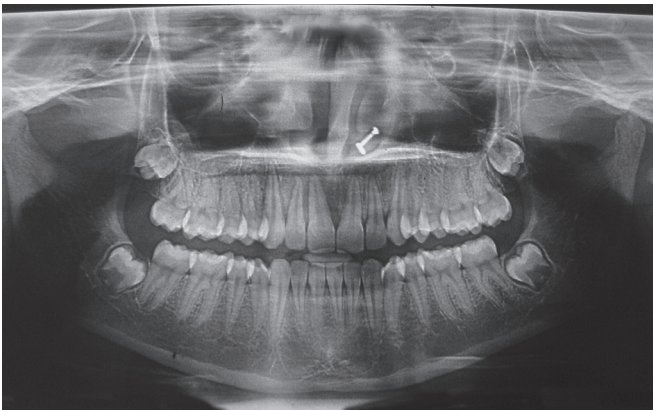


Fig. 4: Orthopantomogram

arch extending from 11 till 17. Marked vague gingivitis and early periodontitis lesions were observed in the teeth concerned (Fig. 3).

Radiographic examination revealed completely detached 11 (maxillary right central incisor) from the alveolar socket with necrosis and destruction of alveolar bone and localized moderate bone destruction in maxillary right quadrant ranging from central incisor tooth up to second molar tooth (Fig. 4).

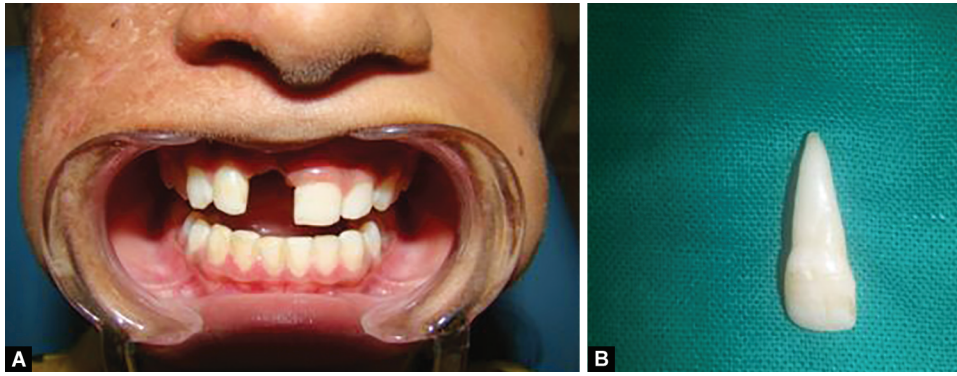
Based on the clinical examination, the case was provisionally diagnosed as sudden tooth loosening out of socket and light alveolar osteonecrosis along with HZ contamination of the maxillary

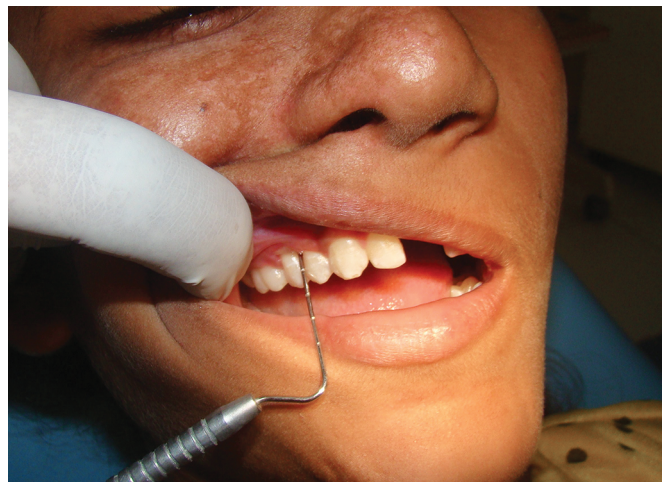

Fig. 5: Localized moderate bone destruction in maxillary right quadrant ranging from central incisor tooth up to second molar tooth

division of trigeminal nerve. A differential diagnosis of osteomyelitis was also considered (Fig. 5).

As the prognosis of teeth number 11 was considered hopeless, it was removed from the socket followed by removal of fragments



Figs 6A and B: After removal of the maxillary right central incisor tooth

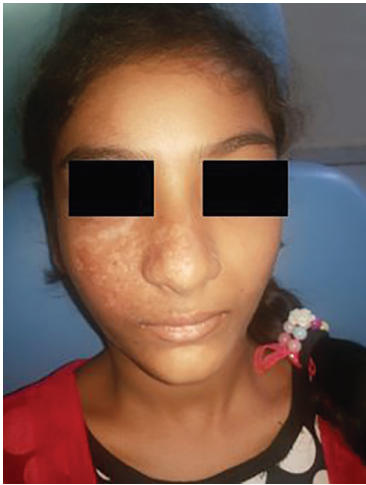

Fig. 7: Relief in scarring and hyperpigmentation involving V2 dermatome after symptomatic drug therapy

of necrotic bone at the time of extraction. The soft tissue from the region gave no signs of malignancy or vasculitis on histopathologic examination. A thorough ultrasonic scaling was performed (Fig. 6).

The patient was kept under symptomatic drug therapy for 1 week, including antiviral; acyclovir 400 mg (5 times a day), vitamin—Cobadex CBZ (1 time a day), antiallergic—Levocetirizine 5 mg (1 time a day), antidopaminergic agent—Ranidom RD (2 times a day), Ointment Herpex (to be applied 3–4 times a day extraorally), and methylcobalamin—Nerve Shine-SR (1 time a day).

A proper medical referral and necessary investigations, blood sugar investigation, quantitative PCR or viral culture, posteroanterior chest X-ray, and ELISA for HIV were prescribed. Patient reported back after a week with symptomatic treatment relief (Fig. 7) and prosthetic rehabilitation was done by providing a removable partial denture in relation to tooth number 11 (Fig. 8). Further continuation of the medicines was instructed and the patient was recalled after a week. But the parents of the child refused to undergo any investigation and then never reported back.

DISCUSSION

Herpes zoster is a sporadic disease. In 1.5–3 of every 1,000 individuals and most commonly affecting nerves are C3, T5, L1, L2, and first division of Trigeminal (V) nerve.¹⁰ With the presence of dental complications along with postherpetic neuralgia about

46 cases have been reported and published to date. Among which 20 cases were those with underlying systemic disease and 26 cases were immune-competent patients.¹⁰ Many scholars stated that the unexpected shedding of teeth in the region of the damaged nerve is an early sign that happens, while some claim it is a slow development in the first 2 weeks of the outbreak, as can be seen in our case.

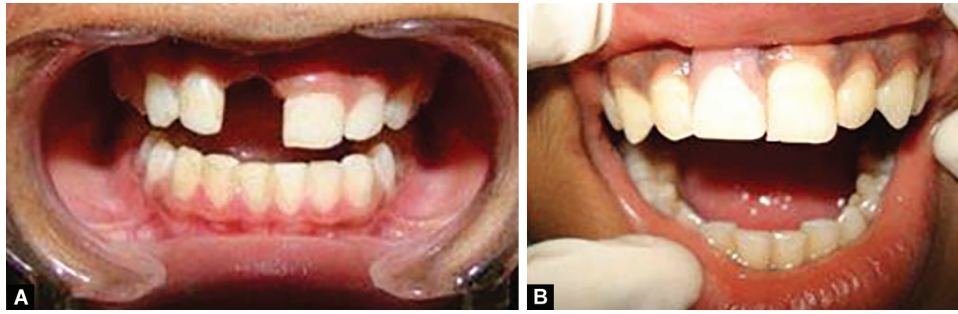
Figure 8 shows average age spanning from 6 to 85 years; four have been under 40 years old, eight were between 40 and 60 years old, and eight have over 60 years old. The maxilla ($n = 9$; 33 teeth exfoliated) while in the mandible ($n = 11$; 33 teeth lost) have been similar through prevalence. Thirty-one of the teeth lost were anterior teeth and thirty were posterior teeth. As not all cases were recorded about both the individuals' gender, but the data available showed more in accordance with females ($N = 9$) than males ($N = 7$).² Only two cases were reported in the pediatric patient, with only one of the two involved loss of teeth, as it is a rare trait.

Ocular involvement is the most prevalent trigeminal nerve infection (50% of all trigeminal occurrences), then it is important to mention that Hutchinson's sign (cutaneous zoster lesions on one side of the nose tip) is a pathognomonic branch involvement of V2 (maxillary).⁹ The patient suffers spontaneous exfoliation of the teeth on the affected side and also osteonecrosis on the further resolution of the acute/active phases. As in the present case, the contralateral side of the patient's jaw remains within normal limits.¹¹

The increasing number of HZ infection in AIDS patients has moved the frequency to older and younger individuals.¹² This may develop after stress or severe injury circumstances but is more closely associated with compromised immune response conditions, including those under systemic corticosteroid medications, cytostatic chemotherapy, immunosuppressants or radiation treatment, or with chronic lymphocytic lymphomas and lymphomas associated with malignancies.^{13–18}

Herpes zoster disease can spread cranial nerves, with both the trigeminal nerve being one of the most frequently affected (18.5–22% of total cases), followed by glossopharyngeal nerve and hypoglossal nerve and limited to a single division, more often the ophthalmic.^{19–21} Oral symptoms may also, take place when influencing the maxillary and mandibular trigeminal divisions.

Ocular swelling and corneal denervation are potential significant complications. In the maxillary branch (V2) HZ the evidence is about V2 dermatome, i.e., cheek, lateral nose, nasal mucosa, lower eyelid, cheek mucosa, maxillary gums, palate, tonsil, and nasopharynx. Sometimes there have been no skin symptoms except for the oral mucosa.²²



Figs 8A and B: Prosthetic rehabilitation—removable partial denture for teeth number 11

Sudden exfoliation of teeth has been reported in the innervated area of the affected nerve. Some studies have indicated that this is an early occurrence that occurs within the infection's first 2 weeks,^{14–17} while others consider it a late complication that happens between the third and twelfth weeks after it begins.²³ Alveolar bone necrosis and/or periodontal ligament necrosis are responsible for the loss of teeth.¹⁴ After the extraction of the tooth, the healing of the periodontal tissue is usually slower than usual and sometimes fragments of the necrotic bone persist following extraction^{15,17,24} to protect the alveolar height.¹⁶ In our case, the tooth was extracted as it was completely avulsed out of the socket with no bone and periodontal support, which occurred 5 weeks after HZ infection ends. At about the same time, it eliminated necrosed osseous tissue.

CONCLUSION

Herpes zoster includes the trigeminal nerve and also has dental complications.

A rare observation yet is an alarming situation for the patient as well as the dentist. Hence, a thorough knowledge regarding the same is a mandatory affair. The success lies in a proper detailed history (medical as well as dental) which helps to reach an early diagnosis and treatment.

REFERENCES

- Gracia San Miguel J. Herpesvirus infections (in Spanish) Ferreras P, Rozman C. Internal Medicine. Barcelona: Doyma; 1989. pp. 2306–2310.
- Tyler KL. Aseptic meningitis, viral encephalitis, and prion diseases Fauci AS, Braunwald E, Isselbacher KJ, et al., ed. Harrison's Principles of Internal Medicine. 14th ed., New York: McGraw-Hill; 1998. pp. 2439–2441.
- Rose F. Postherpetic neuralgia; Trophic lesions in hand's bones similar to rheumatoid arthritis (in French). Nouvelle Iconogr de la Salpêtrière, Soc Neurol 1908. 64.
- Klasser GD, Ahmed AS. How to manage herpes zoster affecting trigeminal nerves. J Can Dent Assoc 2014;80:e42.
- Gupta S, Sreenivasan V, Patil PB. Dental complications of herpes zoster: two case reports and review of literature. Indian J Dent Res 2015;26(2):214–219. DOI: 10.4103/0970-9290.159175.
- Tidwell E, Hutson B, Burkhart N, et al. Herpes zoster of the trigeminal nerve third branch: a case report and review of the literature. Int Endodon J 1999;32(1):61–66. DOI: 10.1046/j.1365-2591.1999.00187.x.
- Mendieta C, Miranda J, Brunet LI, et al. Alveolar bone necrosis and tooth exfoliation following herpes zoster infection: a review of the literature and case report. J Periodontol 2005;76(1):148–153. DOI: 10.1902/jop.2005.76.1.148.
- Makos C, Noussios G, Peios M, et al. Herpes zoster of the trigeminal nerve – two cases reports. Int J Neurol 2010;13(2);1–6.
- Martin JB, Beal MF. Disorders of the cranial nerves Fauci AS, Braunwald E, Isselbacher KJ, et al., ed. Harrison's Principles of Internal Medicine. 14th ed., New York: McGraw-Hill; 1998. pp. 2377–2381.
- Eastern JS, Zoster H, eMedicine <http://www.emedicine.com/derm/topic180.htm>. Last updated September 18, 2006.
- CDC Prevention Guidelines Database (Archive). Available From: <http://wonder.cdc.gov/wonder/prevguid/prevguid.html>.
- Dechaume M, Descrozailles C, Garlopeau F, et al. Localized mandibular necrosis during herpes zoster infection (in French). Rev Stomatol 1955;56:516–521.
- Millar EP, Troulis MT. Herpes zoster of the trigeminal nerve: the dentist's role in diagnosis and treatment. Canad Dent J 1994;60:450–453.
- Muto T, Tsuchiya H, Sato K, et al. Tooth exfoliation and necrosis of the mandible – a rare complication following trigeminal H. Zoster: report of a case. J Oral Maxillofac Surg 1990;48(9):1000–1003. DOI: 10.1016/0278-2391(90)90020-3.
- Eversole LR. Viral infections of the head and neck among HIV-seropositive patients. Oral Surg Oral Med Oral Pathol 1992;73(2):155–163. DOI: 10.1016/0030-4220(92)90188-V.
- Beck JD, Watkins C. Epidemiology of nondental disease in elderly. Clinics Geriat Med 1992;8(3):461–482. DOI: 10.1016/S0749-0690(18)30458-0.
- Toshitaka M, Tsuchiya H, Sato K, et al. Tooth exfoliation and necrosis of the mandible - a rare complication following trigeminal herpes zoster: report of a case. J Oral Maxillofac Surg 1990;48(9):1000–1003. DOI: 10.1016/0278-2391(90)90020-3.
- Mostofi R, Marchmont-Robinson H, Freije S. Spontaneous tooth exfoliation and osteoradionecrosis of the fifth cranial nerve. J Oral Maxillofac Surg 1987;45(3):264–266. DOI: 10.1016/0278-2391(87)90126-1.
- Schwartz O, Kvorning A. Tooth exfoliation, osteonecrosis of the jaw and neuralgia following herpes zoster of trigeminal nerve. Int J Oral Surg 1982;11(6):364–371. DOI: 10.1016/S0300-9785(82)80060-4.
- Shira RB. Necrosis of maxilla in patient with herpes zoster. Oral Surg Oral Pathol 1974;37(5):657–662. DOI: 10.1016/0030-4220(74)90128-5.
- Dolin R, Reichman RC, Mazur MH, et al. Herpes zoster-verricella infections in immunosuppressed patients. Ann Intern Med 1978;89(3):375–388. DOI: 10.7326/0003-4819-89-3-375.
- Hornstien OP, Gorlin RJ. Oral infectious diseases Gorlin RJ, Goldman HM, ed. Thoma's Oral Pathology. Barcelona: Salvat; 1973. pp 822–824.
- Eury J, Gilain L, Peynegre R. Oral manifestations of zona. A case report (in French). Ann Otolaryng 1993;110:170–172.
- Mckenzie CD, Gobetti JP. Diagnosis and treatment of orofacial herpes zoster: report of cases. J Am Dent Assoc 1990;120(6):679–681. DOI: 10.14219/jada.archive.1990.0096.