

## Original Article



# Histopathological and microbiological findings in buffalo chronic mastitis: evidence of tertiary lymphoid structures

Brunella Restucci <sup>1</sup>, Ludovico Dipineto <sup>1</sup>, Manuela Martano <sup>1\*</sup>,  
Anna Balestrieri <sup>2</sup>, Davide Ciccarelli <sup>1</sup>, Tamara Pasqualina Russo <sup>1</sup>,  
Lorena Varriale <sup>1</sup>, Paola Maiolino <sup>1</sup>

## OPEN ACCESS

<sup>1</sup>Department of Veterinary Medicine and Animal Productions, Naples University Federico II, 80137 Naples, Italy  
<sup>2</sup>Istituto Zooprofilattico Sperimentale del Mezzogiorno, Portici, 80055 Naples, Italy

**Received:** Nov 1, 2018  
**Revised:** Jan 26, 2019  
**Accepted:** Mar 27, 2019

### \*Corresponding author:

**Manuela Martano**

Department of Veterinary Medicine and Animal Productions, Naples University Federico II, Via F. Delpino 1, 80137 Naples, Italy.  
E-mail: manuela.martano@unina.it

© 2019 The Korean Society of Veterinary Science

This is an Open Access article distributed under the terms of the Creative Commons Attribution Non-Commercial License (<https://creativecommons.org/licenses/by-nc/4.0>) which permits unrestricted non-commercial use, distribution, and reproduction in any medium, provided the original work is properly cited.

### ORCID iDs

Brunella Restucci   
<https://orcid.org/0000-0001-6307-3395>  
Ludovico Dipineto   
<https://orcid.org/0000-0003-2577-3459>  
Manuela Martano   
<https://orcid.org/0000-0002-1577-4223>  
Anna Balestrieri   
<https://orcid.org/0000-0001-6818-5628>  
Davide Ciccarelli   
<https://orcid.org/0000-0001-8697-5172>  
Tamara Pasqualina Russo   
<https://orcid.org/0000-0002-3844-8455>  
Lorena Varriale   
<https://orcid.org/0000-0002-5397-877X>  
Paola Maiolino   
<https://orcid.org/0000-0002-8863-466X>

<https://vetsci.org>

## ABSTRACT

Buffalo mastitis is an important economic problem in southern Italy, causing qualitative/quantitative alterations in milk and resulting in economic losses due to the sub-clinical course and chronic evolution. We investigated 50 udders of slaughtered buffaloes and subjected them to effectual microbiological screening to evaluate macro and microscopic mammary gland changes, immune-characterize the cell infiltrates, and compare the degree of tissue inflammation with somatic cell counts. Numerous Gram-positive and Gram-negative bacteria were isolated from all samples, majority of which were environmental mastitis pathogens. Histological features referable to chronic mastitis were observed in 92% udders. Lymphocytes, plasma cells and macrophages were found to evolve into aggregates in 48% udders, which often organized to form tertiary lymphoid structures (TLSs). A predominance of interstitial CD8+ over CD4+ lymphocytes and, in TLSs, scattered CD8+ lymphocytes in the mantle cells and CD79+ lymphocytes in germinal centers, were evidenced. Environmental pathogens are known to persist and cause chronic inflammatory changes in buffaloes, where CD8+ lymphocytes play an important role by controlling the local immune response. Moreover, the TLSs evidenced here for the first time in buffalo mastitis, could play a role in maintaining immune responses against persistent antigens, thereby contributing in determining the chronic course of mastitis.

**Keywords:** Chronic mastitis; buffalo; histopathology; microbiology; tertiary lymphoid structures

## INTRODUCTION

Bacterial mastitis in large ruminants is a globally important challenge of the dairy industry, causing considerable economic losses due to a frequently sub-clinical course resulting in persistence of pathogens within the herd [1]. Subsequently, there is a drop in the productivity, and qualitative and quantitative alterations of milk with degradation of organoleptic characteristics and preservability [2]. It is estimated that two-thirds of the total production loss of milk is attributable to subclinical mastitis [3,4]. In addition, infected animals become

### Funding

This research was supported by PON-RICERCA E COMPETITIVITA' 2007-2013, MAREA (PON03PE\_00106\_1 PROJECT "MAREA" ADVANCED MATERIALS FOR RESEARCH AND AGRICULTURAL COMPARTMENT). The funders had no role in the study design, data collection, analysis and interpretation, decision to publish, or preparation of the manuscript.

### Conflict of Interest

The authors declare no conflicts of interest.

### Author Contributions

Conceptualization: Restucci B, Maiolino P; Data curation: Dipineto L, Martano M; Formal analysis: Restucci B, Dipineto L; Funding acquisition: Dipineto L, Restucci B, Maiolino P; Investigation: Ciccarelli D, Russo TP, Varriale L; Methodology: Dipineto L, Martano M, Restucci B; Project administration: Restucci B, Maiolino P, Dipineto L; Resources: Balestrieri A, Restucci B, Dipineto L; Software: Martano M, Ludovico L; Supervision: Balestrieri A, Maiolino P; Validation: Maiolino P, Restucci B; Visualization: Dipineto L, Russo TP, Maiolino P; Writing - original draft: Maiolino P, Restucci B, Dipineto L; Writing - review & editing: Maiolino P, Restucci B, Dipineto L.

asymptomatic carriers of pathogens that spread in the herd. To date, most mastitis studies have been conducted in cows [5,6]; however, recent reports indicate that domesticated dairy buffaloes are similarly affected with mastitis [7]. Numerous bacteria, such as contagious (*Staphylococcus aureus*, *Streptococcus agalactiae*, *Mycoplasma* spp.), environmental (*Streptococcus uberis* and *Streptococcus dysgalactiae*, *Escherichia coli*, *Enterobacteriaceae*, *Klebsiella*, *Pseudomonas* spp.), and opportunistic species (*Coagulase-negative staphylococci*; *CNS*) have been reported in mastitis of these ruminants [8,9]. Different bacteria are likely to cause different clinical forms of mastitis; nevertheless, research in this area considering the Mediterranean buffalo remains scanty and is limited to identification of few individual bacterial species [10,11]. Mastitis susceptibility is chiefly related to intrinsic immune defense system of the mammary gland [12]. Leucocytes, together with epithelial cells shed from the udder, are naturally present in milk and are also known as the somatic cells (SCs). Along with a bacteriological examination, somatic cell count (SCC) is commonly used as an indicator of udder health and milk quality. Buffaloes are considered healthy in terms of dairy production if each mammary quarter produces bacteriologically negative milk with an SCC below  $300 \times 10^3$  cells/mL, as reported in annex III, section IX of the Regulation 853/2004 of the European Parliament, and of the Council of 29 April 2004 (Ref. L139/55 Official Journal of the European Union). However, buffaloes producing bacteriologically positive milk with an SCC higher than  $300 \times 10^3$  cells/mL are defined as suffering from subclinical mastitis [2,9]. It is well known that tissues harboring the target antigens of chronic inflammation are infiltrated mainly by lymphocytes, plasma cells and macrophages. In some chronic inflammatory disease, these cells organize themselves, leading to the de novo formation of lymphoid structures called tertiary lymphoid structures (TLSs) [13-16]. TLSs have a complex microarchitecture and are morphologically and functionally similar to secondary lymphoid organs (SLOs). Although TLSs are usually found in the background of chronic inflammation, autoimmunity and cancer [17-20], their functional significance remains unclear. For effective control of subclinical mastitis, to reduce the risk of chronic infections, and to target antimicrobial therapy, it is essential to identify etiological agents and to evaluate their interaction with the mammary gland immune defense system [5].

Thus, the present study was undertaken to examine clinically healthy buffaloes sent to slaughter, with the aim to: 1) effectuate microbiological screening of sampled mammary gland tissue, 2) identify and characterize subclinical-mastitis by evaluating the macro- and microscopic mammary gland changes, and the possible role played by TLSs to determine the chronic course of mastitis, 3) immuno-characterize the cell infiltrates, and 4) compare the degree of tissue inflammation with SCC.

## MATERIALS AND METHODS

### Animals

During a period of 9 consecutive months, udder samples from 50 water buffaloes of different ages were collected for bacteriological and histological examinations. The animals came from two farms located in the provinces of Foggia and Caserta (southern Italy). All animals were at the end of their lactation period and had been destined to slaughtering because of decreased milk production. No clinical signs of mastitis were evidenced by either the farm or official veterinarians during the ante-mortem examination performed in the slaughterhouse. Sampling was conducted during the slaughtering procedures, strictly in accordance with Council Regulation (EC) No 1099/2009 of 24 September 2009 for the protection of animals

at the time of killing (Ref. Official Journal of the European Union L 303/1); that is, following a mandatory clinical ante-mortem examination as required by the European Union (EU) legislation and during post mortem inspection, with the consent of the slaughterhouse competent authority and of the veterinary inspector responsible for sanitary surveillance.

Inspection and palpation of the udder surface area was performed immediately after slaughter. Supra-mammary lymph nodes were identified and, on each node, a cut involving the cortex and medulla was performed. Subsequently, the skin of the udder was washed, dried and disinfected with cotton, and soaked in 70% alcohol; using sterile blades, a deep cut involving the teat and mammary gland was performed in each quarter. The cut surface was inspected, and tissue samples were collected aseptically for histological examination, from each quarter of the teat region, and the low, middle, and high regions of the mammary gland. In addition, using sterile cotton-tipped swabs, two swab samples were obtained from the lactiferous ducts and teat sinuses for bacteriological examination (Copan Italia, Italy). All samples were carried to laboratories in refrigerated containers, within 1 h after collection.

### **Milk SCC/Milk Somatic Cell Count Grade (SCCG)**

The milk SCC was first performed at the farm, in the month preceding slaughtering. Based on their severity, SCC were categorized into 4 grades: SCCG 0 (< 300,000/mL); SCCG 1 (from 300,000 to 1,000,000/mL); SCCG 2 (from 1,000,000 to 2,000,000/mL); SCCG 3 (> 2,000,000/mL).

In order to know the duration of an eventual subclinical mastitis for each animal, the mean value of SCC/year was calculated using results of 10 monthly counts/year, performed regularly from the first lactation till the year of slaughtering; these cell counts were registered and provided by the farmers.

### **Bacteriological examinations**

#### *Isolation of bacteria*

Samples obtained from each animal were pooled and agitated by vortex; 2 µL each were plated on Columbia Blood Agar Base (CBA; Oxoid), Aeromonas medium base (AMB; Oxoid), *Pseudomonas* Cetrimide Agar (PCA; Oxoid), MacConkey Agar (MCA; Oxoid) and Baird-Parker agar (BPA; Oxoid). An aliquot of PBS was also streaked on Anaerobe Basal Agar (ABA; Oxoid) and *Campylobacter* blood-free selective agar (CCDA; Oxoid). The CBA, AMB, PCA, MCA and BPA plates were incubated at 37°C for 24–48 h, CCDA were micro-aerobically incubated at 42°C for 24–48 h, whereas ABA plates were anaerobically incubated at 37°C for 48 h. All plates were checked daily for an additional week before being discarded.

### **Biochemical and molecular identification**

After incubation, all isolated strains were first identified based on their colonial morphology, their Gram and acid-fast characteristics, growth requirements, motility tests, and pigment production. The strains were then subjected to the tube coagulase test and standard conventional biochemical and phenotypic tests. Finally, API systems (Bio Mérieux, France) and RapID systems (Oxoid) were used to confirm the species of the isolates. *E. coli* isolates were serogrouped with poly- and monospecific antisera (Sifin, Germany).

### **Anatomical and histological examination**

Tissue samples of the low, middle and high region and the whole teat were divided; one part was fixed in 10% neutral buffered formalin and the other was quick-frozen in isopentane

immersed in liquid nitrogen. Tissue samples were subsequently subjected to routine processing. Sections for histological examination were stained with hematoxylin-eosin. To determine the severity and chronicity of inflammation, a quantitative estimation of infiltrating cells was performed for each udder; 20 fields were chosen at higher magnification (40×) and all inflammatory cells were counted in the teat, low, middle and high regions of each quarter. The results were expressed as the average of all inflammatory cells counted in the 20 chosen fields of each region. Four degrees of infiltration (G: infiltration grade) were established for each region: G0, absent (< 20 inflammatory cells); G1, low (20–40 inflammatory cells); G2, moderate (40–60 inflammatory cells); G3, severe (> 60 inflammatory cells) (**Table 1**).

### Immunofluorescence staining

Immunofluorescence staining was performed on 20 frozen samples selected from sections histologically graded as G2 and G3 (5/G2 and 5/G3 for each quarter); only the low mammary gland or teat regions were examined. Mouse monoclonal anti-bovine CD4 (clone ILA11A), anti-bovine CD79 (clone BAQ44A), and anti-bovine CD8 $\alpha$  (clone CACT80C) (Kingfisher Biotech) were used as primary antibodies for typing the infiltrating inflammatory cells. Primary antibodies were reconstituted and diluted 1:10 in PBS. Briefly, sections were incubated overnight at 4°C, and slides were then washed three times (5 min each) in PBS. Sections were subsequently treated with CD4 and CD8 antibodies, followed by incubation with a tetramethyl-rhodamine-isothiocyanate (TRITC)-conjugated goat anti-mouse secondary antibody (diluted 1:100 in PBS) for 2 h at room temperature. The same sections were exposed with CD79 antibody and incubated with fluorescein isothiocyanate (FITC)-conjugated goat anti-rabbit secondary antibody (Chemicon, Germany) diluted 1:100 in PBS, for 2 h at room temperature. Slides were rinsed with PBS and mounted in fluorescent mounting medium (Dako).

To test the specificity of staining, mouse IgG1 (NC490AA, Biocare Medical LLC, USA) was used as the negative control.

### Statistical analysis

Correlation between the leucocyte infiltration grade and SCCG was assessed by using Pearson's correlation coefficient. Correlation between the leucocyte infiltration grade and the presence of TLSs was assessed using  $\chi^2$  trend test. Comparison between isolated bacteria and presence of TLSs was assessed using Fisher's exact test. The value of  $P > 0.05$  is considered to be statistically significant.

## RESULTS

### Milk SCCG

The values of SCC count are presented in **Table 1**; 7 buffaloes were graded as SCCG 0, 17 were SCCG 1, 13 were SCCG 2, and 13 were SCCG 3.

In 32 buffaloes, the mean value of SCC/year during lactation demonstrates a progressive increase from the first lactation until slaughtering. In 18 buffaloes, the SCC increased progressively from the first lactation, reached a peak, and then decreased to finally stabilize at a level higher than that of the first lactation.

**Table 1.** Results of SCC, histological and bacteriological analysis from 50 samples of buffalo chronic mastitis

Case number	Date of birth	SCC/mL	L/M region (G)	Teat region (G)	TLS	<i>E. coli</i>	<i>Klebsiella pneumoniae</i>	Other Enterobacteriaceae	Staphylococcus	Streptococcus	<i>Pseudomonas aeruginosa</i>	<i>Mycoplasmas</i>	Others
1	22/01/2008	506,000	0	0		+			CNS				<i>Acinetobacter</i>
2	07/02/2013	383,000	2	0		+		Citrobacter	CNS				
3	17/07/2006	685,000	1	0		+			CNS				
4	28/06/2010	934,000	1	2	P	+		Citrobacter	CNS				
5	11/05/2010	1,459,000	2	2				Enterobacter	CNS	<i>S. agalactiae</i>			
6	29/04/2009	3,597,000	2	3					CNS				
7	08/04/2007	509,000	1	2		+		Enterobacter	<i>S. aureus</i> /CNS				
8	05/02/2006	1,560,000	1	0		+			CNS		+		
9	24/12/2004	296,000	0	0		+	+		CNS				
10	21/07/2010		1	1		+		Citrobacter	CNS	<i>S. dysgalactiae</i> / <i>viridans</i>		+	
11	01/06/1994	1,888,000	0	2		+			CNS				
12	14/10/2009	2,061,000	2	3	P	+	+	Citrobacter	CNS/ <i>S. aureus</i>	<i>S. agalactiae</i>	+	+	<i>Gemella morbillorum</i> / <i>Acinetobacter</i>
13	28/08/2006	1,103,000	2	2		+		Citrobacter/ Enterobacter	CNS				
14	20/07/2010	651,000	1	1		+		Citrobacter	CNS	<i>S. viridans</i>			<i>Peptococcus indolicus</i> / <i>Acinetobacter</i>
15	06/04/2007	370,000	0	1		+		Enterobacter	CNS	<i>S. viridans</i>		+	<i>Enterococcus avium</i>
16	15/10/2009	851,000	1	2		+	+	Citrobacter	CNS	<i>S. bovis</i> ; <i>S. constellatus</i>		+	<i>Pediococcus acidilactici</i>
17	10/03/2005	2,074,000	3	3	P	+	+	Citrobacter	CNS	<i>S. bovis</i>			<i>Enterococcus avium</i> / <i>Acinetobacter</i>
18	01/09/2010	2,262,000	3	3		+		Enterobacter	CNS	<i>S. agalactiae</i>		+	
19	07/12/2006	743,000	1	2		+		Citrobacter/ Enterobacter	CNS	<i>S. viridans</i>		+	
20	05/02/2006	116,000	0	1	P	+			CNS	<i>S. uberis</i>			
21	11/07/2005	960,000	1	2	P	+			CNS	<i>S. uberis</i> ; <i>S. zooepidemicus</i>			
22	08/02/2007	578,000	0	1	P	+		Enterobacter	CNS	<i>S. uberis</i> ; <i>S. viridans</i>			
23	16/03/2011	2,538,000	2	3	P	+			CNS	<i>S. zooepidemicus</i> ; <i>S. viridans</i>			
24	18/02/2011	982,000	2	2	P			Enterobacter	CNS/ <i>S. aureus</i>	<i>S. zooepidemicus</i>			
25	04/04/2008	1,608,000	2	2	P	+			<i>S. aureus</i>	<i>S. zooepidemicus</i>			
26	12/02/2011	119,000	0	0		+			CNS/ <i>S. aureus</i>	<i>S. uberis</i>			
27	10/12/2008	1,342,000	2	3	P			Citrobacter	<i>S. aureus</i>	<i>S. zooepidemicus</i> ; <i>S. dysgalactiae</i>			
28	28/09/2012	565,000	1	1		+		Citrobacter	CNS	<i>S. uberis</i>			
29	02/09/2010	420,000	0	0		+		Citrobacter	CNS/ <i>S. aureus</i>	<i>S. uberis</i>			
30	01/01/1990	1,420,000	2	3	P				CNS	<i>S. uberis</i> ; <i>S. bovis</i>			

**Table 1.** (Continued) Results of SCC, histological and bacteriological analysis from 50 samples of buffalo chronic mastitis

Case number	Date of birth	SCC/mL	L/M region (G)	Teat region (G)	TLS	E. coli	Klebsiella pneumoniae	Other Enterobacteriaceae	Staphylococcus	Streptococcus	Pseudomonas aeruginosa	Mycoplasmas	Others
31	26/06/2004	2,200,000	3	3	P	+	Acinetobacter	CNS	S. viridans				Trichosporon asahii/ Acinetobacter
32	16/06/2010	1,334,000	2	3	P	+			S. bovis				
33	20/07/2006	1,025,000	2	2		+	Proteus/ Enterobacter		S. zooepidemicus		+		
34	13/04/2010	3,922,000	2	2	P	+	Enterobacter	S. aureus	S. viridans				Campylobacter coli
35	01/04/2003	1,734,000	2	2	P		Enterobacter						Trichosporon asahii/ Campylobacter coli
36	30/06/2010	4,100,000	3	3	P	+	Enterobacter	S. aureus					
37	23/05/2011	2,040,000	2	3	P	+			S. viridans				
38	05/03/2007	1,375,000	1	2	P	+		S. aureus	S. viridans				Acinetobacter
39	29/04/2010	2,150,000	2	2	P	+	Enterobacter	S. aureus			+		Acinetobacter
40	22/03/2011	3,682,000	2	3		+	Enterobacter						
41	23/03/2010	2,442,000	2	2		+	Enterobacter		S. viridans				
42	04/03/2010	60,000	0	0		+	Enterobacter		S. viridans				
43	13/10/2009	1,763,000	1	2	P		Enterobacter	S. aureus					Trichosporon asahii
44	28/07/2012	145,000	0	0		+	Enterobacter		S. bovis				
45	31/03/2008	246,000	0	1	P		Enterobacter		S. viridans				
46	23/01/2009	2,152,000	1	2		+	Enterobacter		S. bovis				
47	09/06/2005	209,000	0	1			Enterobacter		S. zooepidemicus				Campylobacter coli
48	25/01/2011	348,000	0	0			Enterobacter		S. agalactiae				Campylobacter coli
49	22/05/2010	649,000	0	0			Enterobacter	S. aureus	S. bovis				Campylobacter coli
50	29/01/2011	1,188,000	1	2	P		Enterobacter		S. bovis				Campylobacter coli

SCC, somatic cells count; L/M, low/medium region; Gi, infiltration grade; TLS, tertiary lymphoid structures; CNS, Coagulase-negative staphylococci; P, present.



### Bacteriological results

**Tables 1 and 2** summarize the results of bacteriological evaluation. Bacteria were found in all 50 buffalo udders examined (**Tables 1 and 2**), encompassing a wide range of Gram-positive as well as Gram-negative bacteria, often simultaneously within the same mammary gland. Among the Gram-negative isolates, *Escherichia coli* was present in 38/50 (76%) udders, comprising the following serogroups: *E. coli* O114 (n = 2), *E. coli* O120 (n = 5), *E. coli* O25 (n = 2), and *E. coli* O157 (n = 1). The remaining strains (28/38) were identified as generic *E. coli*. In addition, following organisms were also isolated from the 50 buffaloes examined: *Klebsiella pneumoniae* 4/50 (8%), *Acinetobacter* spp. 7/50 (14%), *Enterobacter* spp. 23/50 (46%), *Citrobacter* spp. 12/50 (24%), and *Proteus* spp. 1/50 (2%).

All udder samples (100%) were positive for *Pseudomonas* spp., and 4/50 (8%) were identified as *P. aeruginosa*. *Campylobacter* spp. isolated from 6/50 (12%) buffaloes were identified as *Campylobacter coli*. Considering the Gram-positive isolates, *Staphylococcus* spp. was isolated in all 50 examined buffalo udders (100%); 14/50 (28%) were identified as *S. aureus*. *Streptococcus* spp. was found in 43/50 (86%) udders, and 8/43 (19%) were identified as *S. bovis*, 4/43 (9%) as *S. agalactiae*, 2/43 (5%) as *S. dysgalactiae*, 14/43 (33%) as *S. viridans*, 7/43 (16%) as *S. uberis*, and 7/43 (16%) as *S. zooepidemicus*. Finally, 7/50 (14%) mammary glands were positive for *Mycoplasma* spp. In contrast, potential pathogens such as *Listeria monocytogenes*, *Salmonella* spp., *Prototheca* spp. and *Clostridium* spp. were not found.

**Table 2.** Bacteria isolated from udders of 50 buffaloes

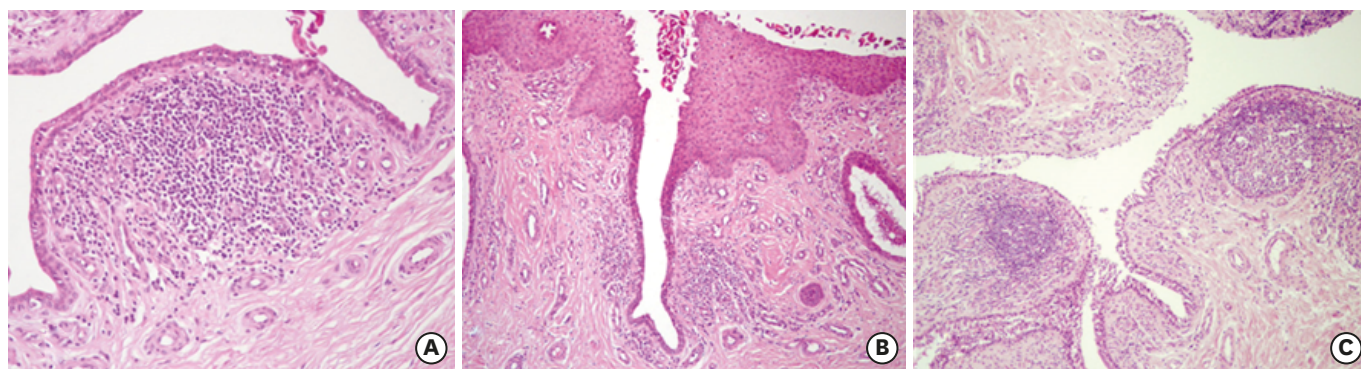
Bacteria	No. (Positive/Buffalo)
<i>E. coli</i>	38/50
<i>E. coli</i> O114	2/38
<i>E. coli</i> O157	1/38
<i>E. coli</i> O120	5/38
<i>E. coli</i> O25	2/38
<i>Klebsiella pneumoniae</i>	4/50
Other Enterobacteriaceae	42/50
<i>Acinetobacter baumannii</i>	7/50
<i>Enterobacter</i> spp.	22/50
<i>Citrobacter</i> spp.	13/50
<i>Proteus</i> spp.	1/50
<i>Staphylococcus</i> spp.	50/50
<i>S. aureus</i>	14/50
<i>Streptococcus</i> spp.	43/50
<i>S. bovis</i>	8/43
<i>S. agalactiae</i>	4/43
<i>S. dysgalactiae</i>	2/43
<i>S. viridans</i>	15/43
<i>S. zooepidemicus</i>	7/43
<i>S. uberis</i>	7/43
<i>Pseudomonas</i> spp.	50/50
<i>P. aeruginosa</i>	4/50
<i>Mycoplasma</i> spp.	7/50
<i>Campylobacter</i> spp.	6/50
<i>C. coli</i>	3/6
Others	
<i>Gemella morbillorum</i>	1/50
<i>Streptococcus constellatus</i>	1/50
<i>Peptococcus indolicus</i>	1/50
<i>Peptostreptococcus</i> spp.	1/50
<i>Trichosporon asahii</i>	3/50
<i>Enterococcus avium</i>	2/50

### Anatomical and histological features

The anatomical and histological features are summarized in **Table 1**. Totally, 2 of the 50 udders (4%) were entirely normal and exhibited neither anatomical nor histological lesions (case number: 9, 26 in **Table 1**); 2 (4%) udders encompassed obvious anatomical and histological lesions (case number: 32, 36 in **Table 1**), with swollen and tense affected quarters and cisterns and ducts filled with serous, floccular or even purulent secretions. Histologically, a remarkable interstitial edema was evident with an extensive migration of neutrophils into the interlobular tissue and the secretory acini. All signs were compatible with diagnosis of acute mastitis.

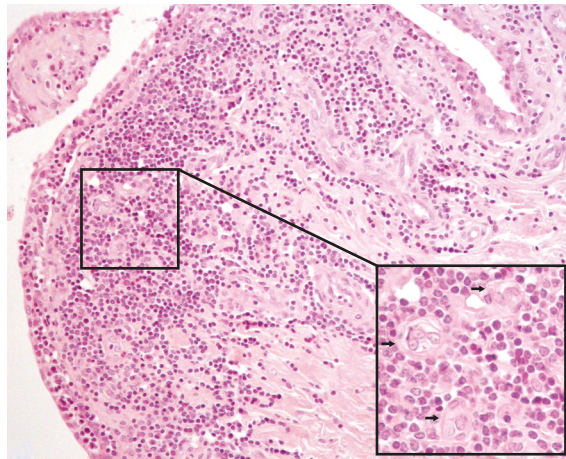
In the remaining 46 (92%) udders, gross anatomical lesions were absent, while histological changes characterized by infiltration of lymphocytes, plasma cells and macrophages, and diffused proliferation within the interstitial tissue, were evident around the large and small ducts, the alveoli in the middle and low gland area, as well as in the teat region in each quarter of mammary glands. Inflammatory infiltrates often reached the ductal epithelium (**Fig. 1A**). Large ducts appeared dilated and contained exfoliated epithelial cells, neutrophils and macrophages; in the ductal lumina, papillary epithelial projections were often present. Mature fibrous connective tissues were seen to have infiltrated the interstitial space, which often showed hyaline features, especially in the teat region. Fibrous thickening of the teat duct with reduction of lumen was also observed in many samples (**Fig. 1B**). In each quarter of the mammary gland, very few lymphocytes were observed in the higher region. Based on these findings, all 46 udders were classified as affected by chronic mastitis. Of these 46 udders, the infiltration grade (G) was classified as follows: G0, present in all (100%) high regions, 22% (10/46) in middle/low gland regions and 17% (8/46) in teat regions; G1, present 35% (16/46) in middle/low gland regions and 20% (9/46) in teat regions; G2, present 37% (17/46) in middle/low gland regions and 41% (19/46) in teat regions; G3, present 6% (3/46) in the middle/low gland regions and 22% (10/46) in teat regions.

The infiltration grade was similar in each quarter of individual mammary glands. Intriguingly, in 22 of the 46 udders (48%), in the low gland and teat regions, sparse lymphocytes, plasma cells and macrophages organized themselves into aggregates to form follicle-like structures, which were considered as TLSs. These were variable in size and were sometimes found as sub-epithelial nodules. They were characterized by a distinct germinal center, a peripheral small, dark and densely packed lymphocyte mantle without



**Fig. 1.** Chronic buffalo mastitis. Haematoxylin and eosin staining: (A) Severe lymphocytes and plasma cells infiltrate reaches the epithelium in the teat region (10 $\times$ ); (B) Fibrous connective tissue with hyaline features is evident under the epithelium. Infiltration of lymphocytes is also evident (10 $\times$ ); (C) Tertiary lymphoid structures are evident in the teat region (5 $\times$ ).





**Fig. 2.** Chronic buffalo mastitis. Haematoxylin and eosin staining: diffuse subepithelial infiltration of lymphocytes and numerous high endothelial venules (arrows) are evident (20 $\times$ ). Inset: high endothelial venules are better showed.

any fibrous encapsulation, and high endothelial venules (HEVs) with a cuboidal appearance (**Fig. 1C**). HEV were also evident in some samples in which the proliferation of lymphocytes and plasma cells were not organized as follicular features, and these were considered as developing TLSs (**Fig. 2**).

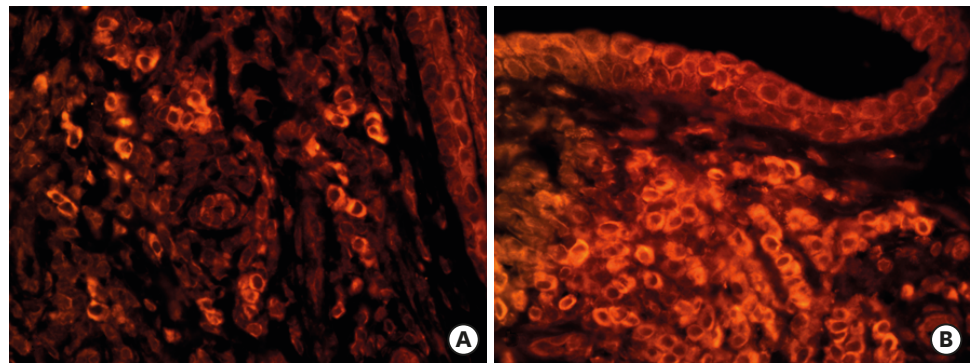
TLS were seen in 2/10 (20%) G0, 6/16 (37%) G1, 13/17 (76%) G2, and 2/3 (70%) G3 middle/low gland areas, and in 3/9 (33%) G1, 11/19 (58%) G2 and 8/10 (80%) G3 teat regions. No TLSs were observed in teat regions classified as G0. With respect to Gram-negative isolates in the 46 udders with chronic mastitis, TLSs were observed in the presence of *Escherichia coli* in 14/34 (41%), *Klebsiella pneumoniae* in 2/3 (67%), *Citrobacter* spp. in 4/12 (33%), *Enterobacter* spp. in 9/22 (40%), and *Acinetobacter* spp. in 4/7 (57%). TLSs were also identified in 3/3 (100%) *Pseudomonas aeruginosa* and 3/6 (50%) *Campylobacter coli* infections. Among the 46 Gram-positive infected udders with chronic mastitis, TLSs were present in infections with *Staphylococcus aureus* in 8/12 (67%), *Streptococcus bovis* in 3/7 (43%), *Streptococcus agalactiae* in 1/3 (33%), *Streptococcus dysgalactiae* in 1/2 (50%), *S. viridans* in 8/13 (61%), *S. uberis* in 2/4 (50%), and *S. zooepidemicus* in 6/7 (86%). Finally, TLSs were observed in 1/7 (14%) *Mycoplasma* infected udders. Frequently, lymphocytes in transit across the epithelial basement membrane (intra-epithelial lymphocytes) were also observed, especially in proximity of TLSs. Furthermore, TLSs were observed in 2 samples of acute mastitis (case number: 32 and 36) and were associated with *E. coli* (2/2), *Enterobacter* infection, *Staphylococcus aureus* and *Streptococcus bovis* (1/2). In 2 samples classified as normal (case number: 9 and 26), TLSs were absent.

### Immunofluorescence staining

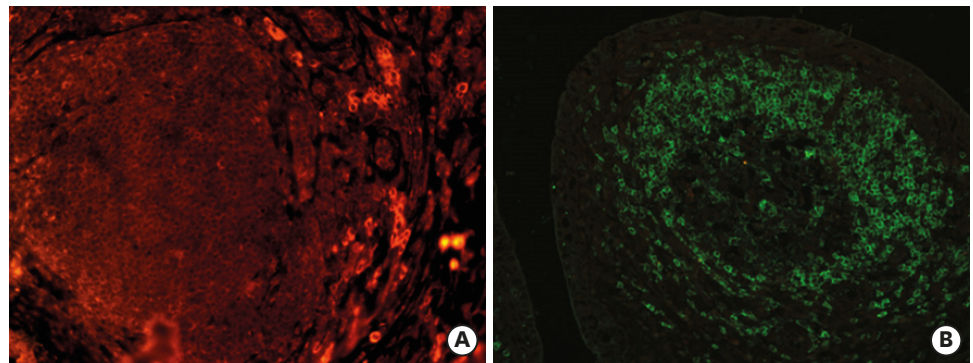
CD8<sup>+</sup> lymphocytes were predominant as compared to CD4<sup>+</sup> lymphocytes, and occurred in close contact with the epithelium and between epithelial cells (**Fig. 3A and B**). In TLSs, scattered CD8<sup>+</sup> lymphocytes were found in the mantle cells (**Fig. 4A**) and consistent CD79<sup>+</sup> lymphocytes were found in the germinal center (**Fig. 4B**).

### Correlation between infiltration grade and SCCG

Pearson's coefficient was not significant ( $r = 0.35$ ) in the high part of the mammary gland, but was statistically significant in the middle-low part ( $r = 0.81$ ) and in the teat region ( $r = 0.92$ ).



**Fig. 3.** Chronic buffalo mastitis. Immunofluorescence staining: (A) few CD4+ infiltrating lymphocytes are evident in the interstitial tissue of mammary gland (red TRITC immunofluorescence, 40×); (B) CD8+ lymphocytes in close contact with the epithelium and between epithelial cells are evident (red TRITC immunofluorescence, 40×). TRITC, tetramethylrhodamineisothiocyanate.



**Fig. 4.** Chronic buffalo mastitis. TLS, Immunofluorescence staining: (A) TLS: scattered CD8+ lymphocytes in mantle cells (red tetramethylrhodamineisothiocyanate immunofluorescence, 20×); (B) TLS: consistent CD79+ lymphocytes in the germinal center region (green fluorescein isothiocyanate immunofluorescence, 20×). TLS, tertiary lymphoid structure.

### Correlation between infiltration grade and TLS

Chi-Square trend value was 5.207 in the low/middle mammary gland region ( $p = 0.02$ ) and was 13,672 in the teat region ( $p = 0.0002$ ).

### Correlation between isolated bacteria and TLS

Significant ( $p = 0.005$ ) correlation between isolated bacteria and TLSs was only found in cases of *Streptococcus uberis* infection.

## DISCUSSION

Mastitis is a major problem in dairy cows and, as shown in the current study, also in buffaloes. Most remarkably, all 50 investigated buffalo udders (100%) were found bacteriologically positive for *Pseudomonas* spp. and *Staphylococcus* spp.; in addition, 86% were positive for *Streptococcus* spp., 76% for *E. coli* and 46% for *Enterobacter* spp. Among the udders positive for *Staphylococcus* spp. and *Streptococcus* spp., 28% were identified as *S. aureus* and 33% as *S. viridans*. These results confirm that mastitis in the group of buffaloes examined by us were mostly caused by environmental mastitis pathogens. Thus, our findings suggest a similar pathogenesis in buffaloes; that is, once established in the udder, environmental

pathogens can persist for extended periods causing continuous infection and chronic inflammatory changes with fibrosis in the mammary tissue [15,21]. This causes an increased milk SCC and can lead to reduced milk production and early culling.

Histological and immunofluorescence analysis of the udders affected by chronic sub-clinical mastitis (92%) showed a predominance of CD8+ lymphocytes mainly localized in close contact with the ductal epithelium and between epithelial cells, preferably in the middle, the low gland and in the teat regions. This finding indicates that, similar to that suggested in cows, the CD8+ lymphocytes play an important role in buffalo udders in the local immune response as cytotoxic cell scavengers, removing old or damaged secretory cells, thereby reducing susceptibility of the gland to infections [22]. The correlation of the infiltration grade with SCC values supports this hypothesis. Furthermore, CD8+ lymphocytes are thought to control or modulate the immune response to bacterial infections and have an important function in the chronic status of coliform intra-mammary infections [23]. Contrarily, several studies have demonstrated that the CD8+ lymphocytes activated during bacterial infections down-regulate the host immune response [12,24]. Evaluation of lacteal secretions from mammary glands of dairy cows infected with *S. aureus* revealed a subpopulation of activated CD8+ lymphocytes capable of altering or suppressing the proliferative responses of CD4+ lymphocytes [25,26]. Such hypo-responsiveness of lymphocyte interaction mediated in part by CD8+ lymphocyte activation by lecithins and bacterial antigens has been demonstrated in bovine mammary glands infected with *S. aureus*; thus, it is suggestive that CD8+ lymphocytes activated by antigens, such those of *S. aureus*, may enhance infectious mastitis and may contribute to its persistence [27].

In dairy cows, composition of the lymphocyte subpopulations vary during the lactation cycle [25,27,28], where CD8+ lymphocytes are predominant in lactating udders, while CD4+ lymphocytes are over-expressed during the dry period. During the lactation cycle, CD8+ lymphocytes begin to increase in the peri-partum [29], reach a peak in the early lactation period, and decrease during late lactation [28].

The predominance of CD8+ lymphocytes observed in our study conducted on late lactating udders, confirms the presence of chronic mastitis.

Studies report observing a peculiar feature in 48% of bubaline mastitis; the sparse inflammatory infiltrates (lymphocytes, plasma cells, and macrophages) organize themselves in newly formed follicular aggregates, exhibiting distinctive histological features of TLSs. TLSs were previously described in urothelial cancer of buffalo [30] and in the endometrium of pregnant dairy cows [31]. In human medicine, they are known to be present in some organ specific disorders [32] such as infectious and neoplastic diseases [20,33,34]. In our samples, these aggregates showed varying levels of organization (including formation of HEVs), which are characteristic for TLSs [35]. The differences in bystander-infiltrating lymphocytes and TLSs is not yet clearly defined but seems to reside in the degree of internal organization of the TLSs. However, the globular structuration with distinct B and T cell compartments, the presence of a network of fibroblast reticular cells as well as follicular dendritic cells and, not in the least, the presence of HEV, are highly indicative features for TLSs [19]. TLSs also shares numerous similarities with SLO. However, the order of events and the molecular mechanisms responsible for postnatal TLS development are significantly different from those regulating lymph node development, and partially different from those of the spleen that are present before birth [19]. The absence of a defined capsule and of an independent vascular network (it is not apparent if lymphatic vessels are afferent and/or efferent) represent the main morphological distinctive

elements. The pathophysiological significance of TLSs is still unclear. They are considered as ectopic and local dynamic structures developing from scattered inflammatory infiltrates that aggregate and eventually organize into lymphofollicular structures. TLS formation is now recognized as a common feature of many chronic inflammatory diseases and might have a role in maintaining the immune responses against persistent antigens [14,36]. During chronic inflammation, a cross talk between stromal cells and recruited immune cells can be established, which is also a necessary requirement for the formation of TLSs. Stromal cells, stimulated by inflammatory cytokines produced by the immune cells, could acquire lymphoid tissue-like characteristic able to provide local structure and survival mechanism to the incoming immune cells [37]. It has been suggested that the stimulus that triggers TLS formation in infected tissues is the causative agent itself [17].

In our study, the presence of TLSs increases progressively from low to severe infiltration grade, and the values are statistically significant both in the low/middle mammary gland and in the teat region, thereby confirming that TLSs are found in highly infiltrated tissues [17]. In the udders examined by us, TLSs were present without apparent correlation to specific bacteria types, except for a significant increase in the presence of *Streptococcus uberis* infection. It is thus reasonable to suggest that environmental mastitis pathogens stimulate the adaptive immune responses, leading to chronic inflammation in which TLSs develop. In our samples, TLSs were mainly present in the low and middle mammary gland and the teat regions. The presence of TLSs mostly in the teat region is suggestive of their role as the first line of immune defense in the ductal area, which is the entry point of germs. Previous studies in sub-clinically affected or healthy cows without mastitis reported complete absence of CD4+ and CD8+ lymphocytes in the teat region [3,38]. The presence of T-lymphocyte infiltrates and TLSs, especially in the teat region, as shown in this study (for the first time) in buffalo chronic mastitis, can be a further indication that tertiary lymphoid structures (TLSs) play a protective function by inducing and maintaining the immune response against infectious agents near their entry point [17]. In fact, it can be envisaged that when the immune system fails to mount an efficient response against an infectious agent, the efficacy of response is likely to increase if the crucial cells of the immune response are located at or near the site of antigen deposition. TLSs can therefore represent the attempt of stromal cells to respond locally and efficiently to the increased request of survival factors for the incoming lymphocytes [37]. Further studies are required to improve the knowledge on TLSs and their potential role in the pathogenesis of chronic mastitis in attempting to reduce or to prevent this serious problem of the buffalo dairy industry.

## ACKNOWLEDGMENTS

We gratefully thank Raffaele Ilsami for histology and Antonio Calamo for his support with confocal laser scanning image acquisition.

## REFERENCES

1. Bradley A. Bovine mastitis: an evolving disease. *Vet J* 2002;164:116-128.  
[PUBMED](#) | [CROSSREF](#)
2. Tripaldi C, Palocci G, Miarelli M, Catta M, Orlandini S, Amatiste S, Di Bernardini R, Catillo G. Effects of mastitis on buffalo milk quality. *Asian-Australas J Anim Sci* 2010;23:1319-1324.  
[CROSSREF](#)



3. Asai K, Kai K, Rikiishi H, Sugarawa S, Maruyama Y, Yamaguchi T, Ohta M, Kumagai K. Variation in CD4 T and CD8 T lymphocyte subpopulation in bovine mammary gland secretions in bovine mammary gland secretions during lactating and non-lactating periods. *Vet Immunol Immunopathol* 1998;16:51-61.  
[PUBMED](#) | [CROSSREF](#)
4. Radostits OM, Gay CC, Hinchcliff KW, Constable PD. *Veterinary Medicine: a Text Book of the Diseases of Cattle, Horses, Sheep, Pigs and Goats*. Elsevier Saunders, New York, 2007.
5. Duarte CM, Freitas PP, Bexiga R. Technological advances in bovine mastitis diagnosis: an overview. *J Vet Diagn Invest* 2015;27:665-672.  
[PUBMED](#) | [CROSSREF](#)
6. Royster E, Wagner S. Treatment of mastitis in cattle. *Vet Clin North Am Food Anim Pract* 2015;31:17-46.  
[PUBMED](#) | [CROSSREF](#)
7. Preethirani PL, Isloor S, Sundareshan S, Nuthanalakshmi V, Deepthikiran K, Sinha AY, Rathnamma D, Nithin Prabhu K, Sharada R, Mukkur TK, Hegde NR. Isolation, biochemical and molecular identification, and in-vitro antimicrobial resistance patterns of bacteria isolated from bubaline subclinical mastitis in South India. *PLoS One* 2015;10:e0142717.  
[PUBMED](#) | [CROSSREF](#)
8. Galiero G. The control of environmental mastitis. *Bubalus Bubalis* 2002;1:26-28.
9. Moroni P, Sgoifo Rossi C, Pisoni G, Bronzo V, Castiglioni B, Boettcher PJ. Relationships between somatic cell count and intramammary infection in buffaloes. *J Dairy Sci* 2006;89:998-1003.  
[PUBMED](#) | [CROSSREF](#)
10. Guccione J, Cosandey A, Pesce A, Di Loria A, Pascale M, Piantedosi D, Steiner A, Graber HU, Ciaramella P. Clinical outcomes and molecular genotyping of *Staphylococcus aureus* isolated from milk samples of dairy primiparous Mediterranean buffaloes (*Bubalus bubalis*). *J Dairy Sci* 2014;97:7606-7613.  
[PUBMED](#) | [CROSSREF](#)
11. Guccione J, Perreten V, Steiner A, Thomann A, Pesce A, Ciaramella P, Bodmer M. Role of *Streptococcus plurianimalium* in Mediterranean buffaloes (*Bubalus bubalis*) with different udder health statuses. *J Dairy Sci* 2016;99:2945-2949.  
[PUBMED](#) | [CROSSREF](#)
12. Burton JL, Erskine RJ. Immunity and mastitis. Some new ideas for an old disease. *Vet Clin North Am Food Anim Pract* 2003;19:1-45.  
[PUBMED](#) | [CROSSREF](#)
13. Drayton DL, Liao S, Mounzer RH, Ruddle NH. Lymphoid organ development: from ontogeny to neogenesis. *Nat Immunol* 2006;7:344-353.  
[PUBMED](#) | [CROSSREF](#)
14. Hjelmström P. Lymphoid neogenesis: de novo formation of lymphoid tissue in chronic inflammation through expression of homing chemokines. *J Leukoc Biol* 2001;69:331-339.  
[PUBMED](#)
15. Hogan JS, Gonzalez RN, Harmon RJ, Nickerson SC, Oliver SP, Pankey JW, Smith KL. *Laboratory Handbook on Bovine Mastitis*. National Mastitis Council, Inc., Madison, 1999.
16. Ruddle NH. Lymphoid neo-organogenesis: lymphotoxin's role in inflammation and development. *Immunol Res* 1999;19:119-125.  
[PUBMED](#) | [CROSSREF](#)
17. Aloisi F, Pujol-Borrell R. Lymphoid neogenesis in chronic inflammatory diseases. *Nat Rev Immunol* 2006;6:205-217.  
[PUBMED](#) | [CROSSREF](#)
18. Goc J, Fridman WH, Sautès-Fridman C, Dieu-Nosjean MC. Characteristics of tertiary lymphoid structures in primary cancers. *OncoImmunology* 2013;2:e26836.  
[PUBMED](#) | [CROSSREF](#)
19. Neyt K, Perros F, GeurtsvanKessel CH, Hammad H, Lambrecht BNNeyt. Tertiary lymphoid organs in infection and autoimmunity. *Trends Immunol* 2012;33:297-305.  
[PUBMED](#) | [CROSSREF](#)
20. Wirsing AM, Rikardsen OG, Steigen SE, Uhlin-Hansen L, Hadler-Olsen E. Characterisation and prognostic value of tertiary lymphoid structures in oral squamous cell carcinoma. *BMC Clin Pathol* 2014;14:38.  
[PUBMED](#) | [CROSSREF](#)
21. Döpfer D, Nederbragt H, Almeida RA, Gastra W. Studies about the mechanism of internalization by mammary epithelial cells of *Escherichia coli* isolated from persistent bovine mastitis. *Vet Microbiol* 2001;80:285-296.  
[PUBMED](#) | [CROSSREF](#)



22. Taylor BC, Dellinger JD, Cullor JS, Stott JL. Bovine milk lymphocytes display the phenotype of memory T cells and are predominantly CD8+. *Cell Immunol* 1994;156:245-253.  
[PUBMED](#) | [CROSSREF](#)
23. Shafer-Weaver KA, Sordillo LM. Enhancing bactericidal activity of bovine lymphoid cells during the periparturient period. *J Dairy Sci* 1996;79:1347-1352.  
[PUBMED](#) | [CROSSREF](#)
24. Oviedo-Boyo J, Valdez-Alarcón JJ, Cajero-Juárez M, Ochoa-Zarzosa A, López-Meza JE, Bravo-Patiño A, Baizabal-Aguirre VM. Innate immune response of bovine mammary gland to pathogenic bacteria responsible for mastitis. *J Infect* 2007;54:399-409.  
[PUBMED](#) | [CROSSREF](#)
25. Park YH, Fox LK, Hamilton MJ, Davis WC. Suppression of proliferative response of BoCD4+ T lymphocytes by activated BoCD8+ T lymphocytes in the mammary gland of cows with *Staphylococcus aureus* mastitis. *Vet Immunol Immunopathol* 1993;36:137-151.  
[PUBMED](#) | [CROSSREF](#)
26. Sordillo LM. Factors affecting mammary gland immunity and mastitis susceptibility. *Livest Prod Sci* 2005;98:89-99.  
[CROSSREF](#)
27. Park YH, Fox LK, Hamilton MJ, Davis WC. Bovine mononuclear leukocyte subpopulations in peripheral blood and mammary gland secretions during lactation. *J Dairy Sci* 1992;75:998-1006.  
[PUBMED](#) | [CROSSREF](#)
28. Asai K, Komine Y, Kozutsumi T, Yamaguchi T, Komine K, Kumagai K. Predominant subpopulations of T lymphocytes in the mammary gland secretions during lactation and intraepithelial T lymphocytes in the intestine of dairy cows. *Vet Immunol Immunopathol* 2000;73:233-240.  
[PUBMED](#) | [CROSSREF](#)
29. Mallard BA, Dekkers JC, Ireland MJ, Leslie KE, Sharif S, Vankampen CL, Wagter L, Wilkie BN. Alteration in immune responsiveness during the peripartum period and its ramification on dairy cow and calf health. *J Dairy Sci* 1998;81:585-595.  
[PUBMED](#) | [CROSSREF](#)
30. Maiolino P, Ozkul A, Sepici-Dincel A, Roperto F, Yücel G, Russo V, Urraro C, Lucà R, Riccardi MG, Martano M, Borzacchiello G, Esposito I, Roperto S. Bovine papillomavirus type 2 infection and microscopic patterns of urothelial tumors of the urinary bladder in water buffaloes. *BioMed Res Int* 2013;2013:937918.  
[PUBMED](#) | [CROSSREF](#)
31. Lucy MC, Evans TJ, Poock SE. Lymphocytic foci in the endometrium of pregnant dairy cows: characterization and association with reduced placental weight and embryonic loss. *Theriogenology* 2016;86:1711-1719.  
[PUBMED](#) | [CROSSREF](#)
32. Takemura S, Braun A, Crowson C, Kurtin PJ, Cofield RH, O'Fallon WM, Goronzy JJ, Weyand CM. Lymphoid neogenesis in rheumatoid synovitis. *J Immunol* 2001;167:1072-1080.  
[PUBMED](#) | [CROSSREF](#)
33. Coronella JA, Spier C, Welch M, Trevor KT, Stopeck AT, Villar H, Hersh EM. Antigen-driven oligoclonal expansion of tumor-infiltrating B cells in infiltrating ductal carcinoma of the breast. *J Immunol* 2002;169:1829-1836.  
[PUBMED](#) | [CROSSREF](#)
34. Murakami J, Shimizu Y, Kashii Y, Kato T, Minemura M, Okada K, Nambu S, Takahara T, Higuchi K, Maeda Y, Kumada T, Watanabe A. Functional B-cell response in intrahepatic lymphoid follicles in chronic hepatitis C. *Hepatology* 1999;30:143-150.  
[PUBMED](#) | [CROSSREF](#)
35. Barone F, Gardner DH, Nayar S, Steinthal N, Buckley CD, Luther SA. Stromal fibroblasts in tertiary lymphoid structures: a novel target in chronic inflammation. *Front Immunol* 2016;7:477.  
[PUBMED](#) | [CROSSREF](#)
36. Junt T, Scandella E, Ludewig B. Form follows function: lymphoid tissue microarchitecture in antimicrobial immune defence. *Nat Rev Immunol* 2008;8:764-775.  
[PUBMED](#) | [CROSSREF](#)
37. Buckley CD, Barone F, Nayar S, Bénézéch C, Caamaño J. Stromal cells in chronic inflammation and tertiary lymphoid organ formation. *Annu Rev Immunol* 2015;33:715-745.  
[PUBMED](#) | [CROSSREF](#)
38. Sordillo LM, Shafer-Weaver K, DeRosa D. Immunobiology of the mammary gland. *J Dairy Sci* 1997;80:1851-1865.  
[PUBMED](#) | [CROSSREF](#)