

Linking Dentistry and Chronic Inflammatory Autoimmune Diseases – Can Oral and Jawbone Stressors Affect Systemic Symptoms of Atopic Dermatitis? A Case Report

Fabian Schick, Johann Lechner , Florian Notter

Clinic for Integrative Dentistry, Munich, Germany

Correspondence: Fabian Schick, Clinic for Integrative Dentistry, Gruenwalder Str. 10A, Munich, 81547, Germany, Tel +49 89 697 00 55, Email drfabischick@outlook.de

Background: This case report demonstrates the value of ultrasound measurements, and immunological and toxicological diagnostics in addition to current x-ray imaging procedures to diagnose hidden oral and maxillofacial infections. Using a clear scheme shows the procedure of the authors' steps. The positive impact on the patient's dermatological clinical picture is shown. Functional regeneration using metal-free ceramic implants and autologous bone augmentation is demonstrated. After a healing period, a postoperative control took place.

Question: Are chronic inflammatory and chronic toxic stressors from the oral region affecting the patient's state of health and dermatological symptoms?

Patients and Methods: A 52 year old female suffering from neurodermatitis, who had been therapy-resistant for several years, was rehabilitated by oral surgery and prosthetics. Radiological examinations with orthopantomogram (OPG) and three-dimensional imaging (DVT/CBCT) were inconclusive for possible jawbone inflammatory sites. Immunological, toxicological diagnostics and trans-alveolar bone densitometry with ultrasound (TAU), were able to show immunological and toxicological stressors and areas of reduced bone density. Bone densitometry with ultrasound raised the suspicion of silent inflammations in the jawbone with potentially increased cytokine levels.

Results: For the patient incompatible materials, teeth with increased toxin exposure and surrounding softened, fatty, ischaemic bone was removed. Histologies and cytokine profiles were obtained. The resulting defects were functionally regenerated using ceramic implants and autologous augmentation. The cytokine profiles showed significantly elevated RANTES/CCL5, confirming the need for surgical intervention. The patient's atopic dermatitis improved significantly in this case.

Summary: Individualized immunological and toxicological diagnostics and trans-alveolar bone density bone densitometry with ultrasound (TAU) identified immunological and toxicological stressors as well as reduced bone density with increased cytokine levels. A therapy-resistant neurodermatitis improved significantly after treatment.

Conclusion: This case report illustrates the need for patient-specific and individualized examinations that link dentistry more closely with other medical conditions in order to clarify possible interactions.

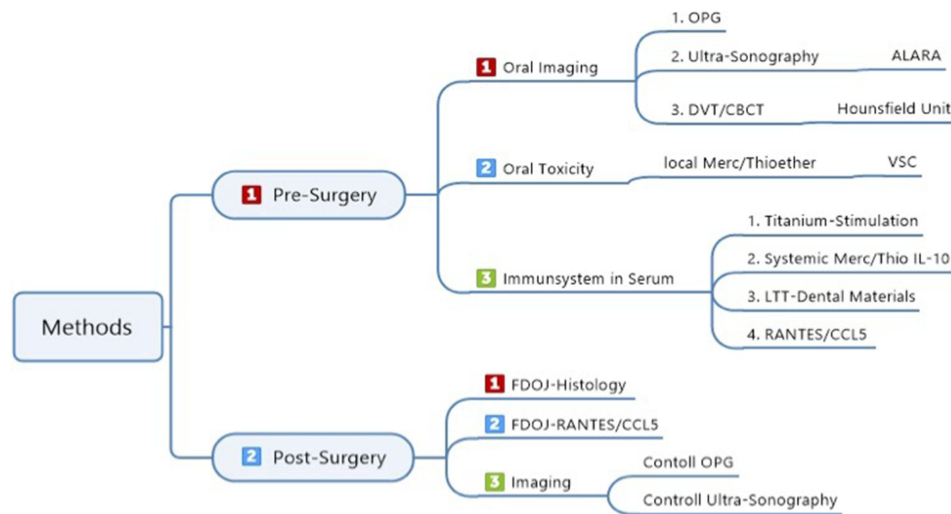
Keywords: atopic dermatitis, CCL5/RANTES, osteoimmunology, ceramic implants, autologous augmentation, silent inflammation, FDOJ, trans alveolar ultrasonography

Introduction

With increasing numbers of chronic-systemic, autoimmune diseases and multimorbidities,^{1–3} health care systems regularly reach their limits.^{1,4} While the patient's quality of life is severely affected by these diseases, causes for the rising numbers often remain unclear.⁵

Interventions in sensitively regulated systems are capable to throw regulations out of balance. Self-healing and compensation of chronic diseases may be suppressed in dysregulated systems. By recovering regulation through

Graphical Abstract



eliminating immunological and toxicological stressors, compensation capacity could be strengthened. Surprising successes of the integrative-complementary therapy approach, which cannot be directly explained causally, strengthen this medical approach.⁶

This is also relevant for neurodermatitis or atopic eczema, a chronic inflammatory skin disease, that can appear in acute and subacute phases. It often affects the scalp, face, and hands and is accompanied by severe itching. Neurodermatitis for that is affecting patient's quality of life.^{7,8} This common chronic skin disease is affecting up to 12% of total population.⁷

Question

This case report highlights possible links between immunological, toxic, and chronic inflammatory stressors in the oral and maxillofacial region and excessive cytokine expressions, chronic diseases and immunological disorders. The associated pathologies are little known, because they often do not clearly show up radiographically. Can further diagnostics and new methods such as trans-alveolar bone densitometry (TAU) with ultrasound clarify these hidden connections? And what other tests (RANTES/cytokines/Titanium/etc.) can be utilized to confirm the type/intensity of the stressor?

Patients and Methods

Case of the Patient

At the beginning of November 2021, a middle-aged female patient presents in our clinic. She has been suffering from eczema on her body, arms, legs and face for years (Figure 1). The woman's quality of life is significantly reduced.

Dermatologically, neurodermatitis was diagnosed and treated with the following methods: Baths in sodium chloride, systemic and local cortisone treatments, antibiotic therapies, and various forms of nutritional changes. These therapies led to temporary relief of skin reactions and itching but could not permanently eliminate or cure the symptoms. Over time, therapy-resistance resistance set in, and inflammatory phases increasingly intensified.

As a last attempt, the patient presented in our practice clinic with the request to clarify to what extent local oral inflammatory stressors could be contributing to systemic inflammation. Other allergies were not known to date.

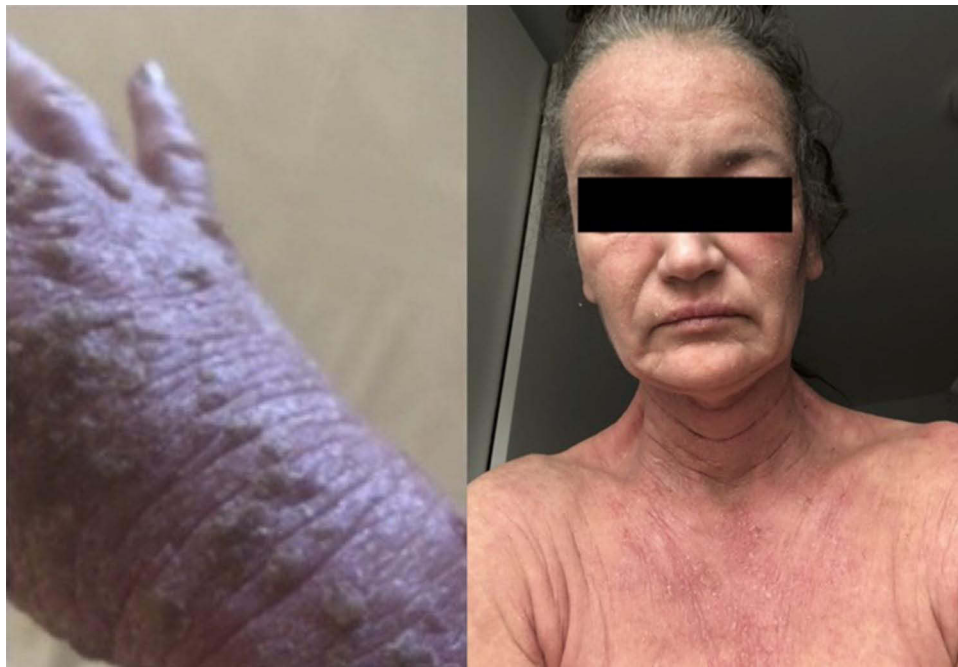

Figure 1 Dermatological symptoms of the patient's arm and face.

Materials and Methods

A comprehensive examination of the oral and maxillary region was performed to identify undiscovered inflammatory stressors that could be contributing to the dermatological symptoms. The patient was informed in advance that examination methods and surgical techniques would be scientifically discussed during the procedure. The patient gave written consent to participate in this case report and to the use of extraoral and intraoral clinical pictures.

The following scheme is intended to illustrate examination steps to diagnose and clarify inflammatory stressors and exclude possible immunologically and toxicologically relevant trigger factors in the maxillo-facial region.

The patient gave its generous agreement to publish the images of her disease and confirmed the written informed consent for us to publish the case details and images. An institutional approval was not required.

Two-Dimensional Radiological Diagnostics (OPG)

The two-dimensional radiographic image (OPG) shows endodontically treated teeth at 25, 34, 45 and 46 after hemisection and titanium implants at 35 and 36. The posterior areas show prosthetic restorations and small radio-opacities in region 48/49 (Figure 2).

Transalveolar Bone Densitometry (TAU) with Ultrasound

After the initial clinical examination excluded acute inflammation, the widely discussed radiographic presentation of chronic inflammatory jawbone pathologies led to further clarification.⁹ In order to follow the ALARA principle,¹⁰ which is part of the Radiation Protection Act, and to clarify possible bone marrow defects or bone marrow edema, ultrasound sonography was performed (Figure 3).^{11,12}

This preliminary screening shows reduced bone density (red) areas in the wisdom tooth areas, around the endodontically treated teeth and the implants. Reference areas of regular bone density (green) are the bone areas around the healthy, vital teeth (Figure 2).

Three-Dimensional Radiographic Image (DVT/CBCT)

In order to verify the areas of reduced bone density revealed by ultrasound TAU and the resulting suspicion of fatty degenerative osteolysis of the jawbone (FDOJ) with digital bone density measurements according to the validated

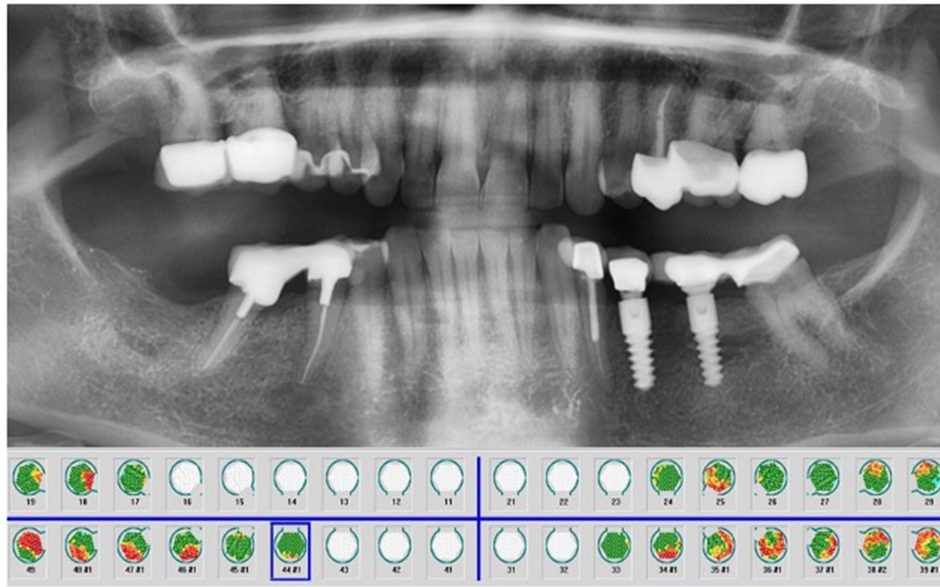


Figure 2 Two-dimensional radiographic imaging - OPG (top image) and imaging by trans-alveolar bone densitometry (TAU) with ultrasound: green corresponds to the solid and dense alveolar bone; red corresponds to reduced bone density with suspected osteolytic areas.

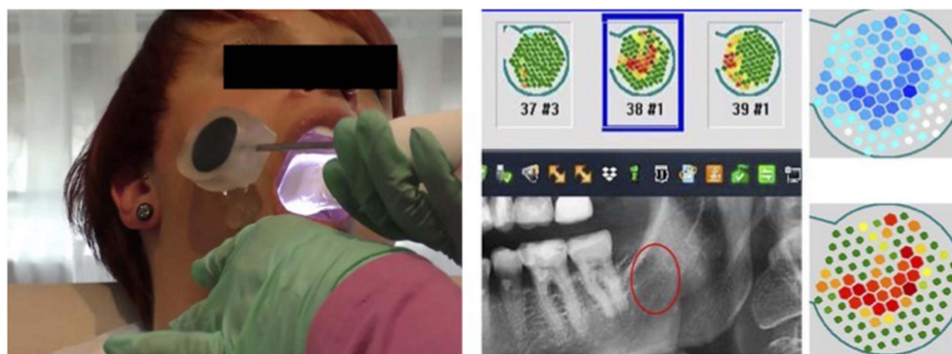

Figure 3 Illustration of a TAU measurement (left image) with ultrasound transmitter extraoral and illuminated ultrasound receiver intraoral. The right image shows the colored imaging of bone density in a single measurement with green for solid and healthy cancellous bone, and red and orange for reduced bone density in the area 38/39 (red circle) as an example.

Hounsfield Units (HU) and to create an implantologic-prosthetic treatment plan,¹³ a three-dimensional radiographic DVT/CBCT was taken.

The digital bone density measurements taken confirmed the results in the ultrasound TAU. In addition, small radiopaque foreign bodies were detected in the wisdom tooth region 48. Figure 4 shows the measurement of reduced bone density value surrounding a foreign body with the HU value of -273 and therefore a possible malfunction of the local bone metabolism.

Local Measurement of Volatile Hydrogen Sulfide Toxins on the Endodontic Tooth

Resident anaerobic bacteria such as *Porphyromonas gingivalis*, *Prevotella intermedia*, *Fusobacterium nucleatum* or *Treponema denticola* can produce toxic hydrogen sulfide compounds such as methyl mercaptans and thioether compounds in root-canal treated teeth.¹⁴

The test* that can be used for this purpose is based on the local detection of the mercaptan/thioether compounds, which diffuse directly into the sulcus of the endodontically treated tooth.¹⁵ Paper points are placed into the sulcus and

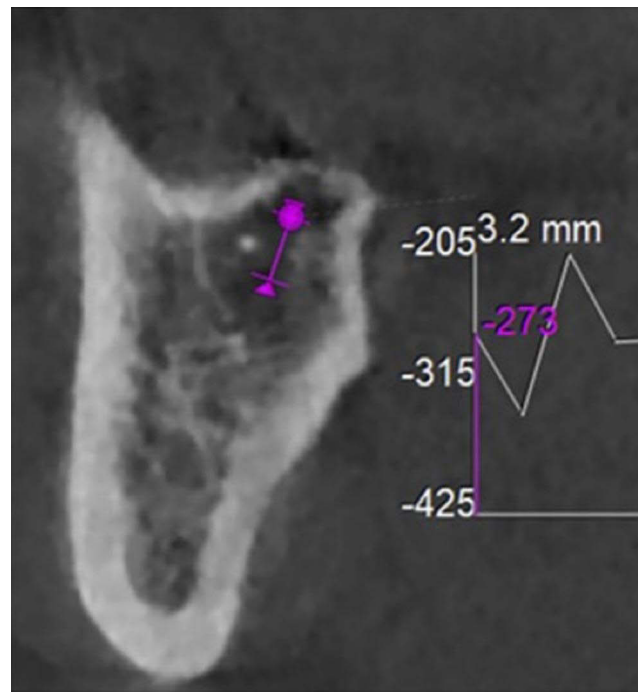


Figure 4 Radio-opaque foreign body in region 48 with corresponding osteolytic bone (Hu = -273).

examined for these compounds. This allows the practitioner to evaluate questionable teeth by a non-invasive measuring method. *www.orotox.de.

Mercaptans/Thioether Sensitisation Test

Studies have shown that protein breakdown products can cause inflammatory reactions and toxic effects, whereby there is no direct correlation to the toxin. The Individual sensitivity is more decisive here. Effector cell typing for mercaptans and thioethers in the laboratory detects an immune reaction to the substances and indicates utilizing the cytokine pattern determined (TH1-IFN- γ / Treg-IL-10) whether an immune reaction against these substances is taking place at the current time. This sensitivity test thus describes systemic inflammatory reactions and explains the different symptoms associated with the endodontically treated teeth.^{15,16}

Titanium Stimulation Test

The most common cause of individual hypersensitivity to titanium is the excessive proinflammatory reactivity of tissue macrophages. Physiologically, macrophages react after contact with titanium oxide particles by releasing proinflammatory cytokines, specifically TNF- α and interleukin-1. The intensity of cytokine release depends on genetic variants (polymorphisms) of the proinflammatory (IL-1 and TNF- α) and anti-inflammatory (IL-1 receptor antagonist IL-1RN) mediators involved. The titanium stimulation test was developed and validated for this purpose.¹⁷ This whole blood stimulation test reveals whether there is an increased release of TNF- α and/or IL-1 β . In patients with positive findings, the macrophages in the titanium implant area react hyperactively to released titanium particles and primarily induce local inflammation.

Determination of RANTES/CCL5 in Serum

RANTES (= Regulated And Normal T cell Expressed and Secreted) is a chemokine with a chemotactic effect. RANTES/CCL5 (R/C) is produced by cytotoxic T lymphocytes (CD28+/ CD8+), neutrophils and eosinophil granulocytes and secreted after activation. Chemotaxis and immune activation are the most essential functions of R/C: R/C is chemotactically active, selectively attracting NK cells, granulocytes, monocytes, and macrophages to an existing area of inflammation. It acts on these cells by binding to surface receptors such as CCR3, CCR5, and CCR1 (CCR = chemokine receptor). R/C is thus involved in many disease patterns in which inflammatory processes occur. Elevated R/C levels are

associated with numerous systemic inflammatory diseases. These include rheumatoid diseases, allergies, asthma, multiple sclerosis, and tumor pathologies.^{16–20}

It has been confirmed that increased R/C blood levels are to be evaluated as an indication of a local inflammatory process. This may be caused by FDOJ, as elevated concentrations of R/C have been described here,^{9,16,17} although R/C as a systemic inflammatory marker, it is not specific for inflammatory jawbone processes. R/C can also increase in the blood in the context of other inflammatory diseases (ie bacterial infections and systemic autoimmune diseases).²⁴ However, if the findings are unremarkable in this respect, R/C does not justify the suspected diagnosis. A normal serum R/C value of 30 ng/mL can be derived from the mean value of scientifically published data.

In the run-up to dental procedures, the patient shows a serum R/C level of 43.4 ng/mL <30 mg/mL.

IMD Laboratory Berlin, Nicolaistraße 22, 12,247 Berlin.

Multiplex Analysis and Quantification RANTES/CCL5 in Samples

The determination of the parameter RANTES/CCL5 in the collected FDOJ samples was performed in the supernatant of the tissue homogenisate on the Luminex[®] 200™ analyzer and xPonent[®] software (Luminex, Austin, TX, USA) at the investigating Institute for Medical Diagnostics Nicolaistr. 22, 12,247 Berlin. The procedure has been described in laboratory detail in previous publications.²³

Postoperative Histological Findings and Cytokine Profile of the Collected Samples

Histological samples were also taken from the osteolytic parts of the mandibular medulla.

* Institute for Pathology&Cytology; Drs. Zwicknagel/Assmus 85635 Freising, Germany

Results and Rehabilitation

The combination of the described findings results in the medical indication for the surgical intervention of the areas of reduced osseodensification.

The first step is to remove the fatty-degenerated osteolytic tissue (FDOJ) in the first and fourth quadrants, the root canal treated teeth 45 and 46, and the foreign bodies in the wisdom tooth region 48 and retromolar 49.

Subsequently, the FDOJ in the second and third quadrants, the root canal-treated teeth 25, 34, and the metallic implants 35, 36 are removed.

Clinical Diagnosis After the Surgical Opening of the Osteolytic Areas

The areas affected by osteolytic bone marrow defects in ultrasound-TAU sonography (in red) and DVT (HU < -100) were removed with minimally invasive piezosurgery and hand instruments. They are clearly demarcated from the surrounding tissue due to reduced blood flow and fatty degenerative osteolysis of the jawbone (FDOJ). [Figures 5](#) and [6](#) show clinical examples of such an FDOJ specimens. These are purely medullary processes; the cortical bone is usually intact and demarcated from the cancellous bone, which is softened and interspersed with cavitations.

Since the pathophysiology of atopic dermatitis via immunological dysregulations^{25–28} is associated with the inflammatory cytokine RANTES/CCL5^{25–27} in the literature and increased RANTES/CCL5 levels have been found in FDOJ in previous publications,^{11,22,23} samples of the fatty degeneration are submitted for multiplex analysis of cytokine expression in the laboratory.

Results of the FDOJ Tissue Analyses

Postoperative Histological Findings and Cytokine Profile of the Collected Samples

Light microscopic examinations of the pathologically conspicuous specimens taken intraoperatively were carried out, with the following findings in two wisdom tooth areas operated on years prior, including retromolar areas in the ascending branch: Assessment area 28/29: “... In the medullary interiors, a translucent, weakly birefringent coarse foreign material, iron negative, plastic particles are to be considered. The medullary canal shows evidence of a discrete chronic fibrosing osteitis on the one hand and also degenerative changes of the type of interstitial fibrosis and fibrous demarcated fat tissue necrosis. “Assessment area 48/49: “Trophic disorder with myxoid degeneration of the

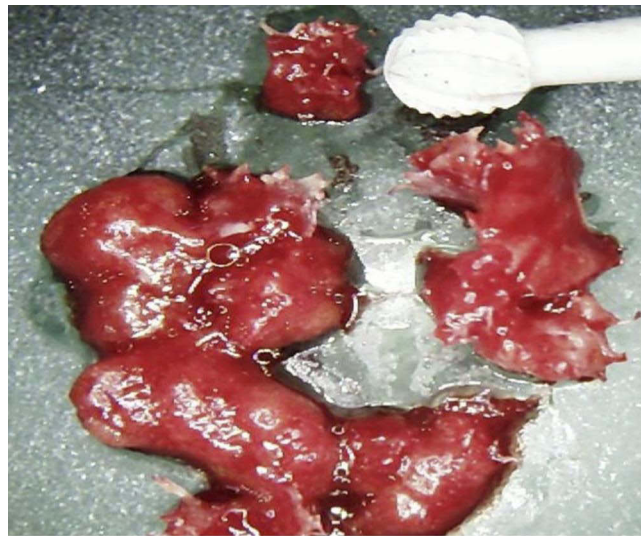


Figure 5 Characteristic morphology of FDOJ bone sample.

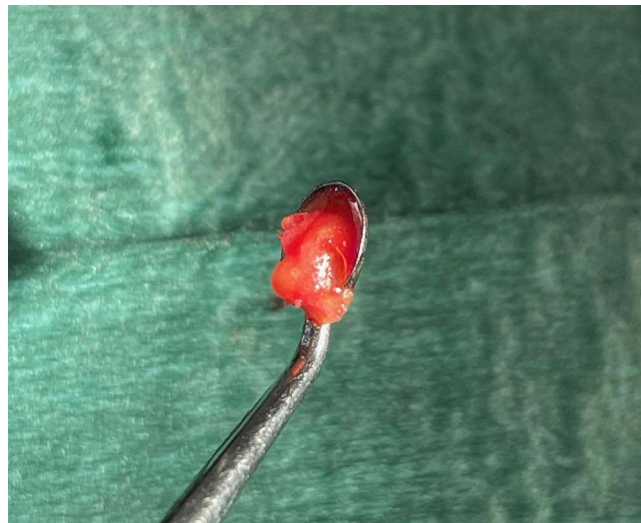


Figure 6 FDOJ bone sample immediately after removal.

intertrabecular fat marrow with small focal fat necrosis and granular tissue disintegration in some areas; metallic foreign bodies”.

Multiplex Analysis and Quantification of RANTES/CCL5 in the Collected Samples

The multiplex analysis of three FDOJ areas (Figure 7) shows the mean value and comparison to the standard value.¹⁹ This corresponds to overexpression of RANTES/CCL5 by approximately 14-fold in the mean of the three FDOJ areas examined. The potential systemic effect of this local overexpression has been discussed in previous studies and case reports.^{10,19–21,30,31} The graphical comparison of these values is shown in Figure 8.

regio	RANTES/CCL5 (R/C) in pg/ml
28/29	405
38/39	4.425
48/49	1.462,5
Mean value	2097,5
Standard	149,9

Figure 7 On average, a concentration of the proinflammatory cytokine RANTES/CCL5 of 2097.5 pg/mL could be detected in the removed tissue in the laboratory multiplex analysis. In healthy cancellous jawbone, 149.9 pg/mL values were measured. Data from Lechner J, von Baehr V. RANTES and fibroblast growth factor 2 in jawbone cavitations: triggers for systemic disease? *Int J Gen Med.* 2013;6:277–290. doi:10.2147/IJGM.S43852.²⁹

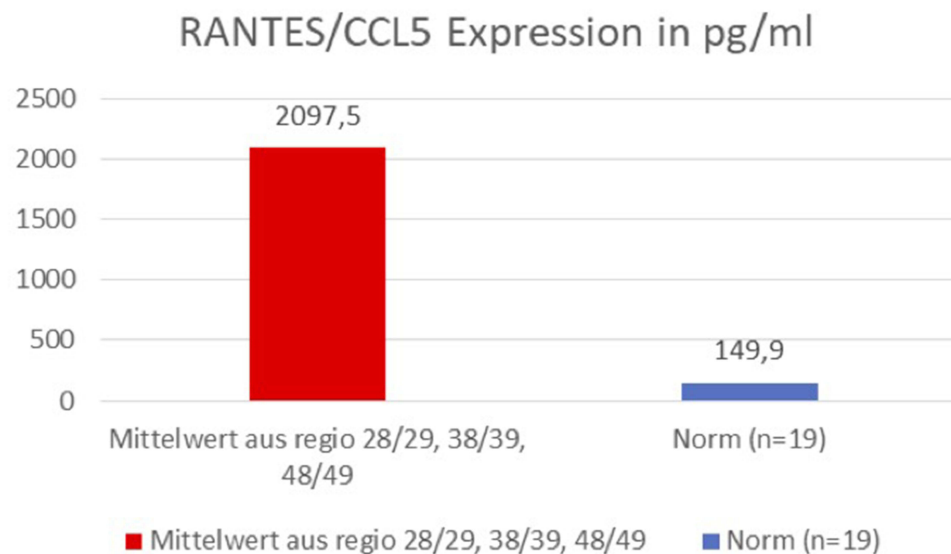


Figure 8 Mean value of RANTES/CCL5 expression from region 28/29, 38/39 and 48/49 compared to a normal value from 19 samples of healthy jawbone cancellous bone.²⁹

Rehabilitation

The fundamental purpose for systemic-immunological dentistry is to eliminate inflammatory triggers and stressors that may set into the jawbone. This is an essential requirement for restoring the long-term functionality of the masticatory organ.

Surgical Rehabilitation

Surgical rehabilitation of a bone marrow defect typical of FDOJ requires a subtle and minimally invasive approach. Frequently, the marrow softening extends to the inferior alveolar nerve. [Figure 9](#) shows the access window into the cortical bone achieved with piezosurgical instruments, and the contents of osteolytic bone.

In order to generate optimal wound and bone healing^{32–34} as well as functional regeneration of hard and soft tissues, PRF (platelet rich fibrin) is inserted into the resulting cavities after ozone flooding.^{35,36}

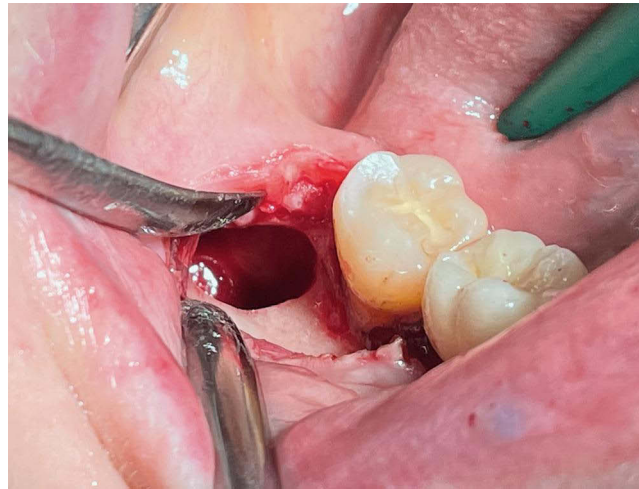


Figure 9 Example of a surgical sequestration of an extensive FDOJ area.

Implantological Rehabilitation

After extraction of the endodontically treated teeth 25, 34 and explantation of the titanium implants 35 and 36, the osteolytic bone was carefully removed, then ozone flooding was performed.^{35,36} In the same session, immediate ceramic implants were placed at sites 25, 34, 35, 36 and delayed implants at sites 45, 46, 47. In region 34–36, a bony augmentation was necessary after osteotomy and extraction of 34 and explantation of 35, 36. This was performed with partial autologous bone from region 38/39 and PRF (Figures 10 and 11). No foreign material was used in order to generate the most biocompatible regeneration possible of healthy new bone.

Prosthetic Rehabilitation

After a three-month healing period of the implants and a complication-free wound healing, the patient was restored with metal-free monolithic restoration (Figures 12 and 13). The crowns were conventionally cemented with glass ionomer cement avoiding allergenic plastic adhesives. The crown at site 37 was restored at a later date.

Management of Ossification of the Chronic Inflammatory Areas

Nine months after complete ossification, a new ultrasound TAU sonography is performed to check the operated FDOJ areas for complete wound healing. The approximately continuous green coloration (lower part in Figure 14) verifies the

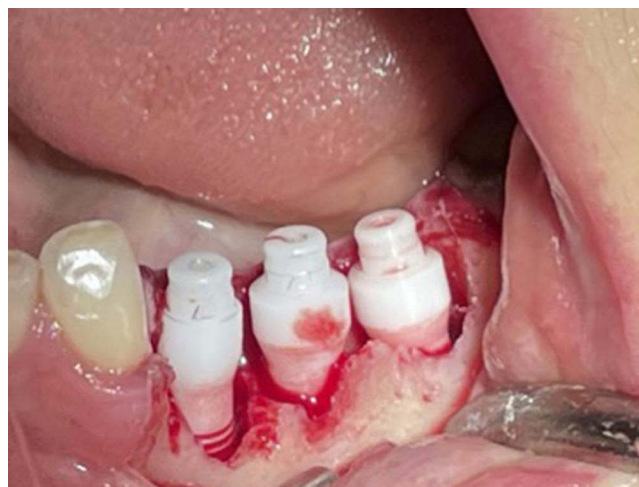

Figure 10 Third quadrant intraoperatively with the removal of the pathological bone, and placement of ceramic implants 34, 35, 36.

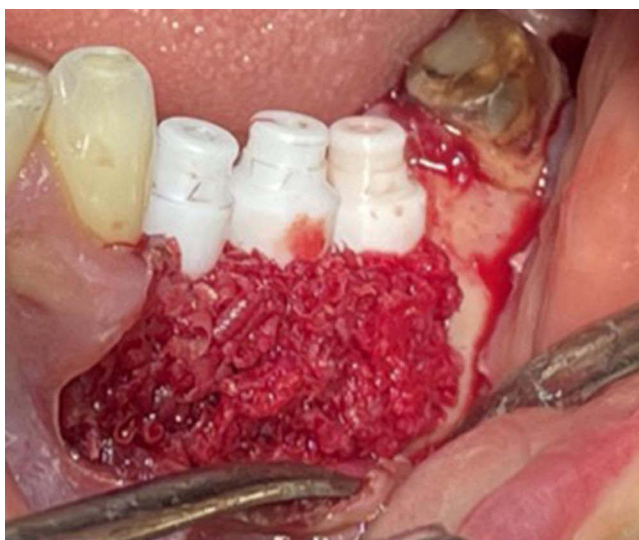

Figure 11 Third quadrant intraoperatively with autologous bone augmentation region 34, 35, 36.

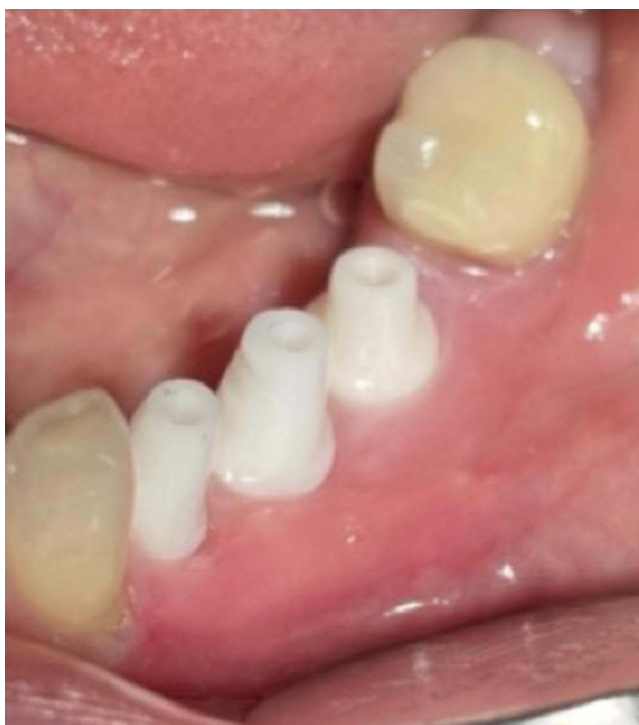

Figure 12 Healed operation site region 35, 36, 37 (osseointegrated ceramic implants surrounded by healthy soft tissue).

postoperative inflammation-free bone density. The elimination of inflammatory bone in the jaw could be seen as an immunological necessity for successfully reducing the patient's dermatological symptoms (Figure 15).

The Clinical Result of the Initial Dermatological Findings

The patient's dermatological symptoms increasingly improved after the surgical intervention (Figure 15). Retrospectively, the patient reports a healing success of 85% and a "real game-changer". The patient has consistently changed her diet and avoids pro-inflammatory foods. Dermatitis and eczema have disappeared mainly except for minor

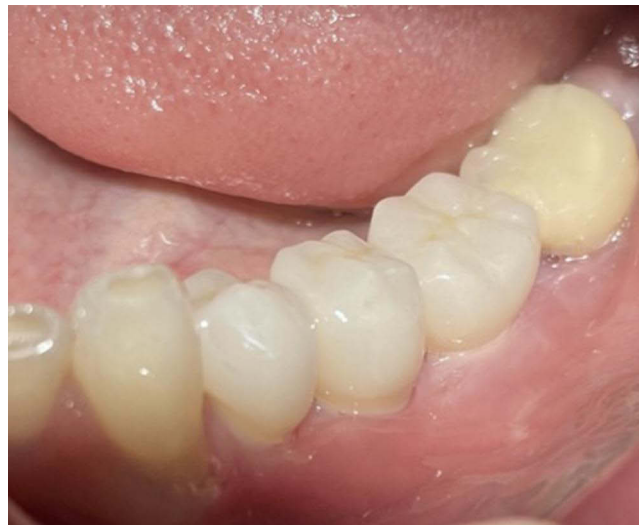

Figure 13 Third quadrant prosthetic restoration (monolithic zirconia crowns, cemented).

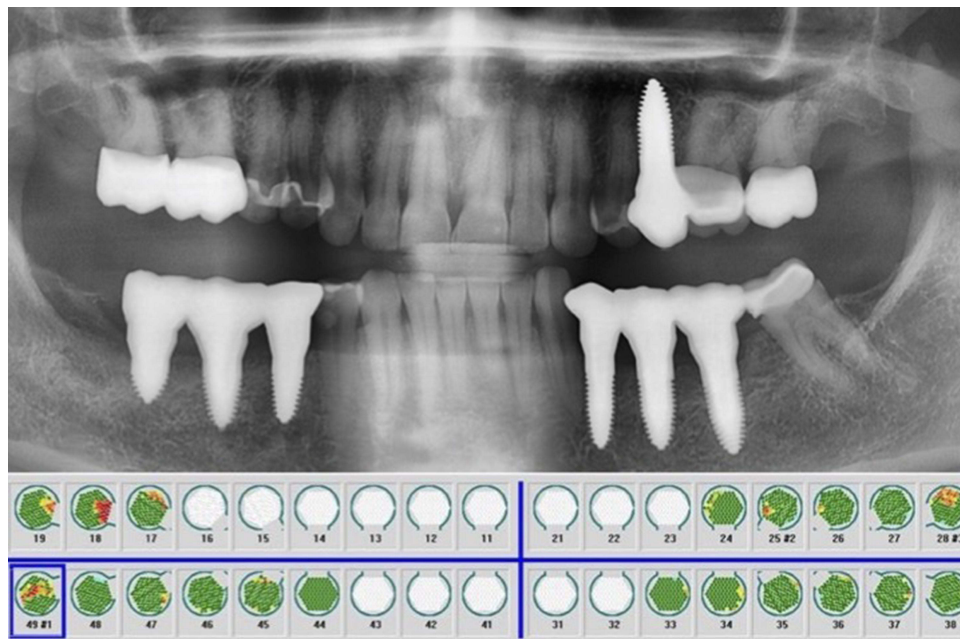


Figure 14 Radiological control image (OPG) with prosthetic restoration (upper image) and control of the metabolic situation of the bone density in the rehabilitated jaw areas with ultrasound TAU sonography (lower image).

inflammatory-dermatological phases, which can now be resolved with the help of dermatological care. The patient feels a significant improvement in her quality of life due to jaw rehabilitation.

Discussion

Clinical Diagnostics

It is striking that no evidence of chronic inflammation of the jawbone was found in the initial clinical and the two-dimensional radiological diagnostics. The patient was free of pain and complaints in the dental jaw region. Trans-alveolar bone densitometry (TAU) revealed the potentially pathogenic osteolytic areas. The immunological relevance could be confirmed postoperatively in the laboratory via the excessive expression of R/C with the multiplex analyses. Following

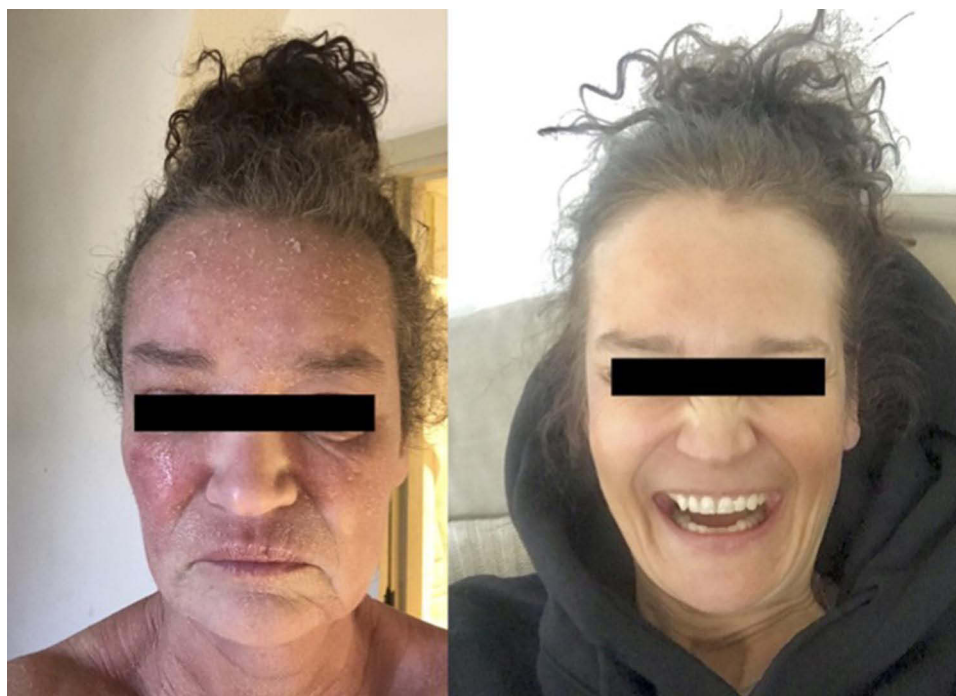

Figure 15 Dermatological appearance of the patient's face before and after completion of treatment.

the legally established ALARA principle⁸ the positive ultrasound TAU findings (Figure 2) were the medical indication for us to take a 3D image using DVT/CBCT (Figure 4).

Dermatological Pathogenesis Due to Chronic Immunological Dysregulation in the Dental-Jaw Region

Discussion of Local Immune Dysregulation by Titanium Particles

The cytotoxic and DNA-damaging potential of titanium particles has been shown,^{37,38} in comparison with zirconia particles.³⁹

There were two titanium implants in the mandible on the left in the patient's initial examination. Studies have demonstrated that titanium particles released into peri-implant tissues are well-known^{40–44} and terms such as biocorrosion and tribocorrosion (friction+corrosion) are getting more popular in both dentistry and orthopedics.^{41,45–47}

Even from well-healed titanium implants, released particles are capable of provoking^{39,43} immunological dysregulation and derailments.

The titanium stimulation test conducted by IMD Berlin shows an increased release of inflammatory mediators IL-1b in response to titanium oxide particles. This overreaction of inflammatory mediators is consistent with the reduced bone density in the ultrasound TAU measurement. Figure 2 shows conspicuous red coloration in the ultrasound TAU in the area of the implant at 35 and 36 in the interimplant septa. This reduced bone density and associated suspicion of R/C expression was a medical indication to remove the implants and replace them with biologically inert ceramic implants. With the implant removal, surrounding osteolytic tissue was also removed.

Discussion of Local Immune Dysregulation by Endodontically Treated Teeth

The patient's initial findings included a total of four endodontically treated teeth without radiological abnormalities in the OPG. It becomes increasingly clear that despite implementing the most advanced preparation, disinfection and filling

techniques, and utilizing the best materials, a complete absence of bacteria in the root canal system can rarely be achieved.^{48–52}

The literature shows that even from radiographically inconspicuous apical areas of endodontically treated teeth, diffusing toxins such as thioethers and mercaptans are capable of causing immunological dysregulation and derailment.^{15,16,53,54} The semi-quantitative measurement of biogenic amines diffusing into the sulcus of the endodontically treated tooth listed in Rehabilitation revealed the following toxin values: Tooth 25 = 5, 34 = 2, 45 = 4 and 46 = 4. The threshold value designated as inconspicuous is >2.

In order to deduce the link of local endodontic toxin exposure to systemic immune dysregulation, a mercaptan/thioether sensitization test was performed.¹⁶ After in vitro stimulation, this showed a greatly increased II-10 response (44.7 to <10) to the protein degradation products mercaptans/thioethers. This indicates immunological sensitization by biogenic amines. With the knowledge of the highly stressful systemic disease, this was a medical indication for the removal of the endodontically treated teeth.

As in the peri-implant bone tissue around the two titanium implants, [Figure 2](#) also showed suspicious red areas surrounding the endodontically treated teeth with the ultrasonic TAU. Investigations show that histologically, apical periodontitis is likely to be present in more than half of the root-filled teeth after treatment.^{55,56}

The suspected teeth were therefore replaced with immediate ceramic implants.

Discussion of Local Immune Dysregulation by FDOJ and RANTES/CCL5

Approximately after removing the extensive FDOJ pathologies in the edentulous jawbone areas, around the titanium implants, and in the periapical area of the endodontically treated teeth, the patient's dermatological symptoms decreased.

These invasive measures were required for reducing the proinflammatory chemokine R/C expression and subsequent systemic-immunological success.

Was this an isolated placebo success or what connections does the scientific literature see between atopic dermatitis and chronic sensitization of the immune system by R/C signaling cascades?

The PubMed search: "atopic dermatitis AND rantes ccl5" from 1994 to 2022 yields a total of 89 results, which we group here according to the activation of RANTES/CCL 5 genes/DNA polymorphism and the direct relation to RANTES/CCL 5 expression:

1. "There was a significant association between the upregulating variant of RANTES –28G and atopic dermatitis, ... These results support a role for RANTES promoter polymorphisms in susceptibility to atopic dermatitis".⁵⁷
2. "These results suggest that RANTES as well as its receptors CCR3 and CCR5 may play important roles in the orchestration of eosinophil infiltration in ongoing chronic inflammation in atopic eczema, and also reflect the severity of the disease".⁵⁸

The PubMed results and the scientists' statements strengthen the authors' hypothesis that the reduction of systemic R/C expression by local dental sanitation measures is directly related to clinical outcomes. At the same time, the authors are aware that the complex issues surrounding FDOJ with the inflammatory process chemokines R/C are controversial from various sides.

This case report gives additional space and clinical significance to the demand for large-scale studies for better evidence support.⁵⁹ The authors agree that there is a need for further studies with significant study designs to provide evidence for this controversially discussed issue. New examination methods, based on technologically advanced ultrasound TAU sonography, are available and increasingly validated.^{28,29,60}

Discussion of Systemic Immune Rehabilitation

Restoring systemic immunological regulation is an essential component of an integrative oral medicine approach. Using autologous blood concentrate (PRF),^{32–34} ozone flooding^{35,36} as well as a perioperative optimization of the bone metabolism via the vitamin D3 level,⁶¹ a biological-functional regeneration and thus a reduction of the inflammatory load could be achieved.

With the removal and functional regeneration of oral stressors and silent inflammations using autologous and more inert materials, an overreactive immune system could be calmed down and thus regulation brought into homeostasis. Chronic autoimmune diseases such as atopic dermatitis could therefore potentially improve.

The patient's dermatological symptoms were significantly reduced with the treatment.

Summary

This case report demonstrates a multi-layered protocol for uncovering chronic toxic and chronic immunological exposures in the oral jawbone region. This protocol is complementary to monocausal attributions and highlights the association of oral stresses, immunologic systemic derailments and complex multimorbidities.

There is a possible connection of chronically elevated levels of the proinflammatory chemokine R/C in areas with impaired wound healing, surrounding titanium implants, endodontically pre-treated teeth, and various foreign bodies to systemic disease patterns such as atopic dermatitis.

Even with conventional X-ray diagnostics, areas of reduced bone density in the jaw could be only detected with the addition of TAU measurements. Most notably, the systemic symptoms improved after biological regeneration of the removed FDOJ areas and functional rehabilitation with ceramic implants. Clinical images and data indicate that the hypothetical cause of the patient's dermatological symptoms was likely a local overexpression of R/C in the surrounding of chronically acting FDOJ areas.

Conclusion

This case can demonstrate for therapists of many specialties the importance of a patient's dental condition in the development of systemic immunological diseases. It also illustrates the importance and benefit of biocompatible dental treatment in conjunction to appropriate examination procedures.

Although a fundamental therapeutic strategy for atopic dermatitis cannot be derived from this individual case description, the outlook of our work is in line with the new licensing regulations for dentists (ZApprO) in Germany: In dental studies, interdisciplinary thinking should be promoted and problem-oriented to the subject taught.

Abbreviations

CBCT/DVT, cone-beam computed tomography/digital volume tomography; TAU, trans-alveolar ultrasound; PRF, platelet rich fibrin; FDOJ, fatty degenerative osteonecrotic jawbone; OPG, orthopantomogram; R/C, chemokine RANTES/CCL5.

Acknowledgments

We want to thank the patient for the generous agreement to publish the images of the different stages of her disease as well as the oral rehabilitation.

Disclosure

CaviTAU[®] (Munich, Germany), the company that designed the new TAU-n apparatus and associated software, provided these tools without charge for the purposes of this study. The ultrasonography procedure was carried out at the Clinic for Integrative Dentistry Munich. CaviTAU[®] and the Clinic for Integrative Dentistry are in ongoing discussions regarding numerous collaborative arrangements to further improve and verify the new TAU apparatus, CaviTAU[®], as it is introduced to the market. Johann Lechner is the holder of a patent used in CaviTAU[®]. The authors report no other conflicts of interest in this work.

References

1. Wang HHX, Wang JJ, Wong SYS, et al. Epidemiology of multimorbidity in China and implications for the healthcare system: cross-sectional survey among 162,464 community household residents in southern China. *BMC Med.* 2014;12:188. doi:10.1186/s12916-014-0188-0
2. Kingston A, Robinson L, Booth H, Knapp M, Jagger C. Projections of multi-morbidity in the older population in England to 2035: estimates from the Population Ageing and Care Simulation (PACSim) model. *Age Ageing.* 2018;47(3):374–380. doi:10.1093/ageing/afx201
3. Bach JF. The effect of infections on susceptibility to autoimmune and allergic diseases. *N Engl J Med.* 2002;347(12):911–920. doi:10.1056/NEJMra020100

4. Hawkes N. Better training is needed to deal with increasing multimorbidity. *BMJ*. 2012;344:e3336. doi:10.1136/bmj.e3336
5. Makovski TT, Schmitz S, Zeegers MP, Stranges S, van den Akker M. Multimorbidity and quality of life: systematic literature review and meta-analysis. *Ageing Res Rev*. 2019;53:100903. doi:10.1016/j.arr.2019.04.005
6. Frass M, Krenner L, Dembowski K. Integrative medicine: evidence-based complementary medicine methods. *Integrative Medizin: evidenzbasierte Komplementärmedizinische Methoden*. 1. Auflage; 2019.
7. An JG, Liu YT, Xiao SX, Wang JM, Geng SM, Dong YY. Quality of life of patients with neurodermatitis. *Int J Med Sci*. 2013;10(5):593–598. doi:10.7150/ijms.5624
8. Ermertcan AT, Gencoglan G, Temeltas G, Horasan GD, Deveci A, Ozturk F. Sexual dysfunction in female patients with neurodermatitis. *J Androl*. 2011;32(2):165–169. doi:10.2164/jandrol.110.010959
9. Lechner J. Validation of dental X-ray by cytokine RANTES - comparison of X-ray findings with cytokine overexpression in jawbone. *Clin Cosmet Investig Dent*. 2014;6:71–79. doi:10.2147/CCIDE.S69807
10. Farman AG. ALARA still applies. *Oral Surg Oral Med Oral Pathol Oral Radiol Endod*. 2005;100(4):395–397. doi:10.1016/j.tripleo.2005.05.055
11. Lechner J, Zimmermann B, Schmidt M, von Baehr V. Ultrasound sonography to detect focal osteoporotic jawbone marrow defects clinical comparative study with corresponding Hounsfield units and RANTES/CCL5 expression. *Clin Cosmet Investig Dent*. 2020;12:205–216. doi:10.2147/CCIDE.S247345
12. Lechner J, Zimmermann B, Schmidt M. Focal bone-marrow defects in the jawbone determined by ultrasonography-validation of new trans-alveolar ultrasound technique for measuring jawbone density in 210 participants. *Ultrasound Med Biol*. 2021;47(11):3135–3146. doi:10.1016/j.ultrasmedbio.2021.07.012
13. Guerrero ME, Jacobs R, Loubele M, Schutyser F, Suetens P, van Steenberghe D. State-of-The-art on cone beam CT imaging for preoperative planning of implant placement. *Clin Oral Investig*. 2006;10(1):1–7. doi:10.1007/s00784-005-0031-2
14. Lechner J, Mayer W. Mitochondrial function and root-filled teeth – detrimental and unknown interfaces in systemic immune diseases. *Int J Gen Med*. 2020;13:387–402. doi:10.2147/IJGM.S258170
15. Lechner J, von Baehr V. Stimulation of proinflammatory cytokines by volatile sulfur compounds in endodontically treated teeth. *Int J Gen Med*. 2015;8:109–118. doi:10.2147/IJGM.S77693
16. Jacobi-Gresser E, Schütt S, Huesker K, Von Baehr V. Methyl mercaptan and hydrogen sulfide products stimulate proinflammatory cytokines in patients with necrotic pulp tissue and endodontically treated teeth. *J Biol Regul Homeost Agents*. 2015;29(1):73–84.
17. Dörner T, Haas J, Loddenkemper C, von Baehr V, Salama A. Implant-related inflammatory arthritis. *Nat Clin Pract Rheumatol*. 2006;2(1):53–56; quiz 57. doi:10.1038/npcrheum0087
18. Raghu H, Lepus CM, Wang Q, et al. CCL2/CCR2, but not CCL5/CCR5, mediates monocyte recruitment, inflammation and cartilage destruction in osteoarthritis. *Ann Rheum Dis*. 2017;76(5):914–922. doi:10.1136/annrheumdis-2016-210426
19. Marques RE, Guabiraba R, Russo RC, Teixeira MM. Targeting CCL5 in inflammation. *Expert Opin Ther Targets*. 2013;17(12):1439–1460. doi:10.1517/14728222.2013.837886
20. Soria G, Ben-Baruch A. The inflammatory chemokines CCL2 and CCL5 in breast cancer. *Cancer Lett*. 2008;267(2):271–285. doi:10.1016/j.canlet.2008.03.018
21. Sada M, Watanabe M, Inui T, et al. Ruxolitinib inhibits poly(I:C) and type 2 cytokines-induced CCL5 production in bronchial epithelial cells: a potential therapeutic agent for severe eosinophilic asthma. *Immun Inflamm Dis*. 2021;9(2):363–373. doi:10.1002/iid3.397
22. Lechner J, Schmidt M, von Baehr V, Schick F. Undetected jawbone marrow defects as inflammatory and degenerative signaling pathways: chemokine RANTES/CCL5 as a possible link between the jawbone and systemic interactions? *J Inflamm Res*. 2021;14:1603–1612. doi:10.2147/JIR.S307635
23. Lechner J, Schuett S, von Baehr V. Aseptic-avascular osteonecrosis: local “silent inflammation” in the jawbone and RANTES/CCL5 overexpression. *Clin Cosmet Investig Dent*. 2017;9:99–109. doi:10.2147/CCIDE.S149545
24. Fichna M, Żurawek M, Budny B, et al. Elevated serum RANTES chemokine levels in autoimmune Addison disease. *Pol Arch Intern Med*. 2018;128(4):216–221. doi:10.20452/pamw.4221
25. Pastore S, Mascia F, Girolomoni G. The contribution of keratinocytes to the pathogenesis of atopic dermatitis. *Eur J Dermatol*. 2006;16(2):125–131.
26. Yeo H, Lee YH, Koh D, Lim Y, Shin SY. Chrysin inhibits NF-κB-dependent CCL5 transcription by targeting IκB kinase in the atopic dermatitis-like inflammatory microenvironment. *Int J Mol Sci*. 2020;21(19):E7348. doi:10.3390/ijms21197348
27. Morar N, Willis-Owen SAG, Moffatt MF, Cookson WOCM. The genetics of atopic dermatitis. *J Allergy Clin Immunol*. 2006;118(1):24–34; quiz 35–36. doi:10.1016/j.jaci.2006.03.037
28. Langan SM, Irvine AD, Weidinger S. Atopic dermatitis. *Lancet*. 2020;396(10247):345–360. doi:10.1016/S0140-6736(20)31286-1
29. Lechner J, von Baehr V. RANTES and fibroblast growth factor 2 in jawbone cavitations: triggers for systemic disease? *Int J Gen Med*. 2013;6:277–290. doi:10.2147/IJGM.S43852
30. Lechner J, von Baehr V, Schick F. RANTES/CCL5 signaling from jawbone cavitations to epistemology of multiple sclerosis - research and case studies. *Degener Neurol Neuromuscul Dis*. 2021;11:41–50. doi:10.2147/DNND.S315321
31. Lechner J, Schick F. Chronic fatigue syndrome and bone marrow defects of the jaw - A case report on additional dental X-Ray diagnostics with ultrasound. *Int Med Case Rep J*. 2021;14:241–249. doi:10.2147/IMCRJ.S306641
32. Simonpieri A, Del Corso M, Vervelle A, et al. Current knowledge and perspectives for the use of platelet-rich plasma (PRP) and platelet-rich fibrin (PRF) in oral and maxillofacial surgery part 2: bone graft, implant and reconstructive surgery. *Curr Pharm Biotechnol*. 2012;13(7):1231–1256. doi:10.2174/138920112800624472
33. Xu J, Gou L, Zhang P, Li H, Qiu S. Platelet-rich plasma and regenerative dentistry. *Aust Dent J*. 2020;65(2):131–142. doi:10.1111/adj.12754
34. Feigin K, Shope B. Use of platelet-rich plasma and platelet-rich fibrin in dentistry and oral surgery: introduction and review of the literature. *J Vet Dent*. 2019;36(2):109–123. doi:10.1177/0898756419876057
35. Stübinger S, Sader R, Filippi A. The use of ozone in dentistry and maxillofacial surgery: a review. *Quintessence Int*. 2006;37(5):353–359.
36. Nogales CG, Ferrari PH, Kantorovich EO, Lage-Marques JL. Ozone therapy in medicine and dentistry. *J Contemp Dent Pract*. 2008;9(4):75–84. doi:10.5005/jcdp-9-4-75

37. Messous R, Henriques B, Bousbaa H, Silva FS, Teughels W, Souza JCM. Cytotoxic effects of submicron- and nano-scale titanium debris released from dental implants: an integrative review. *Clin Oral Investig*. 2021;25(4):1627–1640. doi:10.1007/s00784-021-03785-z
38. Noronha Oliveira M, Schunemann WVH, Mathew MT, et al. Can degradation products released from dental implants affect peri-implant tissues? *J Periodontol Res*. 2018;53(1):1–11. doi:10.1111/jre.12479
39. He X, Reichl FX, Milz S, et al. Titanium and zirconium release from titanium- and zirconia implants in mini pig maxillae and their toxicity in vitro. *Dent Mater*. 2020;36(3):402–412. doi:10.1016/j.dental.2020.01.013
40. Senna P, Antoninha Del Bel Cury A, Kates S, Meirelles L. Surface damage on dental implants with release of loose particles after insertion into bone. *Clin Implant Dent Relat Res*. 2015;17(4):681–692. doi:10.1111/cid.12167
41. Mombelli A, Hashim D, Cionca N. What is the impact of titanium particles and biocorrosion on implant survival and complications? A critical review. *Clin Oral Implants Res*. 2018;29 Suppl 18:37–53. doi:10.1111/clr.13305
42. Olmedo DG, Nalli G, Verdú S, Paparella ML, Cabrini RL. Exfoliative cytology and titanium dental implants: a pilot study. *J Periodontol*. 2013;84(1):78–83. doi:10.1902/jop.2012.110757
43. Lechner J, Nombissi S, von Baehr V. Titanium implants and silent inflammation in jawbone—a critical interplay of dissolved titanium particles and cytokines TNF- α and RANTES/CCL5 on overall health? *EPMA J*. 2018;9(3):331–343. doi:10.1007/s13167-018-0138-6
44. Flatebø RS, Høl PJ, Leknes KN, Kosler J, Lie SA, Gjerdet NR. Mapping of titanium particles in peri-implant oral mucosa by laser ablation inductively coupled plasma mass spectrometry and high-resolution optical darkfield microscopy. *J Oral Pathol Med*. 2011;40(5):412–420. doi:10.1111/j.1600-0714.2010.00958.x
45. Mathew MT, Srinivasa Pai P, Pourzal R, Fischer A, Wimmer MA. Significance of tribocorrosion in biomedical applications: overview and current status. *Adv Tribol*. 2010;2009:250986. doi:10.1155/2009/250986
46. Olmedo DG, Duffó G, Cabrini RL, Guglielmotti MB. Local effect of titanium implant corrosion: an experimental study in rats. *Int J Oral Maxillofac Surg*. 2008;37(11):1032–1038. doi:10.1016/j.ijom.2008.05.013
47. Barão VAR, Yoon CJ, Mathew MT, Yuan JCC, Wu CD, Sukotjo C. Attachment of *Porphyromonas gingivalis* to corroded commercially pure titanium and titanium-aluminum-vanadium alloy. *J Periodontol*. 2014;85(9):1275–1282. doi:10.1902/jop.2014.130595
48. Brosco VH, Bernardineli N, Torres SA, et al. Bacterial leakage in obturated root canals—part 2: a comparative histologic and microbiologic analyses. *Oral Surg Oral Pathol Oral Radiol Endod*. 2010;109(5):788–794. doi:10.1016/j.tripleo.2009.11.036
49. Oliveira ACM, Tanomaru JMG, Faria-Junior N, Tanomaru-Filho M. Bacterial leakage in root canals filled with conventional and MTA-based sealers. *Int Endod J*. 2011;44(4):370–375. doi:10.1111/j.1365-2591.2011.01852.x
50. Navarro-Escobar E, Baca P, Ruiz-Linares M, Arias-Moliz MT, Perez-Heredia M, Ferrer-Luque CM. Bacterial leakage in root canals filled with AH Plus and dentine bonding agents. *Acta Odontol Scand*. 2014;72(8):819–824. doi:10.3109/00016357.2014.913196
51. Razavian H, Barekatin B, Shadmehr E, Khatami M, Bagheri F, Heidari F. Bacterial leakage in root canals filled with resin-based and mineral trioxide aggregate-based sealers. *Dent Res J (Isfahan)*. 2014;11(5):599–603.
52. Siqueira JF, Rôças IN. Polymerase chain reaction-based analysis of microorganisms associated with failed endodontic treatment. *Oral Surg Oral Med Oral Pathol Oral Radiol Endod*. 2004;97(1):85–94. doi:10.1016/S1079-2104(03)00353-6
53. Bergenholtz G, Spångberg L. CONTROVERSIES IN ENDODONTICS. *Crit Rev Oral Biol Med*. 2004;15(2):99–114. doi:10.1177/154411130401500204
54. Clark-Holke D, Drake D, Walton R, Rivera E, Guthmiller JM. Bacterial penetration through canals of endodontically treated teeth in the presence or absence of the smear layer. *J Dent*. 2003;31(4):275–281. doi:10.1016/S0300-5712(03)00032-0
55. Wu MK, Dummer PMH, Wesselink PR. Consequences of and strategies to deal with residual post-treatment root canal infection. *Int Endod J*. 2006;39(5):343–356. doi:10.1111/j.1365-2591.2006.01092.x
56. Petersson A, Axelsson S, Davidson T, et al. Radiological diagnosis of periapical bone tissue lesions in endodontics: a systematic review. *Int Endod J*. 2012;45(9):783–801. doi:10.1111/j.1365-2591.2012.02034.x
57. Tanaka K, Roberts MH, Yamamoto N, Sugiura H, Uehara M, Hopkin JM. Upregulating promoter polymorphisms of RANTES relate to atopic dermatitis. *Int J Immunogenet*. 2006;33(6):423–428. doi:10.1111/j.1744-313X.2006.00635.x
58. Kato Y, Pawankar R, Kimura Y, Kawana S. Increased expression of RANTES, CCR3 and CCR5 in the lesional skin of patients with atopic eczema. *Int Arch Allergy Immunol*. 2006;139(3):245–257. doi:10.1159/000091170
59. Sekundo C, Wiltfang J, Schliephake H, et al. Neuralgia-inducing cavitation osteonecrosis - A systematic review. *Oral Dis*. 2021. doi:10.1111/odi.13886
60. Klein MO, Grötz KA, Manefeld B, Kann PH, Al-Nawas B. Ultrasound transmission velocity for noninvasive evaluation of jaw bone quality in vivo before dental implantation. *Ultrasound Med Biol*. 2008;34(12):1966–1971. doi:10.1016/j.ultrasmedbio.2008.04.016
61. Ghanaati S, Choukroun J, Volz U, et al. One hundred years after Vitamin D discovery: is there clinical evidence for supplementation doses? *Int J Growth Factors Stem Cells Dentistry*. 2020;3(1):3–11. doi:10.4103/GFSC.GFSC_4_20

International Medical Case Reports Journal

Dovepress

Publish your work in this journal

The International Medical Case Reports Journal is an international, peer-reviewed open-access journal publishing original case reports from all medical specialties. Previously unpublished medical posters are also accepted relating to any area of clinical or preclinical science. Submissions should not normally exceed 2,000 words or 4 published pages including figures, diagrams and references. The manuscript management system is completely online and includes a very quick and fair peer-review system, which is all easy to use. Visit <http://www.dovepress.com/testimonials.php> to read real quotes from published authors.

Submit your manuscript here: <https://www.dovepress.com/international-medical-case-reports-journal-journal>