

ALLERGIC NEURITIS: AN EXPERIMENTAL DISEASE OF RABBITS
INDUCED BY THE INJECTION OF PERIPHERAL NERVOUS
TISSUE AND ADJUVANTS*

By BYRON H. WAKSMAN, M.D., AND RAYMOND D. ADAMS, M.D.

*(From the Neurology Service of the Massachusetts General Hospital and the Departments
of Neuropathology-Neurology and Bacteriology and Immunology, Harvard
Medical School, Boston)*

PLATES 27 TO 36

(Received for publication, March 30, 1955)

Experimental allergic encephalomyelitis (EAE),¹ a disease produced in animals by the injection of homologous or heterologous nervous tissue, killed tubercle bacilli, and mineral oil, has been extensively investigated. The characteristic pathologic picture comprises multiple small foci of myelin degeneration and infiltrations of mononuclear leucocytes and lymphocytes in the white matter of the brain and spinal cord and meningitis. The peripheral nervous system, *i.e.* the ventral and dorsal roots, the spinal ganglia, and the peripheral nerves, has not been involved in this disease, according to most observers. The exceptions to this statement are to be found in the writings of Innes (1), who noted lesions of the peripheral nerves in sheep which had been inoculated with homologous brain tissue; Ferraro (2), who illustrated a lesion in the spinal ganglia of monkeys which had received injections of homologous brain tissue; and several workers who have noted root lesions in the guinea pig (3-5). In each of these experimental studies the lesions in the peripheral nervous system were invariably combined with lesions in the central nervous system. Innes was in doubt as to their significance; Ferraro only mentions them in a comment on the occasional involvement of extraneural tissues such as the choroid plexus, meninges, lung, liver, and kidney; and the other writers do not discuss them at all. An experimental, allergic disease limited exclusively to the peripheral nervous system has not been reported.

A noteworthy feature of EAE is that it has usually been produced by the use of antigenic material obtained from the central nervous system. Of the investigators who have attempted to use peripheral nerve as antigen (6-8) only Lumsden has achieved any success (9). He produced the usual disease of the central nervous system (EAE) in guinea pigs by the injection of homologous peripheral nerve with adjuvants. His studies and other experimental work concerned with the effects of injecting whole nervous tissue or various fractions thereof have been thoroughly reviewed by Hurst (10, 11), Kolb (12), and Weil (13) and need not be discussed further at this time.

* This investigation was supported by grants from the United States Public Health Service, National Institute of Neurology and Blindness (No. B-156) and the Kresge Foundation. The results were presented in part before the annual meeting of the American Association of Immunologists, April 15, 1954.

¹ EAE, experimental allergic encephalomyelitis.

The purpose of the present communication is to describe a disease in rabbits produced by the inoculation of homologous or heterologous sciatic nerve with the usual adjuvants. We have called this rabbit disease experimental allergic neuritis (EAN).² The lesions are confined to the nerve roots, spinal ganglia, and peripheral nerves. There is a characteristic change in the cerebrospinal fluid consisting of an elevation of protein without pleocytosis (albumino-cytologic dissociation).

We believe this new experimental disease to be of importance because it represents one of the first laboratory models of non-infectious inflammatory disease of peripheral nerves. Moreover it bears certain resemblances to a group of human diseases which are known by the terms "acute infectious polyneuritis," "Guillain-Barré syndrome," and "Landry's paralysis." A clarification of the mechanism of this experimental disease may therefore shed some light on these human diseases, which have as yet no assigned cause.

Materials and Methods

Rabbits.—Female rabbits of a mixed, albino strain, weighing 2.5 to 3.0 kg. were used in all our experiments. They were kept in individual cages or in bins large enough to accommodate 5 to 10 animals; and they were fed Purina rabbit chow. The majority of the animals remained in good health throughout the experiment, aside from the effects of the experimental disease itself.

Antigens and Inoculations.—Sciatic nerve, which was the source of antigen, was obtained from normal rabbits or animals of other species immediately after death and was kept at -20°C . until used. It was carefully freed of fat and muscle, washed several times in sterile isotonic saline solution, and cut into small pieces on a freezing microtome. 2 gm. of the clean nerve was ground in a mortar with 3 ml. of bayol F containing heat-killed, human type tubercle bacilli,³ 3 mg./ml. No emulsifier was employed. The antigenic mixture remained effective after storage at -20°C . for several weeks or months. In one experiment rabbit spinal ganglia, treated in the same manner, were employed as antigen. An additional study of the effects of injecting whole rabbit spinal cord, rabbit optic nerve, bovine white matter, or certain fractions of bovine white matter (14) was undertaken. The preparation of these materials was the same as that for sciatic nerve; the amount used always corresponded to 2 gm. of whole tissue. All rabbits received a single intradermal injection (0.05 to 0.1 ml.) of a particular antigenic mixture in each of the 4 footpads simultaneously. This technique is known to produce allergic encephalomyelitis in the majority of animals receiving antigenic mixtures containing rabbit spinal cord or bovine white matter (14, 15). The animals were sacrificed at various intervals after the onset of disease or at the end of a 6 week period of observation.

Skin Tests and Serology.—The sciatic nerve of different animal species and whole rabbit spinal cord were used as 10 per cent suspensions in isotonic saline solution for skin testing. The sciatic nerve antigens, after grinding, were passed through gauze to remove pieces of connective tissue. For all tests, 0.1 ml. was given intradermally in a previously shaved area of the flank. Reactions were read at 24 and 48 hours and were observed for several days

² EAN, experimental allergic neuritis.

³ We are grateful to Dr. Jules Freund of The Public Health Research Institute of the City of New York, Inc., for the tubercle bacilli (Jamaica 22 strain) used in this investigation.

thereafter. They were graded from + to ++++ according to the extent of the induration and erythema, as described in an earlier report (15). The same nervous tissue antigens, in a concentration of 0.05 per cent (rabbit spinal cord) or 0.1 per cent (nerves and ganglia), were employed in serological studies. The complement fixation technique employed was essentially that of Lumsden and Kabat (16), with the use of veronal buffer containing optimum amounts of Ca^{++} and Mg^{++} as the diluent and an amount of complement standardized photometrically at six 50 per cent hemolysis units. The antigens were not anticomplementary even at several times the concentration employed. Moreover, few of the sera showed anticomplementary activity beyond the first tube, as they were all kept at -20°C . until studied and were inactivated at 56°C . for 20 minutes just before use. Therefore serum dilution titers are reported in the conventional manner.

Cerebrospinal Fluids.—Cerebrospinal fluids were obtained by cisternal puncture performed under nembutal and ether anesthesia or sometimes immediately postmortem. About 1 ml. of fluid was usually obtained. If the fluid was bloody, as sometimes happened with a "traumatic tap," it was discarded. The total protein content was determined, after precipitation with 5 per cent sulfosalicylic acid, by nephelometry in a Coleman Junior spectrophotometer (17). Readings were made at $550\text{ m}\mu$ and compared with a standard curve obtained with rabbit serum in appropriate dilutions. The white blood cells were counted in all fluids; red cells were counted only if contamination with blood was suspected.

Pathological Studies.—All animals, regardless of whether they manifested signs of nervous disease, were examined post mortem. Autopsies included the entire central nervous system with as many spinal ganglia as could be obtained, the optic nerves, and the entire length of the sciatic and brachial plexuses from one or both sides. In representative animals viscera and muscle were also taken for study. Microscopic sections of the nervous system were prepared from blocks of the lumbar, thoracic, and cervical cord segments, with accompanying ganglia, and the pons, cerebellum, and cerebrum. As routine longitudinal sections were prepared from the full length of one sciatic nerve, and additional sections were obtained for further study when indicated. The Nissl (cresyl violet) or the hematoxylin and eosin methods were used for the initial survey and for cytological details, the oil-red-O hematoxylin technique for fat and myelin, the Gies and Bodian methods for axis cylinders, and the osmic acid, Spielmeyer, Loyez, or luxol fast blue stains for myelin. The grading of the histologic lesions was based on the number, size, and degree of dissemination of lesions in various parts of the nervous system (see Histopathologic Findings under Results). Sections of the viscera were stained with hematoxylin and eosin.

RESULTS

Symptomatology.—A large proportion of the rabbits injected with homologous or heterologous sciatic nerve tissue developed signs of nervous disease. The exact number of animals affected in each experiment is recorded in the tables below. The behavior of the diseased animals was approximately the same in each of the different groups studied and one description will suffice for all. Rabbits with moderate or severe EAN (graded ++ or ++++) showed an abnormality of stance and of locomotion. They tended to lie in a splayed position, with all extremities extended and the head resting on the floor, instead of sitting in the usual compact, hunched posture. In hopping they were unsteady and erratic; they would jump too high or not high enough in going over a low hurdle. Upon landing they would often stagger or lurch to one side and had trouble in righting themselves. It was less difficult to

push them off balance than normal rabbits and they would adopt abnormal postures when handled. The musculature of the extremities and trunk was weak and slack and offered less than the usual resistance to passive movement. However, despite their often extreme weakness, even the most markedly affected animals retained the ability to move all extremities through a full range. In the advanced stages of the disease respiration became labored and gasping. Slight transient urinary incontinence was observed only in two of the most severe cases, and the fur remained clean. Sensory examination was usually unrewarding, but in a few animals tested pain sense appeared to be preserved. There were no symptoms suggestive of brain involvement even in terminal phases of the disease. In animals with mild EAN (graded +) slight abnormalities of locomotion were the only evidence of disease.

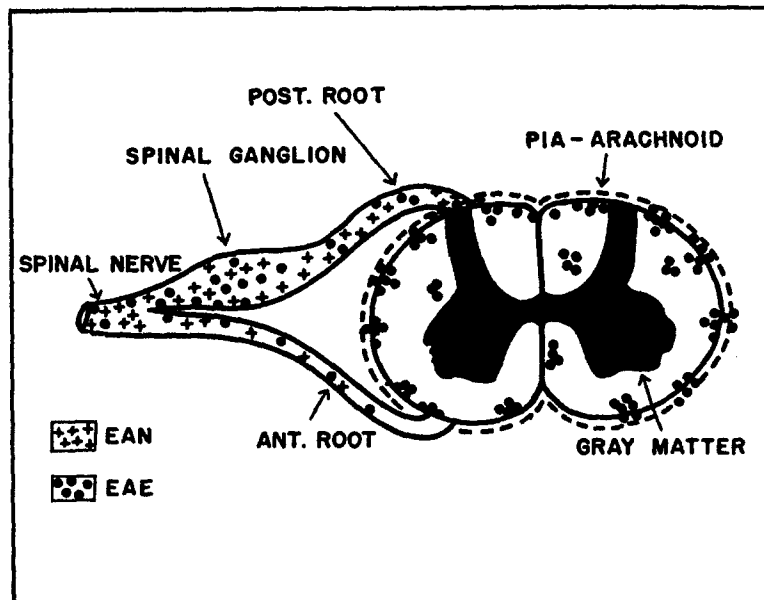
The average day of onset of EAN, in cases in which a definite onset could be determined, was the 14th day following inoculation. Whatever the severity of the illness, the symptoms usually progressed rapidly and reached a maximum within 3 days. Certain unusually marked cases terminated in death during this period. Most of the remaining animals however, after the signs had been stationary for 2 or 3 days, made a rapid and more or less complete symptomatic recovery. The average total duration of symptoms in 8 animals with disease of varying severity which were followed to complete symptomatic recovery was 6 days. However, at least one rabbit had not recovered completely 19 days after the onset of illness. Study of the chronic phases of this disease process was not carried further. None of the animals was followed long enough to determine whether EAN would recur following remission.

These observations in rabbits afflicted with EAN should be contrasted with those in rabbits with EAE. Paralysis is the main feature of the latter disease. Early in the course of the illness abnormalities of motion, comparable to those occurring in EAN, were frequently seen. These, however, were soon obscured as loss of motor power supervened. In mild cases, weakness was usually manifested by a dragging of the hind legs, as the animal jumped over an obstacle, or by a lack of springiness of the legs when it settled. In more markedly affected animals there was a complete paraplegia or quadriplegia, and urinary or fecal incontinence was invariably present. The average day of onset in this disease, as in EAN, was the 14th. EAE also usually took 1 to 3 days to reach its maximum. However, death was relatively more common and symptomatic recovery was slow and rarely, if ever, complete. Even mild cases usually presented neurological abnormalities several weeks after the onset of illness.

After some experience, on the basis of the symptomatology described above, it was usually possible to decide from an examination of individual animals whether they had EAN or EAE.

Histopathologic Findings.—No abnormalities of the brain, spinal cord, or peripheral nerves were visible to the unaided eye. Unlike the bladder in the animals dying of EAE, the bladder was not dilated and distended with urine.

With the microscope one could perceive a number of changes in nerve roots, spinal ganglia, and peripheral nerves which had been sectioned and stained by the histologic techniques used in this study. These changes were of such constancy and uniformity in all the affected animals that they were



TEXT-FIG. 1. Diagram illustrating anatomical relationships in the central and peripheral nervous systems, with approximate distribution of the lesions of EAN and EAE.

unquestionably the manifestation of a special pathologic process. The lesions varied somewhat in the different parts of the peripheral nervous system and it is convenient therefore to describe those in each part separately. A diagram to show the neuroanatomical distribution of the lesions is presented in Text-Fig. 1.

(a) *Dorsal Roots.*—The dorsal root (that part of the nerve which extends from the place of its junction with the anterior spinal root to the point of its entry into the spinal cord (root entry zone)) was often the site of disease. In fact lesions in the dorsal roots were observed to be only slightly less frequent in the affected animals than spinal ganglion lesions. When present these pathologic changes varied in number from one animal to another. In the most severely diseased animals every root which was examined, at all levels of the spinal cord from the cervical to the sacral, was found to

be involved (grade +++); in mildly diseased animals only scattered lesions were seen in a few of the roots (grade +). The junction of the dorsal root and the spinal ganglion was a site of predilection (Figs. 1 and 2). However, lesions could usually be traced in varying numbers up to but not beyond the root entry zone.

The lesions were easily demonstrated by hematoxylin and eosin, cresyl violet, or any general tissue stain. They consisted of infiltrations of histiocytes (mononuclear leucocytes) and lymphocytes, either in small foci or distributed more diffusely. There were also a few neutrophilic leucocytes in some places. In the vicinity of these cellular infiltrates the delicate, reticulated stroma of the myelin sheaths was disrupted and was replaced by oval-shaped vacuoles or by closely packed aggregations of cells. Intraneural veins were surrounded by variable numbers of lymphocytes and mononuclear leucocytes.

Myelin, axis cylinder, and Sudan fat preparations of these nerve roots disclosed other aspects of this pathologic process. Segments of myelin had disintegrated and remnants of it, in the form of oval or irregularly shaped masses or as droplets of fat in macrophages, were noted. In the severely affected animals nearly all the nerve fibers issuing from the spinal ganglion had disappeared and clusters of macrophages had collected at this site (Figs. 1 *b*, 2 *b*). Axis cylinders were involved to a lesser degree; some of them were unquestionably degenerated, appearing as tortuous, swollen argentophilic fragments.

(*b*) *Ventral Roots*.—The ventral root (that part of the peripheral nervous system extending from the anterior surface of the spinal cord to the point of junction with the dorsal root to form the spinal nerve) was by contrast affected only to a slight degree. In some cases these roots appeared to be entirely normal and in others there was not more than a sparse infiltration of mononuclear cells or lymphocytes. A few isolated nerve fibers in a state of degeneration were revealed by myelin stains and in these places the Sudan stain showed small numbers of fatty macrophages.

(*c*) *Spinal Ganglia*.—The most consistent pathologic change was in or next to the spinal ganglia. Indeed if the ganglia were entirely normal one seldom found lesions in other parts of the peripheral nervous system. The most frequent and most easily recognizable change was an increase in the number and size of histiocytes and infiltrations of lymphocytes within small fascicles of myelinated nerve fibers in the central part of the ganglia. The slightest degree of abnormality (graded +) and presumably the earliest lesion were represented by small numbers of these cells in one or two small foci. The maximal degree of this lesion (graded +++) was a heavy cellular infiltration of all parts of the ganglion by histiocytes, lymphocytes, and in some instances, a few neutrophilic leucocytes (Fig. 3 *c*). In the latter cases some of the ganglion cells had degenerated and their former position was marked by eosinophilic debris which was invaded by pleomorphic histiocytes (Fig. 3 *c*) some of which contained phagocytized material in their cytoplasm (neuronophagia). A few satellite cells could be seen in some of these clusters of cells.

Myelin, fat, and axis cylinder stains offered a delicate and convincing confirmation of the lesion. In severe cases all the myelin sheaths had disappeared and large numbers of phagocytic cells, the aforementioned pleomorphic histiocytes, had replaced them (Figs. 4 and 5). These phagocytic cells contained droplets of fat. Under low magnification, as in Fig. 4, one could see intact medullated fibers entering and leaving the

ganglia but none within it, which indicated the limited segmental character of the myelin degeneration. Axis cylinders were affected less than myelin sheaths. A few axis cylinders had degenerated into twisted, swollen, argentophilic fragments which were visible amongst the cellular infiltrates (Fig. 6). The capsule of the ganglia and the periganglionic fat tissue were not altered.

(d) *Peripheral Nerves*.—Here the lesions were of several types, the most obvious of which was seen in hematoxylin and eosin and Nissl stains, again as a cellular infiltrate. The form of these lesions and their distribution within the nerve are well illustrated in Fig. 7. These cellular foci ranged in size from 50 to 200 μ in length. In a few instances they involved the whole width of the nerve, as in Fig. 8 a, but usually they were narrow, not more than 10 to 15 nerve fibers in width, with their long axis parallel to the longitudinal axis of the fiber. A blood vessel, often an endoneural vein, was observed in the center of many of these lesions but the infiltrating cells, instead of being confined to the perivascular space, extended into the adjacent tissues. The cellular components of these infiltrates were predominately histiocytes (mononuclear leucocytes) with oval or pleomorphic nuclei and there were smaller numbers of lymphocytes. A few scattered neutrophilic leucocytes were seen in some of the lesions. There was degeneration of the medullated sheaths of many of the fibers which lay amongst the histiocytes, (Fig. 8 b). The products of the degenerated myelin had been phagocytized by macrophages and converted into fat, (Fig. 8 c). Axis cylinders were affected to a less degree and usually not more than one or two in any one lesion were definitely degenerated.

In small lesions it was possible to observe the slightest degree and presumably the earliest pathologic change (grade + if only 1 or 2 such lesions were found in the nerve). At most only a few of the myelin sheaths were destroyed and small numbers of mononuclear cells had invaded ovoid fragments of myelin. The myelin sheath at each end of the degenerated segment was intact. Schwann cells were seldom identified within the lesion; and when they were, they appeared to be sound and healthy-appearing cells. In severely affected animals as many as 4 to 5 large foci could be found in a single microscopic section of nerve (graded + + +, Fig. 7 a).

In longitudinal sections it was sometimes possible to trace single fibers through several low power microscopic fields. A few fibers appeared to have degenerated throughout their extent. The myelin sheath was disintegrated and had the form of a chain of ellipsoid or ovoid vacuoles some of which were invaded by mononuclear leucocytes (Fig. 9 a). The axis cylinder of such a fiber was broken into tortuous, unevenly expanded argentophilic structures (Fig. 9 b). This type of nerve fiber change probably is an example of Wallerian degeneration or total neurone degeneration.

The epineurial sheath and the fat cells and blood vessels on the surface of the nerve exhibited no important changes.

(e) *Sympathetic Nerves and Ganglia*.—These were not examined systematically owing to difficulties in obtaining suitable material for study. Ganglion cells in viscera, *i.e.* plexus of Meissner and Auerbach, were not altered. Lesions were seen in a few animals extending to the origin of the white rami communicantes.

(f) *Spinal Cord*.—In contrast to the animals with experimental allergic encephalomyelitis, in which subpial and perivascular foci of myelin destruction and mononuclear cell infiltration are invariably found, as illustrated in Figs. 10 and 11, in experimental

allergic neuritis the spinal cord was entirely normal. Also the spinal meninges were usually free of infiltrating cells. Only in rare cases in which the dorsal roots were heavily infiltrated up to the root entry zone was there a slight excess of mononuclear cells and of lymphocytes in the pia mater. In a few animals an occasional anterior horn cell was swollen and the cytoplasmic chromatin of the perinuclear area had disappeared or was converted into fine dust-like particles—an "axonal reaction" due to damage to the axis cylinder of the cell at some peripheral point. Surprisingly few neuronal changes of this type were found. A few perivascular infiltrates were seen in the spinal cord in 2 animals. However, both of them had the typical lesions of encephalitozoon encephalitis in the brain and we concluded that the spinal cord lesion was caused by this infectious agent and not by our experimental disease.

(g) *Brain*.—There were no pathologic changes in the cerebrum, brain stem, and optic nerves except in the few animals with the encephalitozoon infections. The meningitis and foci of inflammatory cell necrosis in the cerebral cortex were then so typical that there was little difficulty in the diagnosis of this disease.

(h) *Muscles*.—Sections of several muscles from the leg and paravertebral region were prepared in 6 animals. A few small, widely dispersed collections of lymphocytes and mononuclear leucocytes were observed in 3 of the animals. These were usually within the endomysial connective tissue in the vicinity of veins. Single muscle fibers had degenerated within these cellular infiltrates and the altered sarcoplasm was invaded by macrophages. A few enlarged sarcolemmic nuclei were noted in the sound part of the fiber.

(i) *Viscera*.—In several of the experimental animals there were a number of lesions in the liver, heart, lungs, and adrenal glands. Those in the liver were the most frequent. The portal areas contained an excess of histiocytes, lymphocytes, and in some instances a few neutrophilic leucocytes. In some animals these infiltrating cells extended out into the parenchyma and here a few liver cells appeared to have degenerated. In addition small clusters of lymphocytes, mononuclear leucocytes, and neutrophilic leucocytes were situated here and there between cords of liver cells. In the myocardium there were one or more collections of these same cells in the form of focal infiltrates. In some animals one or more muscle fibers next to the lesion were degenerated. The lungs of some animals contained large numbers of lymph follicles showing phagocytic activity in centrally placed reticulum cells. A few small cellular infiltrates were observed in the cortex of the adrenal gland.

In order to convey an impression of the relative involvement of different parts of the nervous system in the 2 diseases under investigation (EAE and EAN), the results of histological grading of the main regions of the nervous system in all animals included in the present study are summarized in Table I. It is evident that EAN is distinguished from EAE both by the complete absence of lesions in the central nervous system (including the optic nerves) and by the somewhat greater frequency and intensity of the lesions in the peripheral nervous system. Meningeal inflammation, a major component of the histologic picture in EAE, was infrequent and mild in EAN. An additional tabulation (Table II) permits a comparison of the degree of disease,

as estimated histologically, with the overt antemortem symptoms. The agreement was surprisingly close, considering that each series of data was judged independently.

Cerebrospinal Fluids.—Table III contains the results of one or more cisternal fluid determinations in the majority of the animals forming the sub-

TABLE I
Relative Involvement of Different Regions of the Nervous System in EAN and EAE

Region of nervous system	EAN					EAE				
	No. of rabbits*	Per cent with severity				No. of rabbits*	Per cent with severity			
		0	+	++	+++		0	+	++	+++
Cord, brain, and optic nerve	52	100	0	0	0	94	11	38	35	16
Meninges	52	85	11	4	0	94	8	43	32	17
Root entry zones	51	35	63	2	0	92	26	42	28	4
Spinal nerve roots	52	12	54	32	2	89	45	47	6	2
Spinal ganglia	52	8	48	36	8	67	22	45	21	12
Peripheral nerves	51	20	54	24	2	56	63	26	9	2

* In certain rabbits, particular parts of the peripheral nervous system were missing, largely in groups with EAE autopsied before the present study was begun.

TABLE II
Relation of Symptomatology of EAN to Severity of Histologically Observed Lesions

Severity of EAN symptoms	Average day of onset	Severity of histological EAN*			
		0	+	++	+++
0	—	4	2	2	0
± or +	17	0	11	7	1
++	13	0	4	13	2
+++	12	0	0	3	3

* Severity in this table is the grade assigned to the most severely affected region of the nervous system.

ject of this report. Comparable determinations in normal rabbits and in rabbits which remained normal at various intervals after inoculation with mixtures containing adjuvants are included. The data confirm the finding of Kabat *et al.* (18) that EAE results in a marked elevation both of the white cells and of the total protein in the spinal fluid. In contrast, in the EAN animals, there was an elevation of the protein content whereas the white blood cells generally remained normal. There were instances of definite disease with no apparent spinal fluid changes and cases in which an unusually high cell count was found in EAN or a low count in EAE. It appeared however

that the count, both in EAE and EAN cases, depended largely on meningeal inflammation. A significant correlation (tested by χ^2) was found to exist between the degree of elevation of the white cell count and the severity of histological involvement of the meninges, spinal roots, and ganglia. The cells seen in the more normal fluids were always small lymphocytes. However, when the count was elevated, there were also present considerable numbers of large mononuclear cells. Polymorphonuclear leucocytes were very seldom found and when present usually indicated contamination of the cerebrospinal fluid with blood.

TABLE III
Spinal Fluid Findings in Normal and Diseased Rabbits

Disease category*	Fluids examined	Fluids forming clot	Total protein			White cells		
			Range	Mean	Median	Range	Mean	Median
Normals	23	0	17-53	24	25	1-38	7	5
No disease following inoculation with adjuvants‡	94	0	14-65	31	29	2-40	10	8
EAE								
Mild	19	0	24-88	46	39	3-154	26	10
Moderate-severe	15	3	54-575	251	222	13-2650	348	96
EAN								
Mild	18	1	33-175	58	47	2-144	15	6
Moderate-severe	25	5	36-650	139	98	3-80	23	14

* Disease considered mild when symptoms and histological grade were + or less.

‡ Omitting 3 clearly positive fluids, in which disease (EAE) had apparently been missed both ante mortem and histologically. Includes cases with questionable symptoms and no histological findings.

Relation of Inoculation Antigen to Character of Disease—The use of sciatic nerve tissue from several mammalian sources, as well as of rabbit ganglia or autoclaved rabbit sciatic nerve tissue, in combination with the usual adjuvants, produced essentially the disease picture that has been described in the foregoing paragraphs (Table IV). The relative involvement of different sites in the peripheral nervous system appeared to be comparable in the different groups, as did the day of onset and the intensity of the disease seen histologically.

The production of EAE by the injection of whole rabbit spinal cord, brain, or optic nerve, or of bovine white matter and its fractions resulted (Table V) in the development of lesions in the central nervous system, as described in

earlier publications (14, 15), and in the peripheral nervous system. Myelin degeneration and cellular infiltration of the spinal ganglia appear to be a common phenomenon in the EAE of rabbits, whereas involvement of the peripheral nerves is relatively less frequent. It was thought that possibly

TABLE IV
Comparison of the Effectiveness of Peripheral Nerve Antigens from Different Species in Producing EAN

Antigen	No. of Rabbits	Per cent with involvement of:					Average day of onset*
		CNS	Meninges	Roots	Ganglia	Nerve	
Rabbit sciatic	12	0	17	83	83	75	17
Autoclaved rabbit sciatic	4	0	25	100	100	50	18
Rabbit ganglia	6	0	17	83	83	67	14
Bovine sciatic	7	0	14	100	86	100	13
Human sciatic	4	0	0	75	100	75	14
Dog sciatic	7	0	29	100	86	100	13
Guinea pig sciatic	12	0	17	92	100	92	12
Total.....	52	0	18	90	91	83	14

* Excluding rabbits with minimal signs of disease.

TABLE V
Involvement of Peripheral Nervous System in Rabbits with EAE

Antigen	No. of Rabbits	Per cent with involvement of:					Average day of onset
		CNS	Meninges	Roots	Ganglia	Nerve	
Rabbit cord, brain, or optic nerve	49	88	92	51	70	50	13
Whole bovine white matter	14	93	93	73	100	36	13
Bovine white matter fractions	17	88	88	81	88	46	15
Fractions from one bovine white matter sample	13	100	92	63	78	0	16
Total.....	93	90	91	61	76	35	14

the antigen made of whole rabbit spinal cord may have contained enough root material as a contaminant to account for the occasional severe peripheral nerve lesions produced. However, inoculation with optic nerve produced similar lesions, and bovine white matter, obtained from the centrum semi-ovale and brain stem and relatively free of peripheral nervous tissue, produced involvement of both ganglion and peripheral nerve. Indeed two animals of the group injected with bovine white matter fractions developed

only peripheral lesions. Instances of this sort may account for the occasional animals which develop EAE but in which no lesions are found post mortem, since ganglia and nerves are not examined as routine in most laboratories. It is of particular interest that among groups of rabbits injected with a series of fractions prepared from one particular sample of bovine white matter, no peripheral nerve lesions were found, although the central nervous system and the spinal roots and ganglia were involved to the usual extent (Table V).

The use of rabbit optic nerves as antigen resulted in the production of typical EAE. There was nothing in the distribution of the lesions studied histologically to distinguish this disease from that produced with rabbit cord or bovine white matter. In particular there was no unusual involvement of

TABLE VI
Antibody Production in EAN

Rabbit No.	EAN		Complement fixation titre against:			
	Day of onset	Histologic severity	Rabbit sciatic		Rabbit cord	
			Day 10	Day 16	Day 10	Day 16
1	17	++	30	240	60	>480
2	—	0	60	240	120	480
3	9	+++	120	—	60	—
4	17	++	30	120	60	480
5	18	++	60	120	120	240
6	0	+	0	120	0	240
7	16	++	60	240	60	>480

the optic nerves themselves as contrasted with the remainder of the central nervous system. In about half of the rabbits receiving this antigenic mixture, a mild to moderate iridocyclitis appeared at exactly the same time as the symptoms of nervous system disease. This finding will not be further discussed in the present paper.

Passage of Diseased Tissue to Normal Recipients.—Attempts were made to determine whether any infective agent was present in diseased tissue by removing such tissue with aseptic technique, mincing or grinding it in sterile saline, and immediately injecting it into normal recipient rabbits. Spinal cords and ganglia from three donor rabbits with moderately severe EAN failed to produce any manifest or histological disease in four recipients which received the finely ground tissue intraperitoneally (0.5 to 1.5 gm.) or intrathecally (0.07 to 0.3 gm.). Similarly, the minced sciatics of the same three donors produced no changes in recipients injected intraperitoneally (0.08 to 0.2 gm.) or intradermally (0.01 to 0.02 gm.).

Serologic Studies.—The results of complement fixation tests using rabbit

cord (0.05 per cent) and rabbit sciatic nerve (0.1 per cent) as antigen are shown in Table VI. The sera were drawn at 2 intervals after inoculation in one group of animals. The titres on the 16th day were uniformly higher than on the 10th day and were similar for all the rabbits in the group. They bore no relationship to the development of EAN. The titres measured against whole rabbit cord were one tube greater than those measured against nerve

TABLE VII
Relative Antibody Titres against the Inoculation Antigen and Heterologous Antigens in EAN

Inoculation antigen	Rabbit No.	EAN		Complement fixation titre on 11th day against:					
		Day of onset	Histologic severity	Rabbit nerve	Rabbit cord	Rabbit ganglia	Bovine nerve	Human nerve	Dog nerve
Autoclaved rabbit nerve	8	11	++	480	>480	240	480	—	—
	9	25	++	240	480	120	240	—	—
	10	9	+	240	240	60	60	—	—
Rabbit ganglia	11	11	++	240	480	120	120	—	—
	12	27	+	15	0	0	15	—	—
	13	16	++	240	240	120	120	—	—
	14	16	+++	30	60	15	30	—	—
Bovine nerve	15	20	+	30	60	15	240	—	—
	16	12	+	240	480	120	240	—	—
	17	19	++	60	120	60	120	—	—
Human nerve	18	27	+	120	—	—	60	60	—
	19	11	++	480	—	—	240	120	—
	20	20	++	240	—	—	120	60	—
Dog nerve	21	9	+++	480	—	—	120	—	>480
	22	12	++	240	—	—	120	—	480
	24	14	++	240	—	—	120	—	240

in almost all instances. The two exceptions (nos. 3 and 7) were the first animals in the group to develop disease. These showed a relatively greater titre against nerve on the 10th day. In a group of EAE sera similarly titrated, there existed the same apparent one tube difference between the titres to cord and to nerve. Sera of the next groups of EAN rabbits were titrated with homologous antigen, as well as with rabbit and bovine nerves, and in certain instances rabbit ganglia (Table VII). The titre against ganglia was usually 1 or 2 tubes less than that measured against nerve in the groups investigated. The difference between the titres to cord and nerve was observed

again with some regularity. In this rather uniform relationship, our findings differ from the findings in the monkey, in which titres against homologous peripheral nerve are reported (16) as usually low or even absent in the presence of high titres against homologous brain. In those rabbits receiving human nerve, greater titres were found with heterologous antigen than with homologous, while with dog nerve the reverse was the case. Again there was no

TABLE VIII
*Skin Reactivity in EAN to Various Nerve Antigens**

Inoculation antigen	Rabbit	Induration and erythema at 48 hours to:					
		Rabbit nerve	Rabbit cord	Rabbit ganglia	Bovine nerve	Human nerve	Dog nerve
Autoclaved rabbit nerve	8	+	+	+	±	+--+	±
	9	++	++	+	++	+++	+++
	10	+	+	+	+	++	+
Rabbit ganglia	12	+	++	+	+	++	+--+
	13	+	++	+++	+--+	++	+++
	14	+	+--+	+	+	++	++
Bovine nerve	15	+	+--+	±	++++	++	+
	16	+--+	+--+	±	+++	++	+--+
	17	±	+	0	++++	+	+
Human nerve	18	±	+	±	+--+	+++	+--+
	19	+	+	+	++	++++	+++
	20	+	+	±	+--+	++++	++
Dog nerve	22	+	+	0	+++	+++	++++
	23	+	+	+	++	++++	++++
	24	+	++	+	+--+	++++	++++

* All animals skin tested on 11th day with 10 per cent suspension of each antigen in saline. The nerve antigens, particularly human and dog, contained some connective tissue and produced primary irritation.

relation between the titres of antibody and the development of disease. These tables present fairly clear evidence of considerable immunological heterogeneity of the antigens employed. It is interesting that the most intense disease seen appeared in No. 14, a rabbit with almost negligible antibody titre against the antigens tested.

Skin Reactions in EAN.—In view of the earlier finding (15) that rabbits injected with rabbit cord plus adjuvants develop a tuberculin type of skin reactivity toward rabbit cord suspension, correlated both in time and in

degree with the development of EAE, similar tests were carried out in the rabbits injected with various types of sciatic nerve. Skin reactivity to rabbit sciatic and rabbit cord suspension was relatively less than in the case of EAE, and did not show the same type of correlations to disease. On the other hand, the rabbits injected with foreign nerve reacted very strongly to the antigen with which they had been inoculated, and showed some increase in reactivity to the other types of foreign nerve (Table VIII). These reactions were associated with considerable edema at 24 hours and did not change greatly in appearance between the 24th and 48th hours. While they were not studied histologically, it would appear that they represented mixed Arthus and tuberculin-type responses. The pattern of the responses suggests that a number of antigens, some shared by the different types of nerve, participated in individual reactions. These observations appear comparable to the findings of the serologic study, and provide no insight into the mechanism of the disease.

DISCUSSION

The Evidence That EAN is a Non-Infectious Disease Induced by a Myelin Antigen.—The experimental disease described here appears to be an entity not previously known. Its distinguishing features are a symmetrical, ataxic paresis of the extremities, the retention of control of bowel and bladder sphincters, and the elevation of cerebrospinal fluid protein without concomitant increase in cells. These characteristics set it apart from other nervous diseases of the rabbit and particularly from EAE.

In view of the method whereby EAN is produced, it was necessary to make certain that an infectious agent had not been introduced with the antigenic mixture. There are several lines of evidence which rule out this possibility. Autoclaving the mixture did not affect its ability to cause EAN. The lesions of EAN do not resemble those of any known neurotropic virus disease. The ganglion lesion is indistinguishable from that of EAE, in which virus infection is no longer considered seriously as a possible cause. Finally, intradermal, intraperitoneal, or intrathecal injection into normal animals of minced nerve, ganglia, or cord, freshly taken from rabbits with EAN, have failed to transmit the disease.

The same considerations have led us to reject the possibility that EAN is a spontaneous disease of rabbits or a latent infection which is activated by the inoculation. The absence of similar lesions in a large number of control animals inoculated with various antigenic materials with and without adjuvants also tends to refute this idea. The constancy of the relationship between the time of onset and the time of inoculation is at variance with the concept of a spontaneous involvement. And finally, the same type of disease involving

ganglion and nerve has been produced in guinea pigs and mice by a similar technique.⁴ The possibility that antigen passes along fascial planes to the site of the lesion can also be ruled out, since the disease is symmetrically distributed and appears in the nerves of uninoculated limbs.

It seems quite probable that EAN is the same type of disease as EAE, since the lesions of the two are essentially identical in their localization and histological character, are produced by identical techniques, and follow a similar course in time. Indeed when the two diseases overlap in their distribution, in the roots and ganglia in particular, their lesions are indistinguishable. The antigens involved may be judged to be similar by their lack of species specificity and their resistance to autoclaving (1-3, 7, 19, 20). The only conspicuous differences concern the distribution of the lesions as related to the difference in the source of the antigen, and the spinal fluid findings. The concept that both EAN and EAE are due to an immunologic (allergic) process is in the final analysis largely based on the nature of the technique used to produce them, on the existence of the characteristic latent period, and on the inflammatory character of the lesions in the absence of an infectious agent.

The Character of the Disease Process in EAN.—The more specific details of EAN receive some clarification from the pathologic findings. The most constant alterations in the structure of the peripheral nervous system are the degeneration of myelin sheaths, the proliferation of histiocytes, and the perivenous infiltrations of lymphocytes and mononuclear cells. The cellular proliferation or infiltration was more easily visualized than the myelin degeneration, but it was difficult to determine which of these 2 changes occurred first. From experience with all other types of myelin degenerative lesions we know that destruction of the myelin sheath inevitably leads to activation of histiocytes or mononuclear cells. For this reason we are inclined to believe that myelin degeneration may be primary and the histiocytic proliferation, secondary. This is a matter of inference, however, for our microscopic sections have not settled this point. The idea that the proliferation of mononuclear leucocytes, which are activated in hypersensitivity reactions of tuberculin type, is primary, is also tenable.

The myelin in the peripheral nervous system is normally in the form of short segments, each enclosed within the cytoplasm of a Schwann cell and separated from one another by the nodes of Ranvier. These myelinated segments may be destroyed by a process which injures the Schwann cell itself,

⁴ We have confirmed Lumsden's finding that guinea pigs injected with peripheral nerve (homologous or otherwise) develop the typical central lesions of guinea pig EAE. However, a certain proportion of these animals develop nerve and ganglion lesions, comparable to those found in rabbits with EAN, sometimes in the absence of central nervous system damage. These findings will be published in detail elsewhere (25).

one which damages the myelin directly, or one which causes a degeneration of the axis cylinder, as in Wallerian degeneration, or of the entire neurone. In the milder lesions of EAN the myelin change was in some places limited to a few short segments and the axis cylinders were intact, showing that Wallerian degeneration or neuronal destruction had not occurred. Schwann cells were no longer recognizable in many of the lesions; nevertheless we thought we could detect well stained "healthy-appearing" Schwann nuclei in a few. If this be true the myelin degeneration in some foci at least was not the result of direct injury of the Schwann cells. In places where single nerve fibers were degenerated throughout their length, either Wallerian degeneration (total disintegration of all parts of the axis cylinder and myelin sheath distal to the point of injury, *i.e.*, away from the cell body) or destruction of an entire sensory neurone may have occurred. The fragmentation of a few axis cylinders and the swelling and chromatolysis of a few anterior horn cells (axonal reaction) would be consistent with a Wallerian degeneration.

The other notable pathologic feature of this disease, the infiltrations of lymphocytes and mononuclear leucocytes (? monocytes) was greater than one would expect from a simple degeneration of myelin. This we are inclined to regard as a non-infectious type of inflammatory reaction not unlike that which has been seen in allergic reactions of the delayed tuberculin hypersensitivity type (21). The perivascular or perivenous localization of the inflammatory cells was sufficiently constant, especially in the peripheral nerves, to suggest that the disease process was related in some way to the venous part of the circulatory system. Such a relationship is present in a number of types of hypersensitivity reactions (21, 22).

The degeneration of nerve cells in the spinal ganglia was an unexpected finding in EAN. In all other types of demyelinating disease nerve cell disease is not a part of the pathologic picture. There are two possible explanations for such an occurrence. The disease process itself may have directly affected the ganglion cell or the entire primary sensory neurone. Or the nerve cell, which usually survives injury to its axone, may have degenerated because of the proximity of the axis cylinder injury to the cell body. We favor the latter explanation because in milder cases of EAN the nerve cells remained intact and showed no definite alteration, and in many of our severe cases there was extensive disease of nerve fibers within the ganglia; *i.e.*, close to their cells of origin. The inflammatory reaction within these ganglia was so intense that it may have damaged the nerve cells by still another mechanism such as compression or ischemia.

The muscle and visceral lesions which were observed in many of our animals are difficult to interpret. They consisted essentially of collections of lymphocytes or other inflammatory cells and histiocytes. Parenchymal damage was noted in some of the lesions but others were confined to lymphoid tissue

or components of the reticulo-endothelial system. Some workers have emphasized the granulomatous character of similar visceral lesions in EAE and have assumed them to be a part of the generalized hypersensitivity reaction (2, 5, 23). This may be a correct explanation of their occurrence. However, we have seen them in rabbits subjected to many types of hypersensitivity reaction and therefore can not regard them as a characteristic of EAE or EAN. Moreover we have occasionally seen lesions of the same type but to a lesser degree in control animals which had not been sensitized. We are unable at this time to reach a final conclusion concerning their significance.

A satisfactory theory of EAN (as well as of EAE), must, we believe, account for the primary damage to the myelin sheath, the inflammatory reaction, and the perivenous localization of the lesions. The exact means whereby a hypersensitivity to an antigen composed of myelin can create these specific changes has not been determined.

The cerebrospinal fluid changes observed in the present study were reasonably constant. From a comparison of EAN and EAE it would appear that an increase in both cells and protein occurs only when the meninges and the subpial regions of the brain and spinal cord or the spinal roots are actively involved in the inflammatory process. On the other hand increases of protein without pleocytosis may be found in animals with lesions restricted to the peripheral nervous system. This is not surprising in view of the fact that the spinal nerve roots lie within the subarachnoid space and are bathed by the cerebrospinal fluid. It is of particular interest that albuminocytologic dissociation, which characterized a high proportion of EAN animals, is a common feature of "acute infectious polyneuritis," a human disease of unknown etiology (24).

Factors Which May Determine the Distribution of Lesions in EAN and EAE.

—A major problem that arises in connection with EAE and EAN concerns the factor or factors which determine the localization of the lesions. It was observed in previous investigations of EAE that there are wide variations in the topography of the disease. Thus, in a group of animals with EAE following inoculation with a single, presumably homogenous antigen mixture, some may have lesions predominantly in the brain stem, others in the cord; some may have many subpial cord lesions and no involvement of roots or ganglia while others show affection of both the ganglia and spinal cord. Similarly in EAN, some animals may show lesions restricted to the roots, or ganglia, or peripheral nerves and in others all three parts are involved.

We have considered several hypotheses to explain these phenomena. Firstly, there may be more than one antigen in myelin, and their distribution may differ markedly in different species and even from animal to animal within one species. Secondly, their concentration may vary in different sites within the nervous system, thus determining individual patterns of lesion distribution as

sensitivity develops. Thirdly, these hypothetical antigens may have differing capacities to sensitize, and some species of animals or individuals within a species may be more susceptible to sensitization by one antigen than by another. Fourthly, sensitized animals may react with antigens other than those with which they were inoculated; *i.e.*, there may be cross-reactions in this type of immune system. Fifthly, there may be local, individual, or species' variations in the reactive capacity of the vascular tree. And finally, if there is such an entity as local sensitization, it must be included in this list of possibilities.

Before discussing this problem further it may be profitable to review the facts which emerge from our experiments and those of others.

It is clear that in the rabbit injection of heterologous nerve and homologous nerve, ganglion, and root induces lesions only in the nerves, ganglia, or roots. On the other hand injection of cord, brain, or optic nerve or of heterologous white matter gives rise in the rabbit to lesions of both the central and peripheral nervous system. One series of fractions derived from a particular bovine white matter sample produced lesions restricted to the central nervous system and the ganglia with the peripheral nerves remaining uninvolved. Lastly, an injection of homologous or heterologous peripheral nerve produces largely central lesions in the guinea pig, according to the report of Lumsden (9) and our own unpublished results (25) and no lesions at all in the monkey, according to Kabat and Wolf (7).

From these facts, the inference that we are dealing with more than one antigen is inescapable. There must clearly exist in the rabbit's peripheral nervous system an antigen which is absent in its central nervous system. The experimental findings with rabbit cord may perhaps be considered inconclusive since this material may be accompanied by some root substance. However, the development of typical EAE with antigen made of the rabbit optic nerve is free of this objection.⁵ Since this material produces peripheral lesions while the converse does not occur, it would appear that there must be another antigen, limited to the rabbit's central nervous system and capable of giving rise to a sensitivity which can cause reactions at sites where either the peripheral or central nervous antigens occur. The peripheral antigen apparently produces sensitivity which can only be elicited by peripheral antigen and not by central antigen. This same implication is forced upon us by the observations with bovine nerve as contrasted with bovine white matter and its fractions. There may be still other types of antigens, as suggested by

⁵ We have observed that the optic nerve is involved like the brain and spinal cord in EAE and, when used as a source of antigen, produces typical EAE. This confirms the conclusion long established on embryologic and histologic grounds that this structure is essentially a tract of the central nervous system. The distribution of the lesions in animals receiving optic nerve antigen is essentially the same as that produced by whole spinal cord.

the series of bovine fractions which produced central and ganglion lesions but no nerve lesions. These conclusions imply the existence of a series of similar compounds, each possessing antigenicity, in the sense of producing sensitivity and eliciting lesions, and all cross-reacting to varying degrees. Such a series of compounds may be likened to the serum albumins or other well known series of proteins or carbohydrates which, when studied immunochemically, show different degrees of cross-reaction, depending upon the species of animal in which antibody is produced (see reference 26 for detailed discussion of this class of reactions). In the case of such *in vitro* systems, it is usually found that the cross-reaction is less complete than the reaction with homologous antigen. In the *in vivo* system under discussion, inoculation with central antigen produces less peripheral nerve disease than central disease (Table V).

Our findings could alternatively be explained, but perhaps with greater difficulty, by assuming that the central antigen, or still another, a third antigen common to both central and peripheral nervous tissue, occurs in such concentrations as not to elicit central lesions when peripheral nerve is used for inoculation. And finally a third possibility comes to mind—that which postulates a partial antigen (haptens) in peripheral nerve, capable of evoking disease but not of sensitizing the animal, the complete antigen being present in the spinal cord and brain. All these explanations lack the simplicity of the first hypothesis presented.

One is led into increasingly intricate speculations in attempting to account for variations in the reactions of different species. In guinea pigs (9) homologous peripheral nerve, injected in sufficient amount to cause marked central nervous system disease, has produced little or no peripheral nerve disease, a finding which we have confirmed. This may be due to the operation of a vascular factor or a failure of local sensitization, with the result that lesions do not occur at a site which obviously contains antigen; or it may depend on a difference between the amounts of antigen required to produce sensitivity and to elicit disease. The marked variations in lesion distribution among individuals injected with the same material are probably easiest to understand in terms of factors of this type. It is obvious that these and other related problems cannot be solved until purified antigens have actually been isolated (14, 27, 28) and their concentration at various sites determined.

Significance of the Immunologic Findings.—It is idle at present to speculate on the immunologic mechanisms involved in the production of EAN and EAE. The serologic tests reported in these experiments, as in all earlier studies of EAE (4, 16, 29), have demonstrated complement-fixing antibody against the homologous tissue in titres which bear no relationship to the presence or severity of the experimental disease. Kabat has pointed out (16) that in these tests one is measuring a crude reaction between a mixture of antibodies and a variety of antigens. Furthermore it is even possible that if there is an anti-

body which is responsible for disease, it is fixed by "*in vivo* antigen" and is not present in the peripheral circulation (7, 19). The skin reactions in the various groups of EAN animals were strongly positive only in animals which had received and were tested with heterologous antigen. The correlation between skin reaction and the occurrence of nervous disease, noted earlier (15) in investigations of EAE did not obtain. It is apparent that available immunologic techniques will remain uninformative until relatively simple homogeneous antigens can be prepared.

The Similarity of EAN to Human Diseases of the Peripheral Nervous System.—There is a disease or a group of diseases of the human peripheral nervous system which has been called "Landry's paralysis," "acute febrile polyneuritis," "infectious neuronitis," acute "infectious" polyneuritis, and the "Guillain-Barré syndrome" (30). They are characterized by an acute onset of an ascending flaccid motor paralysis with loss of tendon reflexes and sensory changes in the extremities, and by elevation of the cerebrospinal fluid protein without pleocytosis (termed albuminocytologic dissociation by Guillain and Barré (24)). Their cause is unknown. Although attempts to isolate a filterable virus or a neurotoxin have been unsuccessful, an infectious agent has been predicated because of the usual antecedent respiratory or gastrointestinal infection, the acute and sometimes febrile course, and the nature of the pathologic changes.

Complete agreement concerning the morbid anatomy of these diseases has not been reached. In some rapidly fatal cases little or no definite change has been found either in peripheral or central nervous system. Other cases, especially those succumbing during the 2nd and 3rd week of the illness, may exhibit a degeneration of myelinated sheaths and an infiltration of lymphocytes, plasma cells, and mononuclear leucocytes in the spinal ganglia, roots and nerves. Similar aggregates of infiltrating cells may be found in the visceral organs (31). In some of the cases which we have examined post mortem the disease was more intense in the spinal roots and ganglia than in the peripheral nerves, the myelin was affected more than axis cylinders, and the nerve fibers suffered greater damage than the nerve cells in the spinal ganglia or spinal cord. Moreover the inflammatory cells in the nerves tended to collect around venules and small veins. Other cases of approximately the same duration have shown little or no change. This fact and the variable clinical course in series of cases of acute "infectious" polyneuritis suggest that more than one disease is being subsumed under this title.

It is of course highly speculative that a disease of the peripheral nervous system of a rabbit may be the same as a well known human disease merely because of a certain similarity of pathologic findings. Nevertheless the resemblances are sufficiently impressive to justify a further exploration of the possibility that acute "infectious" polyneuritis may have an immunologic

basis. This has already been suggested by a number of writers who could not otherwise comprehend the inflammatory character of the pathologic findings, the clinical sequence of non-specific infection followed after an interval of time by polyneuritis, and the prompt recovery following ACTH and cortisone therapy, which has been reported in some cases.

EAN provides the first experimental model of a reproducible non-infectious inflammatory disease of the peripheral nervous system.

SUMMARY

In experimental allergic encephalomyelitis (EAE), produced by injecting rabbits with whole rabbit spinal cord together with tubercle bacilli and mineral oil, lesions comparable to those seen in the central nervous system are found in the nerve roots, spinal ganglia, and peripheral nerves. When special fractions of bovine white matter are used as antigen in rabbits, the same distribution of lesions is seen but peripheral nerve involvement is relatively less frequent.

When rabbit sciatic nerve or spinal ganglia are used as antigen in rabbits, lesions occur only in the roots, ganglia, and peripheral nerves. Lesions are not produced in the central nervous system, nor is there a meningitis. This disease picture has been called experimental allergic neuritis (EAN). The antigenicity of rabbit nerve is not impaired by autoclaving. Sciatic nerve of other mammalian species produces the same disease in rabbits as does rabbit nerve.

Optic nerve, used as antigen, produces the typical picture of EAE, not EAN. The optic nerves are not affected in EAN, whereas they commonly contain lesions in EAE.

There are differences of symptomatology, referable to the difference in distribution of lesions, between EAE and EAN. The spinal fluid of EAE shows an increase both in the number of cells and in the total protein content. In EAN, the same changes in protein are observed, but usually the cell count remains normal. The cell count appears to be related to the involvement of cerebral and spinal meninges, which is an almost invariable accompaniment of EAE. The skin tests and serologic studies made with homologous and heterologous antigens were essentially non-contributory, apparently as a consequence of the diversity of antigens present in the inoculated materials.

The similarity between EAN and certain of the human polyneuritides is indicated and discussed.

BIBLIOGRAPHY

1. Innes, J. R. M., *J. Comp. Path. and Therap.*, 1951, **61**, 241.
2. Ferraro, A., and Roizin, L., *J. Neuropath. and Exp. Neurol.* 1954, **13**, 60.
3. Freund, J., Stern, E. R., and Pisani, T. M., *J. Immunol.*, 1947, **57**, 179.
4. Hill, K. R., *Bull. Johns Hopkins Hosp.*, 1949, **84**, 302.
5. Allegranza, A., and Cazzullo, C. L., *Boll. soc. ital. patol.*, 1950, **1**, 3.

6. Morgan, I. M., *J. Exp. Med.* 1947, **85**, 131.
7. Kabat, E. A., Wolf, A., and Bezer, A. E., *J. Exp. Med.*, 1948, **88**, 417.
8. Alvord, E. C., Jr., *J. Immunol.*, 1949, **61**, 355.
9. Lumsden, C. E., *Brain*, 1949, **72**, 198.
10. Hurst, E. W., *J. Hyg.*, Cambridge, Eng., 1932, **32**, 33.
11. Hurst, E. W., *Am. J. Med.*, 1952, **12**, 547.
12. Kolb, L. C., *Medicine*, 1950, **29**, 99.
13. Weil, A. J., *Bact. Rev.*, 1941, **5**, 293.
14. Waksman, B. H., Porter, H., Lees, M. D., Adams, R. D., and Folch, J., *J. Exp. Med.*, 1954, **100**, 451.
15. Waksman, B. H., and Morrison, L. R., *J. Immunol.*, 1951, **66**, 421.
16. Lumsden, C. E., Kabat, E. A., Wolf, A., and Bezer, A. E., *J. Exp. Med.*, 1950, **92**, 253.
17. Kingsbury, F. B., Clark, C. P., Williams, G., and Post, A. L., *J. Lab. and Clin. Med.*, 1926, **11**, 981.
18. Kabat, E. A., Wolf, A., Bezer, A. E., and Murray, J. P., *J. Exp. Med.*, 1951, **93**, 615.
19. Kabat, E. A., Wolf, A., and Bezer, A. E., *J. Exp. Med.*, 1947, **85**, 117.
20. Lumsden, C. E., *Brain*, 1949, **72**, 517.
21. Gell, P. G. H., and Hinde, I. T., *Brit. J. Exp. Path.*, 1951, **32**, 516.
22. Abell, R. G., and Schenck, H. P., *J. Immunol.*, 1938, **34**, 195.
23. Campbell, B., and Good, R. A., *Arch. Neurol. and Psychiat.*, 1950, **63**, 298.
24. Guillain, G., Barré, J. A., and Strohl, A., *Bull. et mém. Soc. méd. hôp. Paris*, 1916, **40**, 1462.
25. Waksman, B. H., and Adams, R. D., unpublished data.
26. Kabat, E. A., and Mayer, M. M., *Experimental Immunochemistry*, Springfield, Illinois, Charles C. Thomas, 1948, 216.
27. Tal, C., and Olitsky, P. K., *Proc. Soc. Exp. Biol. and Med.*, 1952, **81**, 590.
28. Goldstein, N. P., Kolb, L. C., Mason, H. L., Sayre, G. P., and Karlson, A. G., *Neurology*, 1953, **3**, 609.
29. Thomas, L., Paterson, P. Y., and Smithwick, B., *J. Exp. Med.*, 1950, **92**, 133.
30. Haymaker, W., and Kernohan, J. W., *Medicine*, 1949, **28**, 59.
31. Sabin, A. B., and Aring, C. D., *Am. J. Path.*, 1941, **17**, 469.

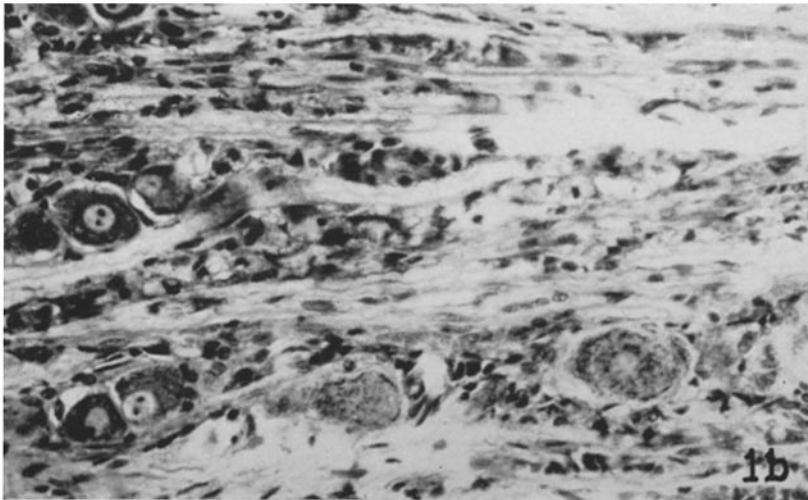
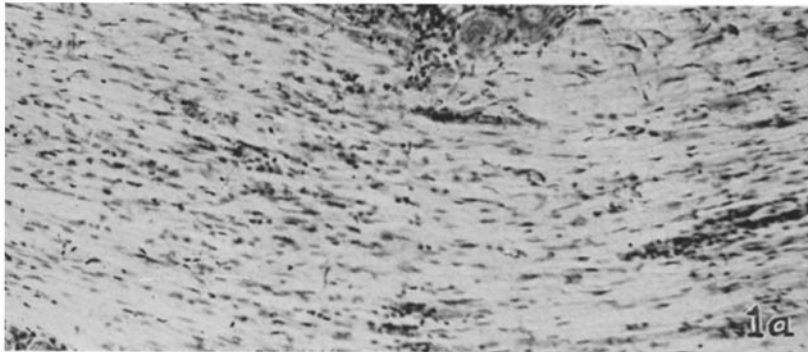
EXPLANATION OF PLATES

PLATE 27

FIG. 1. Posterior roots near spinal ganglia in EAN. (Cresyl violet stain.)

Fig. 1 *a*. There is a diffuse infiltration of histiocytes and the veins are outlined by lymphocytes and mononuclear leucocytes. $\times 120$.

Fig. 1 *b*. The rows of cells with small, irregularly shaped nuclei and vacuolated cytoplasm are macrophages which have replaced degenerating myelinated fibers. Note the intact nerve cells with prominent nucleoli. $\times 180$.



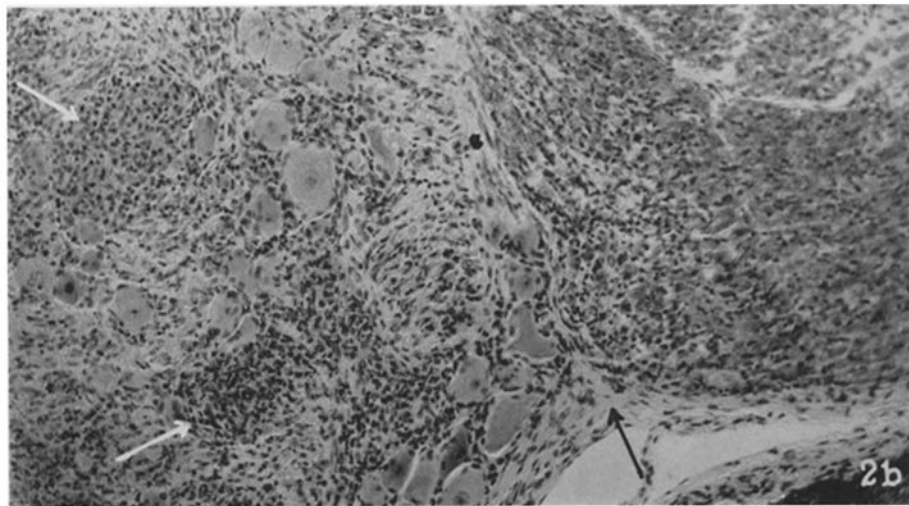
(Waksman and Adams: Allergic neuritis in rabbits)

PLATE 28

FIG. 2. Radicular and ganglion lesions in EAN. The arrows mark the junction of posterior root and ganglion.

Fig. 2 *a*. Histiocytic proliferation among nerve fibers and ganglion cells; perivenous cuffing of lymphocytes and mononuclear leucocytes. Cresyl violet stain. $\times 100$.

Fig. 2 *b*. Degeneration of myelin sheaths in root (at right) at the point of junction with the spinal ganglion (left); cellular infiltration of the ganglion, and neuronophagia (indicated by white arrows). Oil-red-O and hematoxylin. $\times 150$.



(Waksman and Adams: Allergic neuritis in rabbits)

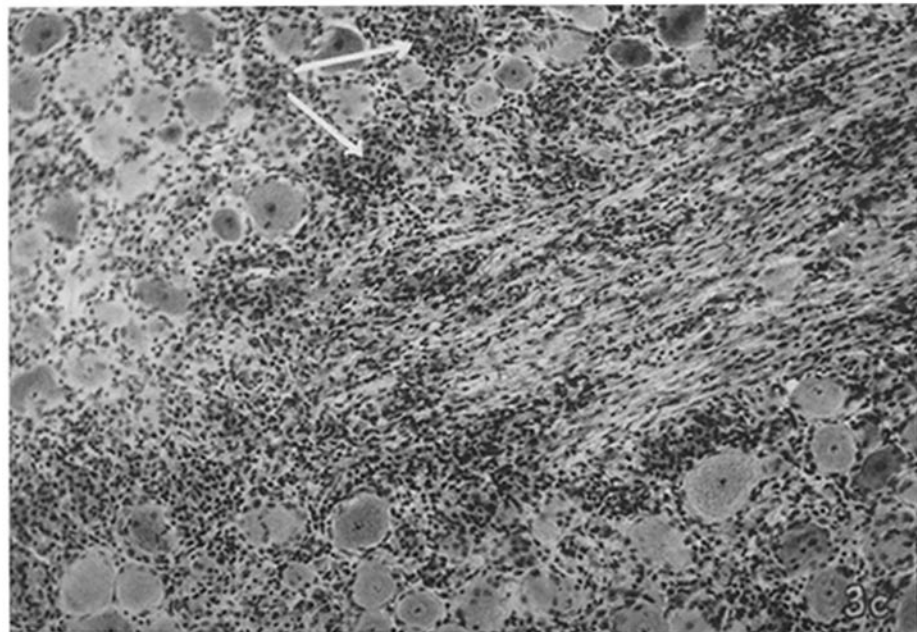
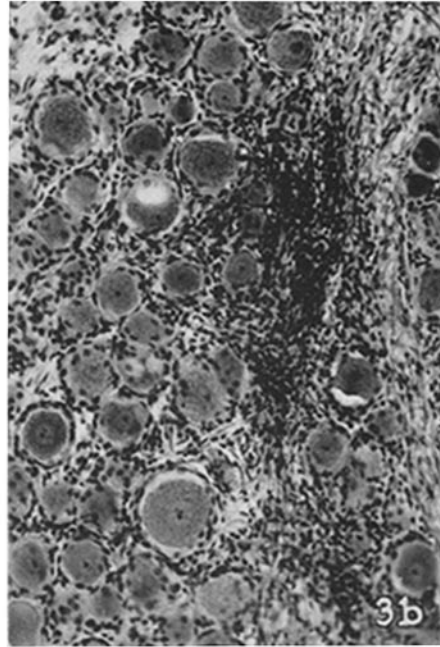
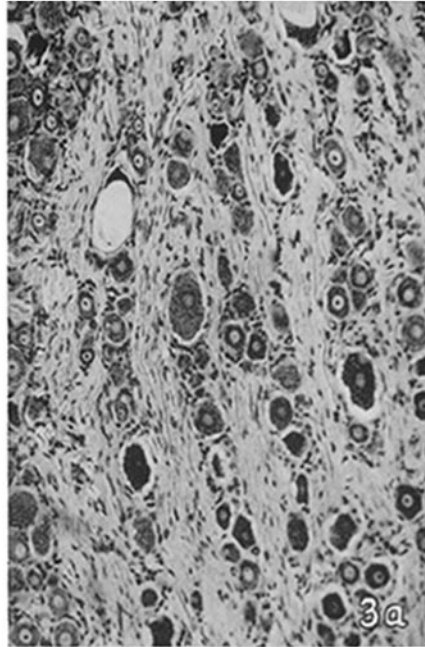
PLATE 29

FIG. 3. Spinal ganglion lesions in EAN.

Fig. 3 *a*. Normal rabbit ganglion. Cresyl violet stain. $\times 120$. The ganglion cells have dark cytoplasm, pale nuclei, and prominent nucleoli. Schwann cell and fibroblast nuclei appear as dots amongst the fibers separating the ganglion cells.

Fig. 3 *b*. Focal infiltration of lymphocytes and mononuclear cells. Hematoxylin and eosin. $\times 180$.

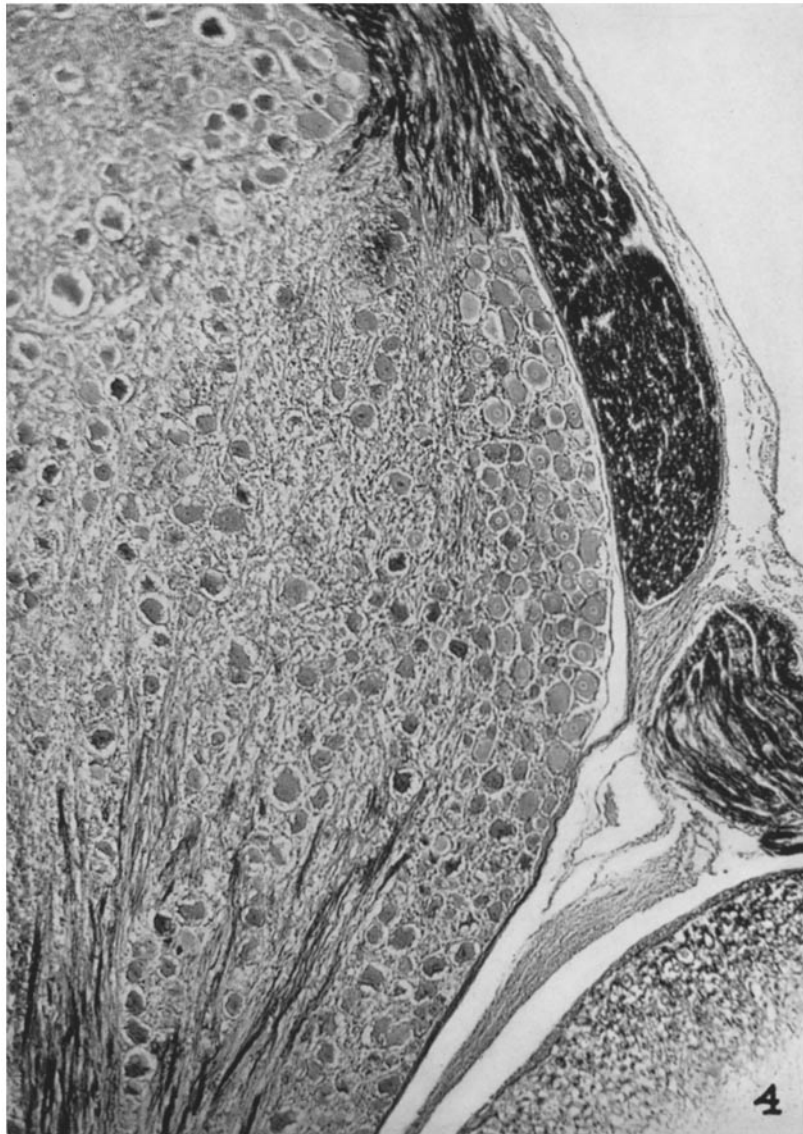
Fig. 3 *c*. Proliferation of histiocytes amongst nerve fibers in the central part of the ganglion and aggregations of activated histiocytes (white arrows) replacing nerve cells (neuronophagia). Hematoxylin and eosin. $\times 180$.



(Waksman and Adams: Allergic neuritis in rabbits)

PLATE 30

FIG. 4. Low power view of a spinal ganglion in EAN showing the intact anterior root (staining black) in the right side of the picture, the posterior root entering the ganglion from below and leaving the ganglion above. The spinal cord and meninges are seen in the lower right corner. Note the complete degeneration of myelinated sheaths within the ganglion. Luxol fast blue with cresyl violet counterstain. $\times 80$.

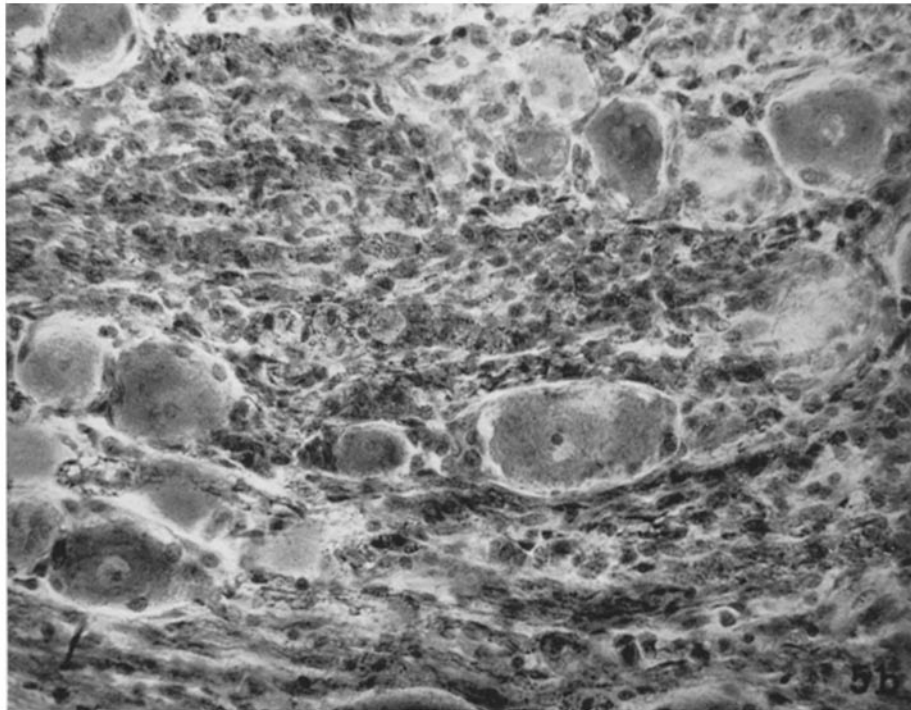
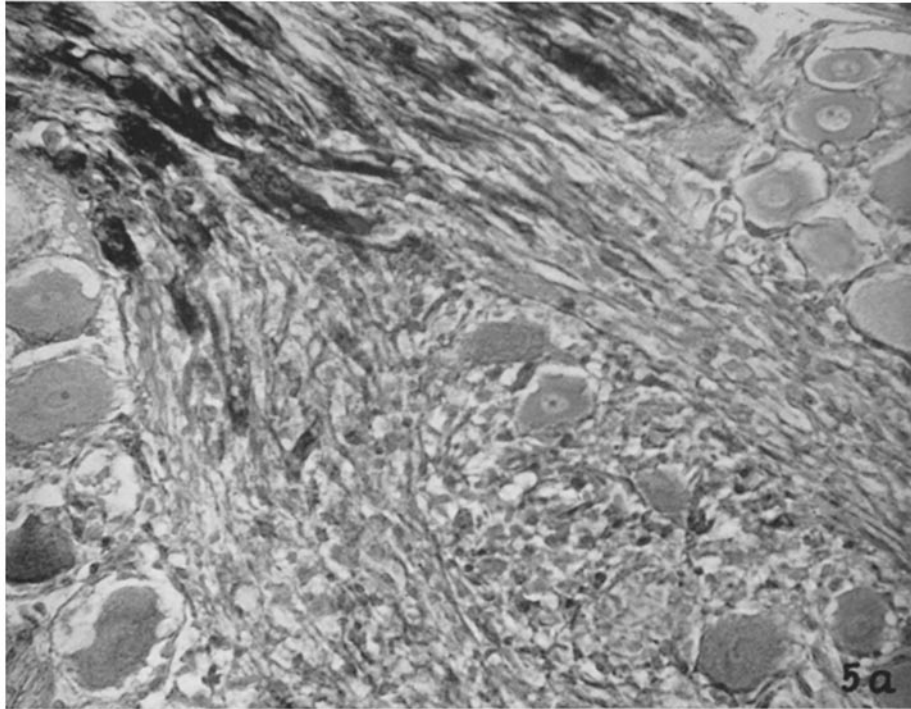


(Waksman and Adams: Allergic neuritis in rabbits)

PLATE 31

FIG. 5 *a*. Higher magnification of Fig. 4 to show degeneration of the myelin sheaths of the intraganglionic fibers. The intact myelin appears as black columns in the upper part of the picture. Luxol fast blue with cresyl violet. $\times 420$.

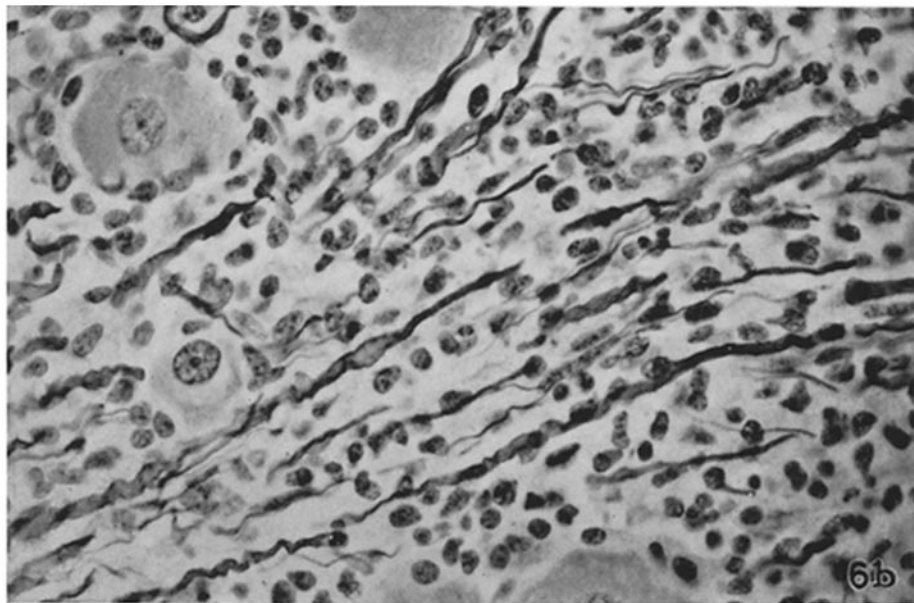
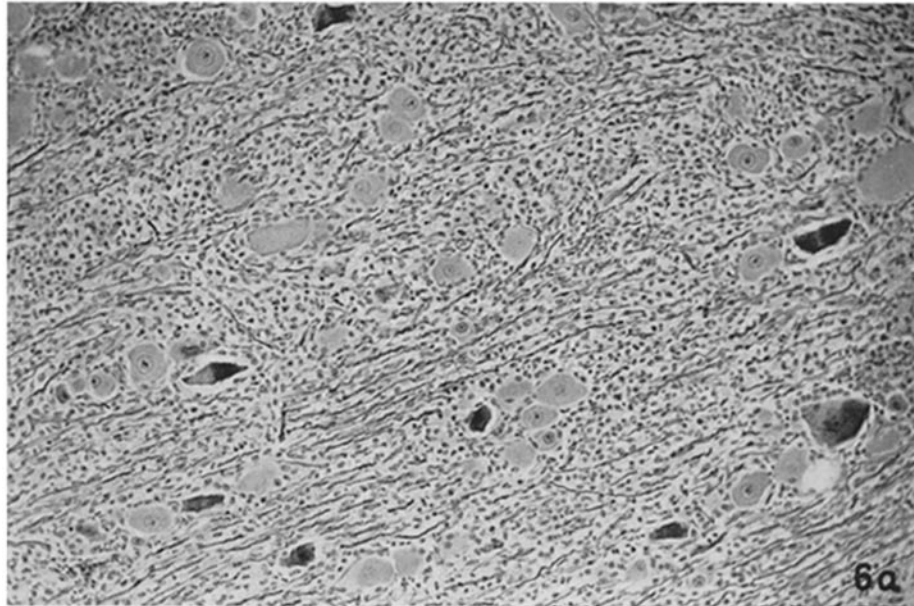
FIG. 5 *b*. The same ganglion in a fat (oil-red-O) and hematoxylin stain. The degenerated myelin is replaced by rows of macrophages which are identified by their granular cytoplasm. The large cells with prominent nucleoli are nerve cells. $\times 420$.



(Waksman and Adams: Allergic neuritis in rabbits)

PLATE 32

FIG. 6. Spinal ganglion lesion. Note large number of preserved axis cylinders appearing as thin wavy lines among cellular infiltrates. A few tortuous and unevenly dilated segments are seen and probably represent degenerating fibers. Bodian stain: Fig. 6 *a*, $\times 160$; Fig. 6 *b* $\times 420$.



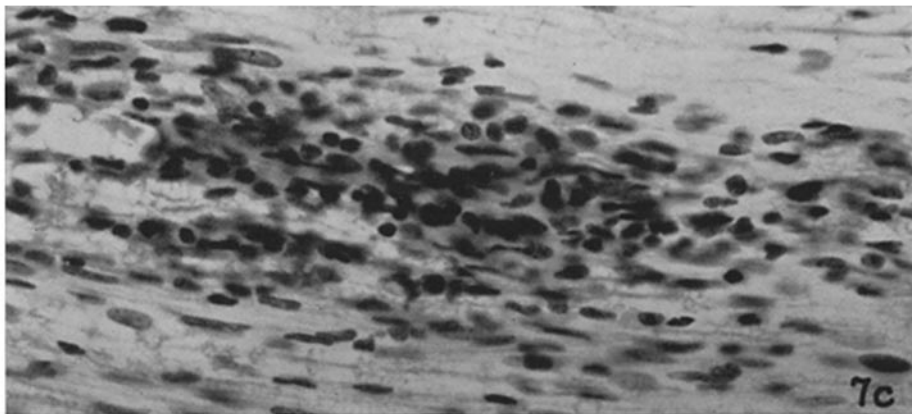
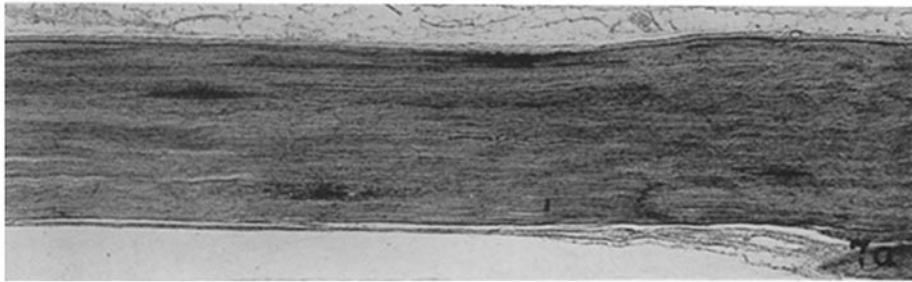
(Waksman and Adams: Allergic neuritis in rabbits)

PLATE 33

FIG. 7. Peripheral nerve lesions in EAN.

Figs. 7 *a* and 7 *b*. Lower power views to show morphology of cellular infiltrates in peripheral nerves. In Fig. 7 *a* a severely affected nerve; 5 lesions are visible. Hematoxylin and eosin. $\times 70$ and $\times 160$, respectively.

Fig. 7 *c*. Perivenous infiltration of lymphocytes and mononuclear cells. The lymphocyte nuclei are round and dark; the mononuclear leucocyte nuclei are oval or elongated. Cresyl violet. $\times 420$.



(Waksman and Adams: Allergic neuritis in rabbits)

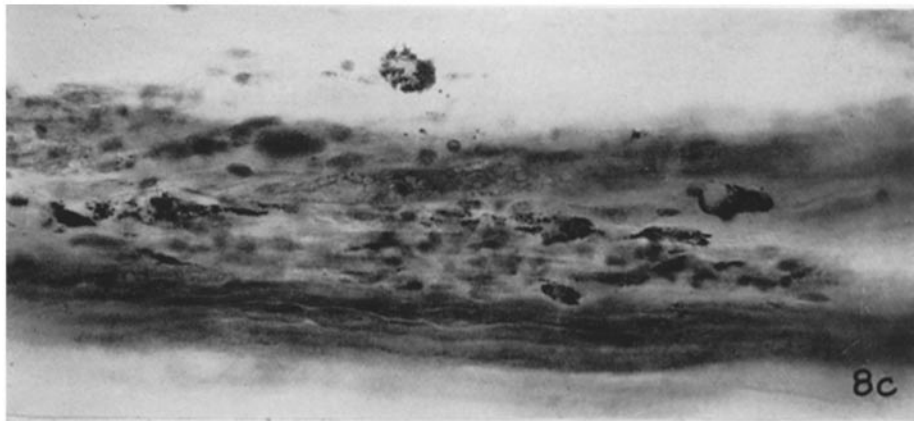
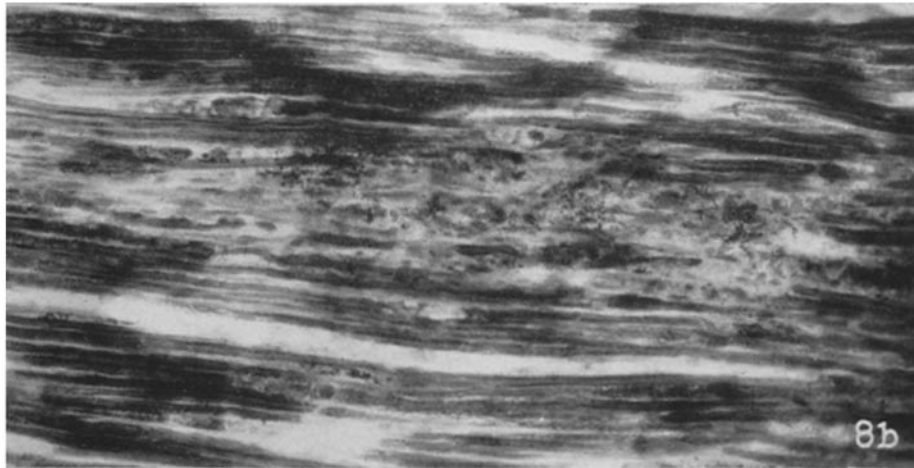
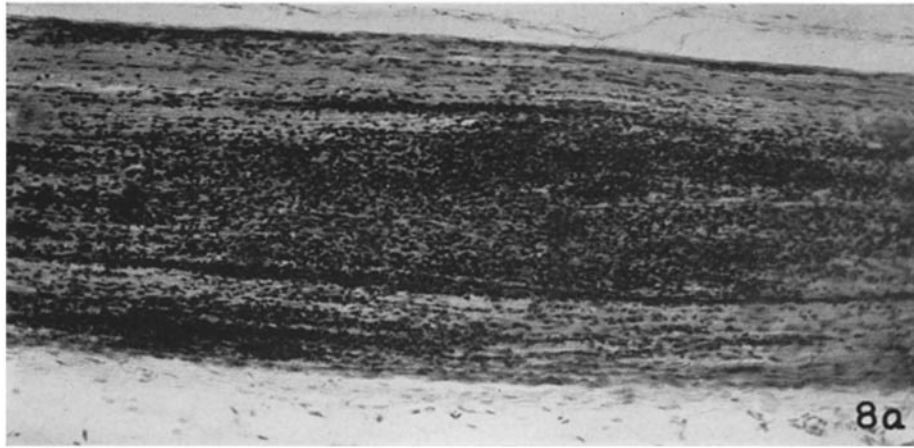
PLATE 34

FIG. 8. Peripheral nerve lesions in EAN.

Fig. 8 *a*. Cellular infiltration of sciatic nerve. Hematoxylin and eosin. $\times 150$.

Fig. 8 *b*. Focal degeneration of myelinated nerve fibers, in vicinity of vein. The myelin sheaths appear as wide straight lines. The granular material in the center of the picture is fragmented myelin and fat. Oil-red-O and hematoxylin. $\times 260$.

Fig. 8 *c*. Higher magnification of a similar lesion to show fatty macrophages. Oil-red-O and hematoxylin. $\times 370$.



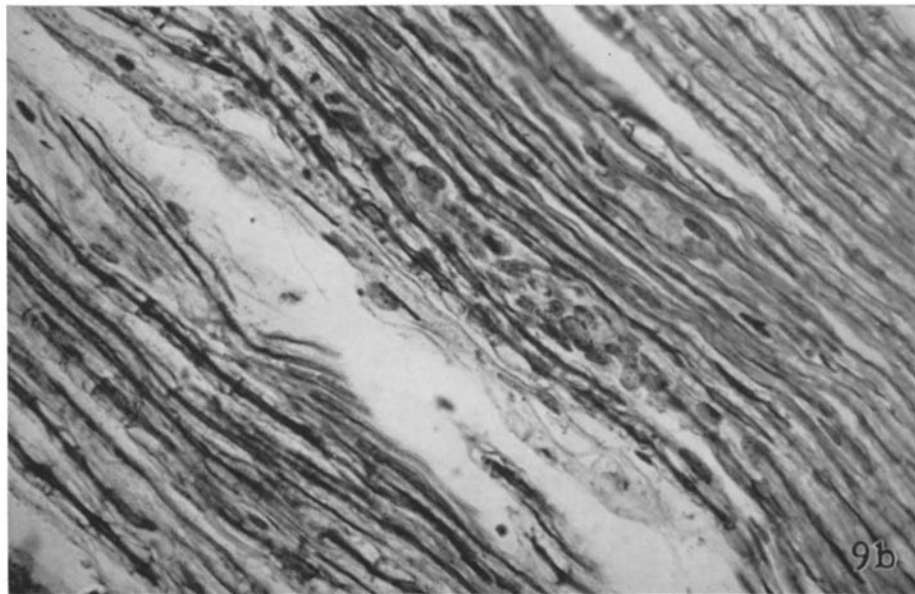
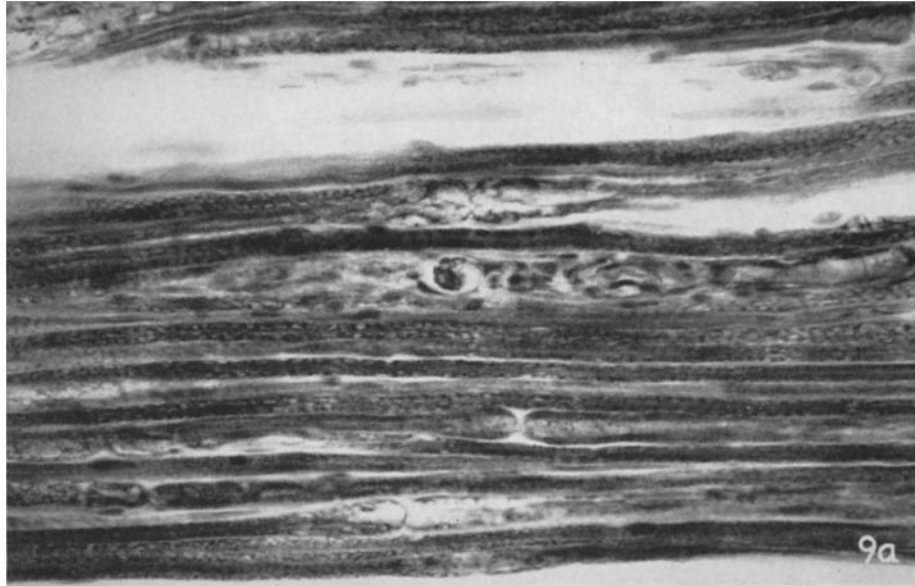(Waksman and Adams: Allergic neuritis in rabbits)

PLATE 35

FIG. 9. Peripheral nerve lesion in EAN. Wallerian degeneration.

Fig. 9 *a*. A single medullated nerve fiber has disintegrated. Two nodes of Ranvier are seen in the lower part of picture. Oil-red-O and hematoxylin. $\times 370$.

Fig. 9 *b*. A fragmented axis cylinder has been replaced by a column of histiocytes. Bodian. $\times 370$.

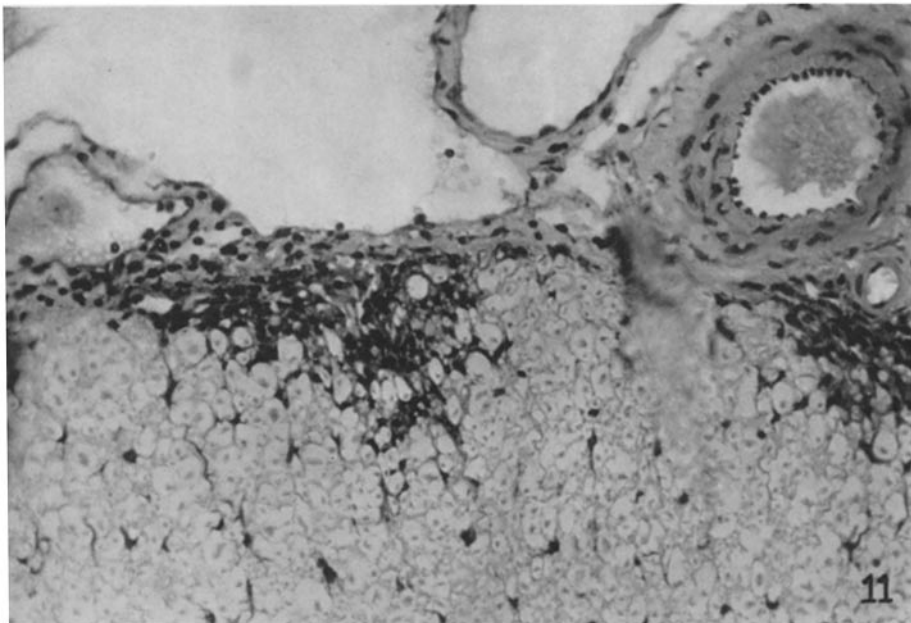
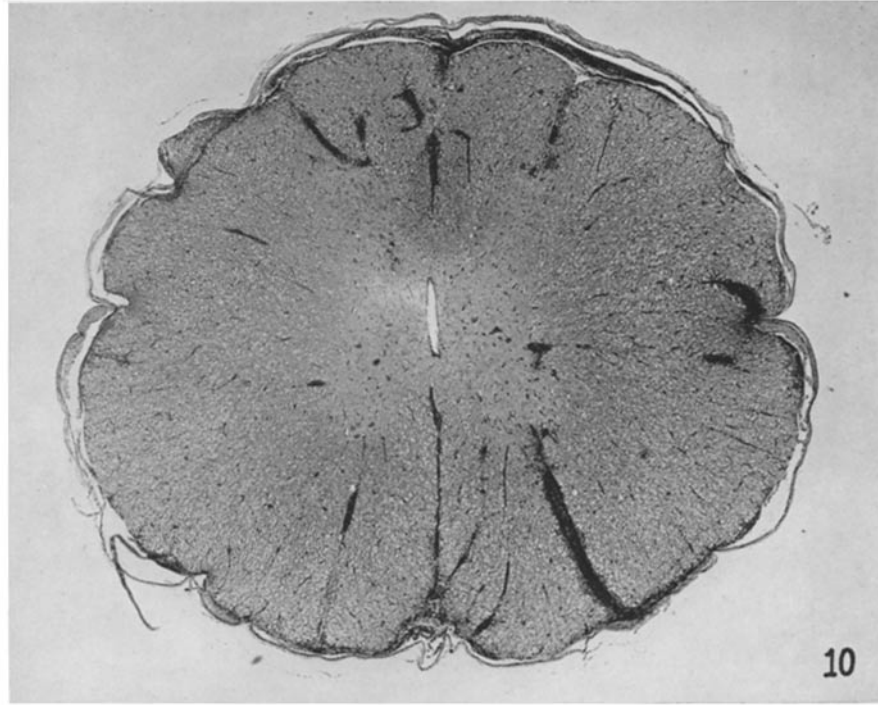


(Waksman and Adams: Allergic neuritis in rabbits)

PLATE 36

FIG. 10. Spinal cord lesions in EAE. Hematoxylin and eosin. $\times 26$. Note meningeal infiltrations (of lymphocytes and mononuclear leucocytes) and subpial and perivenous infiltrations (of microglial cells) in spinal cord.

FIG. 11. Spinal cord lesion in EAE. Characteristic subpial lesion with a collection of pleomorphic microglial cells. Intact axis cylinders represented by small dots in the center of round clear zones, are visible within the lesion. Cresyl violet. $\times 160$.



(Waksman and Adams: Allergic neuritis in rabbits)