

# Magnetic Resonance Imaging Fusion Transrectal Ultrasound-guided Biopsy for Diagnosis of Prostate Cancer

Hsin-Kai Wang<sup>1,2\*</sup>

<sup>1</sup>Division of Ultrasound and Breast Imaging, Department of Radiology, Taipei Veterans General Hospital, Taipei, Taiwan, <sup>2</sup>School of Medicine, National Yang Ming Chiao Tung University, Yangming Campus, Taipei, Taiwan

## THE DEVELOPMENT OF TARGETED BIOPSY AND IMAGING FUSION FOR THE PROSTATE CANCER

Systematic biopsy of the prostate using transrectal ultrasound (TRUS) is the traditional diagnostic method for prostate cancer. This standard practice has undergone significant changes in recent years with the rise and popularity of magnetic resonance imaging (MRI). Multiparametric MRI combines image information of T2-weighted images, diffusion-weighted images, and dynamic contrast-enhanced images, and is effective in detecting and localizing prostate cancer.<sup>[1]</sup> Hence, the targeted biopsy of the lesion detected by MRI has become a clinical demand to acquire a pathological diagnosis and guide further management. However, as opposed to systematic biopsy, targeted biopsy requires additional equipment support to achieve lesion targeting. Among all available methods, in-bore MRI-guided biopsy provides the most straightforward solution, in which the single imaging modality (MRI) is utilized for both lesion detection and guidance for targeted biopsy. However, the procedure is complicated and requires MR-compatible facilities. There are limited medical systems that can provide enough capacity to perform in-bore MRI-guided biopsy for all patients with lesions identified by prostate MRI. Alternatively, targeted biopsy using TRUS, as in systematic biopsy, involves an operator reviewing the MRI in advance and localizing the corresponding lesions in the TRUS image for targeted biopsy, known as cognitive TRUS-targeted biopsy. This method can be accomplished by employing the existing devices applied in TRUS-guided prostate biopsy. However, the operator requires a skilled anatomical perception to achieve accurate positioning. Besides, a substantial number of the lesions identified in MRI are not demonstrated on ultrasound images. Therefore, difficulty in lesion localization in TRUS images may be encountered with

the accuracy of lesions targeting greatly dependent on the experience of the operator. The imaging fusion technology is the key solution to overcome the limitations of in-bore MRI-guided biopsy and cognitive TRUS-guided biopsy. Imaging fusion is a mature technology in the ultrasound-guided interventional procedure of the liver and has gradually been applied to guide prostate biopsy in recent years. This specific method employs an electromagnetic sensor to detect the position and scanning plane of the ultrasound transducer, and timely reconstruct the MR image equivalent to the sectional plane of TRUS. The TRUS image and reconstructed MR image are simultaneously displayed side by side or overlay to assist lesion positioning for targeted biopsy [Figure 1].

## INTRODUCTION OF IMAGING FUSION TECHNOLOGY

Currently, there are different imaging fusion systems commercially available for targeted prostate biopsy, some are developed by manufacturers that focus on prostate image fusion technology, while others are developed by producers of conventional ultrasound scanners. These image fusion systems can be divided into two types: rigid fusion and elastic fusion.<sup>[2]</sup> In general, rigid fusion system is the same technology utilized in the imaging fusion of the liver, which extends its application to TRUS transducer for prostate biopsy. The elastic fusion systems were originally designed for prostate biopsy and calibrate the changes of the prostate contour during imaging fusion, potentially improving the accuracy of lesion targeting. The elastic fusion system is more expensive and more commonly used in Europe and the United States,

**Address for correspondence:** Dr. Hsin-Kai Wang,  
Division of Ultrasound and Breast Imaging,  
Department of Radiology, Taipei Veterans General Hospital,  
Taipei, Taiwan.  
E-mail: ushkwang@gmail.com

Received: 02-03-2021 Revised: 15-04-2021 Accepted: 16-04-2021 Available Online: 21-06-2021

### Access this article online

Quick Response Code:



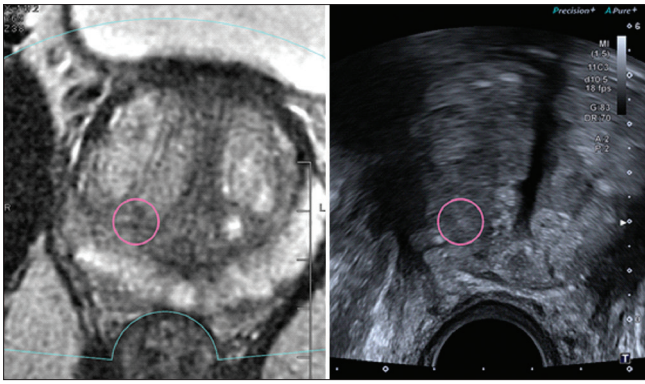
Website:  
[www.jmuonline.org](http://www.jmuonline.org)

DOI:  
10.4103/jmu.jmu\_96\_21

This is an open access journal, and articles are distributed under the terms of the Creative Commons Attribution-NonCommercial-ShareAlike 4.0 License, which allows others to remix, tweak, and build upon the work non-commercially, as long as appropriate credit is given and the new creations are licensed under the identical terms.

For reprints contact: WKHLRPMedknow\_reprints@wolterskluwer.com

**How to cite this article:** Wang HK. Magnetic resonance imaging fusion transrectal ultrasound-guided biopsy for diagnosis of prostate cancer. *J Med Ultrasound* 2021;29:75-6.



**Figure 1:** Transrectal ultrasound-guided targeted prostate biopsy using rigid imaging fusion device (Aplio i-series A800, Canon Medical Systems) with a transcavitary curvilinear transducer, 3–11 MHz): A 69-year-old man underwent a blood test and was found to have an elevated prostatic specific antigen (11.4 ng/dl, normal value: <4 ng/dl). Magnetic resonance imaging revealed a suspected lesion in the right lobe of the prostate. The picture on the right is the axial transrectal ultrasound image of the prostate, and the picture on the left is the reconstructed T2-weighted magnetic resonance imaging. With the aid of imaging fusion, the lesion located at the posterior edge of the right transition zone of the prostate was identified in the ultrasound image (red circles). Targeted biopsy found Gleason score 3 + 4 adenocarcinoma. Systematic biopsy performed at the same session also found Gleason score 3 + 3 adenocarcinoma in the prostate on the same side of the target lesion

while the rigid fusion system can be achieved by upgrading the conventional ultrasound machine, which has lower cost and is more commonly used in regions outside Europe and the United States.

## TARGETED BIOPSY VERSUS SYSTEMATIC BIOPSY

Targeted biopsy with imaging fusion has superior specificity and sensitivity for the diagnosis of prostate cancer when compared with systematic biopsy. Targeted biopsy has a relatively higher detection rate for clinically significant prostate cancer (Gleason score  $\geq 3 + 4$ ) and a lower detection rate for clinically insignificant prostate cancer (Gleason score = 3 + 3), suggesting that targeted biopsy can find more prostate cancers that need active treatment.<sup>[3]</sup> However, targeted biopsy cannot completely replace the role of systematic biopsy because in a few cases, targeted biopsy failed to detect cancer lesions, but systematic biopsy found clinically significant prostate cancers. Two possible reasons for this result are (1) MRI failed to accurately diagnose malignant lesions and (2) targeting error of the imaging fusion-guided biopsy.<sup>[4]</sup> A combination of

targeted biopsy and systematic biopsy offers best diagnostic rate for clinically significant prostate cancer, implying that there is room for optimization in the multiparametric MRI or targeted biopsy technology.

## FUTURE PROSPECT

Targeted prostate biopsy has brought changes in the diagnosis of prostate cancer, and also potentially leads to conceptual changes of its treatment. For example, is the certain tumor grade (such as Gleason 4 + 3, grade group 3) obtained by targeted biopsy of the same clinical outcome as that obtained by systematic biopsy? Do they have the same prognosis? For another example, as opposed to radical prostatectomy, focal therapy may become a choice of prostate cancer treatment, especially for patients with solitary tumor focus (account for 20% of prostate cancer) confirmed by MRI and targeted biopsy.<sup>[5]</sup> The above questions are likely to emerge after targeted prostate biopsy being widely adopted in clinical practice, which need to be answered by future evidence.

## Declaration of patient consent

The author certifies that he has obtained all appropriate patient consent form. In the form the patient has given his consent for his images and other clinical information to be reported in the journal. The patient understands that his name and initials will not be published and due efforts will be made to conceal the identity, but anonymity cannot be guaranteed.

## Financial support and sponsorship

Nil.

## Conflicts of interest

There are no conflicts of interest.

## REFERENCES

1. Murphy G, Haider M, Ghai S, Sreeharsha B. The expanding role of MRI in prostate cancer. *AJR Am J Roentgenol* 2013;201:1229-38.
2. Venderink W, de Rooij M, Sedelaar JP, Huisman HJ, Fütterer JJ. Elastic versus rigid image registration in magnetic resonance imaging-transrectal ultrasound fusion prostate biopsy: A systematic review and meta-analysis. *Urol Focus* 2018;4:219-27.
3. Kasivisvanathan V, Rannikko AS, Borghi M, Panebianco V, Mynderse LA, Vaarala MH, *et al.* MRI-targeted or standard biopsy for prostate-cancer diagnosis. *N Engl J Med* 2018;378:1767-77.
4. Gold SA, Hale GR, Bloom JB, Smith CP, Rayn KN, Valera V, *et al.* Follow-up of negative MRI-targeted prostate biopsies: When are we missing cancer? *World J Urol* 2019;37:235-41.
5. Marien A, Gill I, Ukimura O, Betrouni N, Villers A. Target ablation--image-guided therapy in prostate cancer. *Urol Oncol* 2014;32:912-23.