

Access this article online
Quick Response Code:

Website: www.ajts.org
DOI: 10.4103/ajts.AJTS_98_19

Passenger lymphocyte syndrome in a bidirectional ABO-mismatched renal transplant

P. A. Prethika, Shamee Shastry, Ganesh Mohan, Ravindra Attur Prabhu¹, Shankar Prasad Nagaraju¹, Dharshan Rangaswamy¹

Abstract:

Passenger lymphocyte syndrome (PLS), a subtype of graft-versus-host disease, is due to the production of antibodies by the donor "passenger" B lymphocytes against recipient's red cells. It is a rare disorder encountered mostly in ABO blood group-mismatched solid organ transplantation. The present case report illustrates the clinical presentation and the mode of management of PLS in a bidirectional ABO-incompatible renal transplantation. A 43-year-old male diagnosed with chronic kidney disease Stage 5-D (diabetic nephropathy) Type-2 hypertension with ischemic heart disease underwent ABO bidirectional-mismatched renal transplantation. The blood group of the patient was B Rh D positive and that of the donor (patient's wife) was A Rh D positive. In the pretransplantation phase, immunoglobulin G anti-A titer was 64 by column agglutination method, which was subsequently brought down to 4 by therapeutic plasma exchange and immunosuppression. Good graft function was established in the posttransplantation phase, but a significant drop in the hemoglobin (Hb) was noted. A fall in Hb, peripheral smear findings suggestive of hemolysis, and direct antiglobulin test positivity along with raised lactate dehydrogenase suggested the diagnosis of PLS; the patient was managed successfully for the same by transfusion of O blood group packed red blood cell transfusion and immunosuppression. PLS is a rare but important cause of immune-mediated hemolytic anemia in ABO-mismatched transplants.

Keywords:

ABO antibodies, B lymphocyte, direct Coombs test, hemolysis, passenger lymphocyte syndrome, renal transplantation

Introduction

The demand for organ transplantation is on rise, and with profound nature of transplant immunology, the prevalence of ABO-mismatched organ transplantation is now a routine medical practice.^[1] Passenger lymphocyte syndrome (PLS) is due to the production of antibodies by the viable donor B "passenger" lymphocytes that is transferred at the time of organ transplantation against the recipient's red blood cell antigens.^[2] In general, PLS is a

self-limiting condition; nevertheless, cases of multiorgan failure and death have been reported.^[3]

Case Report

Mr. X, a 43-year-old male who was a case of chronic kidney disease 5-D (with diabetic nephropathy) with ischemic heart disease underwent ABO bidirectional-mismatched renal transplantation at our center.

Blood group of the patient and donor was B Rh D positive and A Rh D positive, respectively (AutoVue Innova, Ortho Clinical Diagnostics, USA). On admission, the patient

This is an open access journal, and articles are distributed under the terms of the Creative Commons Attribution-NonCommercial-ShareAlike 4.0 License, which allows others to remix, tweak, and build upon the work non-commercially, as long as appropriate credit is given and the new creations are licensed under the identical terms.

For reprints contact: WKHLRPMedknow_reprints@wolterskluwer.com

How to cite this article: Prethika PA, Shastry S, Mohan G, Prabhu RA, Nagaraju SP, Rangaswamy D. Passenger lymphocyte syndrome in a bidirectional ABO-mismatched renal transplant. Asian J Transfus Sci 2020;14:63-6.

Departments of
Immunohematology and
Blood Transfusion and
¹Nephrology, Kasturba
Medical College, Manipal
Academy of Higher
Education, Manipal,
Karnataka, India

Address for correspondence:

Dr. Shamee Shastry,
Department of
Immunohematology
and Blood Transfusion,
Kasturba Medical College,
Manipal Academy of
Higher Education,
Manipal - 576 104,
Karnataka, India.
E-mail: shameeshastry@
gmail.com

Submitted: 18-09-2019
Accepted: 15-03-2020
Published: 24-07-2020

had oliguria, raised serum creatinine level (12.04 mg/dl) and serum urea levels (102 mg/dl). Pretransplant direct antiglobulin test (DAT) and antibody screening were found to be negative. Immunoglobulin G (IgG) anti-A titer in the recipient was 64 by column agglutination technology (CAT). The patient was on standard triple immunosuppression (tacrolimus + mycophenolate mofetil + steroid), and interleukin-2 induction by basiliximab as a prophylactic protocol to prevent graft rejection. Preoperatively, the patient underwent two procedures of therapeutic plasma exchange (TPE) with 5% albumin and crystalloids as replacement fluid processing 1.2 plasma volume per procedure. Four doses of intravenous immunoglobulin (IVIg) were administered prior to transplant to reduce the IgG anti-A titer levels from 64 to 4 by CAT [Figure 1]. Rituximab was started on preoperative day 7. His intraoperative period was uneventful. Postoperatively, one session of TPE was performed in view of raised IgG anti-A titer of 8; post procedure, the titer reduced to 4. Good graft function was established with creatinine level of 1.15 mg/dl and urine output.

On postoperative day 4, the patient was pale and tachycardic. A gradual fall in hemoglobin (Hb) from 7.5 g/dl on postoperative day 0 to 5.9 g/dl on postoperative day 4 was noticed [Figure 2]. To know the cause of drop in Hb; upper gastrointestinal endoscopy, stool for occult blood test, and ultrasonography abdomen were performed, which turned out to be negative. Peripheral smear showed normocytic normochromic cells with microcytes, anisocytosis, polychromasia, and spherocytes. Lactate dehydrogenase (LDH) level was also found to be elevated (271 IU/L). Hemolysis was suspected due to Hb drop, raised LDH, and peripheral smear findings. DAT (Bio-Rad, Switzerland) was positive (2+), suggesting an immune mechanism and probable PLS.

The diagnosis of PLS was supported by clinical and laboratory signs such as immunosuppression, Hb

drop, hemolytic picture in peripheral smear, elevated LDH, and DAT positivity. The patient received Coombs crossmatch-compatible fresh leukodepleted "O" blood group packed red blood cells (PRBCs) for anemia correction as it was a case of bidirectional ABO-mismatched transplantation (donor: A positive; recipient: B positive). Following blood transfusion, the patient's Hb improved, and he was discharged on the 8th postoperative day. On discharge, his renal function was normal, Hb was 7.7 g/dL, and anti-A titer was 4. On subsequent follow-up, the patient's Hb improved and maintained a good graft function.

Discussion

The age distribution at diagnosis of PLS ranged from 9 to 69 years.^[3] In ABO-mismatched solid organ transplantation, the appearance of antibodies against red blood cells is well described occurring in 17% of renal, 40% of liver, and 70% of heart-lung transplants.^[1] It is a subtype of graft versus host reaction.^[4] PLS is often seen in minor ABO-incompatible solid organ transplantation and rarely seen in bidirectional-mismatched transplantation. PLS is primarily due to the production of IgG antibodies (anti-A and anti-B) by donor B lymphocytes against recipient's red cell antigens. PLS can also be due to anti-D;^[2] isolated cases of anti-c, anti-e, anti-Kell, anti-Jk^a, or anti-Fy^a have been reported.^[5]

Donor-derived cells have been found in the recipients after transplantation of any solid organ. It is presumed that within minutes to hours, passenger lymphocytes migrate out of the graft, circulate in blood, and rapidly home to spleen, lymph nodes, thymus, and bone

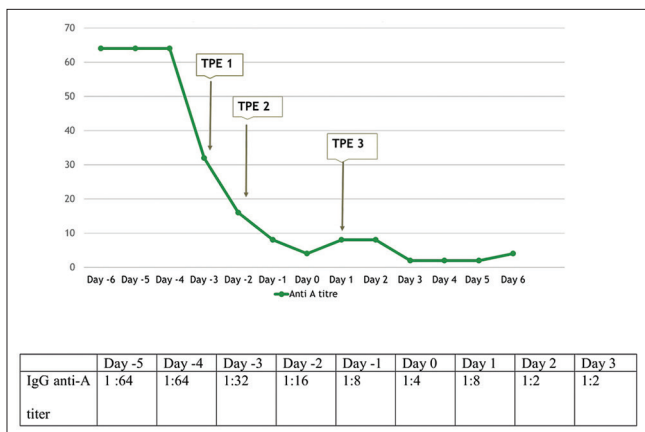


Figure 1: Trend in the anti-A titer in the patient. TPE – Therapeutic plasma exchange

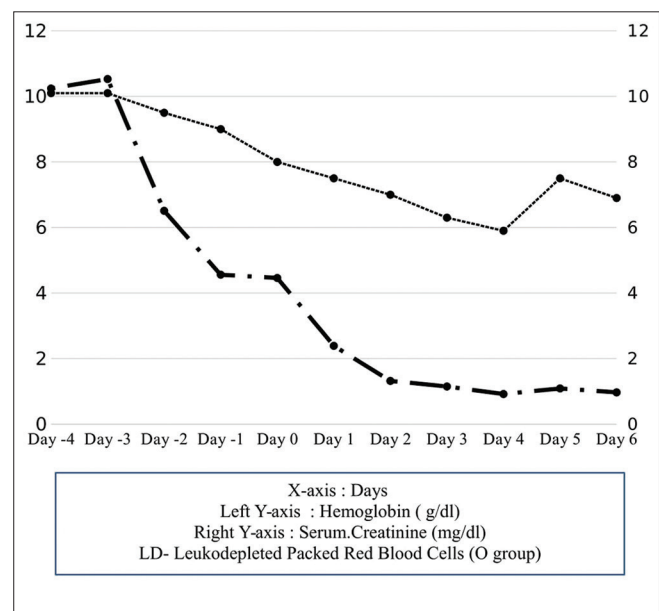


Figure 2: Trends in hemoglobin and serum creatinine

marrow. Under immunosuppressive therapy, donor bone marrow-derived cells rest in lymphoid organs for 2 weeks and then migrate. It has been suggested that donor B lymphocytes require stimulation after transfer either through infection^[6] or relative recipient T-lymphocyte inhibition such as anti-thymocyte globulin (ATG) so as to cause B-lymphocyte-induced antibody production.^[2] Antibodies derived from donor lymphocytes typically do not appear until 7–14 days postoperatively and survive for 14–21 days after a transplant. PLS must be suspected in patients with sudden anemia 1–3 weeks after an ABO-mismatched transplantation.^[1]

Risk factors for the development of PLS include prior donor sensitization by transfusion or pregnancy, passive administration of IVIG, ATG, infection immediately after transplantation, amount of lymphoid tissue transferred along with the transplanted organ, monoclonal antibodies such as basiliximab, and maintenance immunosuppressive agents that target cellular rejection such as cyclosporine and tacrolimus which spare humoral immunity relatively.^[3] The severity of hemolysis depends on the amount of transplanted lymphoid tissue, the level of red cell isoagglutinins in the donor before transplant, and the rapid rise of donor-derived antibodies titer in the recipient after transplant.^[2]

The diagnostic features that are suggestive of PLS in ABO-mismatched transplantations are (1) abrupt-onset hemolytic anemia,^[7] (2) positive direct antiglobulin test,^[4] (3) evidence of donor-derived ABO antibodies,^[7] and (4) donor lymphocyte microchimerism.^[2] Other tests such as elution studies can be done to identify donor-derived antibodies coating recipient red cells; flow cytometry or polymerase chain reaction method can be used to know about donor microchimerism. DAT may not be always positive in PLS as it has been suggested that the frequency of a positive DAT in patients after solid organ transplant varies from 17% to 70%.^[8]

Features suggestive of PLS in our case were Hb drop, hemolytic anemia picture in peripheral smear, DAT positivity, elevated LDH, and immunosuppression with tacrolimus and basiliximab.^[3] PLS is a unique immunological phenomenon, which is usually mild and self-limiting most of the time; nevertheless, substantial morbidities such as hypotension, acute renal failure, disseminated intravascular coagulation, and multiorgan failure may occur. There is no definitive treatment for PLS. It has been successfully treated with supportive care and blood transfusions. In a bidirectional mismatch, Group “O” PRBCs which are compatible with both recipient and donor are considered, whereas in case of

minor mismatch transplant, transfusing donor group specific rather than recipient’s group specific will be the ideal choice.

Corticosteroids can induce remission of antibody production, thus quelling the effect of the donor-derived cells until their natural life cycle ends.^[9] TPE^[1] to remove the passenger lymphocyte-derived antibodies from circulation maybe helpful in patients with severe hemolysis.^[6] Rituximab, a monoclonal antibody against the protein CD20 found on the surface of B cells, destroys the passenger cells and prevents further production of antibodies.^[5] Local irradiation maybe a prophylactic measure in reducing the incidence of passenger lymphocyte-derived antibodies.^[8]

As our patient was on rituximab, he underwent postoperative plasmapheresis in view of mildly raised anti-A IgG titer and received appropriate blood group PRBC transfusion; the prognosis of our patient turned out to be good.

Conclusion

A high index of clinical suspicion of PLS is essential in ABO-mismatched organ transplantation during the postoperative period when the patient presents with anemia. Recognizing PLS as a rare but potential cause for posttransplant anemia may allow for an early diagnosis and appropriate timely management.

Declaration of patient consent

The authors certify that they have obtained all appropriate patient consent forms. In the form the patient(s) has/have given his/her/their consent for his/her/their images and other clinical information to be reported in the journal. The patients understand that their names and initials will not be published and due efforts will be made to conceal their identity, but anonymity cannot be guaranteed.

Financial support and sponsorship

Nil.

Conflicts of interest

There are no conflicts of interest.

References

1. Triulzi DJ, Shirey RS, Ness PM, Klein AS. Immunohematologic complications of ABO-unmatched liver transplants. *Transfusion* 1992;32:829-33.
2. Brunetta DM, Albuquerque LM, Batista AH, Santos LH, Schreen D, Lima CA, et al. Passenger lymphocyte syndrome in liver transplantation. *Rev Bras Hematol Hemoter* 2017;39:364-7.
3. Nadarajah L, Ashman N, Thuraisingham R, Barber C, Allard S, Green L. Literature review of passenger lymphocyte syndrome

- following renal transplantation and two case reports. *Am J Transplant* 2013;13:1594-600.
4. ElAnsary M, Hanna MO, Saadi G, ElShazly M, Fadel FI, Ahmed HA, *et al.* Passenger lymphocyte syndrome in ABO and Rhesus D minor mismatched liver and kidney transplantation: A prospective analysis. *Hum Immunol* 2015;76:447-52.
 5. Seltsam A, Hell A, Heymann G, Salama A. Different organs from the same donor. *Transfusion* 2001;41:365-70.
 6. Peces R, Navascués RA, Laurés AS, Baltar J, García-Gala J, Sanzo C, *et al.* Alloimmune haemolytic anaemia resulting from anti-A and anti-B antibody induced by group O graft in renal transplant recipients. *Nephrol Dial Transplant* 1998;13:1866-9.
 7. Ainsworth CD, Crowther MA, Treleaven D, Evanovitch D, Webert KE, Blajchman MA. Severe hemolytic anemia post-renal transplantation produced by donor anti-D passenger lymphocytes: Case report and literature review. *Transfus Med Rev* 2009;23:155-9.
 8. Ramsey G. Red cell antibodies arising from solid organ transplants. *Transfusion* 1991;31:76-86.
 9. Chandra A, Gupta S, Sharma RK, Kaul A, Bhadauria D, Prasad N. Passenger lymphocyte syndrome exhibited in a renal transplant recipient: A case report. *Indian J Transplant* 2012;6:97-9.