



## NOTE

Pathology

# Multifocal suppurative granuloma caused by *Actinobacillus lignieresii* in the peritoneum of a beef steer

Kazufumi KASUYA<sup>1\*</sup>, Tilusha MANCHANAYAKE<sup>2,3</sup>, Kei UENOYAMA<sup>1</sup>,  
Sayaka KAWA<sup>1</sup>, Kou TAKAYAMA<sup>1</sup>, Naoto IMAI<sup>4</sup> and Tomoyuki SHIBAHARA<sup>3</sup>

<sup>1</sup>Moji Branch Shinmoji Detention Facility, Animal Quarantine Service, 3-1-2 Shinmojikita, Moji, Kitakyushu, Fukuoka 800-0113, Japan

<sup>2</sup>Division of Pathology, Veterinary Research Institute, Gannoruwa, Peradeniya, 20400, Sri Lanka

<sup>3</sup>Pathology and Pathophysiology Research Division, National Institute of Animal Health, 3-1-5 Kannondai, Tsukuba, Ibaraki 305-0856, Japan

<sup>4</sup>Fukushima Prefectural Kenchu Livestock Hygiene Service Centre, 2 Mansuida, Tomitamachi, Koriyama, Fukushima 963-8041, Japan

*J. Vet. Med. Sci.*

79(1): 65–67, 2017

doi: 10.1292/jvms.16-0402

Received: 1 August 2016

Accepted: 5 October 2016

Published online in J-STAGE:

21 October 2016

**ABSTRACT.** An imported crossbred Angus beef steer aged eight to twelve months died suddenly on the eighth day of a quarantine period in Japan. Gross examination showed the peritoneum and mesentery consisted of numerous nodules of various sizes. Histological examination revealed chronic suppurative granulomatous peritonitis with eosinophilic rosettes surrounding colonies of Gram-negative bacilli. The bacteria isolated from the nodules were confirmed to be *Actinobacillus lignieresii* based on the results of 16S rRNA gene sequencing and immunohistochemistry. Antibiotic sensitivity testing showed that the isolate was resistant to penicillin. Thus, a diagnosis of atypical actinobacillosis caused by *A. lignieresii* was made.

**KEY WORDS:** *Actinobacillus lignieresii*, cattle, peritoneal granuloma

Actinobacillosis is a globally prevalent infectious animal disease caused by Gram-negative bacilli of the genus *Actinobacillus*. *Actinobacillus lignieresii* is a common commensal inhabitant of the ruminant oral cavity. The bacteria can cause infection by invading adjacent soft tissues after the development of a penetrating wound. This type of *A. lignieresii* infection is characterized by pyogranulomas containing sulfur granules. In cattle, the typical inflammatory lesions occurring in the oral cavity and the tongue are commonly referred to as “wooden tongue”. However, the infection may not be limited to the oral cavity and tongue, and can spread to the adjacent soft tissues of the mouth and regional lymph nodes [8]. Granulomatous lesions in the skin (cutaneous form), lymph nodes [5], head, flank, wall of the stomach and limbs [2] have been reported in cases of *A. lignieresii* infection. Atypical *Actinobacillus* granulomas have been identified in the nasal cavity, cervical area and the lungs in cattle [7]. These lesions had been confused with neoplasms, nasal polyps or exuberant granulation tissue [7]. Furthermore, multiple granulomas have been detected in the abdomen of cows after Cesarean sections [3]. The purpose of this case study is to describe atypical *A. lignieresii* infection characterized by multifocal suppurative granulomatous peritonitis in a beef steer.

Nine hundred sixty crossbred Angus cattle (8 to 12 months of age) were imported from Australia to Japan. Upon delivery to Japan, none of the cattle showed abnormal clinical signs or evidence of disease. ELISA test for brucellosis and Johne’s disease; a delayed type hypersensitivity test using Johnin; and microscopic examinations of blood smear samples for piroplasmiasis, anaplasmosis and trypanosomiasis were conducted as routine examinations for imported feeder cattle, and all the results were negative. Two animals died during the 15-day quarantine period: one animal died suddenly on the eighth day (animal 1), and the second animal (animal 2) developed respiratory signs and died on the twelfth day. Necropsy was performed on both animals. No clinical abnormalities were observed in remaining 958 cattle.

During the departure quarantine period in Australia, all cattle were vaccinated against *Mannheimia haemolytica*, bovine herpesvirus (Bovilis MH+IBR; Coopers Animal Health, Macquarie Park, NSW, Australia) and bovine pestivirus (Pestigard; Zoetis, Parsippany, NJ, U.S.A.). In addition, to comply with animal health requirements for importing cattle to Japan from Australia, animals were treated with long-acting oxytetracycline for leptospirosis.

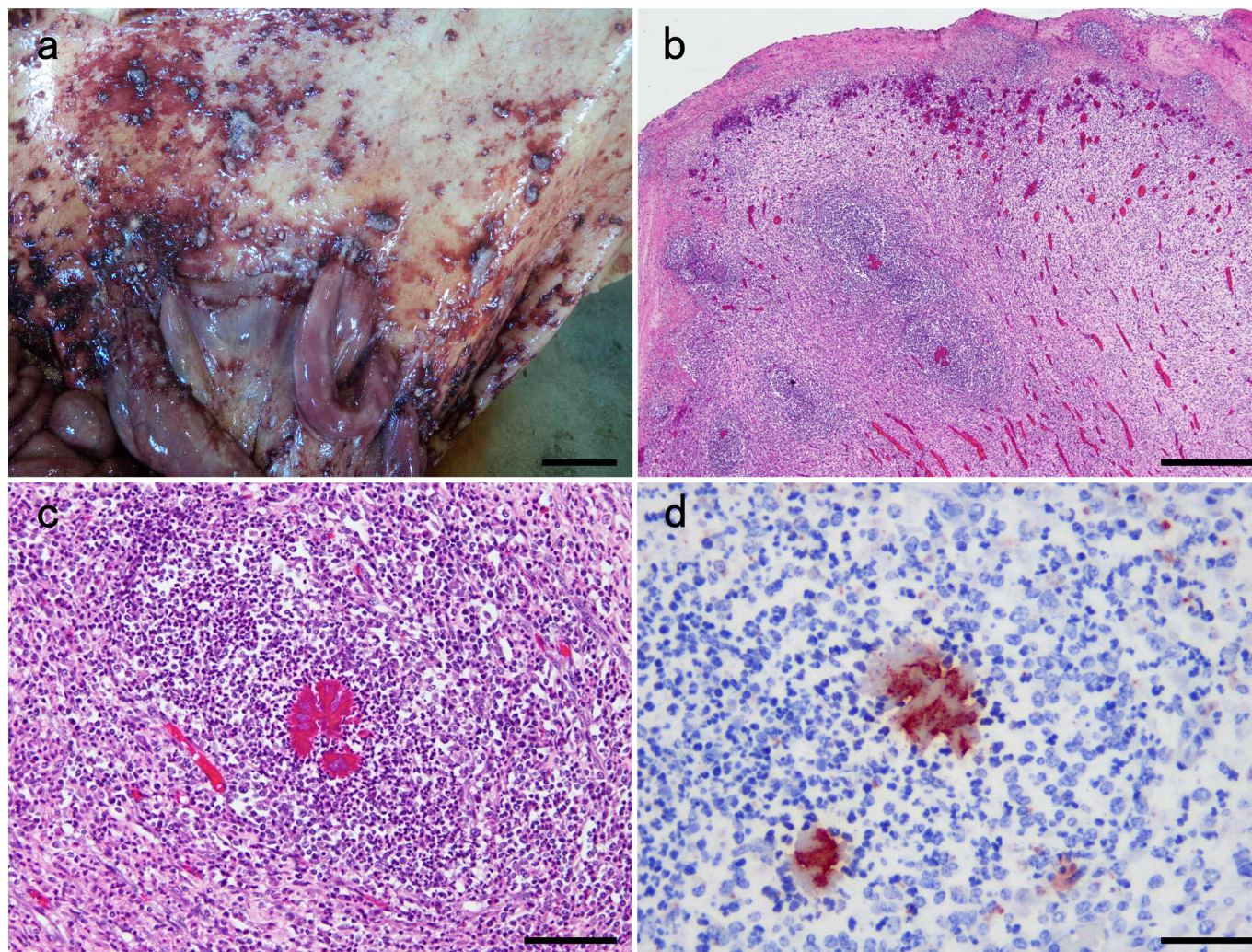
Gross necropsy examination of animal 1 revealed extensive adhesions between the peritoneum and the intestines. Both the peritoneum and mesentery had numerous firm nodules of varying sizes (Fig. 1a). The jejunal mucosa was extensively congested

\*Correspondence to: Kasuya, K., Moji Branch Shinmoji Detention Facility, Animal Quarantine Service, 3-1-2 Shinmojikita, Moji, Kitakyushu, Fukuoka 800-0113, Japan. e-mail: kazufumi\_kasuya160@maff.go.jp

©2017 The Japanese Society of Veterinary Science



This is an open-access article distributed under the terms of the Creative Commons Attribution Non-Commercial No Derivatives (by-nc-nd) License <<http://creativecommons.org/licenses/by-nc-nd/4.0/>>.



**Fig. 1.** a. Gross finding of the peritoneum showing extensive adhesion to the intestine. Numerous firm foci were disseminated throughout the peritoneum and the mesentery. Bar=5 cm. b. Low magnification of the abdominal mass demonstrating granuloma surrounded by extensive fibrous tissue. HE stain. Bar=500  $\mu$ m. c. Eosinophilic club-like spicules (asteroid bodies) contain bacterial colonies. A lot of neutrophils and macrophages infiltrate around the granule. HE stain. Bar=20  $\mu$ m. d. Immunohistochemistry showing that bacilli in the asteroid bodies react with an antibody against *A. lignieresii* serotypes 1 to 6 mix. Bar=10  $\mu$ m.

and focally thickened. The mesenteric lymph nodes were moderately swollen. Foamy fluid was identified in the trachea, and blood clots were found at the tracheal bifurcation. Petechial to ecchymotic hemorrhages were observed throughout the lungs. No gross lesions were found in other organs, including the brain and spinal cord.

Gross necropsy of animal 2 showed only severe fibrinous pneumonia.

At necropsy, tissue samples of the liver, spleen, kidney, heart, lung and intestines, and of any noted gross abnormalities (nodules of the peritoneum and mesentery) were fixed in 10% neutral-buffered formalin. Fixed tissues were embedded in paraffin wax, sectioned (approximately 3- $\mu$ m thick) and stained for histological examination with hematoxylin and eosin (HE) and Gram stain.

Histological examination revealed that the affected peritoneum of animal 1 was composed of multiple suppurative granulomas (Fig. 1b), which were characterized by asteroid bodies with bacterial colonies. The colonies were Gram-negative bacilli on Gram stain, and those were surrounded by neutrophils, macrophages and fibroblasts and showed evidence of neovascularization (Fig. 1c). Some coccidial schizonts were observed at the mucosa of the jejunum. Lymphangiectasia and slight to moderate inflammatory cell infiltration to the jejunal lamina propria were noted surrounding the protozoan lesions. The bronchiolar lumen contained a small amount of red blood cells, necrotic cells, bacterial colonies and food debris, and moderate diffuse congestion was observed in the lung.

Immunohistochemistry was performed to detect the *A. lignieresii* antigen. All formalin-fixed tissues were cut in 3- $\mu$ m-thick sections, treated with 3% hydrogen peroxide in methanol (to suppress endogenous peroxidase activity), then treated with 0.1% actinase E solution and incubated at 37°C for 20 min for antigen retrieval. The tissues were then incubated with rabbit anti-*A. lignieresii* serotypes 1 to 6 mix primary antibody (National Institute of Animal Health, Tsukuba, Japan) for 30 min at room temperature and then reacted with a secondary antibody (Histofine Simple Stain MAX-PO (R), Nichirei Bioscience Inc., Tokyo,

Japan). After rinsing with phosphate buffered saline, the specimens were incubated with aminoethyl carbazole (AEC) substrate solution (Histofine Simple Stain AEC solution, Nichirei Bioscience Inc.) at room temperature for 5 min and then counterstained with hematoxylin. Immunohistochemistry analysis demonstrated that the Gram-negative bacilli identified in the asteroid bodies of the suppurative granulomas reacted with the antibody against *A. lignieresii* serotypes 1 to 6 mix (Fig. 1d).

For bacterial culture, tissue samples of the liver, spleen, kidney, heart, lungs and peritoneal nodules were inoculated into normal blood agar, deoxycholate-hydrogen sulfide-lactose (DHL) agar and Gifu anaerobic medium (GAM) blood agar and then incubated at 37°C under 5% CO<sub>2</sub>, aerobic or anaerobic condition. In addition, the nodules were inoculated into heart infusion agar, Columbia colistin and nalidixic acid (CNA) agar, and trypticase soy broth (TSB) and incubated at 37°C under 5% CO<sub>2</sub>. A Gram-negative bacillus was isolated from the nodules of the peritoneum, and the isolate was catalase and oxidase positive. No bacteria were isolated from any of the other tissue samples.

The isolate was assayed for susceptibility to 7 antibiotics: penicillin, imipenem, ofloxacin, norfloxacin, kanamycin, sulfamethoxazole-trimethoprim and chloramphenicol (Sensi disk; Becton, Dickinson and Co., Franklin Lakes, NJ, U.S.A.) and showed resistance to penicillin.

In order to identify the bacteria, genomic DNA was extracted from bacterial colonies by using a DNA extraction kit (InstaGene Matrix; Bio-Rad Laboratories, Hercules, CA, U.S.A.) according to the manufacturer's instruction. Phylogenetic analysis based on 16S ribosomal RNA gene (16S rDNA) was used to identify the bacteria [11]. A ~500 bp region of the 16S rDNA gene was amplified and sequenced using a MicroSeq 500 16S rDNA PCR/Sequencing Kit (Applied Biosystems Life Technologies, Carlsbad, CA, U.S.A.). The isolate was identified as *A. lignieresii* (ATCC 3369, 100% identity) by sequencing the amplified 16S rRNA region.

The typical clinical manifestation of *A. lignieresii* infection involves the tongue and soft tissues around head [8], and subclinical infection is often identified at slaughter [10]. However, atypical actinobacillosis is also common. Atypical distribution of granulomatous lesions with *A. lignieresii* has been reported in cutaneous tissues [2, 5, 6], rhinopharynx [1] and omentum [9] of cattle. In the case reported here, tuberculosis, nocardiosis and actinomycosis were also suspected for a differential diagnosis, however, immunohistochemical analysis and isolation, identification and genetic sequencing of isolate denied these diseases and confirmed the diagnosis of *A. lignieresii* infection.

*A. lignieresii* infection in soft tissues occurs following mucosal abrasion or penetrating wounds of the mouth or skin, respectively [8]. The presence of granulomas on the peritoneum suggests the organism was disseminated either via blood or via lymphatic vessels. Young cattle are at a risk for infection and may develop the characteristic lesions in a few days [8]. In our case, the stress of transportation is a likely predisposing factor for the infection.

Animal 2 died of severe fibrinous pneumonia. *A. lignieresii* was not isolated from any of the tissue samples. The cause of death in this animal was bovine respiratory disease complex unrelated to the actinobacillosis identified in animal 1.

The *A. lignieresii* identified in our study was resistant to penicillin, a finding that has been previously reported [5]. However, the isolate was susceptible to sulfamethoxazole-trimethoprim. The susceptibility of this bacterium to sulfamethoxazole-trimethoprim is important, because of the rare zoonotic potential of *A. lignieresii*; human infection with *A. lignieresii* has been reported after a horse bite [4].

The occurrence of *A. lignieresii* granulomas in the peritoneum of cattle is rare and has not been previously reported in Japan. Therefore, additional investigations will be necessary to confirm the difference of pathogenicity among the conventional strains of *A. lignieresii* and the isolate in this study.

ACKNOWLEDGMENTS. The authors thank Mr. M. Kobayashi and Ms. M. Shimada for histopathological assistance.

## REFERENCES

1. Angelo, P., Alessandro, S., Noemi, R., Giuliano, B., Filippo, S. and Marco, P. 2009. An atypical case of respiratory actinobacillosis in a cow. *J. Vet. Sci.* **10**: 265–267. [Medline] [CrossRef]
2. Cahalan, S. D., Sheridan, L., Akers, C. R., Lorenz, I. and Cassidy, J. 2012. Atypical cutaneous actinobacillosis in young beef cattle. *Vet. Rec.* **171**: 375. [Medline] [CrossRef]
3. de Kruif, A., Mijten, P., Haesebrouck, F., Hoorens, J. and Devriese, L. 1992. Actinobacillosis in bovine caesarean sections. *Vet. Rec.* **131**: 414–415. [Medline] [CrossRef]
4. Dibb, W. L., Digranes, A. and Tønjum, S. 1981. *Actinobacillus lignieresii* infection after a horse bite. *Br. Med. J. (Clin. Res. Ed.)* **283**: 583–584. [Medline] [CrossRef]
5. Margineda, C. A., Odriozola, E., Moreira, A. R., Canton, G., Micheloud, J. F., Gardey, P., Spetter, M. and Campero, C. M. 2013. Atypical actinobacillosis in bulls in Argentina: granulomatous dermatitis and lymphadenitis. *Pesqui. Vet. Bras.* **33**: 1–4. [CrossRef]
6. Milne, M. H., Barrett, D. C., Mellor, D. J., O'Neill, R. and Fitzpatrick, J. L. 2001. Clinical recognition and treatment of bovine cutaneous actinobacillosis. *Vet. Rec.* **148**: 273–274. [Medline] [CrossRef]
7. Rebhun, W. C., King, J. M. and Hillman, R. B. 1988. Atypical actinobacillosis granulomas in cattle. *Cornell Vet.* **78**: 125–130. [Medline]
8. Rycroft, A. N. and Garside, L. H. 2000. *Actinobacillus* species and their role in animal disease. *Vet. J.* **159**: 18–36. [Medline] [CrossRef]
9. Sheikh-Omar, A. K. 1980. Actinobacillosis of the omentum in a cow. *Pertanika* **3**: 64–65.
10. Tageldin, M. H., el Sanousi, S. M., Suliman, T. A. and Fawi, M. T. 1988. Concurrent infection with *Mycobacterium farcinogenes* and *Actinobacillus lignieresii* in slaughtered cattle. *J. Comp. Pathol.* **99**: 431–437. [Medline] [CrossRef]
11. Therese, K. L., Bartell, J., Deepa, P., Mangaiyarkarasi, S., Ward, D., Dajcs, J., Madhavan, H. N. and Stroman, D. 2009. DNA sequencing by Microseq kit targeting 16S rRNA gene for species level identification of mycobacteria. *Indian J. Med. Res.* **129**: 176–181. [Medline]