

Minimally Invasive Modified Lemaire Tenodesis

Bart Muller, M.D., Ph.D., Gijs J. A. Willinge, B.Sc., and Jacco A. C. Zijl, M.D.



Abstract: Increasing emphasis in the literature is recently being put on controlling rotational stability in patients with an anterior cruciate ligament rupture by addressing the anterolateral complex during anterior cruciate ligament reconstruction. Many different techniques for lateral extra-articular tenodesis have been described, with the (modified) Lemaire technique being widely favored. Recent literature does report that lateral extra-articular tenodesis leads to a reduction in persistent rotatory laxity and graft rupture rate, but also may be associated with increased pain, reduced quadriceps strength, reduced subjective functional recovery, and cosmetic complaints. Thus this article aims to describe our minimally invasive technique for a modified Lemaire tenodesis.

In 1879, Segond¹ was the first to describe an avulsion fracture on the anterolateral side of the tibial plateau that was later understood to be pathognomonic for tears of the anterior cruciate ligament (ACL).^{2,3} More than 100 years later, in 2013, Claes et al.⁴ described the ligament primarily responsible for the avulsion and named it the “anterolateral ligament” (ALL). Subsequently, many studies emerged that attributed function to the ALL as part of the anterolateral complex (ALC) being an important secondary rotational knee stabilizer,^{5,6} especially in cases with concomitant ACL injuries.

The ALC is responsible for controlling internal rotation and includes the following structures: the ALL, the iliotibial band (ITB), distal and proximal Kaplan’s fibers, and the capsular attachment of the lateral meniscus.⁵ In several cadaveric experiments, the ALC was demonstrated to not only serve as a secondary restraint to internal rotation, but at high flexion angles, to even serve as the primary restraint.^{7,8}

The incidence of ACL reconstructive surgery is ever increasing, with a population that is increasingly active, and for longer. The results of ACL reconstruction appear somewhat disappointing, however. Persisting rotatory instability after primary ACL reconstruction is reported in $\leq 25\%$ of cases, which in turn has been shown to be a risk factor for recurrent injuries.^{9,10}

Renewed interest in the ALC and insights into its synergistic function to the ACL as a rotational knee stabilizer,¹¹ together with the relatively unsatisfactory outcomes of ACL reconstruction, have led to a growing clinical and scientific focus on lateral extra-articular tenodesis (LET) procedures as an augmentation to ACL reconstruction.¹² Many different techniques for LET have been described, with the (modified) Lemaire technique being widely favored.¹³⁻¹⁵ The recent literature does report that LET leads to a reduction in persistent rotatory laxity and ACL graft rupture rate,^{16,17} but also may be associated with increased pain, reduced quadriceps strength, reduced subjective functional recovery, and cosmetic complaints.¹⁸ Thus this article aims to describe our minimally invasive technique for a modified Lemaire tenodesis.

Surgical Technique: Minimally Invasive Modified Lemaire Tenodesis

The Video details the technique (Video 1). Pearls and pitfalls and advantages and disadvantages of the technique are described in Tables 1 and 2, respectively.

Indications

In our practice, all patients undergoing LET do so as augmentation to ACL reconstruction, either during ACL

From the St. Antonius Hospital, Department of Orthopaedic Surgery, Utrecht, the Netherlands

The authors report the following potential conflicts of interest or sources of funding: The Department of Orthopaedic Surgery, St. Antonius Hospital, Utrecht, the Netherlands, receives grants from Arthrex. Full ICMJE author disclosure forms are available for this article online, as [supplementary material](#).

Received June 10, 2020; accepted September 10, 2020.

Address correspondence to Bart Muller, MD, PhD, St. Antonius Hospital, Department of Orthopaedic Surgery, Postbox 2500, 3430 EM, Nieuwegein, the Netherlands. E-mail: b.muller@antoniuziekenhuis.nl

© 2020 by the Arthroscopy Association of North America. Published by Elsevier. This is an open access article under the CC BY-NC-ND license (<http://creativecommons.org/licenses/by-nc-nd/4.0/>).

2212-6287/201107

<https://doi.org/10.1016/j.eats.2020.09.006>

Table 1. Pearls and Pitfalls

Pearls	Pitfalls
Mark specific landmarks on the skin to adequately plan the incision and navigate perioperatively	With the risk of overconstraint, perform lateral extra-articular tenodesis only for pivoting instability or pivoting demand and without additional procedures on the lateral side of the knee (e.g. posterolateral corner reconstruction)
Specific tests (during examination under anesthesia) to evaluate damage to the anterolateral complex are the pivot shift test, the tibial internal rotation test, and the anterolateral drawer test	Blindly distally advancing the Smillie knife comes with the risk of cutting the graft distally; therefore, advance the knife with care, anteriorly and posteriorly of Gerdy's tubercle
Incise skin and iliotibial band simultaneously (with a stab incision scalpel)	
Use of a Smillie knife facilitates working through a short incision	
Slight varus stress may help with identifying the fibular collateral ligament	
Use the looped passing wire as a Gigli saw to widen the tunnel	
Dissecting the soft tissues and stimulating the cortex with a debridement rasp facilitates graft ingrowth onto the lateral femur	
The tip of the FASTak anchor (Arthrex) can be gently tapped with a hammer and screwed into the cortex; it does not need predrilling	
Neutral rotation when fixating the graft helps avoid overconstraint of the lateral compartment	

reconstruction or secondary to ACL reconstruction with complaints of persistent rotatory instability. Generally, for the indication of a LET procedure, we follow the decision tree published in the consensus paper by the Anterolateral Ligament Expert Group¹⁷ with both decisive and secondary criteria. Decisive criteria (meeting 1 criterion advocates LET) are ACL revision, pivot shift grade 2 or 3, Segond fracture, pivoting sports (high-level athletes and competition), or general hyperlaxity. Secondary criteria (meeting at least 2 criteria advocates LET) are contralateral ACL rupture, 7-mm Δ on Lachman test, deep lateral femoral notch sign (as seen on a lateral radiograph), and <25 years old.¹⁷

Patient Positioning and Examination Under Anesthesia

The patient is positioned supine on the operating table and brought under either spinal or general

Table 2. Advantages and Disadvantages

Advantages	Disadvantages
Better aesthetics	Risk of iatrogenic damage to the iliotibial band graft
Less tissue damage	Difficulty identifying fibular collateral ligament
No converging tunnels	
No prominent hardware (e.g. staple)	
No vastus lateralis retraction	
Less pain	
Relatively quick procedure	

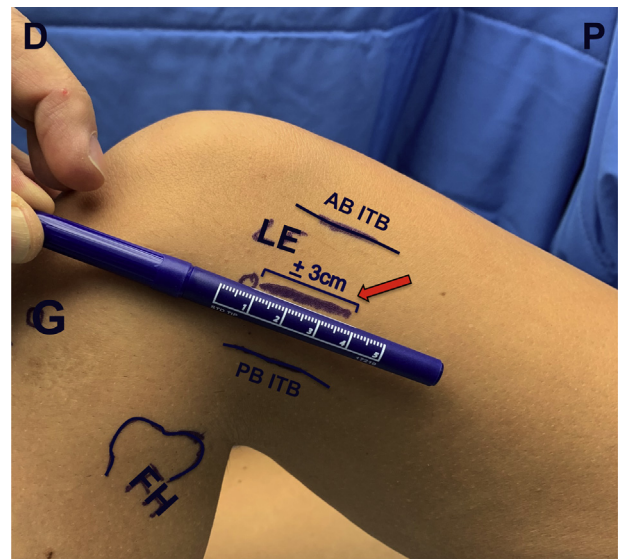


Fig 1. The patient is in supine position with the left knee in $>90^\circ$ flexion and neutral rotation. Before primary anterior cruciate ligament repair, important landmarks and the intended skin incision for the minimally invasive modified Lemaire tenodesis are marked. The arrow marks the intended incision site, measuring ~ 3 cm in length. The incision will be made with a stab incision scalpel, starting from the lateral epicondyle and extended proximally along the intended incision marking. The skin and iliotibial band are incised simultaneously, aiming centrally in the iliotibial band. Abbreviations: AB ITB, anterior border iliotibial band; D, distal side; FH, fibular head; G, Gerdy's tubercle; LE, lateral epicondyle (femur); P, proximal side; PB ITB, posterior border iliotibial band.

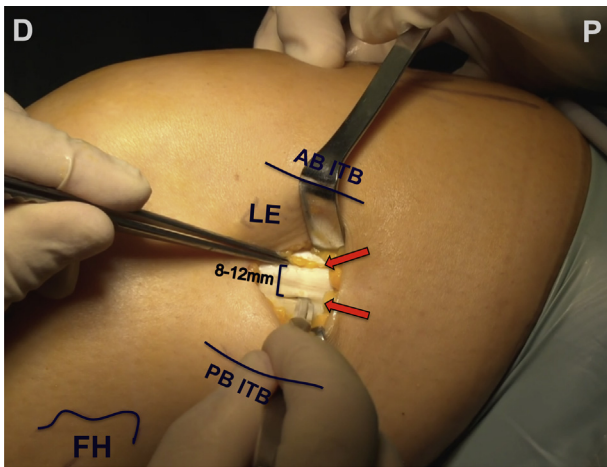


Fig 2. The patient is in supine position with the left knee in $>90^\circ$ flexion and neutral rotation. Depending on placement of the initial stab incision, the second iliotibial band (ITB) incision is placed either anteriorly or posteriorly (posteriorly in this figure), so that an 8- to 12-mm-wide strip can be harvested from the central one third of the ITB. The arrows mark the anterior and posterior incision in the ITB, with the intended harvested ITB strip measuring 8 to 12 mm. Abbreviations: AB ITB, anterior border iliotibial band; D, distal side; FH, fibular head; LE, lateral epicondyle (femur); P, proximal side; PB ITB, posterior border iliotibial band.

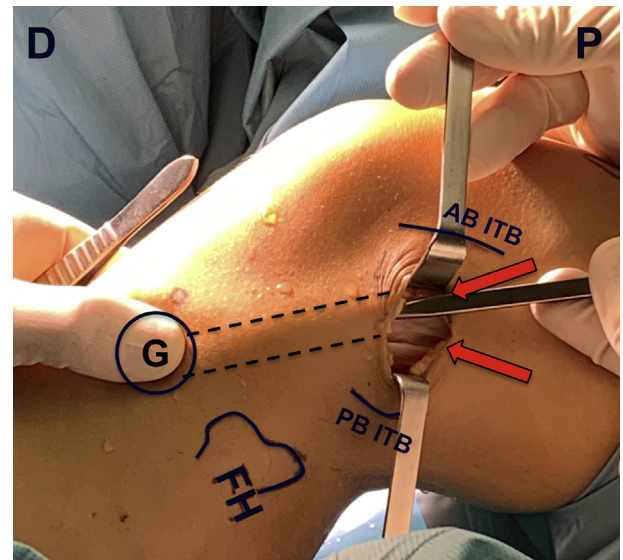


Fig 4. The patient is in supine position with the left knee in $>90^\circ$ flexion and neutral rotation. With the Smillie knife in the right hand, the iliotibial band (ITB) incisions are extended distally, aiming posteriorly and toward the thumb of the left hand, which is placed directly on Gerdy's tubercle. The intended trajectories of both the extended ITB incisions are marked by the dotted line. Abbreviations: D, distal side; FAB ITB, anterior border iliotibial band; H, fibular head; G, Gerdy's tubercle; P, proximal side; PB ITB, posterior border iliotibial band.

anesthesia. First, an extensive bilateral knee examination under anesthesia is performed to assess the extent of the injury. Specific tests we use to evaluate damage to the ALC are the pivot shift test, the tibial

internal rotation test, and the anterolateral drawer test.

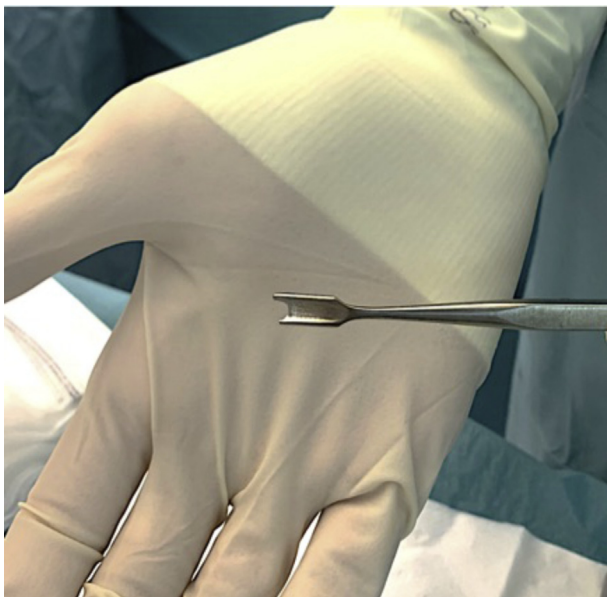


Fig 3. Smillie knife. The minimally invasive modified Lemaire tenodesis allows only a short skin incision of maximum 4 cm. By using a Smillie knife, the iliotibial band incision can be extended down to Gerdy's tubercle without further incising the skin.

After examination under anesthesia, the injured leg is placed in a high-placed thigh tourniquet and an electric knee support unit (Maquet, Rastatt, Germany), which allows the surgeon to control intraoperative knee motion using a foot switch. With it, the knee is placed in 90° flexion, and important landmarks and the intended skin incision are marked (Fig 1).

Surgical Approach

If LET is carried out during the same procedure as ACL reconstruction, the ACL reconstruction should be carried out first, since the ACL (graft) is a primary knee stabilizer. During diagnostic knee arthroscopy, concomitant intra-articular injuries are assessed and addressed. Meniscal injuries are treated by means of repair whenever possible. Our preferred technique for ACL reconstruction is the all-inside technique with hamstring graft (Arthrex, Naples, FL). When preparing the femoral tunnel, we make the incision for LET to prevent excess fluid extravasation locally and to see the flipping of the femoral suspensory button underneath the ITB when passing the ACL graft. A short lateral incision is made with a stab incision scalpel, starting from the lateral epicondyle and extending 3 to

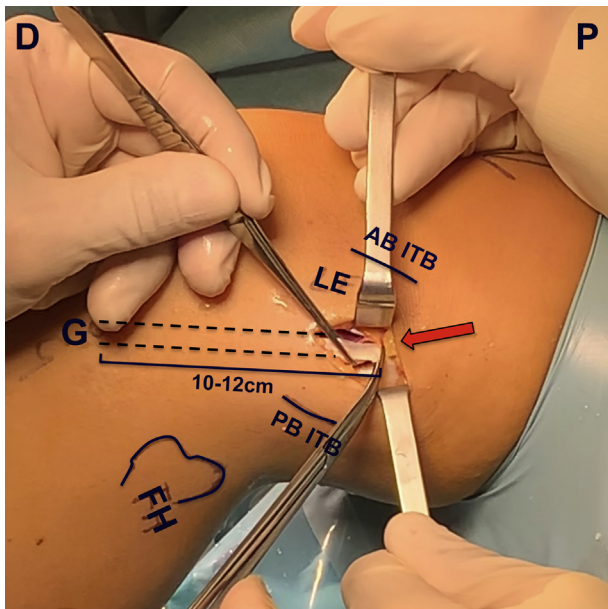


Fig 5. The patient is in supine position with the left knee in $>90^\circ$ flexion and neutral rotation. With both the posterior and anterior iliotibial band incisions distally extended to Gerdy's tubercle, the proximal end of the graft is detached using Metzenbaum scissors (arrow). The distal attachment is left intact. Using this technique, an iliotibial band graft with a total length of 10 to 12 cm and width of 8 to 12 mm is harvested. Abbreviations: AB ITB, anterior border iliotibial band; D, distal side; FH, fibular head; G, Gerdy's tubercle; LE, lateral epicondyle (femur); P, proximal side; PB ITB, posterior border iliotibial band.

4 cm proximally. With a single smooth move, the skin and ITB are incised simultaneously aimed centrally in the ITB.

When ACL reconstruction is completed, the knee is brought to 90° flexion, and the surgeon sits down at the lateral side of the knee. The ITB is further exposed by blunt dissection with gauze.

Tenodesis

Depending on placement of the initial 3- to 4-cm stab incision, a second incision in the ITB is made either anteriorly or posteriorly, so that an 8- to 12-mm-wide strip can be harvested from the central one third of the ITB (Fig 2). Because a minimally invasive procedure allows for only a short skin incision, we make use of a Smillie knife (Fig 3) to extend both ITB incisions down to Gerdy's tubercle. With the thumb of 1 hand placed on Gerdy's tubercle, the Smillie knife in the other hand is directed distally, aiming anteriorly and posteriorly of the placed thumb (Fig 4).

A graft with a total length of 10 to 12 cm is harvested from the ITB, leaving the distal attachment intact and proximally detaching it with a pair of

Metzenbaum scissors (Fig 5). Then the proximal end can be grasped and manipulated with an Allis tissue forceps while dissecting away the distal soft tissues and fat.

With the graft held by an assistant toward the distal corner of the skin incision, the femoral attachment of the fibular collateral ligament (FCL) is identified. Slight varus stress may help with identifying the FCL. With Metzenbaum scissors, a soft tissue tunnel is created medially from the FCL, and a curved-tip forceps is placed from anterior to posterior through this tunnel (Fig 6). A looped wire is pulled through the tunnel, and with the loop in 1 hand anteriorly and the ends of the wire in the other hand posteriorly, the tunnel is widened by gently moving the wire like a Gigli saw proximally and distally (Fig 7). With a sufficiently wide tunnel, the wire loop is put around the proximal end of the ITB graft and pulled through (Fig 8).

The femoral fixation of the LET should be just anteriorly to the insertion of the distal Kaplan's

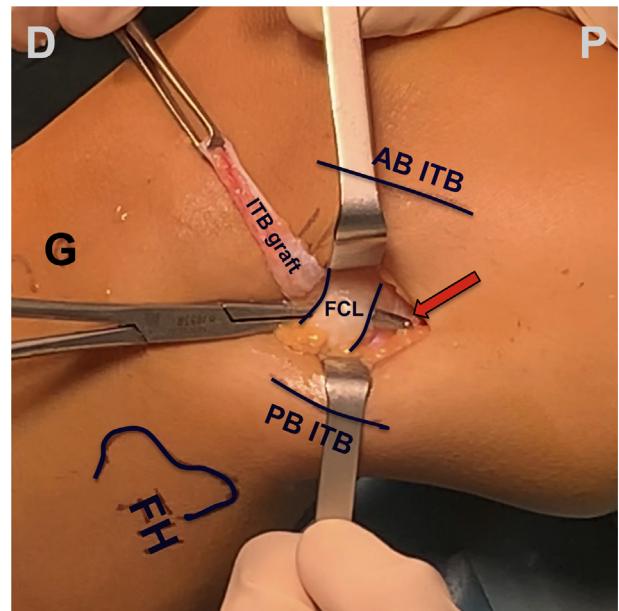


Fig 6. The patient is in supine position with the left knee in $>90^\circ$ flexion and neutral rotation. Using an Allis tissue forceps, the proximal end of the graft is grasped and manipulated. Soft tissues and fat are dissected away from the graft. While an assistant holds the iliotibial band (ITB) graft toward the distal corner of the skin incision, the femoral attachment of the fibular collateral ligament (FCL) is identified. A soft tissue tunnel is then created medially from the FCL using Metzenbaum scissors. A curved-tip forceps is placed from anterior to posterior through this tunnel. The arrow marks the tip of the curved-tip forceps. Abbreviations: AB ITB, anterior border iliotibial band; D, distal side; FH, fibular head; G, Gerdy's tubercle; P, proximal side; PB ITB, posterior border iliotibial band.

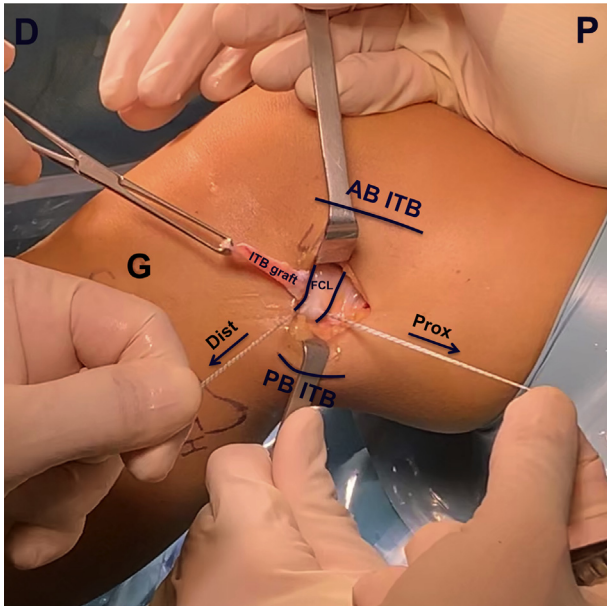


Fig 7. The patient is in supine position with the left knee in $>90^\circ$ flexion and neutral rotation. A looped wire is placed in the tip of the curved-tip forceps and pulled through the tunnel. By gently moving the looped wire proximally with the right hand and distally with the left hand (directions marked by arrows), the tunnel is widened. Abbreviations: AB ITB, anterior border iliotibial band; D, distal side; Dist, directed distally; FCL, fibular collateral ligament; G, Gerdy's tubercle; ITB graft, iliotibial graft; P, proximal side; PB ITB, posterior border iliotibial band; Prox, directed proximally.

fibers and proximal to the femoral suspensory button of the ACL graft. Here, the soft tissues are dissected away, the bony surface is stimulated with a debridement rasp, and a 2.8-mm titanium suture anchor (FASTak; Arthrex) is placed (Fig 9). One wire coming from the suture anchor is used to whipstitch the ITB graft (Fig 10) and, with the knee brought to 30° flexion and in neutral rotation, the other wire coming from the suture anchor is used to hoist the graft toward the femur (Fig 11). With sufficient tension on the graft, the wires are tied together. The knee should have full range of motion, and the LET should tension with internal rotation. The ITB donor defect is then closed using a barbed suture (Stratafix; Johnson & Johnson, New Brunswick, NJ) (Fig 12), after which the skin is closed (Fig 13).

Postoperative Rehabilitation

Postoperatively we always make anteroposterior and lateral knee radiographs to confirm correct positioning of hardware (Fig 14).

Our postoperative protocol after LET is similar to our protocol after ACL reconstruction, since the 2 procedures are usually performed simultaneously. If the

LET is an augmentation to ACL reconstruction performed earlier, a customized rehabilitation program is made.

Generally, after combined ACL reconstruction and LET, during the first 4 weeks postoperatively, weightbearing is limited (to 50%) with crutches, and focus is on regaining full extension and reducing swelling. When walking without a limp is possible, crutches are weaned, and gradual strengthening exercises are initiated. Between 4 and 6 months postoperatively, physical therapy progresses to straight-line running; between 6 and 9 months, sport-specific exercises may start. Unrestricted return to sports is generally not allowed before 9 months postoperatively. Progression to each new phase of the rehabilitation protocol depends on physical diagnostic exams, with Biodex measurements (Shirley, NY) that are performed at 3, 6, and 9 months to assess patient progress and adequately address weakness or balance deficiency.

Discussion

This Technical Note describes our minimally invasive modified Lemaire tenodesis. In our

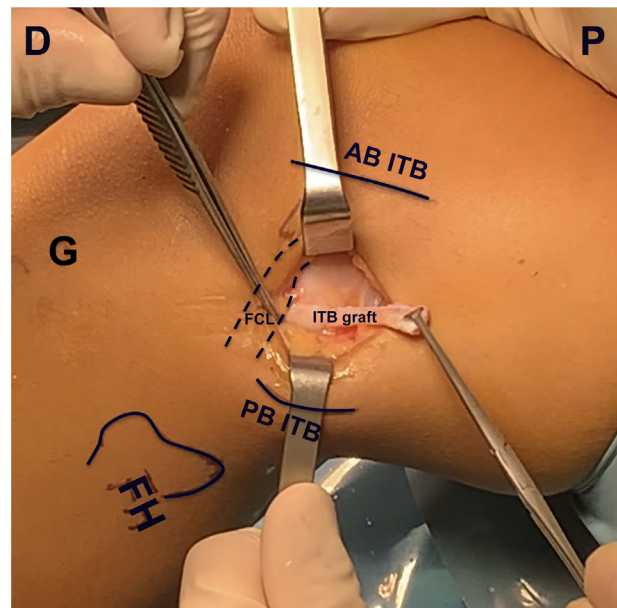


Fig 8. The patient is in supine position with the left knee in $>90^\circ$ flexion and neutral rotation. After the tunnel is sufficiently widened, the looped wire is placed around the iliotibial band (ITB) graft and pulled through the tunnel medially from the fibular collateral ligament (FCL). The dotted line marks the trajectory of the FCL, crossing over the ITB graft after the graft is pulled through the tunnel. Abbreviations: AB ITB, anterior border iliotibial band; D, distal side; FH, fibular head; G, Gerdy's tubercle; P, proximal side; PB ITB, posterior border iliotibial band.

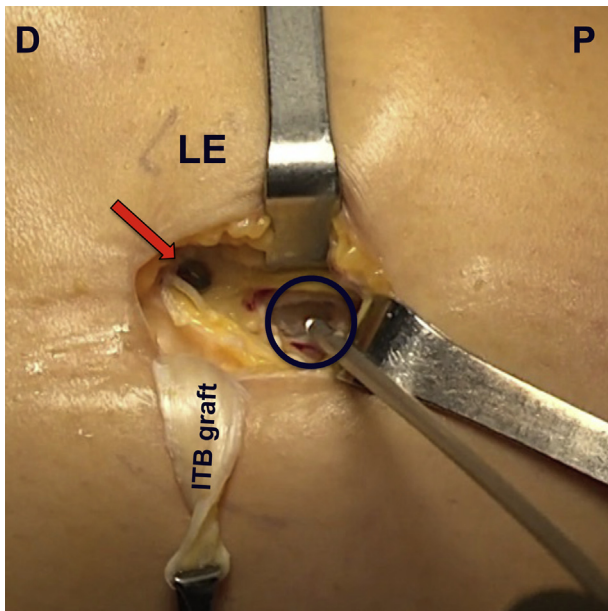


Fig 9. The patient is in supine position with the left knee in $>90^\circ$ flexion and neutral rotation. The femoral fixation site of the lateral extra-articular tenodesis (circle) should be just anterior to the insertion of the distal Kaplan's fibers and proximal to the femoral suspensory button of the anterior cruciate ligament graft (arrow). The soft tissues at the femoral fixation site are dissected away, and the bony surface is stimulated with a debridement rasp. A 2.8-mm titanium suture anchor (FASTak; Arthrex) is placed. Abbreviations: D, distal side; ITB, iliotibial; LE, lateral epicondyle (femur); P, proximal side.

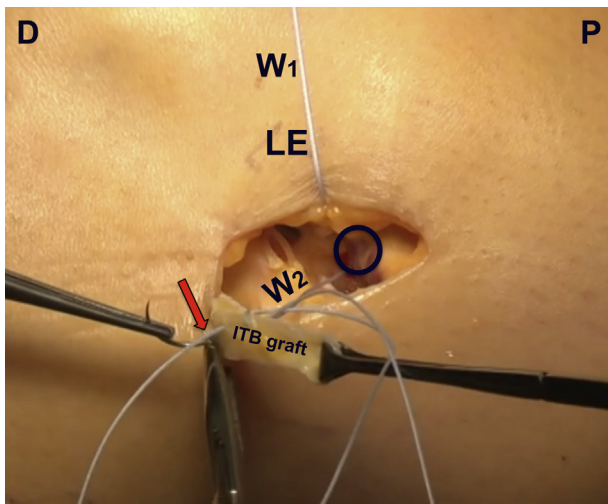


Fig 10. The patient is in supine position with the left knee in $>90^\circ$ flexion and neutral rotation. Two wires originate from the placed suture anchor (circle). Wire 1 (W1) is held toward the anterior border of the skin incision by an assistant and is later used to hoist the iliotibial band (ITB) graft toward the femur. Wire 2 (W2) is attached to a suture needle and is used to whipstitch the ITB graft (marked by arrow). Abbreviations: D, distal side; LE, lateral epicondyle (femur); P, proximal side.

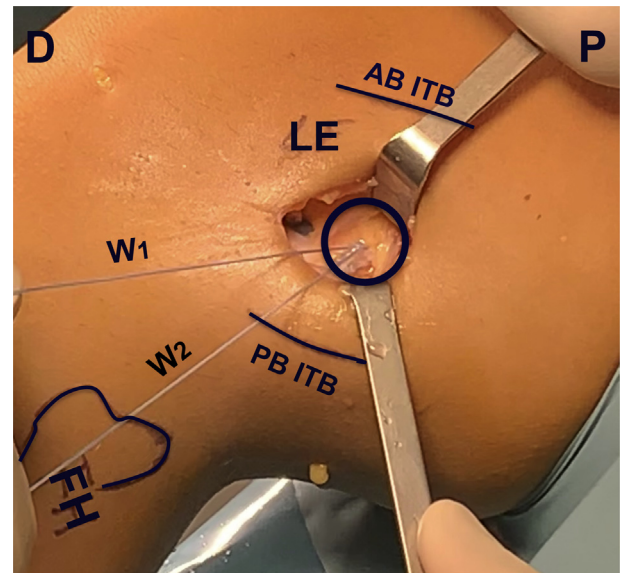


Fig 11. The patient is in supine position with the left knee brought from $>90^\circ$ to $>30^\circ$ flexion and neutral rotation. After whipstitching the iliotibial band (ITB) graft with wire 2 (W2), wire 1 (W1) is used to hoist the ITB graft toward the suture anchor placed on the femur (circle). With sufficient tension on the graft, the wires are tied together, securing the graft onto the femur. Abbreviations: AB ITB, anterior border iliotibial band; D, distal side; FH, fibular head; LE, lateral epicondyle (femur); P, proximal side; PB ITB, posterior border iliotibial band.

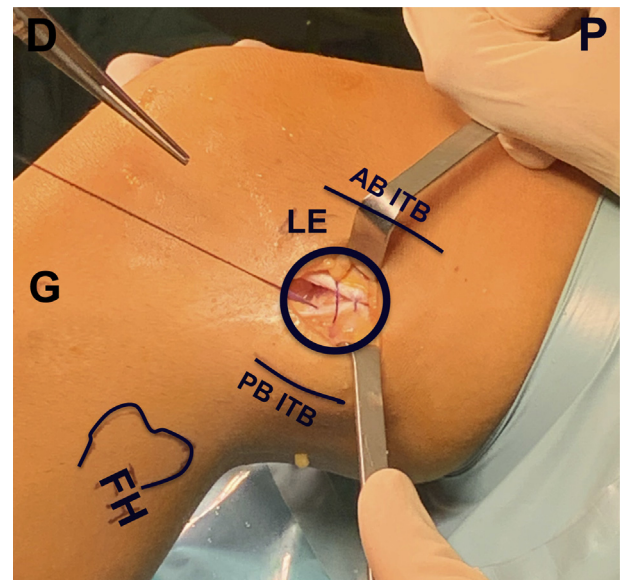


Fig 12. The patient is in supine position with the left knee in $>30^\circ$ flexion and neutral rotation. After evaluating adequate tensioning patterns (the lateral extra-articular tenodesis should tension with internal rotation), the iliotibial band donor defect is closed using a barbed suture (Stratafix; Johnson & Johnson) (circle). Abbreviations: AB ITB, anterior border iliotibial band; D, distal side; FH, fibular head; G, Gerdy's tubercle; LE, lateral epicondyle (femur); P, proximal side; PB ITB, posterior border iliotibial band.

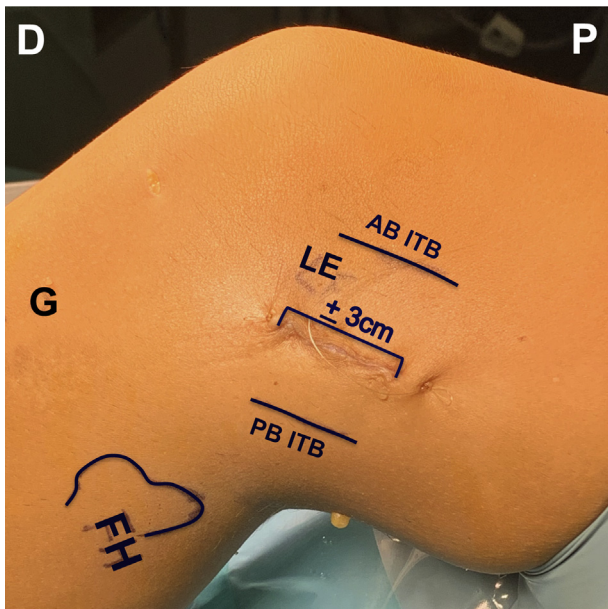


Fig 13. The patient is in supine position with the left knee in $>30^\circ$ flexion and neutral rotation. The wound, measuring ~ 3 cm in length, is closed, and the minimally invasive modified Lemaire procedure is complete. Abbreviations: AB ITB, anterior border iliotibial band; D, distal side; FH, fibular head; G, Gerdy's tubercle; LE, lateral epicondyle (femur); P, proximal side; PB ITB, posterior border iliotibial band.

experience, this technique primarily leads to increased knee stability and decreased graft rupture rate, similar to other LET techniques, but also may

be associated with less pain, quicker recovery, and better cosmesis compared with other LET techniques.

There is an increasing body of evidence that an LET procedure as augmentation to ACL reconstruction helps control rotatory laxity and reduces the chance of an early graft failure in young and active patients.^{16,19,20} Different techniques have been described for either LET or ALL reconstruction, with no technique clinically superior to another.^{21,22} Despite their apparent advantage, techniques for reinforcing the ALC come with their own subset of complications associated with the additional procedure and use of extra hardware. Drilling an additional tunnel in the lateral femoral condyle may lead to converging with the ACL tunnel, thereby compromising fixation.^{23,24} Alternatively, the use of additional hardware such as staples prominent on the femoral cortex may lead to pain or discomfort, warranting hardware removal.¹⁶ Perioperative retraction of the vastus lateralis muscle may lead to decreased quadriceps strength,^{18,25} and finally, shorter scars are generally preferred over longer scars.²⁶

In an attempt to overcome these drawbacks, we hereby propose a surgical technique requiring only a short skin incision for better aesthetics and use of a small femoral suture anchor obviating tunnels or staples, while not compromising the vastus lateralis muscle.

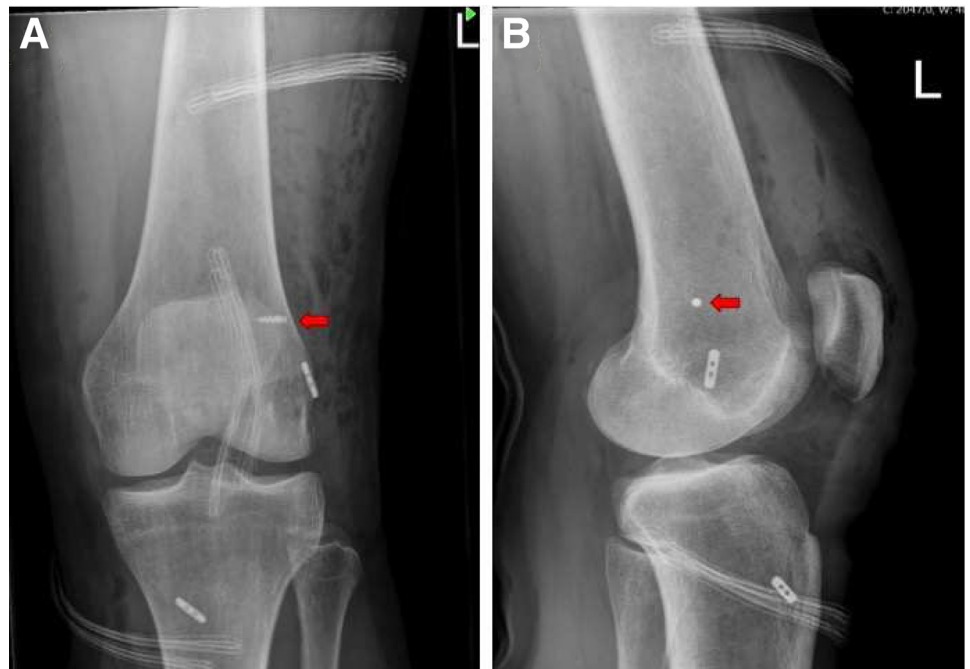

Fig 14. Radiographic imaging of the left knee after all-inside anterior cruciate ligament reconstruction combined with minimally invasive modified Lemaire tenodesis. (A) Anteroposterior image. (B) Lateral image. The red arrow marks the titanium suture anchor (FASTak; Arthrex).

References

- Segond P. Recherches cliniques et expérimentales sur les épanchements sanguins du genou par entorse. *Prog Méd* 1879;16:297-421.
- Hess T, Rupp S, Hopf T, Gleitz MLJ. Lateral tibial avulsion fractures and disruptions to the anterior cruciate ligament: A clinical study of their incidence and correlation. *Clin Orthop Relat Res* 1994;303:193-197.
- Goldman AB, Pavlov H, Rubenstein D. The Segond fracture of the proximal tibia: A small avulsion that reflects major ligamentous damage. *Am J Roentgenol* 1988;151:1163-1167.
- Claes S, Vereecke E, Maes M, Victor J, Verdonk P, Bellemans J. Anatomy of the anterolateral ligament of the knee. *J Anat* 2013;223:321-328.
- Musahl V, Rahnama-Azar AA, Costello J, et al. The influence of meniscal and anterolateral capsular injury on knee laxity in patients with anterior cruciate ligament injuries. *Am J Sports Med* 2016;44:3126-3131.
- Spencer L, Burkhart TA, Tran MN, et al. Biomechanical analysis of simulated clinical testing and reconstruction of the anterolateral ligament of the knee. *Am J Sports Med* 2015;43:2189-2197.
- Noyes FR, Huser LE, Levy MS. Rotational knee instability in ACL-deficient knees: Role of the anterolateral ligament and iliotibial band as defined by tibiofemoral compartment translations and rotations. *J Bone Joint Surg Am* 2017;99:305-314.
- Parsons EM, Gee AO, Spiekerman C, Cavanagh PR. The biomechanical function of the anterolateral ligament of the knee. *Am J Sports Med* 2015;43:669-674.
- Chouliaras V, Ristanis S, Moraiti C, Stergiou N, Georgoulis A. Effectiveness of reconstruction of the anterior cruciate ligament with quadrupled hamstrings and bone-patellar tendon-bone autografts: An in vivo study comparing tibial internal-external rotation. *Am J Sports Med* 2007;35:189-196.
- Lohmander LS, Englund PM, Dahl LL, Roos EM. The long-term consequence of anterior cruciate ligament and meniscus injuries: Osteoarthritis. *Am J Sports Med* 2007;35:1756-1769.
- Novaretti JV, Arner JW, Chan CK, et al. Does lateral extra-articular tenodesis of the knee affect anterior cruciate ligament graft in situ forces and tibiofemoral contact pressures? *Arthroscopy* 2020;36:1365-1373.
- Sonnery-Cottet B, Saithna A. Let's ALL agree—anterior cruciate ligament reconstruction outcomes need to be improved and extra-articular procedures have an essential role. *Arthroscopy* 2020;36:1702-1705.
- Schlichte LM, Aitchison AH, Green DW, Cordasco FA. Modified Lemaire lateral extra-articular tenodesis in the pediatric patient: An adjunct to anterior cruciate ligament reconstruction. *Arthrosc Tech* 2020;9:e111-e116.
- Pavão DM, Cruz RS, de Faria JLR, de Sousa EB, Barretto JM. Modified Lemaire lateral tenodesis associated with an intra-articular reconstruction technique with bone-tendon-bone graft using an adjustable fixation mechanism. *Arthrosc Tech* 2019;8:e733-e740.
- Bernholt DL, Kennedy MI, Crawford MD, DePhillipo NN, LaPrade RF. Combined anterior cruciate ligament reconstruction and lateral extra-articular tenodesis. *Arthrosc Tech* 2019;8:e855-e859.
- Getgood AMJ, Bryant DM, Litchfield R, et al. Lateral extra-articular tenodesis reduces failure of hamstring tendon autograft anterior cruciate ligament reconstruction: 2-Year outcomes from the STABILITY study randomized clinical trial. *Am J Sports Med* 2020;48:285-297.
- Sonnery-Cottet B, Daggett M, Fayard JM, et al. Anterolateral Ligament Expert Group consensus paper on the management of internal rotation and instability of the anterior cruciate ligament—deficient knee. *J Orthop Traumatol* 2017;18:91-106.
- Getgood A, Hewson C, Bryant D, et al. No difference in functional outcomes when lateral extra-articular tenodesis is added to anterior cruciate ligament reconstruction in young active patients: The Stability Study. *Arthrosc J Arthrosc Relat Surg* 2020;36:1690-1701.
- Song GY, Hong L, Zhang H, Zhang J, Li Y, Feng H. Clinical outcomes of combined lateral extra-articular tenodesis and intra-articular anterior cruciate ligament reconstruction in addressing high-grade pivot-shift phenomenon. *Arthroscopy* 2016;32:898-905.
- Hewison CE, Tran MN, Kaniki N, Remtulla A, Bryant D, Getgood AM. Lateral extra-articular tenodesis reduces rotational laxity when combined with anterior cruciate ligament reconstruction: A systematic review of the literature. *Arthroscopy* 2015;31:2022-2034.
- Delaloye JR, Hartog C, Blatter S, et al. Anterolateral ligament reconstruction and modified lemaire lateral extra-articular tenodesis similarly improve knee stability after anterior cruciate ligament reconstruction: A biomechanical study. *Arthroscopy* 2020;36:1942-1950.
- Ra HJ, Kim JH, Lee DH. Comparative clinical outcomes of anterolateral ligament reconstruction versus lateral extra-articular tenodesis in combination with anterior cruciate ligament reconstruction: Systematic review and meta-analysis. *Arch Orthop Trauma Surg* 2020;140:923-931.
- Perelli S, Erquicia JI, Ibañez M, et al. Evaluating for tunnel convergence in anterior cruciate ligament reconstruction with modified Lemaire tenodesis: What is the best tunnel angle to decrease risk? *Arthroscopy* 2020;36:776-784.
- Jaeger V, Herbort M, Bouillon B, Günther D, Shafizadeh S. High incidence of tunnel collision in combined ACL reconstruction and LET. *Orthop J Sport Med* 2020;8(5 suppl 4):2325967120S0031.
- Strum GM, Fox JM, Ferkel RD, et al. Intraarticular versus intraarticular and extraarticular reconstruction for chronic anterior cruciate ligament instability. *Clin Orthop Relat Res* 1989;245:188-198.
- Chaung K, Duke WS, Oh SJ, et al. Aesthetics in thyroid surgery: The patient perspective. *Otolaryngol Head Neck Surg* 2017;157:409-415.