

---

## Anaesthesia for frameless stereotactic neurosurgery in a patient with Cheyne-Stokes respiration

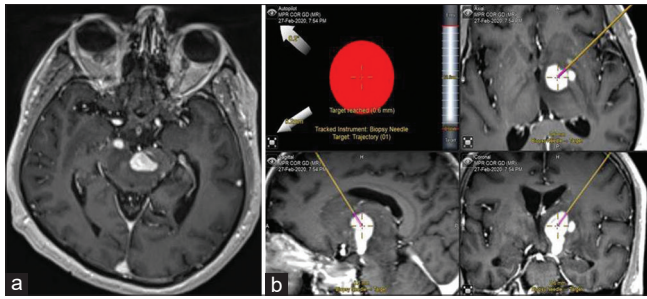
Sir,

Frameless stereotactic biopsy is commonly employed for precision neurosurgery to increase diagnostic yield and patient safety. This technique avoids patient discomfort and allows for better airway management.<sup>[1]</sup> Most patients receive general anaesthesia and perioperative complications are rare. There are no previous reports on anaesthetic management in a patient with Cheyne–Stokes respiration (CSR) and hence this report.

A 52-year-old gentleman presented with complaints of progressive drowsiness since 2 months. Frame-based stereotactic biopsy for right capsuloganglionic lesion extending into the brainstem performed elsewhere did not yield conclusive results. Currently, he presented to our hospital with drowsiness and drooping of the left eyelid. On examination, he was drowsy but arousable with weakness on the right side and left third nerve palsy. Cardiac workup did not suggest evidence of heart failure. Magnetic resonance imaging revealed left midbrain [Figure 1a] and right capsuloganglionic lesion, suggestive of lymphomas. He was scheduled for a frameless stereotactic navigation-guided biopsy

of the right capsuloganglionic lesion. Pre-anaesthetic evaluation revealed oxygen saturation (SpO<sub>2</sub>) of 91% with irregular respiration (hyperventilation with periods of apnoea). Considering various factors, i.e., apnoea-hyperventilation breathing pattern, history of snoring, midbrain pathology, neurological status, minimally invasive diagnostic nature of the surgery and proposed early discharge, we planned awake surgery with incision-site local anaesthetic infiltration with 6 mL of 1% lignocaine and dexmedetomidine to retain spontaneous respiration close to his preoperative physiological status. Dexmedetomidine infusion was started at 0.5 µg/kg/h and titrated between 0.5 to 1 µg/kg/h during surgery after 1 µg/kg bolus dose over 10 min. No other opioid/non-opioid analgesia or sedation was used. Conscious sedation was maintained with Ramsay sedation score between 2 and 4.

After establishing a path to the target using neuronavigation system (Brainlab Varioguide® frameless stereotactic system), burr-hole was made and needle passed to yield biopsy tissue. A total of three biopsies were taken and the procedure was completed in 20 min [Figure 1b]. Patient remained cooperative, immobile and comfortable for surgery with no additional neurological deficits. Though, CSR persisted throughout surgery [Figure 2], patient was stable with SpO<sub>2</sub> in the range of 96%–99%, heart rate 64–88/min and mean blood pressure 62–84 mmHg with supplemental oxygen at 6 L/min. Post-operative imaging demonstrated biopsy tract within the lesion. He was discharged with the same neurological status on prednisolone and levetiracetam medications.

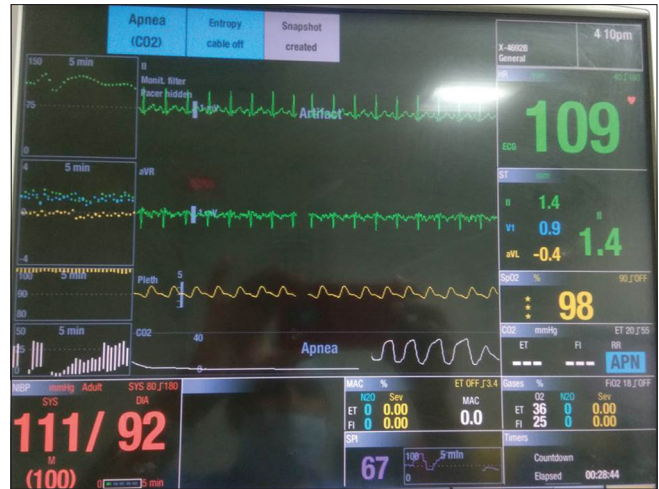


**Figure 1:** Gadolinium-enhanced axial cut of magnetic resonance imaging study demonstrating an enhancing left midbrain lesion (a) and trajectory of the frameless stereotactic biopsy with intraoperative position of the needle inside the target i.e., right capsulo-ganglionic lesion (b)

Histopathology report suggested diffuse B-cell lymphoma. He was on chemotherapy with improved clinical status at 3-months follow-up.

The CSR is a breathing disorder characterised by cyclical episodes of apnoea and hyperventilation and is mostly seen in heart failure.<sup>[2]</sup> Mesencephalon and thalamus stroke also result in central apnoea, obstructive apnoea and pathological respiratory events.<sup>[3]</sup> Central hyperventilation is known in pontine malignant lymphoma.<sup>[4]</sup> Shibata *et al.* reviewed 13 patients with neurogenic hyperventilation of which 10 had pontine involvement, highlighting the impact of brainstem lesions on respiratory pattern. Patients with intracranial pathology present with weaning difficulty from neurogenic respiratory failure.<sup>[5]</sup>

There are several implications of CSR for anaesthesiologists.<sup>[6]</sup> First, though under-reported in anaesthesia literature, it is not an uncommon occurrence. It is mostly described in patients with cardiac failure who should be thoroughly evaluated and optimised before surgery. Second, in the absence of heart failure, CSR due to neurological pathology should be evaluated for obstructive and central sleep apnoeas. Third, patients with CSR exhibit extreme sensitivity and vulnerability to respiratory depressant effects of anaesthetic agents, opioids and neuromuscular blocking drugs. General anaesthesia, where possible, should be avoided as these patients are at an increased risk of adverse perioperative respiratory events (apnoea, airway obstruction, hypoxaemia and difficulty in weaning and extubation). Dexmedetomidine on the contrary, has no/minimal effect on the respiratory pattern in CSR, provides conscious-sedation and results in patient comfort and satisfaction during stereotactic neurosurgeries.



**Figure 2:** Snapshot of the multi-parameter patient monitor showing Cheyne–Stoke respiration at baseline (Hyperventilation-apnoea breathing pattern)

Loco-regional anaesthesia with dexmedetomidine<sup>[7]</sup> provides desirable conditions and is therefore preferable for awake neurosurgery in patients with CSR.

#### Declaration of patient consent

Written informed consent was obtained from the legal guardian of the patient for scientific dissemination of the case.

#### Financial support and sponsorship

Nil.

#### Conflicts of interest

There are no conflicts of interest.

**Kamath Sriganesh, Harsh Deora<sup>1</sup>, GM Tejaswi**

Departments of Neuroanaesthesia and Neurocritical Care, and  
<sup>1</sup>Neurosurgery, National Institute of Mental Health and Neurosciences,  
Bengaluru, Karnataka, India

#### Address for correspondence:

Dr. Kamath Sriganesh,  
Department of Neuroanaesthesia and Neurocritical Care, National  
Institute of Mental Health and Neurosciences, Bengaluru, Karnataka,  
India. E-mail: drsri23@gmail.com

**Submitted:** 31-Mar-2020

**Revised:** 07-May-2020

**Accepted:** 27-May-2020

**Published:** 01-Oct-2020

#### REFERENCES

- Lu Y, Yeung C, Radmanesh A, Wiemann R, Black PM, Golby AJ. Comparative effectiveness of frame-based, frameless, and intraoperative magnetic resonance imaging-guided brain biopsy techniques. *World Neurosurg* 2015;83:261-8.
- Rudrappa M, Bollu PC. Cheyne Stokes Respirations. [Updated

2019 Dec 10]. In: StatPearls [Internet]. Treasure Island (FL): StatPearls Publishing; 2020 Jan. Available from: <https://www.ncbi.nlm.nih.gov/books/NBK448165>.

3. Faludi B, Tóth M, Pusch G, Komoly S. Dynamic changes in sleep-related breathing abnormalities in bilateral paramedian mesencephalon and thalamus stroke: A follow-up case study. *Sleep Breath* 2016;20:237-42.
4. Shibata Y, Meguro K, Narushima K, Shibuya F, Doi M, Kikuchi Y. Malignant lymphoma of the central nervous system presenting with central neurogenic hyperventilation. Case report. *J Neurosurg* 1992;76:696-700.
5. Carvalho FA, Bernardino T, Maciel RO, Felizola SF, Costa EL, Silva GS. Central neurogenic respiratory failure: A challenging diagnosis. *Case Rep Neurol* 2011;3:75-81.
6. Ariès P, Danguy des Déserts M, Nguyen BV,

Ould-Ahmed M. Cheyne-Stokes respiration: Implications for anaesthesiologists. *Anaesth Crit Care Pain Med* 2017;36:245-6.

7. Sokhal N, Rath GP, Chaturvedi A, Dash HH, Bithal PK, Chandra PS. Anaesthesia for awake craniotomy: A retrospective study of 54 cases. *Indian J Anaesth* 2015;59:300-5.

| Access this article online                                                         |                                                                |
|------------------------------------------------------------------------------------|----------------------------------------------------------------|
| Quick response code                                                                | Website:<br><a href="http://www.ijaweb.org">www.ijaweb.org</a> |
|  | DOI:<br>10.4103/ija.IJA_322_20                                 |

This is an open access journal, and articles are distributed under the terms of the Creative Commons Attribution-NonCommercial-ShareAlike 4.0 License, which allows others to remix, tweak, and build upon the work non-commercially, as long as appropriate credit is given and the new creations are licensed under the identical terms.

**How to cite this article:** Sriganesh K, Deora H, Tejaswi GM. Anaesthesia for frameless stereotactic neurosurgery in a patient with Cheyne–Stokes respiration. *Indian J Anaesth* 2020;64:913-5.  
© 2020 Indian Journal of Anaesthesia | Published by Wolters Kluwer - Medknow