

Cooperation between ENT surgeon and dentist in head and neck oncology

Cooperazione tra otorinolaringoiatra e odontostomatologo in oncologia cervico-cefalica

Mattia Berrone^{1,2}, Carlo Lajolo^{3,4}, Eugenio De Corso³, Stefano Settimi³, Cosimo Rupe³, Erika Crosetti¹, Giovanni Succo^{1,2}

¹ Head and Neck Oncology Service, Candiolo Cancer Institute – FPO, IRCCS, Candiolo, Italy; ² Department of Oncology, University of Turin, Turin, Italy; ³ Head and Neck Department, “Fondazione Policlinico Universitario A. Gemelli – IRCCS” Rome, Italy; ⁴ School of Dentistry, Università Cattolica del Sacro Cuore, Rome, Italy

SUMMARY

Head and neck cancer (HNC) patients require specialized care throughout the continuum of cancer diagnosis, treatment, and survival. Cooperation between ENT and dentists is crucial, since all of the different anatomic areas affected by cancer have distinctive characteristics and the best results in terms of life expectancy and patients' quality of life can only be achieved through a multidisciplinary approach. The synergic cooperation of all health care workers in the early diagnosis of HNC allows a better prognosis for such patients. As soon as dentists diagnose a Potentially Malignant Disorder (PMD), patients should undergo complete ENT screening for detection of lesions in any portion of the upper aerodigestive tract. Before and after cancer diagnosis and before any oncologic treatment, it is critical that these patients undergo an accurate and complete dental and periodontal assessment to optimize treatment and minimize complications or side effects. Multidisciplinary ablative, reconstructive and prosthetic programming in Head & Neck oncologic surgery has become imperative to offer patients the best functional and esthetic outcome. An improvement in oral function and associated quality of life is strictly related to correct prosthetic rehabilitation. Finally, after surgery and/or radiotherapy (RT), the main objectives of dental treatment in these patients are the prevention and therapy of dental diseases and the side effects of oncological therapies involving the oral cavity.

KEY WORDS: potentially malignant disorder (PMD), oral care, osteoradionecrosis, oral mucositis, prosthetic implant, jaw reconstruction

RIASSUNTO

I pazienti affetti da tumori della testa e del collo (HNC) richiedono cure specialistiche lungo tutto l'iter diagnostico-terapeutico. La collaborazione tra otorinolaringoiatra e odontostomatologo risulta fondamentale, poiché le diverse sedi anatomiche coinvolte dalla patologia oncologica hanno caratteristiche peculiari, e i migliori risultati in termini di aspettativa e qualità di vita possono essere raggiunti solo attraverso un approccio multidisciplinare. La collaborazione sinergica di tutti gli operatori sanitari nella diagnosi precoce di tali tumori consente una prognosi migliore per questi pazienti; in quest'ottica, subito dopo la diagnosi di patologie odontostomatologiche potenzialmente maligne (PMD), i pazienti dovrebbero sottoporsi a uno screening ORL completo per l'individuazione di lesioni del tratto aero-digestivo superiore. È fondamentale che, dopo la diagnosi di carcinoma e prima di qualsiasi trattamento oncologico, questi pazienti ricevano una valutazione dentale e parodontale accurata e completa, per ottimizzare il trattamento e ridurre al minimo le complicanze o gli effetti collaterali. La pianificazione multidisciplinare ablativa, ricostruttiva e protesica nella chirurgia oncologica testa-collo è diventata indispensabile per offrire ai pazienti il miglior risultato funzionale ed estetico; un miglioramento della funzione orale e della relativa qualità di vita è infatti strettamente correlato a una corretta riabilitazione protesica. Infine, prima e dopo l'intervento chirurgico e/o la radioterapia, gli obiettivi principali del trattamento odontoiatrico in questi pazienti sono rappresentati dalla prevenzione e dal trattamento delle malattie dentali e degli effetti collaterali dei vari trattamenti oncologici a livello del cavo orale.

PAROLE CHIAVE: disordini potenzialmente maligni (PMD), salute orale, osteoradionecrosi, mucosite orale, riabilitazione implanto-protesica, ricostruzione mandibolare, ricostruzione mascellare

Received: October 2, 2020

Accepted: January 8, 2021

Correspondence

Carlo Lajolo

Head and Neck Department, “Fondazione Policlinico Universitario A. Gemelli – IRCCS”, School of Dentistry, Università Cattolica del Sacro Cuore, Largo A. Gemelli 8, 00168 Rome, Italy
E-mail: carlo.lajolo@unicatt.it

Funding

None.

Conflict of interest

The Authors declare no conflict of interest.

How to cite this article: Berrone M, Lajolo C, De Corso E, et al. Cooperation between ENT surgeon and dentist in head and neck oncology. Acta Otorhinolaryngol Ital 2021;41(SUPPL.1):S124-S137. <https://doi.org/10.14639/0392-100X-suppl.1-41-2021-13>

© Società Italiana di Otorinolaringoiatria e Chirurgia Cervico-Facciale



OPEN ACCESS

This is an open access article distributed in accordance with the CC-BY-NC-ND (Creative Commons Attribution-NonCommercial-NoDerivatives 4.0 International) license. The article can be used by giving appropriate credit and mentioning the license, but only for non-commercial purposes and only in the original version. For further information: <https://creativecommons.org/licenses/by-nc-nd/4.0/deed.en>

Introduction

The term “head and neck cancer” (HNC) generally comprises malignant cancers which arise in the upper aerodigestive tract, and the complex anatomy makes the diagnosis and treatment of these cancers highly demanding. Cooperation between ENT and dentists is crucial to achieve good clinical practice, since all of the different anatomic areas have distinctive characteristics. Furthermore, the oral cavity can experience both the cancer itself and the side effects of cancer therapy of adjacent anatomic areas (i.e., the pharynx, sinuses, major salivary glands, the nasal cavity, and the ears). HNCs and their therapy can lead to devastating cosmetic and functional deficits with resultant psychological, physical, functional and nutritional detriments, thus a personalized medical approach and minimally invasive techniques can help to increase the quality of life of these patients. Furthermore, on the basis of more recent experience, the best results in terms of life expectancy and patients’ quality of life can only be achieved through a multidisciplinary approach, beginning with prevention, and then early diagnosis, therapy and follow-up. This review has been written considering the most salient aspects of the clinical collaboration between otolaryngologists and dentists in the early diagnosis and management of the patient affected by head and neck cancer.

Diagnosis and management of potentially malignant disorders

Many different oral lesions can have an increased probability of evolving into cancer and constitute a heterogeneous group of diseases; historically, in 1978, WHO classified all these diseases as “oral lesions” or “oral conditions”, considering the first as a disease of the oral mucosa and the second as systemic diseases, which can carry an increased probability to develop/evolve into oral cancer. The WHO classification was revised in 2007 and recently in 2017 introduced the term potentially malignant disorder (PMD), based on the field cancerization concept. All of these diseases have not only an increased probability to evolve into cancer in the affected oral mucosa, but in addition, other primary cancers can arise in any portion of the upper aerodigestive tract¹. A multidisciplinary synergic approach in the early diagnosis of HNC provides a better prognosis for such patients, in terms of quality of life and life expectancy. As soon as dentists diagnose a PMD, patients should undergo complete ENT screening for detection of lesions in any portion of the upper aerodigestive tract². Leukoplakia, erythroplakia, oral lichen planus and oral submucous fibrosis are the most frequent

PMDs with some geographic and epidemiologic differences (Fig. 1).

The term *Oral Leucoplakia* (LP) describes a white patch or plaque, with an increased risk of malignant transformation (or, in a few cases, it can already be a cancer) having excluded (other) known diseases or disorders that are white (i.e. Frictional keratosis, Acute pseudomembranous candidiasis, Leukoedema, Lichen planus (plaque type) and Lichenoid lesion and reaction, Discoid lupus erythematosus, Hairy leukoplakia, Reverse Smoking). This definition is an exclusion diagnosis and a biopsy is mandatory to explore the pathology, which can range from squamous hyperplasia, to mild, moderate, or severe dysplasia/carcinoma in situ, or to carcinoma. LP is the most frequent PMD. Non-homogeneous lesions have a higher risk of dysplasia or cancer. Severe dysplasia, aneuploidy, loss of heterozygosity, HPV 16+, diameter wider than 2 cm, ventral tongue or floor of the mouth, female sex, age older than 50 years are all risk factors for further progression toward cancer³. Smoking habit is a risk factor for the onset of LP, nevertheless, LP in a non-smoking patient could have a higher risk of malignant transformation.

Erythroplakia (EP) is a clinical term that describes a red patch or plaque, with an increased risk of malignant transformation (or in many cases, its pathology shows severe dysplasia, carcinoma in situ or cancer) having excluded (other) known diseases or disorders that appear as red in color (i.e. Oral lichen planus, Discoid lupus erythematosus, Pemphigoid and Pemphigus, Kaposi’s sarcoma, Erythematous candidiasis, Hemangioma). It often appears as a mixture of LP and EP, known as erythroleukoplakia, since pure EP is rare. Optimum therapy and follow-up (recall) visits for leukoplakia are still debated since relapses and new localizations are frequent, whereas a more aggressive therapy (mainly surgery) and follow-up regimen are suggested for erythroplakia⁴.

Oral lichen planus (OLP) is a mucocutaneous inflammatory disorder which can affect the skin and/or mucous membrane. Oral lesions are generally bilateral, white in color on an erythematous base, and typically reticular and/or radiate. The etiology of OLP is still unknown and all of the aspects of immunity have been detected as dysregulated, with an important role played by lymphocyte T cells. Clinical features can vary (reticular, plaque, atrophic erosive and desquamative gingivitis) and in many cases, pain and a burning sensation affect the patients, especially in its atrophic/erosive forms. On the other hand, when clinical and pathological features are not conclusively detected, a final diagnosis of Oral lichenoid lesions can be made⁵. The risk of transformation is around 1.4% per year and tongue lesions, erosive form and female sex are risk factors for

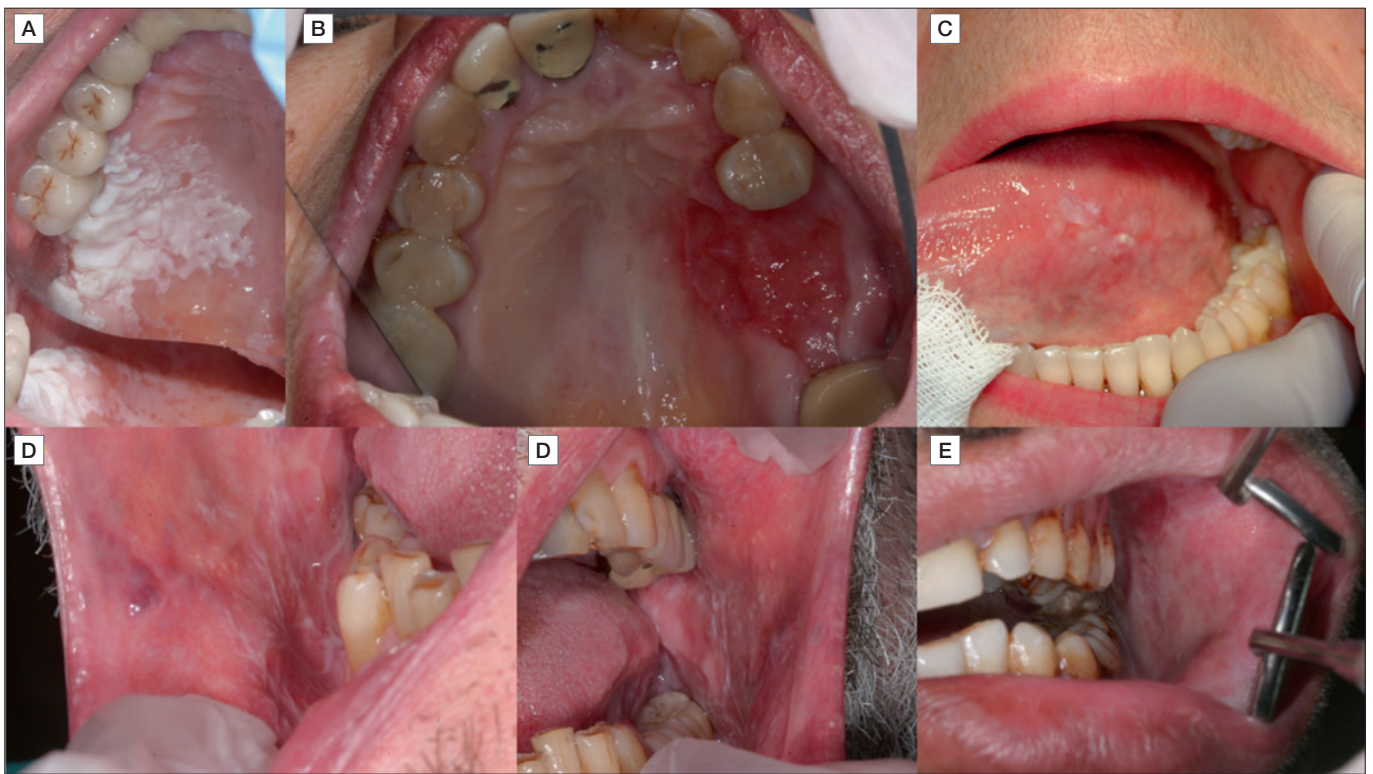


Figure 1. Potentially malignant disorders: the most common are: (A) leukoplakia; (B) erythroplakia; (C) leukoerythroplakia; (D) oral lichen planus (same patient); (E) oral submucous fibrosis.

transformation, thus OLP patients should undergo a strict clinical follow-up (recall visits every 3 months and biopsies must be performed whenever lesions become more suspicious) ^{5,6}.

Oral submucous fibrosis is a progressive fibrotic degeneration of the oral mucous membrane predominantly seen in South East Asia and which affects young adults. It is mainly due to the areca nut and use of its derived products (chewing): these products, mixed with tobacco, are stored in the buccal vestibule and chewed. The affected mucosa appears initially inflamed and, with continuing carcinogenic stimuli, it becomes fibrotic, opaque and blanched and finally, movements of the tongue and of the buccal mucosa are impaired with a diminished opening of the mouth. Even though some medical therapies have been suggested ^{7,8}, treatment should consider stopping areca nut chewing, monitoring for malignant transformation, and surgical procedures to improve mouth opening ^{9,10}.

Diagnostic procedures

PMDs, and all pathological tissue removed from the oral cavity, should undergo histological examination to confirm the nature of the lesion. Biopsy can be performed either with a diagnostic-therapeutic purpose (Excisional

biopsy) or with just a diagnostic purpose (Incisional biopsy) ¹¹.

No criteria have been defined to choose between an excisional or incisional biopsy, but, since oral cancer therapy varies according to staging, excisional biopsy should only be considered for benign lesions or for small lesions (0.5-1 cm) highly suspicious for malignancy. An excisional biopsy with diagnostic and therapeutic purpose can also be performed in selected lesions less than 2 cm in width, if oncologic radicality can be guaranteed. In this case, the surgical specimen should include at least 1 cm of healthy tissue all around the lesion ¹². Biopsy can be performed either with a cold blade or with laser according to the experience of the surgeon, but the presence and sparing of delicate structures (i.e. arteries, nerves, gland ducts) should be considered.

Indications for incisional biopsy are: 1) lesions of large dimensions, 2) lesions with a high probability of malignancy which could not be completely removed, 3) lesions involving most of the oral mucosa, or 4) lesions that are difficult to reach. The experience of the authors is that incisional biopsy should be performed when malignancy is suspected, even for lesions with small dimensions (1-2 cm width), for at least two reasons: 1) small cancers could have already

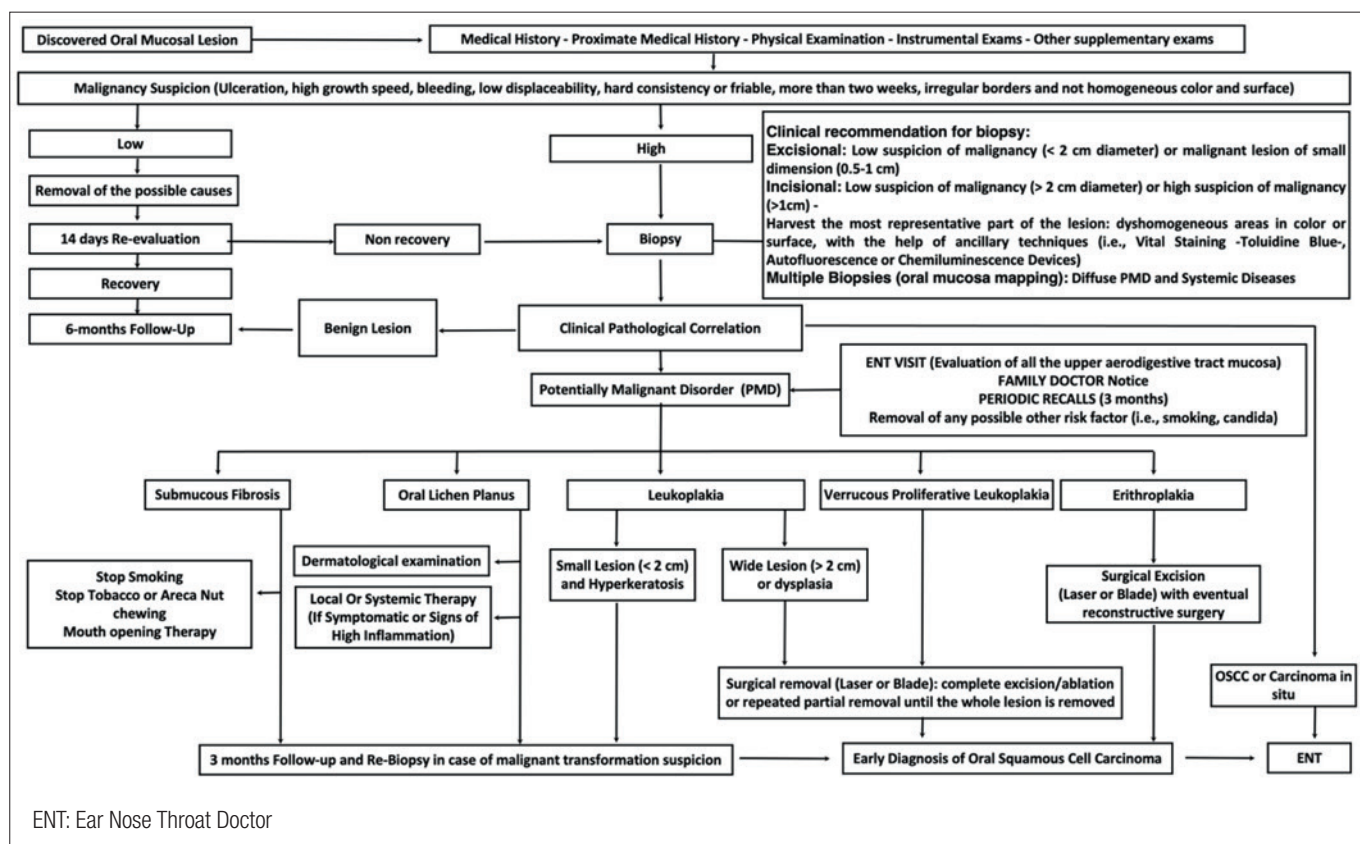


Figure 2. Diagnostic-therapeutic flow-chart for Oral Mucosal Lesions, focusing on the clinical management of Potentially Malignant Disorders (PMD) and early diagnosis of Oral Squamous Cell Carcinoma (OSCC).

spread to the lymph nodes and 2) to facilitate the ENT oncologic surgeon in identifying the site of primary malignancy¹³.

Incisional biopsy can include part of the healthy surrounding tissue in order to provide some information on possible infiltration, but the biopsy should be collected with the aim of giving the pathologist the most representative part of the lesion (often its center); on the other hand, necrotic areas in large lesions should be avoided because they do not provide useful information. However, during incisional biopsy, attention must be paid to preservation of the original characteristics of the lesion (site, dimensions, margins), in order to ensure the optimal conditions for possible radical excision in the case of malignancy. If the surgeon is unsure about the adequacy of the specimen, multiple biopsies can be performed. A diagnostic-therapeutic flow chart for oral mucosal lesions is proposed in Figure 2.

Diagnosis of intraosseous lesions of the mandible and maxillary sinus

Intraosseous lesions are often the result of problems as-

sociated with dentition. Bone biopsy indications mainly include those lesions that do not heal through traditional dental therapies, lesions that apparently have no correlation with dentition, and lesions not specifically identified by clinical and radiographic findings; these lesions can range from benign to malignant (i.e., maxillary sinus carcinomas to myxomas, ameloblastomas, sarcomas, keratocysts and odontogenic cysts). As pathologies in this region are difficult to reach or are in close proximity to important anatomic structures, e.g., tooth roots or nerves, they often represent a challenge¹⁴ to perform a correct biopsy without damaging those structures. Two types of biopsy technique can be used for diagnosing endosseous lesions according to their radiological aspect. Radiolucent lesions, especially those which do not erode the cortex, require the creation of a bone window to be able to biopsy the lesion; all radiolucent lesions should be aspirated before biopsy to obtain valid information on the contents of the lesion such as fluid-filled, solid, vascular or without contents. Radiopaque lesions can be biopsied with special cylindrical drills (trephine drill) capable of coring the bone itself, with a depth indicator to reach the correct depth, and based on an earlier computed

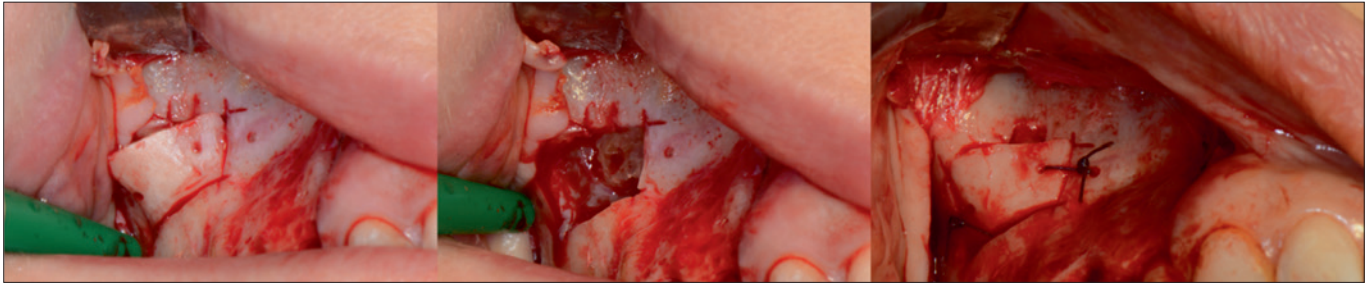

Figure 3. Lateral approach to the right maxillary sinus with bone window repositioning technique.

tomography (CT) scan. At present, guided biopsy of osseous pathologies in the jawbone using a 3D-printed drilling template¹⁴ allows a precise, minimally invasive approach, with an exact three-dimensional determination of the biopsy location before surgery. Moreover, an intraoral approach can easily be performed for intraosseous lesions of the maxillary sinus¹⁵ through the execution of the biopsy on an outpatient basis with local anesthesia (Fig. 3). An important aspect of hard tissue biopsies is to prevent the lesion from invading soft tissues after the biopsy examination¹⁶; this can be achieved by careful management of the periosteum and by positioning resorbable membranes over the bone breach.

Oral evaluation and prophylaxis before oncologic treatment

It is critical that, after the cancer diagnosis (i.e., during the period of staging procedures) and before any oncologic treatment¹⁷, these patients have an accurate and complete head, neck, oral, dental, and periodontal assessment to optimize treatment and minimize complications or side effects¹⁷. Assessment should include salivary gland function, the range of jaw opening and temporomandibular joint dysfunctions.

The presence of dental foci and poor periodontal status, in addition to influencing the healing of soft tissues, creates the risk of contamination of plates, screws and bone grafts in bone reconstructions. It is also essential to take into consideration that, after surgery and during adjuvant therapies, dental care is much more difficult. Patients often have considerable difficulty in opening their mouths and coordinating tongue and chewing movements, which are debilitated because of the therapies, and dental problems can be underestimated until they are of particular severity. Furthermore, other known risk factors such as irritation caused by ill-fitting dentures and other rough teeth surfaces must be explored and corrected. Pre-treatment dental care must be personalized and tailored to the patient's oral condition,

ability, and specific expected toxicities from the planned anti-neoplastic regimen. The dentist must:

- detect and treat dental and soft tissue infections;
- set up maintenance and prophylactic measures and instruct the patient for the duration of the therapy;
- select healthy dental elements that will support future prosthetic rehabilitation;
- cooperate in the reconstructive choice;
- define the best prosthodontic rehabilitation choice for the patient on the basis of a multidisciplinary comparison.

In addition, at present, dentistry can make use of optical impression systems that can be coupled with three-dimensional reconstructions of CT data to carry out appropriate studies even in patients with advanced disease and in whom it is difficult or impossible to take traditional impressions. These technologies allow the design of temporary prosthodontic rehabilitations by simulating surgical resection and by designing the prosthesis, the temporary obturator or customized bone implants on the basis of the resection.

Currently, multiplanar reconstruction (MPR) and cross-sectional images associated with tridimensional (3D) reconstruction represent the most useful imaging modalities for diagnoses and surgical planning in the head and neck district. With the advent of virtual surgical planning, tumors in the orofacial district require optimization of the diagnostic radiological phase. First of all, whenever possible, it is advisable to have a cervical-maxillofacial district CT examination performed after removing both the fixed and mobile prosthetic metal objects from the patient's oral cavity. This aspect has particular importance, especially as a function of the localization of the tumor and its proximity to metal artifacts, in particular, if there is a fixed supported implant rehabilitation. Optimization of the radiological diagnostic path is therefore up to the clinician, who, according to his/her experience and according to the patient's general condition, will have to immediately request a series of radiological examinations necessary for the staging of the disease but also for the reconstructive programing, espe-

cially in cases where the maxillary or mandibular bones are involved. This last consideration translates into requiring a thin-slice CT scan (1 mm) of the maxillofacial complex and at the same time as the donor site¹⁸. Moreover, it is important to remember that a thin-slice CT scan of this region is of great help in identifying dental foci and in planning dental treatments before oncologic surgery.

Planning of maxillary and mandibular reconstruction, implant therapy and prosthetic rehabilitation

Multidisciplinary ablative, reconstructive and prosthetic programming in Head & Neck oncologic surgery has become imperative to offer patients, even the elderly¹⁹, the best functional and esthetic result, especially when the stomatognathic system is involved. In our experience, this approach has also shown a greater adhesion and participation of patients in the therapeutic process as they are aware of the perspectives given and of the planned final result. Given the multifactorial challenges of maintaining quality of life, nutrition, and particularly oral intake, in this patient group, it is vital that interventions to support eating and drinking address the range of problems which interfere with the physical, functional and psychosocial aspects of opening the mouth, chewing, tasting and swallowing food. Each reconstructive method has distinctive characteristics and capabilities that can affect the subsequent phases of the patient's functional rehabilitation; the consideration of these complexities in jaw reconstruction is reflected in the wide variety of approaches and techniques that have evolved over the past century^{20,21}.

A primary reconstruction, where possible, generates significant benefits for a patient's residual quality of life and avoids major surgical procedures for secondary reconstruction. With the advent of virtual surgical planning, it is important to plan immediately what the targeted outcome will be, regardless of the timing in which the various steps

will be addressed. Preoperative comorbidities can often be the main factor leading to poorer results and are optimized whenever possible. A range of reconstructive options will be available and patient participation in the selection of procedures should be emphasized.

The reconstructive and rehabilitative management of the maxilla and mandible have different characteristics and options depending on the type of resection that will be performed.

Maxillary reconstruction

Maxillectomy defects are complex and involve a number of anatomic structures such as the hard and soft palate, nasal cavity, maxillary sinus and, in some cases, extend to the orbit with various grades of functional impairment. In their systematic review, Bidra et al.²² have concluded that a description of the defect based on six criteria (dental status, oroantral/nasal communication status, soft palate and other contiguous structure involvement, superior-inferior extent, anterior-posterior extent, medial-lateral extent of the defect) could be more objective and suitable for universal application in a classification system rather than a defect-based description alone.

The reconstructive choice (obturators, local/regional flaps, and microvascular free tissue transfer) depends primarily on the need to be able to clinically inspect the operated region and detect local recurrences. This aspect is strongly linked to the type and extent of the tumor. A prosthetic maxillary obturator, local and regional flaps are generally indicated for smaller defects, while microvascular grafts are highly recommended for larger defects (Fig. 4), with particular reference to defects requiring bone support²³. An obturator is the only solution able to give the patient a better quality of life when a local, regional or microvascular surgical approach is not feasible due to the characteristics and dimensions of the lesion or to poor systemic-medical conditions²³. Prosthodontic rehabilitation with a prosthetic obturator restores the missing structures and acts as a barrier

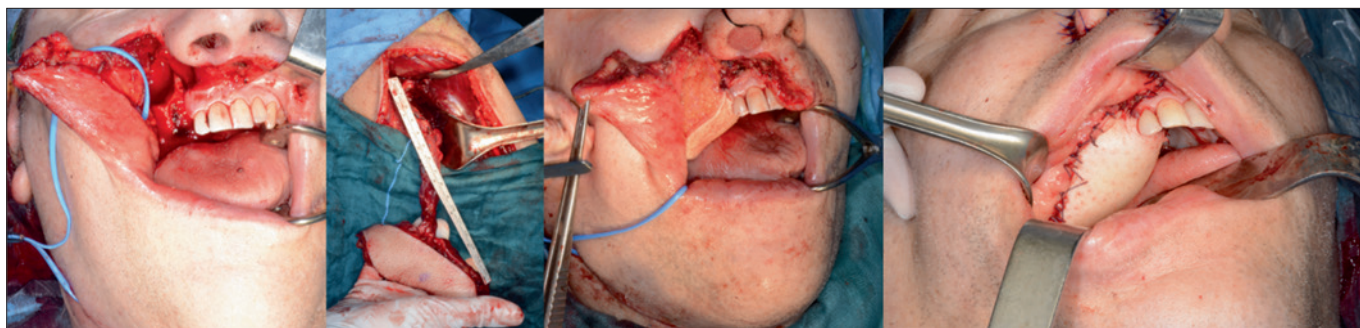


Figure 4. Maxillary reconstruction with fibula osteofasciocutaneous flap.

er to communication among the various cavities. The most common problem with prosthetic treatment is in attaining adequate retention, stability, and support. The size and location of the defect usually influence the amount of impairment and consequently the degree of difficulty regarding prosthetic rehabilitation. Residual dentition and the possibility of implant placement to stabilize the obturator play a key role. Advances in microvascular surgical techniques require comprehensive treatment planning guidelines for functional rehabilitation²⁴. Free-tissue transfer offers the most effective and reliable form of reconstruction for complex maxillectomy defects. At present, a combination of reconstructive techniques using local flaps, free flaps and implant-prosthetic procedures allows satisfactory results to be obtained in both functional and esthetic terms. Zygomatic implantology and the advent of customized titanium subperiosteal implants represent new and important therapeutic options from both a reconstructive and rehabilitative point of view²⁵.

Mandibular reconstruction

Mandibular defects due to major surgery can be classified according to location and extent, as well as involvement of mucosa, skin, and tongue. From the point of view of bone, mandibular defects can be continuous or discontinuous in relation to the bone invasion by the tumor and the possibility of being able to perform a marginal or segmental mandibulectomy.

Vascularized bone flaps, in general, provide the best functional and esthetic outcome, with the fibula flap remaining the gold standard for mandible reconstruction in segmental mandibulectomy. This flap can be modeled with multiple osteotomies and can provide bone, muscle and skin for composite reconstruction. Oral tongue/floor of mouth squamous cell carcinoma with a depth of invasion up to 10 mm involves extrinsic muscles, and lingual neurovascular/lymphatic bundles require a “compartmental” hemiglossopelectomy to improve locoregional control by “en bloc” removal of tumor and its pathways of spread^{26,27}. Compartmental surgery (CTS) has been proposed in advanced lesions with the intent to remove the tumor en bloc, within the entire hemitongue and floor-of-mouth compartment, along with the tract between the primary tumor and neck lymph nodes, the T-N tract, and draining lymph nodes, thus standardizing the surgical technique and improving locoregional control²⁸.

The introduction of computer-assisted mandibular reconstruction (CAMR) with the pivotal role of virtual surgical planning has further increased the accuracy of the preoperative plan and gives greater precision to the surgical procedure and a reduction in surgical time¹⁸. At the present

time, virtual surgical planning is a recognized technology for optimizing surgical outcome and minimizing operating time. Recent advances in mandibular reconstruction could be further refined through the application of the “two arches” concept. To optimize the outcome of the free fibula flap in mandibular reconstruction, the central portion of the mandible can be divided into upper and lower arches during preoperative evaluation and planning²⁹ in order to reconcile both the functional dental rehabilitation needs and the esthetic ones dictated by the lower edge of the mandible. CAMR allows osteotomy lines to be easily programmed oblique to the long axis of the fibula and mandible in an attempt to increase the contact area between the two bone surfaces³⁰. The combination of mandibular and fibular cutting guides and templates allows a precise and seamless surgical reconstruction; this technology is especially useful in minimizing operating time in complex defects where an osteofasciocutaneous flap is used for defect reconstruction and multiple osteotomies are required for bone modeling. The possibility of accurately programming the position of the bone segments is also important in the patient’s prosthetic rehabilitation; accurate occlusal restoration is definitely a key point to maintain stability over time without functional repercussions at the articular level; however, satisfactory rehabilitation only becomes achievable with a correctly positioned implant³¹. Dental implants in patients with fibula flaps are an appropriate and successful option for dental rehabilitation, even in those with risk factors such as smoking, alcohol use, and irradiation³². Implant virtual planning during CAMR must be considered an integral part of the reconstructive program to place fibular segments in the optimum position from both a functional and esthetic point of view regardless of their effective placement during surgery³¹ (Fig. 5). Moreover, correct programming, in selected cases, can also allow the use of dental implants to stabilize the bone segments in reconstructions that require a double barrel fibula flap³¹. CAMR offers the possibility of programming and executing both mandibular reconstruction and prosthetic implant rehabilitation in a single surgical and prosthetic session called “jaw in a day”. This procedure requires very accurate programming from both a surgical and implant-prosthetic point of view and careful coordination between all of the teams during surgery. We should remember how CAMR plays an important role in secondary mandibular reconstructions too. The possibility of programming reconstructions using the mirroring technique to restore good mandibular symmetry makes this type of reconstruction highly predictable from an esthetic and functional point of view. On the other hand, patients with advanced stages of oral cancer and reconstructed mandibles are nearly always additionally treated with radiotherapy and/

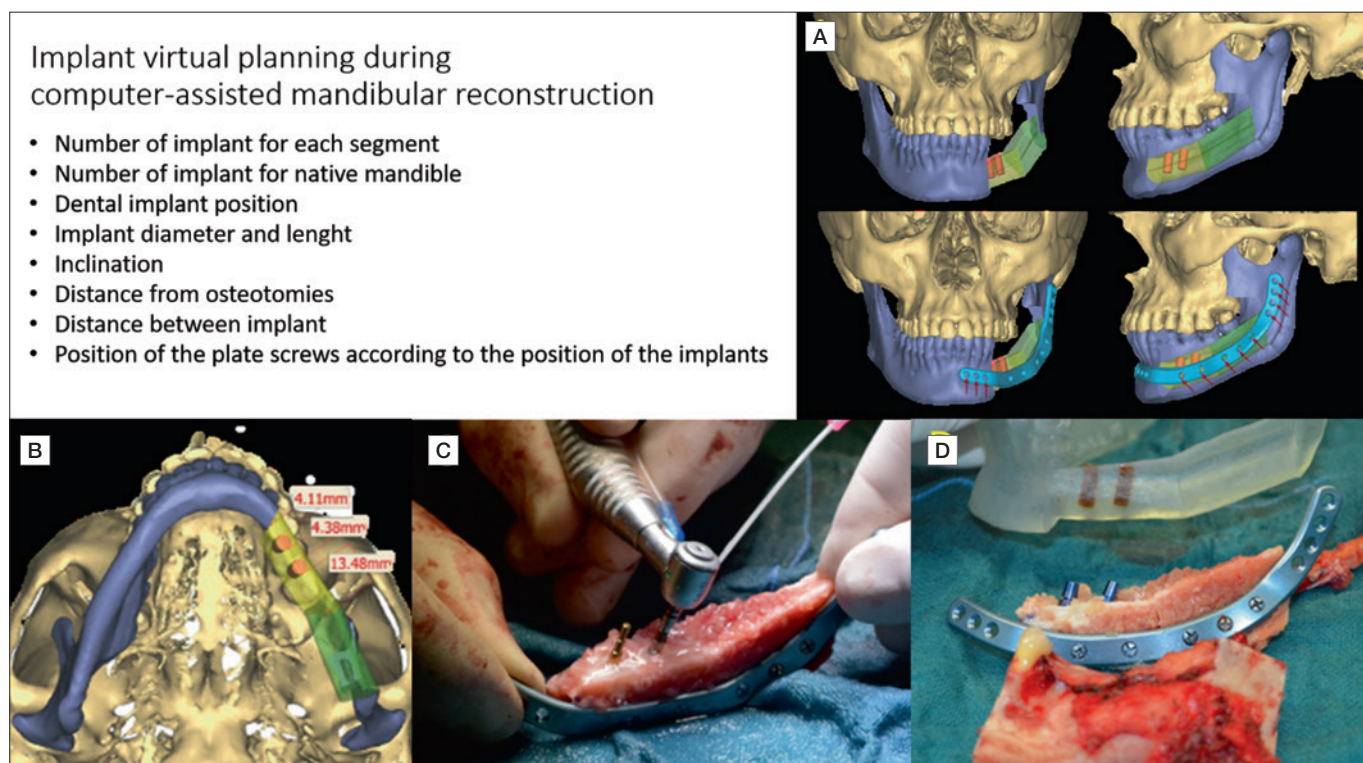


Figure 5. CAMR (A) with implant virtual planning (B); intraoperative positioning of implants into the fibula (C); final reconstructive complex (D): plate, fibula flap and dental implants.

or chemotherapy. The combination of these treatment modalities increases the risk for impaired wound healing after secondary (pre)prosthetic surgery, despite precautions such as hyperbaric oxygen therapy. Therefore, the patient's need and desire for dental rehabilitation must be weighed against the risk of complications after (pre)prosthetic surgery.

Implant surgery and prosthetic rehabilitation

Improvement in oral function and related quality of life would be expected with correct prosthetic rehabilitation. The main problems that may hamper proper prosthodontic rehabilitation of these patients include a severe reduction in the neutral zone, an impaired function of the tongue, and a very poor load-bearing capacity of the remaining soft tissue and mandibular bone.

From a prosthetic rehabilitation point of view, it is very important to consider how radiation therapy can influence the reconstructive dental therapeutic program and procedures, although a definitive decision on radiotherapy (RT) is usually made after definitive histological examination. The evolution of implant hardware and improvement in treatment strategies during recent years have affirmed that dental implant-supported rehabilitation is a valuable treatment option for patients with a history of RT in the head and

neck region^{33,34}; one of the most debated aspects is when dental implants must be placed to have the least possible complications³⁴. The presence of dental implants does not increase the risk of complications after surgery or during radiation treatment. Implants do not alter radiation dosimetry but do appear to positively impact early postoperative patient quality of life³¹. Based on the international literature³⁵⁻⁴⁰ and personal experience^{18,31,41,42}, the authors recommend following what is reported in Figures 6, 7 and 8. A further aspect that plays a fundamental role in patients reconstructed and rehabilitated with supported implant prostheses is the management of peri-implant soft tissue. The reconstructed soft tissue lacks the physiological properties and function of native mucosa. In reconstructions where an intraoral skin component is present, after implant-prosthesis restoration, excessive soft-tissue bulk, movement, chronic inflammation and hypertrophy are readily observed around implants and risk compromising the long-term success of the implant. Various clinical reports suggest different approaches, with contradictory results. A detailed soft-tissue analysis in these patients is essential. It is clear that normal attached gingiva and alveolar mucosa differ from soft tissue reconstructed with skin and muscle³⁶. It is very important that these cases are treated and managed by specifically trained implantologists (Fig. 9).

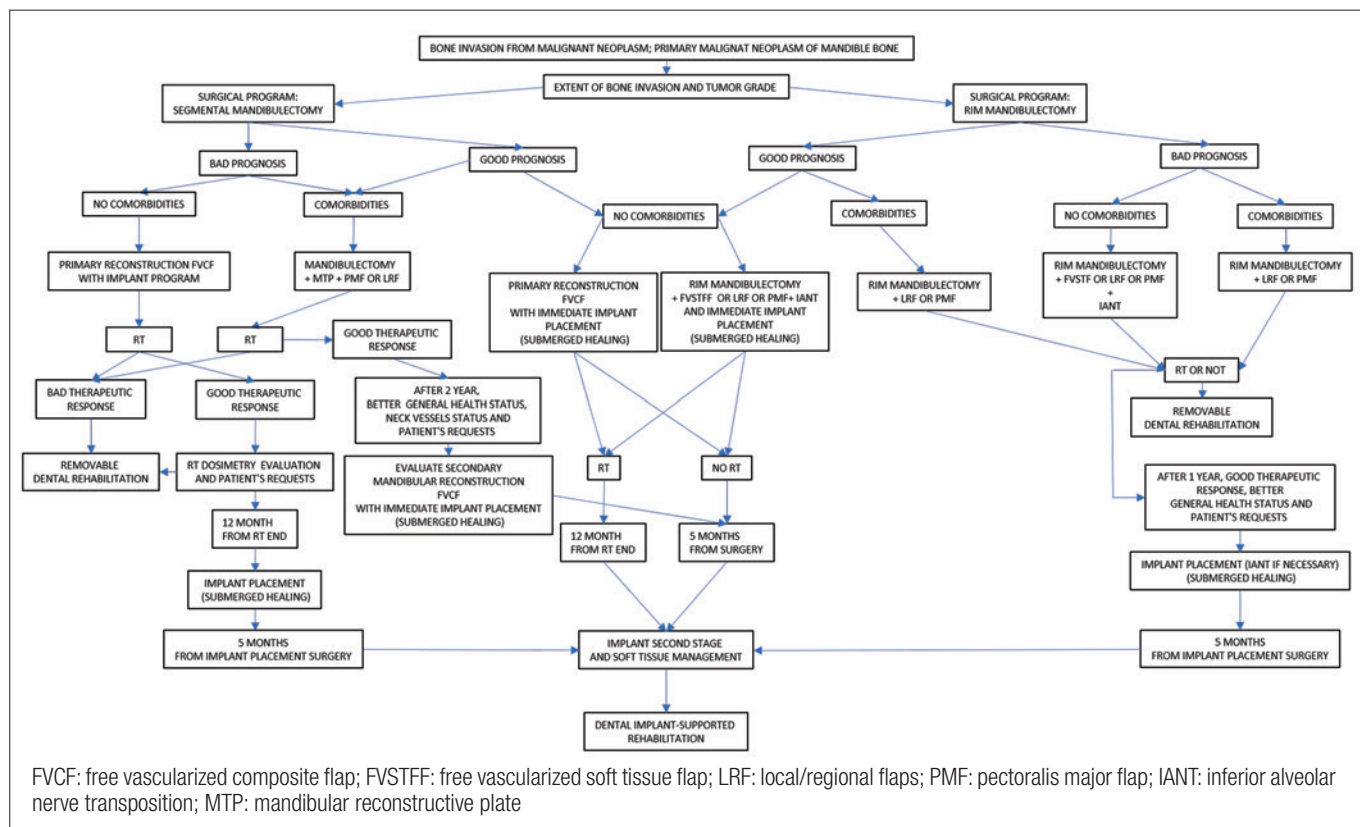


Figure 6. Mandible malignant neoplasms with bone involvement: reconstructive and dental rehabilitative program.

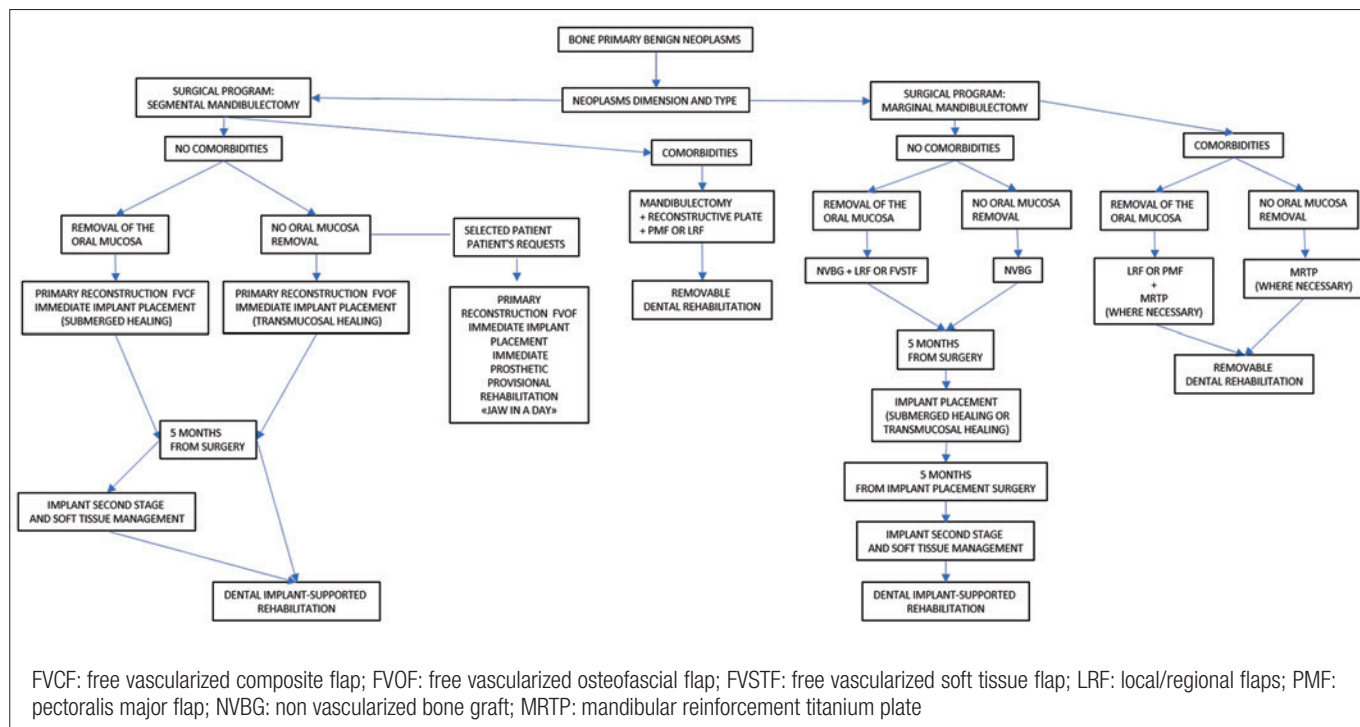
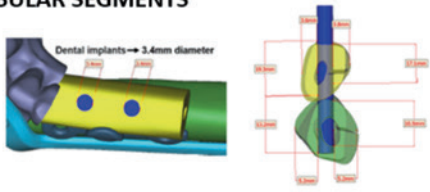


Figure 7. Mandible benign neoplasms with bone involvement: reconstructive and dental rehabilitative program.

Always perform implant virtual planning during computer-assisted mandibular reconstruction regardless of their effective placement during surgery: **IMPLANTS AFFECT POSITIONING OF THE FIBULAR SEGMENTS**

GENERAL CONCEPTS FOR FIBULA SEGMENTS POSITIONING:

- NUMBER OF FIBULA SEGMENTS
- FIBULA SEGMENTS LENGTH > 2,5 cm
- CONCEPT OF TWO ARCHES
- OCCLUSAL GUIDED POSITIONING
- MAINTAIN 15 MM OF OCCLUSAL SPACE



GENERAL CONCEPTS FOR IMPLANT VIRTUAL PLANNING AND POSITIONING:

- NUMBER OF IMPLANTS: INTER-IMPLANTS DISTANCE > 3 mm ; IMPLANT DISTANCE FROM OSTEOTOMY > 4 mm
- TYPE OF DENTAL IMPLANT:
- IMPLANTS DIAMETER: BONE SURROUNDING IMPLANT > 1mm; THE IMPLANTS MUST NOT OBLITERATE THE HOLLOW PART OF THE FIBULA
- IMPLANT INCLINATION
- IMPLANTS PLACED UNDER THE BONE CREST OF 1,2 MM (When the implants are placed during reconstructive surgery)
- DENTAL IMPLANTS DISTANCE FROM SCREW AND PLATES

Figure 8. General concepts for fibula segments and dental implants planning and positioning.

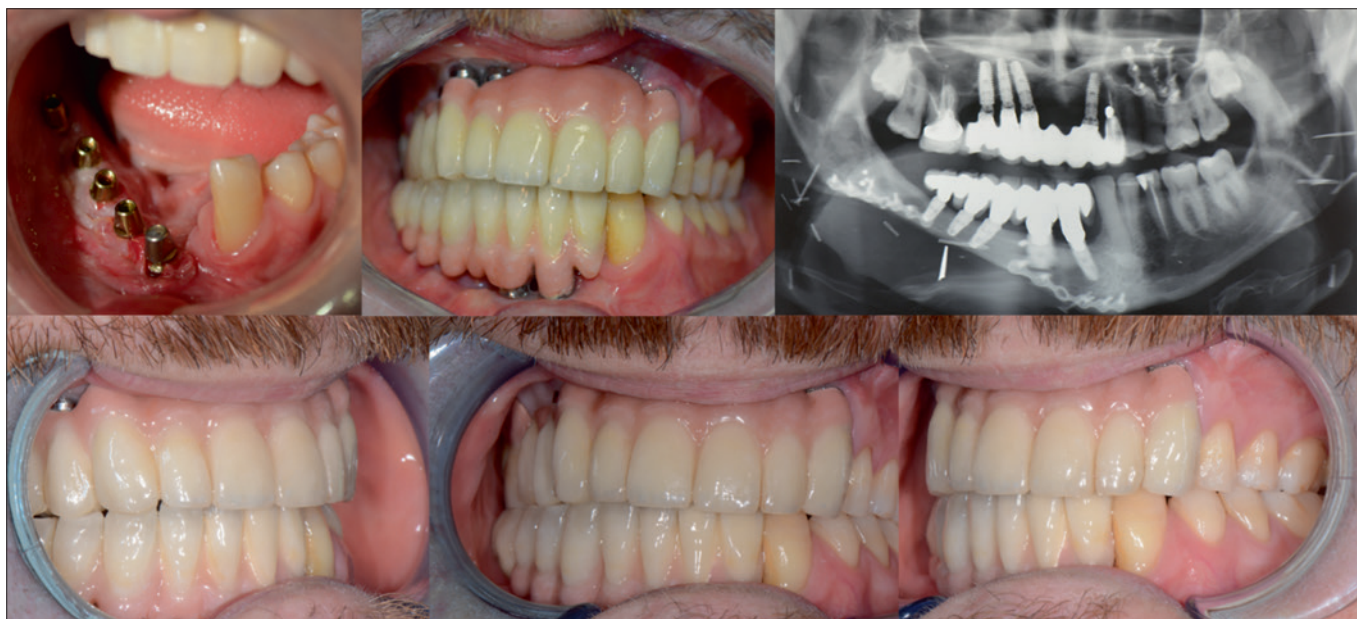

Figure 9. Prosthetic implant supported rehabilitation after mandibular reconstruction with fibula free flap.

On the basis of the above considerations, the importance of a multidisciplinary approach is clear. To date, not all of the Italian national health care system offers oral rehabilitation after Head & Neck cancer treatment: the Italian health system does not consider the functional and esthetic rehabilitation of patients who have undergone impairments to the stomatognathic system due to radical surgery for tumor removal since prosthetic and implant rehabilitation is subject to prohibitively high costs. Moreover, it is necessary to train specific staff so that they have a complete knowledge of both the oncologic problems and the most suitable rehabilitation techniques for these patients (Fig. 10).

Management of radiotherapy complications and oral health supportive care

Radiotherapy (RT) now plays a fundamental role in the treatment of HNCs, and nearly 75% of all these patients undergo this therapy with curative, adjuvant, or palliative intent⁴³. Unfortunately, RT, especially when combined with chemotherapy, may cause acute and/or late onset side effects on oral and maxillofacial tissue, and in particular, osteoradionecrosis (ORN), oral mucositis, hyposalivation, and dental caries⁴⁴. The development of more accurate RT techniques (e.g. intensity-modulated radiation therapy

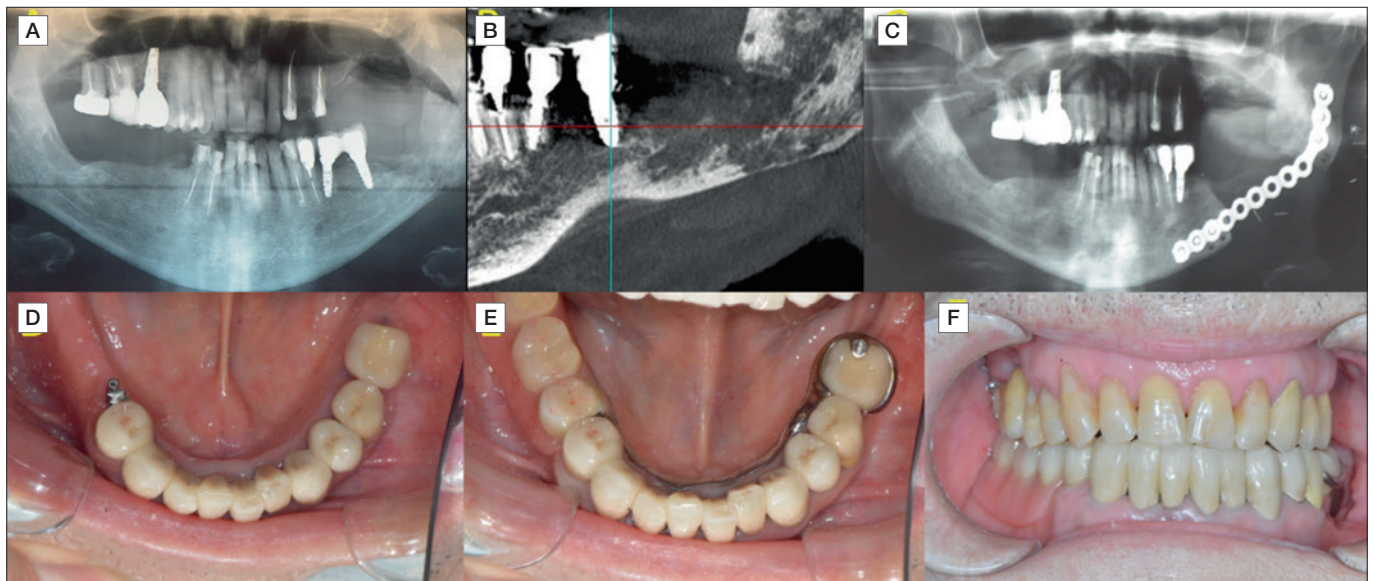


Figure 10. ORN of the left jaw (A); dental implant involvement in the ORN (B); orthopantomography after 3 months from surgery (left mandibulectomy, reconstructive plate with pectoralis major flap (C); conventional prosthetic dental rehabilitation (D-F).

(IMRT) has decreased the number of side effects in the oromaxillofacial district⁴⁵; nevertheless, ORN remains the most important event which can sometimes impair a patient's quality of life.: it can occur in 2 to 22% of irradiated patients.

Osteoradionecrosis can be defined as irradiated exposed necrotic bone which has not healed over a 3-month period, in the absence of cancer recurrence⁴⁶. Since teeth extractions are risk factors for ORN development⁴⁷, a thorough dental examination and removal of oral foci are generally recommended before starting RT to minimize the risk of ORN. The removal of oral foci before RT, taking advantage of the healing capability of unaffected bone and mucosa, seems to reduce ORN onset. No evidence-based guideline exists to help the clinician in the decision-making process, but some indications, mainly based on expert opinion, may be highlighted: impacted third molars with radiographic signs of pericoronitis, teeth with periapical lesions, unrestorable teeth, and teeth affected by periodontitis (Pocket Probing Depth (PPD) ≥ 5 mm, Clinical Attachment Loss (CAL) ≥ 8 mm, Grade 2 Tooth Mobility or worse, Grade 2 Furcation Involvement (FI) or worse) should be extracted. Every tooth extraction should be performed with antibiotic and antiseptic prophylaxis in order to prevent any possible socket infection and protect the reparatory mechanisms of the wound. Furthermore, a minimum interval of 15 days should elapse between the last extraction and the beginning of RT. In the case of ORN onset, its treatment can be non-surgical (encouraging oral hygiene improvement, prescrib-

ing local or systemic antibiotics, hyperbaric oxygen (HBO) therapy)⁴⁸ or surgical (debridement of necrotic bone, sequestrectomy, mandibular excision)⁴⁹.

Oral mucositis (OM) is an acute response to treatment that affects most patients receiving RT or chemotherapy for HNC. In patients receiving a typical 6- to 7-week course of RT, OM presents as erythema of the oral mucosa in the first 2-3 weeks of RT and progresses to ulceration and pseudomembranes as the dose of radiation increases⁵⁰. The general long-term prognosis is reasonably good since most lesions resolve within 2-4 weeks after stopping RT or chemotherapy. Although OM is considered to be a self-limited injury in some patients, it could be a lethal injury in moderately to severely ill patients, which could lead to obligatory cessation of RT. Since an established treatment does not exist, OM prevention can be crucial. Benzylamine mouthwash can be used to prevent OM in patients with HNC receiving moderate dose radiation therapy (up to 50 Gy), without concomitant chemotherapy⁵¹. Although many studies had stated that sucralfate has no significant advantage for preventing OM in patients receiving chemoradiotherapy, a recent systematic review found that cancer patients treated with sucralfate mouthwash before receiving chemotherapy had a significantly reduced incidence of severe OM compared with controls⁵².

Xerostomia and hyposalivation remain a significant burden for many individuals treated with RT. Several treatment strategies have been proposed for the management of xerostomia and they all aim to reduce patients' symptoms

and/or increase salivary flow. Easy remedies are proper hydration, an increase in humidity at night-time, avoidance of irritating toothpaste and crunchy/hard foods, and the use of sugar-free chewing gums/candies. Medications include mucosal lubricants, saliva substitutes, and saliva stimulants. Hyposalivation and oral flora impairment are often the cause of a high predisposition to dental caries. Prevention of dental caries should be directed at the treatment of xerostomia-related complaints, oral hygiene, change of diet, control of cariogenic flora, and the use of frequent fluoride applications. With a daily topical 1.0% sodium fluoride gel application by custom-made fluoride carriers, caries occurrence can be greatly reduced. Due to the previously mentioned hyposalivation-related problems, fluoridation has to be continued on a lifelong basis (if hyposalivation persists), and high concentrations in toothpaste (5000 ppm fluoride) obviously fulfill the oral hygiene needs of these patients.

Tooth extractions performed after RT have been identified as the main risk factor for the development of ORN; for this reason, dentists should prevent dental diseases to minimize the number of extractions after RT⁵³. Unfortunately, irradiated patients have a higher risk of developing dental caries and periodontal disease, which can give rise to oral foci and these are the main reason for tooth extraction in the general population. To prevent ORN and ensure that Head & Neck cancer patients have a higher quality of life, it is crucial to instigate a strict follow-up protocol, with a minimum frequency of every 6 months with continuous assessment of periodontal conditions and accurate caries detection.

The diagnostic procedure usually includes an assessment of the following:

- oral hygiene and plaque index;
- determination of sites with periodontal inflammation (bleeding on probing (BoP) or infection (suppuration); assessment of clinical probing depths);
- evaluation of existing reconstructions and vitality checks on teeth;
- examination for carious lesions. This is crucial in irradiated patients, due to their high risk of developing caries; early detection allows the clinician to easily restore a tooth, preventing the risk of developing oral foci.

This phase is followed by the scaling and root planning of periodontal sites, by assessing the motivation of the patient with regard to his oral hygiene, and a re-instruction on oral hygiene procedures.

Supportive care for oral health should include the measurement of salivary flow, since, when the salivary glands are within the irradiated field, irreversible damage to the salivary glands occurs in 63-93% of patients.

Conclusions

Head and Neck cancer treatment is intrinsically complex, and at the present time, it is necessary to create and make available measures capable of dealing with the disease in a multidisciplinary⁵⁴ way and with multimodality treatments. It is important to emphasize that it takes years of strict collaboration between ENT and dentists to reach a good working relationship, and garner sufficient experience and familiarity with oncological therapies. This also becomes possible through the organization of interdisciplinary training courses which, in addition to training new operators, allow continuous comparison and updating between the teachers themselves.

References

- 1 Muller S. Update from the 4th Edition of the World Health Organization of Head and Neck Tumours: tumours of the oral cavity and mobile tongue. *Head Neck Pathol* 2017;11:33-40. <https://doi.org/10.1007/s12105-017-0792-3>
- 2 Chung CS, Lo WC, Wen MH, et al. Long term outcome of routine image-enhanced endoscopy in newly diagnosed head and neck cancer: a prospective study of 145 patients. *Sci Rep* 2016;6:29573. <https://doi.org/10.1038/srep29573>
- 3 Iocca O, Sollecito TP, Alawi F, et al. Potentially malignant disorders of the oral cavity and oral dysplasia: a systematic review and meta-analysis of malignant transformation rate by subtype. *Head Neck* 2020;42:539-555. <https://doi.org/10.1002/hed.26006>
- 4 Awadallah M, Idle M, Patel K, et al. Management update of potentially premalignant oral epithelial lesions. *Oral Surg Oral Med Oral Pathol Oral Radiol* 2018;125:628-636. <https://doi.org/10.1016/j.oooo.2018.03.0105>
- 5 Giuliani M, Troiano G, Cordaro M, et al. Rate of malignant transformation of oral lichen planus: A systematic review. *Oral Dis* 2019;25:693-709. <https://doi.org/10.1111/odi.12885>
- 6 Cheng YS, Gould A, Kurago Z, et al. Diagnosis of oral lichen planus: a position paper of the American Academy of Oral and Maxillofacial Pathology. *Oral Surg Oral Med Oral Pathol Oral Radiol* 2016;122:332-354. <https://doi.org/10.1016/j.oooo.2016.05.004>
- 7 Hazarey VK, Sakrikar AR, Ganvir SM. Efficacy of curcumin in the treatment for oral submucous fibrosis – A randomized clinical trial. *J Oral Maxillofac Pathol* 2015;19:145-152. <https://doi.org/10.4103/0973-029X.164524>
- 8 Warnakulasuriya S, Kerr AR. Oral submucous fibrosis: a review of the current management and possible directions for novel therapies. *Oral Surg Oral Med Oral Pathol Oral Radiol* 2016;122:232-241. <https://doi.org/10.1016/j.oooo.2016.02.020>
- 9 Rao NR, Villa A, More CB, et al. Oral submucous fibrosis: a contemporary narrative review with a proposed inter-professional approach for an early diagnosis and clinical management. *J Otolaryngol Head Neck Surg* 2020;49:3. <https://doi.org/10.1186/s40463-020-0399-7>
- 10 Kamath VV. Surgical interventions in oral submucous fibrosis: a systematic analysis of the literature. *J Maxillofac Oral Surg* 2015;14:521-531. <https://doi.org/10.1007/s12663-014-0639-3>
- 11 Masthan KM, Sankari SL, Babu NA, et al. How to help the oral pathologist in making an accurate diagnosis. *J Clin Diagn Res* 2013;7:181-184. <https://doi.org/10.7860/JCDR/2012/4967.2703>

- 12 Bai XX, Zhang J, Wei L. Analysis of primary oral and oropharyngeal squamous cell carcinoma in inhabitants of Beijing, China—a 10-year continuous single-center study. *BMC Oral Health* 2020;20:208. <https://doi.org/10.1186/s12903-020-01192-6>
- 13 Avon SL, Klieb HB. Oral soft-tissue biopsy: an overview. *J Can Dent Assoc* 2012;78:c75.
- 14 Valdec S, Schiefersteiner M, Rucker M, et al. Guided biopsy of osseous pathologies in the jaw bone using a 3D-printed, tooth-supported drilling template. *Int J Oral Maxillofac Surg* 2019;48:1028-1031. <https://doi.org/10.1016/j.ijom.2019.04.007>
- 15 Fadda GL, Berrone M, Crosetti E, et al. Monolateral sinonasal complications of dental disease or treatment: when does endoscopic endonasal surgery require an intraoral approach? *Acta Otorhinolaryngol Ital* 2016;36:300-309. <https://doi.org/10.14639/0392-100X-904>
- 16 Exner GU, Kurrer MO, Mamisch-Saupe N, et al. The tactics and technique of musculoskeletal biopsy. *EFORT Open Rev* 2017;2:51-57. <https://doi.org/10.1302/2058-5241.2.160065>
- 17 Jackson LK, Epstein JB, Migliorati CA, et al. Development of tools for the oral health and panoramic radiograph evaluation of head and neck cancer patients: a methodological study. *Spec Care Dentist* 2015;35:243-252. <https://doi.org/10.1111/scd.12125>
- 18 Succo G, Berrone M, Battiston B, et al. Step-by-step surgical technique for mandibular reconstruction with fibular free flap: application of digital technology in virtual surgical planning. *Eur Arch Otorhinolaryngol* 2015;272:1491-1501. <https://doi.org/10.1007/s00405-014-3078-3>
- 19 Molteni G, Valerini S, Alicandri-Ciuffelli M, et al. Unravelling the risk factors that underlie oral and oropharyngeal surgery in elderly. *Acta Otorhinolaryngol Ital* 2018;38:409-416. <https://doi.org/10.14639/0392-100X-1507>
- 20 Genden EM. Reconstruction of the mandible and the maxilla: the evolution of surgical technique. *Arch Facial Plast Surg* 2010;12:87-90. <https://doi.org/10.1001/archfacial.2010.18>
- 21 Crosetti E, Caracciolo A, Arrigoni G, et al. Barbed suture in oral cavity reconstruction: preliminary results. *Acta Otorhinolaryngol Ital* 2019;39:308-315. <https://doi.org/10.14639/0392-100X-2130>
- 22 Bidra AS, Jacob RF, Taylor TD. Classification of maxillectomy defects: a systematic review and criteria necessary for a universal description. *J Prosthetic Dentistry* 2012;107:261-270. [https://doi.org/10.1016/S0022-3913\(12\)60071-7](https://doi.org/10.1016/S0022-3913(12)60071-7)
- 23 Ruggiero G, Bocca N, Magrini G, et al. Surgical procedures performed to improve the prosthetic prognosis in case of maxillary defects: a review of the literature. *J Osseointegr* 2019;11:519-524. <https://doi.org/10.23805/JO.2019.11.03.09>
- 24 Okay DJ, Buchbinder D, Urken M, et al. Computer-assisted implant rehabilitation of maxillomandibular defects reconstructed with vascularized bone free flaps. *JAMA Otolaryngol Head Neck Surg* 2013;139:371-381. <https://doi.org/10.1001/jamaoto.2013.83>
- 25 Melville JC, Manis CS, Shum JW, et al. Single-unit 3D-printed titanium reconstruction plate for maxillary reconstruction: the evolution of surgical reconstruction for maxillary defects—a case report and review of current techniques. *J Oral Maxillofac Surg* 2019;77:874.e1-874.e13. <https://doi.org/10.1016/j.joms.2018.11.030>
- 26 Piazza C, Grammatica A, Montalto N, et al. Compartmental surgery for oral tongue and floor of the mouth cancer: oncologic outcomes. *Head Neck* 2019;41:110-115. <https://doi.org/10.1002/hed.25480>
- 27 Grammatica A, Piazza C, Montalto N, et al. Compartmental surgery for oral tongue cancer: objective and subjective functional evaluation. *Laryngoscope* 2021;131:e176-e183. <https://doi.org/10.1002/lary.28627>
- 28 Calabrese L, Giugliano G, Bruschini R, et al. Compartmental surgery in tongue tumours: description of a new surgical technique. *Acta Otorhinolaryngol Ital* 2009:259-264.
- 29 Chen YS, Hu KY, Lin TW. The concept of “two arches” in mandibular reconstruction. *Ann Plast Surg* 2012;69:616-621. <https://doi.org/10.1097/SAP.0b013e318273f92a>
- 30 Haddock NT, Monaco C, Weimer KA, et al. Increasing bony contact and overlap with computer-designed offset cuts in free fibula mandible reconstruction. *J Craniofac Surg* 2012;23:1592-1595. <https://doi.org/10.1097/SCS.0b013e318257576c>
- 31 Berrone M, Crosetti E, Battiston B, et al. Virtual surgical planning for mandible reconstruction with a double barrel fibula flap and immediate implant placement. *J Craniofac Surg* 2020;31:e41-e43. <https://doi.org/10.1097/SCS.0000000000005842>
- 32 Jacobsen C, Kruse A, Lübbers HT, et al. Is mandibular reconstruction using vascularized fibula flaps and dental implants a reasonable treatment? *Clin Implant Dent Relat Res* 2014;16:419-428. <https://doi.org/10.1111/cid.12004>
- 33 Schiegnitz E, Al-Nawas B, Kämmerer PW, et al. Oral rehabilitation with dental implants in irradiated patients: a meta-analysis on implant survival. *Clin Oral Investig* 2014;18:687-698. <https://doi.org/10.1007/s00784-013-1134-9>
- 34 Panchal H, Shamsunder MG, Petrovic I, et al. Dental implant survival in vascularized bone flaps: a systematic review and meta-analysis. *Plast Reconstr Surg* 2020;146:637-648. <https://doi.org/10.1097/PRS.0000000000007077>
- 35 Sandoval ML, Rosen EB, Robert AJ, et al. Immediate dental implants in fibula free flaps to reconstruct the mandible: a pilot study of the short-term effects on radiotherapy for patients with head and neck cancer. *Clin Implant Dent Relat Res* 2020;22:91-95. <https://doi.org/10.1111/cid.12870>
- 36 Zhang L, Ding Q, Liu C, et al. Survival, function, and complications of oral implants placed in bone flaps in jaw rehabilitation: a systematic review. *Int J Prosthodont* 2016;29:115-125. <https://doi.org/10.11607/ijp.4402>
- 37 Bolzoni A, Mapelli A, Baj A, et al. Evaluation of three-dimensional mandibular movements after reconstruction with free fibula flap. *Acta Otorhinolaryngol Ital* 2015;35:371-378. <https://doi.org/10.14639/0392-100X-504>
- 38 Saponaro G, Gasparini G, Cervelli D, et al. Osteoperiosteal free fibula flap as an effective preprosthetic reconstructive option in severe jaw atrophy and oncological resection. *Acta Otorhinolaryngol Ital* 2015;35:394-399. <https://doi.org/10.14639/0392-100X-763>
- 39 Colletti G, Autelitano L, Rabbiosi D, et al. Technical refinements in mandibular reconstruction with free fibula flaps: outcome-oriented retrospective review of 99 cases. *Acta Otorhinolaryngol Ital* 2014;34:342-348.
- 40 Qaisi M, Murphy J, Fung H. Principles of fibula jaw in a day reconstruction: a step-by-step approach. In: Melville J, Shum J, Young S, et al., editors. *Regenerative strategies for maxillary and mandibular reconstruction*. Cham (CH): Springer; 2019. pp. 211-233. https://doi.org/10.1007/978-3-319-93668-0_16
- 41 Berrone M, Crosetti E, Tos PL, et al. Fibular osteofasciocutaneous flap in computer-assisted mandibular reconstruction: technical aspects in oral malignancies. *Acta Otorhinolaryngol Ital* 2016;36:469-478. <https://doi.org/10.14639/0392-100X-1282>
- 42 Berrone M, Crosetti E, Succo G. Repositioning template for mandibular reconstruction with fibular free flaps: an alternative technique to pre-plating and virtual surgical planning. *Acta Otorhinolaryngol Ital* 2014;34:278-282.
- 43 Ratko TA, Douglas GW, de Souza JA, et al. Radiotherapy treatments for head and neck cancer update. Rockville (MD): Agency for Healthcare Research and Quality, 2014.

- ⁴⁴ Dong Y, Ridge JA, Li T, et al. Long-term toxicities in 10-year survivors of radiation treatment for head and neck cancer. *Oral Oncol* 2017;71:122-128. <https://doi.org/10.1016/j.oraloncology.2017.05.009>
- ⁴⁵ Gomez-Millan J, Fernández JR, Medina Carmona JA. Current status of IMRT in head and neck cancer. *Rep Pract Oncol Radiother* 2013;18:371-375. <https://doi.org/10.1016/j.rpor.2013.09.008>
- ⁴⁶ Chronopoulos A, Zarra T, Ehrenfeld M, et al. Osteoradionecrosis of the jaws: definition, epidemiology, staging and clinical and radiological findings. A concise review. *Int Dent J* 2018;68:22-30. <https://doi.org/10.1111/idj.12318>
- ⁴⁷ Lajolo C, Gioco G, Rupe C, et al. Tooth extraction before radiotherapy is a risk factor for developing osteoradionecrosis of the jaws: a systematic review. *Oral Dis* 2020 Jun 12. <https://doi.org/10.1111/odi.13485>. Online ahead of print.
- ⁴⁸ Raggio BS, Winters R. Modern management of osteoradionecrosis. *Curr Opin Otolaryngol Head Neck Surg* 2018;26:254-259. <https://doi.org/10.1097/MOO.0000000000000459>
- ⁴⁹ Bettoni J, Olivetto M, Duisit J, et al. Treatment of mandibular osteoradionecrosis by periosteal free flaps. *Br J Oral Maxillofac Surg* 2019;57:550-556. <https://doi.org/10.1016/j.bjoms.2019.01.028>
- ⁵⁰ Sroussi HY, Epstein JB, Bensadoun RJ, et al. Common oral complications of head and neck cancer radiation therapy: mucositis, infections, saliva change, fibrosis, sensory dysfunctions, dental caries, periodontal disease, and osteoradionecrosis. *Cancer Med* 2017;6:2918-2931. <https://doi.org/10.1002/cam4.1221>
- ⁵¹ Lalla RV, Bowen J, Barasch A, et al. MASCC/ISOO clinical practice guidelines for the management of mucositis secondary to cancer therapy. *Cancer* 2014;120:1453-1461. <https://doi.org/10.1002/cncr.28592>
- ⁵² Wilairat P, Kengkla K, Kaewpanan T, et al. Comparative efficacy and safety of interventions for preventing chemotherapy-induced oral mucositis in adult cancer patients: a systematic review and network meta-analysis. *Eur J Hosp Pharm* 2020;27:103-110. <https://doi.org/10.1136/ejhp-2018-001649>
- ⁵³ Castagnola R, Miniciacchi I, Rupe C, et al. The outcome of primary root canal treatment in postirradiated patients: a case series. *J Endod* 2020;46:551-556. <https://doi.org/10.1016/j.joen.2019.12.005>
- ⁵⁴ Bergamini C, Locati L, Bossi P, et al. Does a multidisciplinary team approach in a tertiary referral centre impact on the initial management of head and neck cancer? *Oral Oncol* 2016;54:54-57. <https://doi.org/10.1016/j.oraloncology.2016.01.001>