

## Use of standing low-field magnetic resonance imaging to assess oblique distal sesamoidean ligament desmitis in three Thoroughbred racehorses

Fumiaki MIZOBE<sup>1)\*</sup>, Jun OKADA<sup>1)</sup>, Yuta SHINZAKI<sup>1)</sup>, Motoi NOMURA<sup>1)</sup>, Tomohiro KATO<sup>1)</sup>, Kazutaka YAMADA<sup>2)</sup> and Mathieu SPRIET<sup>3)</sup>

<sup>1)</sup>Racehorse Hospital, Ritto Training Center, Japan Racing Association, 1028, Misono, Ritto, Shiga 520–3085, Japan

<sup>2)</sup>Obihiro University of Agriculture and Veterinary Medicine, 2–11, Inada-cho, Obihiro, Hokkaido 080–8555, Japan

<sup>3)</sup>Department of Surgical and Radiological Sciences, School of Veterinary Medicine, University of California Davis, One Garrod Drive, Davis, California 95616, U.S.A.

(Received 17 November 2015/Accepted 27 May 2016/Published online in J-STAGE 16 June 2016)

**ABSTRACT.** Desmitis of the oblique distal sesamoidean ligaments (ODSL) is caused by hyperextension of the metacarpophalangeal/metatarsophalangeal joint and has been described as a significant cause of lameness in racehorses. In this study, three Thoroughbred racehorses (age range: 3–6 years) were diagnosed with desmitis of the forelimb ODSL using standing low-field magnetic resonance imaging (sMRI). Radiography and ultrasonography were inconclusive with regard to a definitive diagnosis. For all horses, the sMRI characteristics included increased signal intensity within the medial ODSL on T1-weighted gradient echo, T2-weighted fast spin echo and short tau inversion recovery fast spin echo images, which use a fat suppression technique. Effusion of the digital flexor tendon sheath was also clearly visible on sMRI. Following rest and controlled exercise for roughly 3 months, two horses successfully returned to racing within 5 months. Our findings support the use of sMRI for diagnosing ODSL injuries in Thoroughbred racehorses.

**KEY WORDS:** desmitis, magnetic resonance imaging, oblique distal sesamoidean ligament, racehorse

doi: 10.1292/jvms.15-0656; *J. Vet. Med. Sci.* 78(9): 1475–1480, 2016

Overextension of the metacarpophalangeal/metatarsophalangeal (MCP/MTP) joint during high speed exercise is known to pose a risk of musculoskeletal injury in racehorses [1]. Different components of the MCP/MTP joint, such as the third metacarpal/metatarsal bones, first phalangeal bones and surrounding ligaments and tendons, are prone to damage. The straight, paired oblique, paired cruciate and paired short distal sesamoidean ligaments act as part of the suspensory apparatus and provide resistance to fetlock extension [7]. These distal sesamoidean ligaments (DSLs) connect the proximal sesamoid bones to the proximal and middle phalanges. All DSLs attach proximally to the base of the proximal sesamoid bones and the intersesamoidean ligament. The paired cruciate and paired short sesamoidean ligaments insert on the proximal phalanx. The paired oblique distal sesamoidean ligaments (ODSL) form a V-shape as they travel distally and axially to become a single band where they attach to a roughened area on the palmar/plantar aspect of the distal third of the proximal phalanx [3]. The pair of ODSL is important in limiting the rotation and abaxial movements of the MCP/MTP joint. The straight distal sesamoidean ligament (SDSL) inserts via the scutum medium on the proximal and palmar/plantar aspects of the middle phalanx [3, 4]. SDSL stabilizes MCP/MTP and proximal interphalangeal joints in a sagittal

direction.

Injuries to the suspensory apparatus including DSL have been recognized as a cause of lameness in horses [6, 7, 16, 18]. It is not usually possible to distinguish individual ligaments by palpation, because these ligaments are situated deep in relation to the superficial and deep digital flexor tendons. Furthermore, in cases of severe injury, marked swelling often persists over the pastern, thus rendering a definitive diagnosis by palpation even more difficult. Radiography can help rule out other causes of lameness [12], although a definitive diagnosis requires other imaging modalities, such as ultrasonography and magnetic resonance imaging (MRI). Injuries of DSLs have been documented using ultrasonography [15, 17]. However, it is not always easy to maintain good surface contact with the ultrasound probe when passing over the palmar surface of the pastern, and thus, it is difficult to obtain a clear sonographic image of the distal part of DSL [16]. In addition, experience is required for a thorough evaluation of DSLs using ultrasonography [6, 19].

MRI was first introduced to equine practice in 1997 and has since been utilized for the specific diagnosis of bone and soft tissue injuries of the distal limb in horses [2, 5, 8, 10, 14, 24]. Sampson described a series of 27 horses diagnosed with desmitis of DSLs using MRI with a 1.0-Tesla high-strength magnetic field [20]. High-field MRI is reported to be superior to ultrasonography for detecting pathologic changes in ligaments, because it yields high resolution and high quality images under general anesthesia [20, 21]. On the other hand, standing low-field MRI (sMRI) allows the cost-saving process of scanning under sedation, which poses a lower risk of accident during the examination. sMRI was first introduced in 2005 [9]. To date, limited information

\*CORRESPONDENCE TO: MIZOBE F., Racehorse Hospital, Ritto Training Center, Japan Racing Association, 1028, Misono, Ritto, Shiga, 520–3085, Japan. e-mail: Fumiaki\_Mizobe@jra.go.jp

©2016 The Japanese Society of Veterinary Science

This is an open-access article distributed under the terms of the Creative Commons Attribution Non-Commercial No Derivatives (by-nc-nd) License <<http://creativecommons.org/licenses/by-nc-nd/4.0/>>.

is available on the use of sMRI to assess DSL injuries in racehorses. This study aimed to describe the clinical appearance of desmitis of ODSL as diagnosed by sMRI in three Thoroughbred racehorses.

## MATERIALS AND METHODS

**Case selection:** All horses that were presented to the Racehorse Hospital, Ritto Training Center for lameness evaluation in 2014 and diagnosed with MRI abnormalities of one of the ODSLs were included in this study.

**Radiography and ultrasonography:** Radiographs were taken using a computed digital radiography system (FCR Speedia CS, Fujifilm, Tokyo, Japan). In all cases, radiographic projections included standing lateromedial and dorsopalmar views of the MCP joint, and dorsolateral palmaromedial 45° oblique and dorsomedial palmarolateral 45° oblique views of the MCP joint. Ultrasonographic evaluation of the palmar pastern region was performed using an ultrasound system (HI VISION Avius, Hitachi, Tokyo, Japan) with a 14–6 MHz linear probe.

**Standing MRI:** A 0.27-Tesla dedicated equine MRI system (Equine Limb Scanner, Hallmarq Veterinary Imaging, Ltd., Guilford, U.K.) was used to obtain MRI images of the pastern regions. T1-weighted gradient echo (GRE) [echo time (TE): 8 msec/repetition time (TR): 50 msec, flip angle 55°], T2-weighted fast spin echo (FSE) (TE: 88 msec/TR: 1681 msec) and short tau inversion recovery (STIR) FSE [TE: 22 msec/TR: 2,460 msec, inversion time (TI)=110 msec] were acquired in the frontal, transverse and sagittal planes. MRI images were acquired and reviewed by several clinicians experienced in the interpretation of sMRI images of Thoroughbred racehorses, using the Digital Imaging and Communications in Medicine (DICOM) viewer OsiriX, version 3.9.2 (OsiriX Project, Geneva, Switzerland).

In all horses, sMRI was performed under sedation. Medetomidine (Domitor, Meiji Seika Co., Tokyo, Japan) was administered at an initial dose of 5 µg/kg prior to the onset of positioning within the magnet. Thereafter, small doses of medetomidine (0.2 µg/kg) were administered periodically to maintain sufficient tranquilization for the scan.

Follow-up was conducted through interviews of the trainers or evaluation of the horses upon return to the Ritto Training Center.

## RESULTS

### Case 1

A 5-year-old Thoroughbred mare exhibited acute-onset left foreleg lameness following a race on a flat turf course. A 3-day course of oral diclofenac sodium (1 mg/kg; Blesin Tablets, Sawai Pharmaceutical Co., Ltd, Osaka, Japan), leg cooling and boxed rest did not improve the heat and pain in the pastern. On day 4, the mare was admitted to the hospital. Radiography revealed new periosteal bone formation at the mid-palmaromedial surface of the proximal phalanx (Fig. 1). A marked increase in fluid and small amount of fibrin in the digital flexor tendon sheath (DFTS) were observed via ultra-

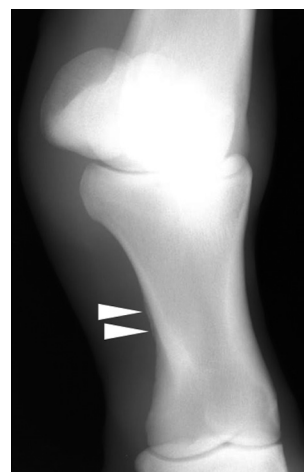


Fig. 1. Dorsomedial palmarolateral 45° oblique radiographic image of the metacarpophalangeal joint of case 1. Periosteal osteoproliferation is visible at the mid-palmaromedial surface of the proximal phalanx (arrowheads).

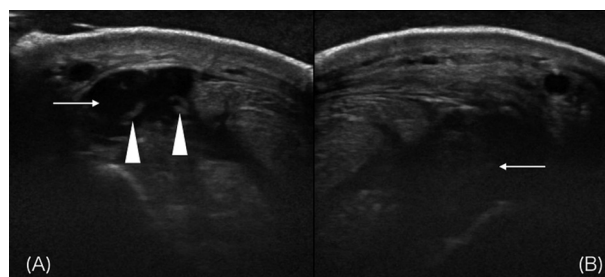


Fig. 2. (A) Transverse ultrasonographic image of case 1, obtained in a lateral oblique position over the proximal pastern region. The palmar is at the top, and the lateral direction is at left. Marked increases in fluid (arrow) and fibrin (arrowheads) are visible in the digital flexor tendon sheath. (B) Transverse ultrasonographic image of case 1, obtained in a medial oblique position over the proximal pastern region. Note the hypoechoic changes in the medial oblique distal sesamoidean ligament.

sonography (Fig. 2). In addition, the medial ODSL appeared to be hypoechoic. To obtain a further diagnosis, sMRI was performed on day 6. sMRI images revealed high signal intensity in the enlarged medial ODSL on T1-weighted GRE, T2-weighted FSE and STIR FSE images from the proximal pastern to mid-pastern that likely represented desmitis of the medial ODSL (Fig. 4). The enlarged DFTS exhibited a hypointense signal on T1-weighted GRE images, and hyperintense signals on T2-weighted FSE and STIR FSE images (Fig. 4).

Following the sMRI examination, the mare was sent to a farm for rest.

### Case 2

A 3-year-old Thoroughbred filly exhibited right foreleg lameness after exercise. Dexamethasone (CORSON P IN-

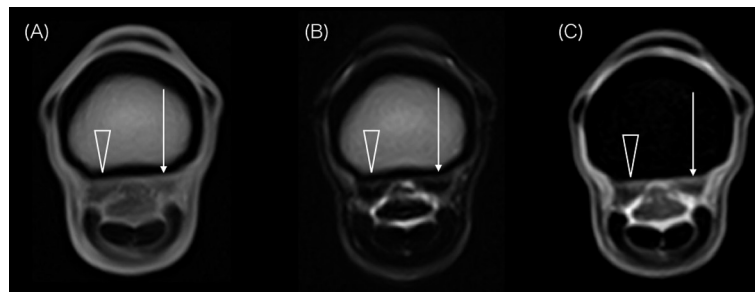


Fig. 3. Transverse T1-weighted gradient echo (A), T2-weighted fast spin echo (FSE) (B) and short tau inversion recovery FSE (C) images of a normal pastern at the level of the proximal third of the proximal phalanx. The dorsal and medial directions are at the top and right, respectively. The medial oblique distal sesamoidean ligament (ODSL) (arrow) and lateral ODSL (open arrowhead) have fairly uniform shapes with low to intermediate signal intensity in all sequences.

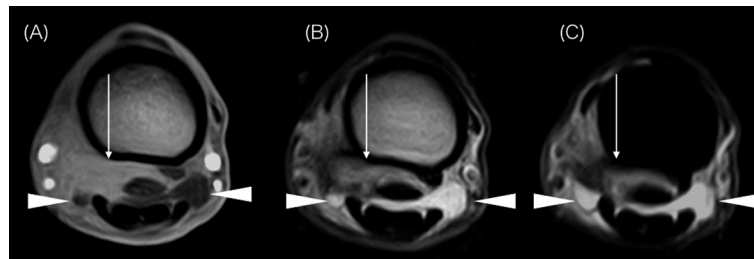


Fig. 4. (A) Transverse T1-weighted gradient echo image acquired at the level of the proximal third of the proximal phalanx in case 1. The dorsal and medial directions are at the top and left, respectively. Enlargement of and increased signal intensity in the medial oblique distal sesamoidean ligament (ODSL) are visible (arrow). An area of low signal intensity is visible in the digital flexor tendon sheath (DFTS; arrowheads). (B) Transverse T2-weighted fast spin echo (FSE) image of the proximal phalanx of case 1, acquired at the same level as above. Abnormally high signal intensity is visible in the medial ODSL (arrow). An increased amount of fluid is present within the DFTS (arrowheads). (C) Transverse short tau inversion recovery FSE image of the proximal phalanx from the case 1, acquired at the same level as above. Increased signal intensity is visible in the medial ODSL (arrow). An increased amount of fluid is present within the DFTS (arrowheads).

JECTION, Nihon Zenyaku Kogyo, Fukushima, Japan) was administered intravenously at a dose of 40  $\mu\text{g}/\text{kg}$  to reduce swelling over the right fore pastern, and the filly was placed on boxed rest for 1 day, followed by 3 days of light exercise. On day 5, the lameness and swelling recurred, and the filly was admitted to the hospital for further diagnosis. A distended DFTS was identified via ultrasonography, and the medial ODSL appeared to be enlarged (Fig. 5). No abnormality was observed on the other DSL or the branches of superficial digital flexor tendon. The lameness gradually improved each day, although the pastern remained swollen. In addition, the marked pain response over the medial pastern did not resolve. On day 6, sMRI was performed for further evaluation. The medial ODSL exhibited increased signal intensity on T1-weighted GRE, T2-weighted FSE and STIR FSE images (Fig. 6). Moreover, a focal hyperintense signal in the lateral ODSL was observed on T1-weighted GRE and T2-weighted FSE images. Effusion of the DFTS was also visible as areas of low signal intensity on T1-weighted GRE images and of high signal intensity on T2-weighted FSE and STIR FSE images.

Based on the above diagnosis, the filly was prescribed 4

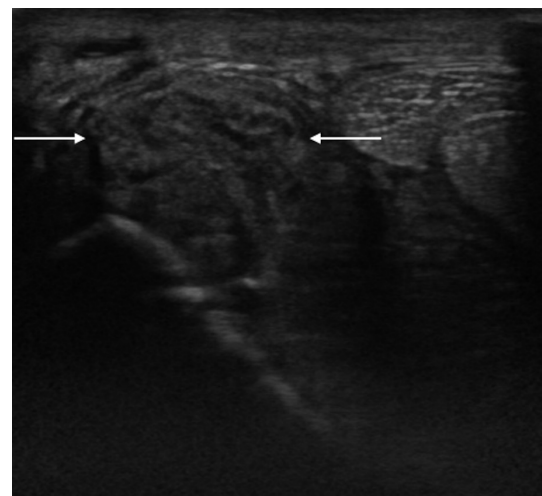


Fig. 5. Transverse ultrasonographic image obtained in the medial oblique direction over the proximal pastern region of case 2. The palmar and medial directions are at the top and left, respectively. Note the enlargement of the medial oblique distal sesamoidean ligament (arrows).

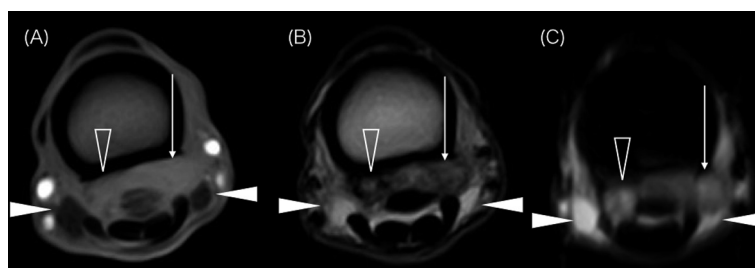


Fig. 6. (A) Transverse T1-weighted gradient echo image of the proximal pastern of case 2. The dorsal and medial directions are at the top and right, respectively. High signal intensity is observed in the medial oblique distal sesamoidean ligament (ODSL; arrow). A discrete area of increased signal intensity is visible within the lateral ODSL (open arrowheads). The distended digital flexor tendon sheath exhibits a hypointense signal (arrowheads). (B) Transverse T2-weighted fast spin echo (FSE) image of the proximal pastern of case 2. Increased signal intensity is visible in the medial ODSL (arrow). The lateral ODSL exhibits focal hyperintensity (open arrowheads). An increased amount of fluid is present within the DFTS (arrowheads). (C) Transverse short tau inversion recovery FSE image of the proximal pastern of case 2. Increased signal intensity is present in the medial ODSL (arrow) and lateral ODSL (open arrowheads). Hyperintense fluid is observed within the DFTS (arrowheads).

months of rest. Following this rest period, the filly resumed exercise and returned to racing 5 months after the injury.

### Case 3

A 6-year-old Thoroughbred colt was referred to the hospital with a sustained increased digital pulse and persistent swelling over the palmar aspect of the pastern on the left forelimb. Although the colt did not exhibit signs of lameness, the increased digital pulse became more remarkable as the training intensity increased. Radiography and ultrasonography were performed to determine the cause of this symptom. However, these examinations did not yield any particular findings. Therefore, sMRI was performed. An area of high signal intensity was observed within the medial ODSL on T1-weighted GRE and T2-weighted FSE images (Fig. 7). Based on these findings, a reduction in training intensity was advised, and eventually, the colt was removed from the Ritto Training Center.

The colt resumed training at the Ritto Training Center approximately 3 months after the sMRI. Subsequently, the colt returned to racing 4 months after the injury and won the second race.

### DISCUSSION

Previous studies have described the etiology of DSL desmitis [6, 16, 21]. These studies suggest that ODSL are more prone to damage than SDSL. Concurrent injuries to ODSL and SDSL have also been reported. In the present study, DSL abnormalities were observed medially in all cases. Injuries to ODSL usually occur uniaxially, likely as a result of asymmetric loading caused by abnormal conformation, foot imbalance, a misstep or poor footing [1]. Most horses with minor DSL desmitis exhibit moderate lameness that quickly subsides with rest. However, persistent lameness has been attributed to severe desmitis in some horses [6], and in some cases, this lameness persists or recurs with exercise. In the

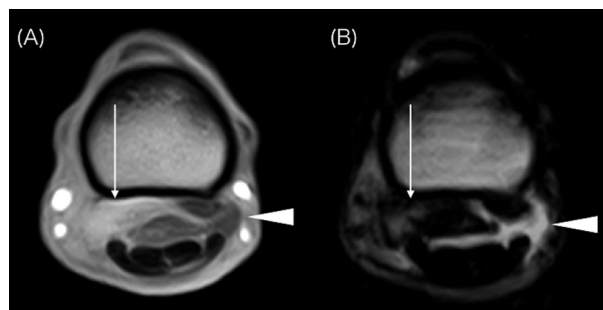


Fig. 7. (A) Transverse T1-weighted gradient echo image of case 3 showing high signal intensity (arrow) in the medial oblique distal sesamoidean ligament (ODSL) at the proximal third of the proximal phalanx. The dorsal and medial directions are at the top and left, respectively. Fluid in the digital flexor tendon sheath (DFTS) is observed as an area of low signal intensity (arrowhead). (B) Transverse T2-weighted fast spin echo image acquired at the level of the proximal third of the proximal phalanx in case 3. The medial ODSL exhibits increased signal intensity (arrow). An increased amount of fluid is present within the DFTS (arrowhead).

present study, case 1 and case 2 presented with lameness. Case 1 exhibited acute-onset forelimb lameness that gradually improved to a degree that allowed hand-walking within a week. In case 2, the lameness initially improved with rest and medication, but recurred after 3 days of light exercise. The degrees of lameness in the present cases corresponded with the cases of ODSL injury described in previous studies.

In the present study, all cases were initially examined by radiography. The primary importance of radiography in cases of lameness is to rule out fracture and to examine bone changes, such as periosteal osteoproliferation and bone resorption. In case 1, radiography revealed periosteal osteoproliferation at the mid-palmaromedial aspect of the proximal phalanx, which likely indicated enthesiophytosis at the distal attachment of ODSL. Dyson reported that enthesiophytosis

at the attachment of the ODSL is a relatively common and possibly incidental finding [6]. In other words, these lesions should not always be considered clinically significant. Simultaneously, the presence of these lesions might also suggest chronic stress remodeling at the insertion site of one of the ODSLs, because periosteal osteoproliferation only gradually becomes visible after mechanical irritation. The periosteal osteoproliferation observed in case 1 indicated that the horse might have accumulated minor damage to the medial ODSL without exhibiting any clinical symptoms. In contrast, periosteal osteoproliferation was not present in the radiographic evaluation of case 3, despite the fact that this horse had a history of persistent digital pulse increase, which likely represented chronic inflammation of the lower limb. Based on these findings, radiographic findings were presumed to be inconclusive for the diagnosis of ODSL injury.

In case 1 and case 2, ultrasonography identified significant effusion of the DFTS. The digital flexor tendons were clearly visualized using ultrasonography, and no abnormalities were observed in any case. In contrast, it was difficult to obtain good quality ultrasonographic images of DSL, because of the challenge in maintaining good surface contact in the distal direction, as well as acoustic shadowing caused by other surrounding tissues. Dyson reported that it could be difficult to determine the extent of desmitis and whether the damage extended distally using ultrasonography alone [6]. In case 2, the medial ODSL appeared to be enlarged, although echogenicity was homogeneous. A previous report described the diagnosis of severe DSL desmitis based on the echogenicity changes observed with ultrasonography [6]. Hypochoic changes were observed around the medial ODSL in the ultrasonographic images of case 1. The sMRI images of case 1 revealed that damage to the medial ODSL was present from the proximal attachment to the distal end of the ligament. As suggested in the previous study, ultrasonography could detect changes only when the damage was significant and present proximally, given the limited viewing capability of ultrasonography.

In the present study, the following sequences were used in the sMRI examination: T1-weighted GRE, T2-weighted FSE, and STIR FSE. For MRI, image quality is dependent on the resolution and signal-to-noise ratio (SNR), which can be affected by several factors including field strength, number of averaging, slice thickness and field of view (FOV) [13]. The T1-weighted GRE sequence provides excellent anatomic detail, characterized by a relatively high resolution resulting from a high SNR. In the present study, the T1-weighted GRE sequence was particularly useful for evaluating tissues that require symmetrical imaging, such as the medial and lateral ODSL. One advantage of the GRE sequence over the spin echo sequence is that the former requires a shorter acquisition time to generate a comparable SNR. A longer acquisition time increases the risk of motion artifacts during sMRI, as the images are obtained under sedation. The T2-weighted FSE sequence and STIR FSE sequence produce images with prominent tissue contrast. In the present study, these sequences were used to identify fluid and pathologic changes within soft tissues and bones. The damaged ODSL exhibited

a hyperintense signal in all sequences. Because ODSL normally exhibits a uniform low to intermediate signal (Fig. 3), the increased signal intensity within ODSL likely indicates changes in the extracellular matrix and increased water content in the ligament. These signal changes corresponded well with the findings of a previous study by Smith [23]. Injuries that affect ligaments could cause changes in the shapes and sizes of these ligaments. In the present study, high-contrast FSE sequence images were useful for distinguishing the borders of the enlarged ligament from the surrounding tissues. Importantly, the signal differences between these tissues could be detected with relatively low-resolution sMRI. The FSE sequence normally requires a longer acquisition time than GRE sequences. With sMRI, it is important to recognize that resolution should be compromised in the FSE sequence to avoid motion artifact. Higher resolution can be achieved by adjusting FOV. In the present study, the requirement of the low-field magnet to image the whole pastern placed a limitation on further reduction of FOV.

The signal intensity of ODSL is known to be influenced by the magic angle effect (MAE) on images acquired with sMRI [13, 22]. The proximal aspect of the medial ODSL is particularly susceptible to the MAE. This phenomenon has been attributed to the variable fiber pattern within the proximal one-third of the ligament and the tendency for the medial ODSL to exist at a more oblique angle to the vertical, relative to the lateral ODSL [3, 22]. The MAE is particularly noticeable in sequences with a short TE, such as the T1-weighted sequence. In contrast, long TE sequences, such as the T2-weighted sequences, are the least susceptible to the MAE [13]. All cases in the present study exhibited a high signal within the medial ODSL on T2-weighted FSE images. Accordingly, these areas were considered to be true lesions.

In the present study, distention of the DFTS appeared as areas of low signal intensity on T1-weighted GRE images, whereas the areas exhibited high signal intensity on T2-weighted FSE and STIR FSE images. The results of the present study suggest that both T2-weighted FSE and STIR FSE sequences could detect signals generated from fluid in the DFTS. The STIR FSE sequence, which use a fat suppression technique, outweighs the T2-weighted FSE sequence for evaluating fat-based tissues, such as the trabecular bone [13]. In the present study, DFTS effusion was evident in all cases subjected to sMRI. Horses with acute desmitis often present with a sudden onset of lameness and swelling of the palmar surface of the pastern region, which are caused by DFTS effusion [1]. Distention of the DFTS was suggested to represent the inflammatory changes that occurred concurrently with DSL injury.

In the three horses described in the present report, desmitis of DSL was considered to be severe, based on the required length of resting time and the sMRI image interpretation. In a previous report, the mean resting period required for DSL desmitis was 6 months [20]. Extracorporeal shock wave therapy, ligament splitting, injection of the DFTS with corticosteroids and hyaluronan, and regenerative therapies using platelet-rich plasma or stem cells are common treatment options for DSL injury [11, 20]. In the present study, a follow-

up interview of the trainers revealed that none of the horses received these treatments. Two cases in the present study successfully returned to racing following rehabilitation, in which the exercise intensity was controlled and gradually increased over time.

In conclusion, ODSL injury should be considered as a differential diagnosis in Thoroughbred racehorses with swelling over the palmar surface of the proximal phalanx. Radiographic and ultrasonographic assessments may be inconclusive. sMRI is an excellent diagnostic modality for the diagnosis of ODSL desmitis. The image quality yielded by this modality is suitable for a detailed evaluation of each tissue and exclusion of artifacts, such as the MAE. However, given the limited number of cases, the correlation between prognosis and severity according to sMRI image interpretation remains to be investigated.

#### REFERENCES

- Bertone, A. L. 2011. Lameness in the Extremities. pp. 588–613. *In: Adams and Stashak's Lameness in Horses*, 6th ed. (Baxter, G. M. ed.), Blackwell Publishing, Ltd., West Sussex.
- Busoni, V., Snaps, F., Trenteseaux, J. and Dondelinger, R. F. 2004. Magnetic resonance imaging of the palmar aspect of the equine podotrochlear apparatus: normal appearance. *Vet. Radiol. Ultrasound* **45**: 198–204. [[Medline](#)] [[CrossRef](#)]
- Denoix, J. M. 2000. The Equine Pastern. pp. 129–241. *In: The Equine Distal Limb: An Atlas of Clinical Anatomy and Comparative Imaging*. (Denoix J. M. ed.), Manson Publishing Ltd., London.
- Denoix, J. M., Crevier, N. and Azevedo, C. 1991. Ultrasound examination of the pastern. *Proc. Am. Assoc. Equine Pract.* **37**: 363–379.
- Denoix, J. M., Crevier, N., Roger, B. and Lebas, J. 1993. Magnetic resonance imaging of the equine foot. *Vet. Radiol. Ultrasound* **34**: 405–411. [[CrossRef](#)]
- Dyson, S. J. and Denoix, J. M. 1995. Tendon, tendon sheath, and ligament injuries in the pastern. *Vet. Clin. North Am. Equine Pract.* **11**: 217–233. [[Medline](#)]
- Kainer, R. A. 2002. Functional anatomy of equine locomotor organs. pp. 11–13. *In: Adam's Lameness in Horses*, 5th ed. (Stashak, T. S. ed.), Lippincott Williams & Wilkins, Philadelphia.
- Kleiter, M., Kneissl, S., Stanek, C., Mayrhofer, E., Baulain, U. and Deegen, E. 1999. Evaluation of magnetic resonance imaging techniques in the equine digit. *Vet. Radiol. Ultrasound* **40**: 15–22. [[Medline](#)] [[CrossRef](#)]
- Mair, T. S., Kinns, J., Jones, R. D. and Bolas, N. M. 2005. Magnetic resonance imaging of the distal limb of the standing horse. *Equine Vet. Educ.* **17**: 74–78. [[CrossRef](#)]
- Martinelli, M. J., Kuriashkin, I. V., Carragher, B. O., Clarkson, R. B. and Baker, G. J. 1997. Magnetic resonance imaging of the equine metacarpophalangeal joint: three-dimensional reconstruction and anatomic analysis. *Vet. Radiol. Ultrasound* **38**: 193–199. [[Medline](#)] [[CrossRef](#)]
- McClure, S. R., VanSickle, D., Evans, R., Reinertson, E. L. and Moran, L. 2004. The effects of extracorporeal shock-wave therapy on the ultrasonographic and histologic appearance of collagenase-induced equine forelimb suspensory ligament desmitis. *Ultrasound Med. Biol.* **30**: 461–467. [[Medline](#)] [[CrossRef](#)]
- Moyer, W. and Raker, C. W. 1980. Diseases of the suspensory apparatus. *Vet. Clin. North Am. Large Anim. Pract.* **2**: 61–80. [[Medline](#)]
- Murray, R. and Werpy, N. 2011. Principles of MRI in horses. pp. 101–145. *In: Equine MRI*. (Murray, R. C. ed.), Blackwell Publishing, Ltd., West Sussex.
- Park, R. D., Nelson, T. R. and Hoopes, P. 1987. Magnetic resonance imaging of the normal equine digit and metacarpophalangeal joint. *Vet. Radiol.* **28**: 105–116. [[CrossRef](#)]
- Rantanen, N. W. 1998. Examination procedures and normal anatomy. pp. 114–117. *In: Equine Diagnostic Ultrasonography*. (Rantanen, N. W. and McKinnon, A. O. eds.), The Williams & Wilkins Co., Baltimore.
- Redding, W. R. 1998. Distal sesamoidean ligament injuries and desmitis of the accessory ligament of the deep digital flexor tendon. *Proc. Dubai. Inter. Equine Symp.* 227–240.
- Reef, V. B. 1998. Musculoskeletal ultrasonography. pp. 43–64. *In: Equine Diagnostic Ultrasound*. (Reef, V. B. ed.) W. B. Saunders Co., Philadelphia.
- Reef, V. B. and Genovese, R. 2003. Soft tissue injuries of the pastern. pp. 716–723. *In: Diagnosis and Management of Lameness in the Horse*, 1st ed. (Ross, M. and Dyson, S. eds.), Saunders, St. Louis.
- Reimer, J. M. 1996. Ultrasonography of the pastern: 1. anatomy and pathology; 2. outcome of selected injuries in race horses. *Proc. 43rd. Annu. Conv. Am. Assoc. Equine Pract.* 123–125.
- Sampson, S. N., Schneider, R. K., Tucker, R. L., Gavin, P. R., Zubrod, C. J. and Ho, C. P. 2007. Magnetic resonance imaging features of oblique and straight distal sesamoidean desmitis in 27 horses. *Vet. Radiol. Ultrasound* **48**: 303–311. [[Medline](#)] [[CrossRef](#)]
- Schneider, R. K., Tucker, R. L., Habegger, S. R., Brown, J. and Leathers, C. W. 2003. Desmitis of the straight sesamoidean ligament in horses: 9 cases (1995–1997). *J. Am. Vet. Med. Assoc.* **222**: 973–977. [[Medline](#)] [[CrossRef](#)]
- Smith, M. A., Dyson, S. J. and Murray, R. C. 2008. Is a magic angle effect observed in the collateral ligaments of the distal interphalangeal joint or the oblique sesamoidean ligaments during standing magnetic resonance imaging? *Vet. Radiol. Ultrasound* **49**: 509–515. [[Medline](#)] [[CrossRef](#)]
- Smith, S., Dyson, S. J. and Murray, R. C. 2008. Magnetic resonance imaging of distal sesamoidean ligament injury. *Vet. Radiol. Ultrasound* **49**: 516–528. [[Medline](#)] [[CrossRef](#)]
- Snow, V. E. 1996. Sectional anatomy of the equine digit with MRI. pp. 9–40. *In: Sectional Anatomy of the Equine Digit with MRI*. (Snow, V. E. and Rantanen, N. W. eds.), Santa Ynez Valley Printing and Lithography, Buellton.