

# Radiofrequency ablation of stellate ganglion in a patient with complex regional pain syndrome

Chinmoy Roy, Nilay Chatterjee<sup>1</sup>

Department of Anesthesia and Pain Medicine, Institute of Neurosciences Kolkata, Kolkata, West Bengal, <sup>1</sup>Department of Neuroanesthesiology and Pain Medicine, Sree Chitra Tirunal Institute for Medical Sciences and Technology, Trivandrum, Kerala, India

## Address for correspondence:

Dr. Nilay Chatterjee,  
NFQ B-10, Sree Chitra Tirunal  
Institute for Medical Sciences  
and Technology, Faculty Quarters,  
Kumarapuram, Poonthi Road,  
Medical College,  
PO, Trivandrum - 695011,  
Kerala, India.  
E-mail: nilay.chatt@gmail.com

## ABSTRACT

Complex regional pain syndrome (CRPS) is characterized by a combination of sensory, motor, vasomotor, pseudomotor dysfunctions and trophic signs. We describe the use of radiofrequency (RF) ablation of Stellate ganglion (SG) under fluoroscopy, for long-term suppression of sympathetic nervous system, in a patient having CRPS-not otherwise specified. Although the effects of thermal RF neurolysis may be partial or temporary, they may promote better conditions toward rehabilitation. The beneficial effect obtained by the RF neurolysis of SG in this particular patient strongly advocates the use of this mode of therapy in patients with CRPS.

**Key words:** *Complex regional pain syndrome, radiofrequency ablation, stellate ganglion*

## INTRODUCTION

Complex regional pain syndrome (CRPS) usually occurs following a complication of surgery or trauma, although spontaneous development has also been reported. International association of study of pain has defined CRPS as a collection of locally appearing painful conditions following a trauma, which chiefly occur distally and exceed in intensity and duration of the expected clinical course of the original trauma, often resulting in considerably restricted motor function.<sup>[1]</sup> Clinically, CRPS is characterized by a combination of sensory, motor, vasomotor and pseudomotor dysfunctions, along with trophic signs. Despite the disagreement in the literature regarding the exact pathophysiology, the current understanding underlines the involvement of central, peripheral, afferent and efferent mechanisms.<sup>[2,3]</sup> CRPS has been further classification of CRPS into types I and II

on the basis of the absence or presence of demonstrable nerve damage. Afterward, a third type was added i.e., CRPS not otherwise specified (NOS), describing a syndrome only partially complying with the diagnostic criteria, in such a situation, where no other diagnosis is probable.<sup>[1]</sup> There is no proven and universally acceptable treatment protocol for managing such patients. Pharmacotherapy with a wide array of drugs<sup>[4-6]</sup> and physical therapy in the form of graded motor imagery therapy remains two major arms in the conservative management.<sup>[7]</sup> When they fail, interventions are considered, which includes sympathetic blocks, brachial plexus block, epidural administration of drugs and neurostimulation.

In the following section, we describe the use of radiofrequency (RF) ablation of Stellate ganglion (SG) for long-term suppression of sympathetic nervous system in a patient having CRPS-type III (NOS).

## CASE REPORT

A 15-year-old boy presented with severe resting pain over the right hand for last 6 months. He had a history of traumatic fracture and sustained near amputation injury of third and fourth fingers (distal phalanges) of the right hand 8 years ago, which eventually healed with malunion. Presently, the area over the healed would is

### Access this article online

#### Quick Response Code:



#### Website:

www.saudija.org

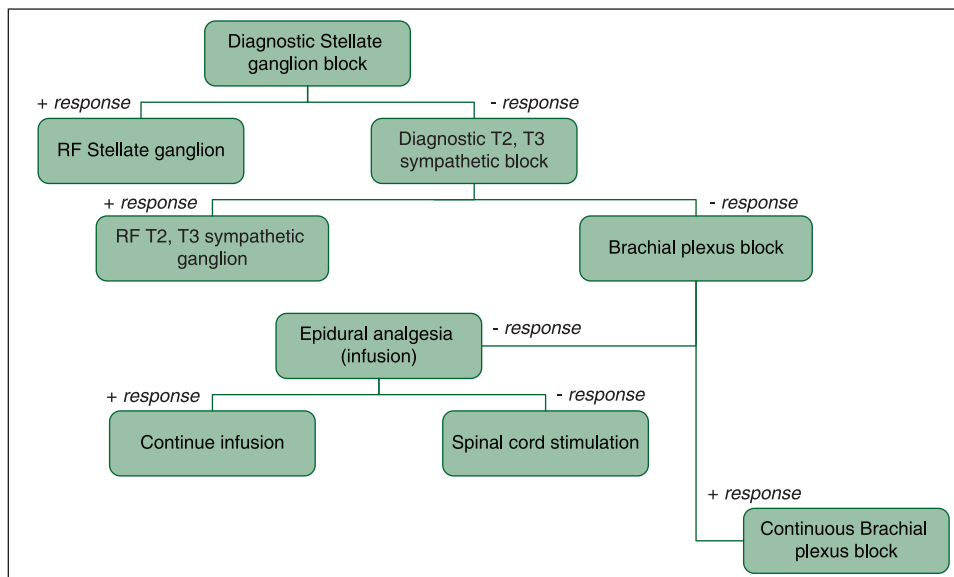
#### DOI:

10.4103/1658-354X.136636

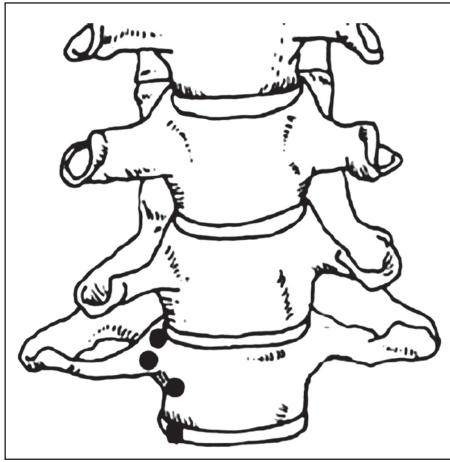
scarred and from that site pain initially appeared and gradually spread over few days to the entire right hand. He is unable to use the affected hand because of severe pain, even merely touching the extremity aggravated the pain severely. The glove like distribution of pain was not confined to any dermatome. Associated features e.g., changes in temperature, sweating abnormalities, edema, trophic changes, significant alterations in skin colour: Were all absent in the affected hand. Before presenting to our clinic the patient had consulted several physicians and varied differential diagnoses were made including carpal tunnel syndrome, Raynaud’s disease, arthritis, disuse atrophy, Munchausen syndrome and somatoform disorder. Reports of hematological, serological and radiological investigations did not reveal any abnormality. Nerve conduction study could not be performed because of severe pain. Patient had been treated with steroids, antiepileptics and tricyclic antidepressants and their diverse combinations, without much effect. Physiotherapy was advised but was not feasible because of severe pain. On the basis of history and physical examination, a diagnosis of CRPS was made. However, as this particular patient does not fulfill all the criteria of CRPS and pain remains the only major symptom, it was further classified to CRPS — NOS. The authors did not consider as any further investigation deemed to be necessary.

Since the conservative treatment options had already exhausted, a decision was made to proceed further with interventional treatment. A sequential treatment plan was made as shown in Flow Chart 1. It was decided beforehand that physiotherapy must begin as soon as pain is relieved. Patient and his father were explained meticulously about

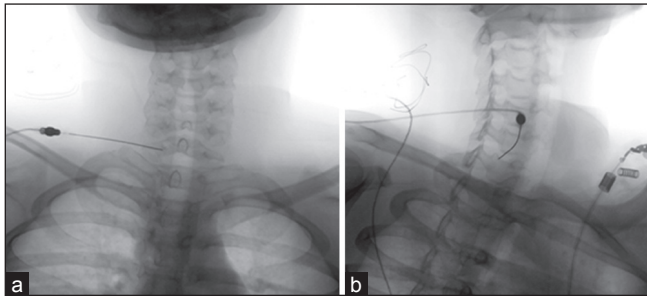
the treatment plan and an informed consent was obtained from his father. Oblique fluoroscopic approach was used for the diagnostic procedure, while patient lying supine with neck extended. Fluoroscope was rotated to right starting from an antero-posterior position to obtain a foraminal view. A 25-gauge spinal needle was directed towards the C7 vertebral body at the base of the uncinat process and just anterior to the foramina. A total volume of 2 ml of radio-opaque dye was injected under continuous fluoroscopy. Once a characteristic distribution of dye was obtained, 5 ml of 0.5% of preservative free lignocaine was injected. After about 5 min, the patient reported significant pain relief. Following this the patient was observed for 2 h and asked to come after 2 days for RF ablation of SG. RF thermal ablation was performed following the same approach, with a 21G (10 cm, 5 mm active tip) RF cannula. The site of needle placements are shown in Figure 1. Correct positioning was confirmed using “swimmer’s view” and also with small volume of dilute contrast, so that landmarks were not lost (Figure 2 shows the fluoroscopic views in antero-posterior and foraminal projection). Lignocaine (0.5 ml, 1%) was injected before lesioning. Four lesions were made (each at 80°C for 60s) at C7 level after confirming the precise needle placement by using sensory (50 Hz, upto 0.7 V) and motor (2 Hz, upto 1.5V) stimulations. During motor stimulation the patient made a verbal sound described previously.<sup>[8]</sup> Following the RF lesioning patient was closely observed in the recovery room for 4 h for any untoward complication. Significant pain relief as described by the patient associated with both subjective and objective improvement in function observed almost immediately after the procedure (Figure 3).



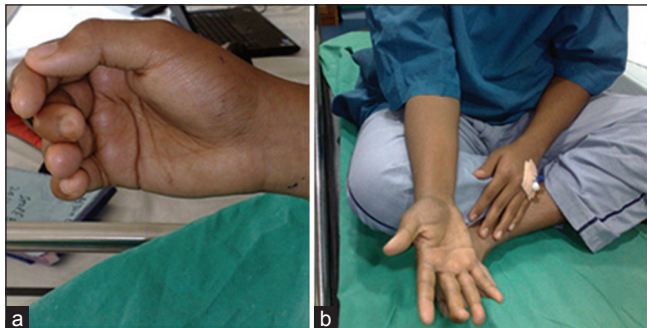
**Flow Chart 1:** Plan of treatment (+ response indicates subjective significant pain relief; >50% pain relief is considered as significant)



**Figure 1:** Sites for radiofrequency lesioning



**Figure 2:** Antero-posterior (a) and foraminal view (b) under fluoroscopy demonstrating radiofrequency needle position



**Figure 3:** Pre-procedure (a) and post-procedure (b) position of the affected hand

Until date, the patient has been followed-up for a period of 12 months and maintaining complete pain relief with normal function.

## DISCUSSION

There are few discrete reports on the efficacy of RF ablation of SG in CRPS.<sup>[9,10]</sup> We selected RF on the basis of our treatment protocol, as it could provide a long-term blockage to the SG compared to conventional blocks (local anesthetic and steroid, phenol or alcohol), which in turn

would result early and intense mobilization of the limb with vigorous physiotherapy.

The SG has been implicated in multiple painful conditions including hot flushes, post traumatic stress disorder and in CRPS<sup>[11]</sup> by generating a cascade of physiological events, mediated by the nerve growth factor. Application of local anesthetic to the SG might reverse that cascade. Summary of evidence for interventional pain management in CRPS suggests 2B+ recommendation for SG block and spinal cord stimulation.<sup>[1]</sup> RF ablation of SG does not carry any recommendation at present, but has been tried by Forouzanfar *et al* with overall success.<sup>[9]</sup> When intense physiotherapy was initiated under block conditions, joint and tissue mobilization is maximum, which facilitate the restoration of function.

SG may be reached by several approaches: Paratracheal, anterior, posterior and oblique. Neurolysis could be performed either by neurolytic solution or by RF. RF lesions have been instituted because of easy controllability of lesion size and site, well-tolerated and having few adverse effects. In this patient, almost immediate and nearly complete pain relief was probably due to the local anesthetic rather than the RF procedure. However, the sustained relief of pain for a considerable period of time can not be attributed to local anesthetic effect alone. Another notable finding was Horner's syndrome (ptosis and miosis were clearly visible), along with flushing of the conjunctiva and skin of hand, which patient had immediately following RF of SG. However, this did not last even for a day, whereas duration of the pain relief was prolonged. Therefore, one can not be completely certain whether this analgesic effect is only due to sympathetic blockade.

de Mos *et al.* have shown that the basis of the pain relief observed after SG blockade using local anesthetics may not be sympatholysis.<sup>[12]</sup> Interestingly, a recent report has demonstrated the effectiveness of pulsed RF to the SG for sympathetically mediated pain in hand, with a pain relief lasting for 19 months.<sup>[13]</sup> These reports support the notion that mechanisms other than sympatholysis, such as alteration of gene expression in the dorsal horn of cervical dorsal ganglion, induced by RF current reaching the site, reduction in the release of substance P in response to noxious stimuli, could be some of the probable reasons behind the beneficial effects of RF of SG.<sup>[14,15]</sup> However, further research are needed to clarify the precise mechanisms responsible for the long-term analgesic efficacy of RF lesions of the SG.

Although the effects of thermal RF neurolysis may be partial or temporary, they may promote better conditions

toward rehabilitation. Technically, a cooled RF would have produced a better lesion due to its enlarged lesion size and without having the compulsion for parallel placement unlike thermal RF.

Findings from this case report highlight the importance to have a comprehensive plan for diagnosing and managing CRPS. The beneficial effect obtained by the RF neurolysis of SG in this particular patient strongly advocates the use of this mode of therapy in patients with CRPS.

## REFERENCES

1. vanEijs F, Stanton-Hicks M, Van Zundert J, Faber CG, Lubenow TR, Mekhail N, *et al.* Evidence-based interventional pain medicine according to clinical diagnoses. 16. Complex regional pain syndrome. *Pain Pract* 2011;11:70-87.
2. Groeneweg JG, Huygen FJ, Heijmans-Antonissen C, Niehof S, Zijlstra FJ. Increased endothelin-1 and diminished nitric oxide levels in blister fluids of patients with intermediate cold type complex regional pain syndrome type 1. *BMC Musculoskelet Disord* 2006;7:91.
3. Gibbs GF, Drummond PD, Finch PM, Phillips JK. Unravelling the pathophysiology of complex regional pain syndrome: Focus on sympathetically maintained pain. *Clin Exp Pharmacol Physiol* 2008;35:717-24.
4. Manicourt DH, Brasseur JP, Boutsen Y, Depreseux G, Devogelaer JP. Role of alendronate in therapy for posttraumatic complex regional pain syndrome type I of the lower extremity. *Arthritis Rheum* 2004;50:3690-7.
5. Christensen K, Jensen EM, Noer I. The reflex dystrophy syndrome response to treatment with systemic corticosteroids. *Acta Chir Scand* 1982;148:653-5.
6. Harke H, Gretenkort P, Ladleif HU, Rahman S, Harke O. The response of neuropathic pain and pain in complex regional pain syndrome I to carbamazepine and sustained-release morphine in patients pretreated with spinal cord stimulation: A double-blinded randomized study. *Anesth Analg* 2001;92:488-95.
7. Moseley GL. Graded motor imagery is effective for long-standing complex regional pain syndrome: A randomised controlled trial. *Pain* 2004;108:192-8.
8. Prithvi Raj P, Leland L, Serdar E, Peter SS, Steven DW, Gabor R, *et al.* *Interventional Pain Management: Image-Guided Procedures*. 2<sup>nd</sup> ed. Philadelphia: Saunders Elsevier; 2008. p. 123.
9. Forouzanfar T, van Kleef M, Weber WE. Radiofrequency lesions of the stellate ganglion in chronic pain syndromes: Retrospective analysis of clinical efficacy in 86 patients. *Clin J Pain* 2000;16:164-8.
10. Yamaguchi S, Iida H, Sumi K, Takenaka M, Yoshimura N, Dohi S. Preliminary study of the efficacy of radiofrequency lesions of stellate ganglion in chronic pain patients. *Pain Med* 2010;11:142-4.
11. Lipov EG, Joshi JR, Sanders S, Slavin KV. A unifying theory linking the prolonged efficacy of the stellate ganglion block for the treatment of chronic regional pain syndrome (CRPS), hot flashes, and posttraumatic stress disorder (PTSD). *Med Hypotheses* 2009;72:657-61.
12. de Mos M, Sturkenboom MC, Huygen FJ. Current understandings on complex regional pain syndrome. *Pain Pract* 2009;9:86-99.
13. Martin DC, Willis ML, Mullinax LA, Clarke NL, Homburger JA, Berger IH. Pulsed radiofrequency application in the treatment of chronic pain. *Pain Pract* 2007;7:31-5.
14. Van Zundert J, de Louw AJ, Joosten EA, Kessels AG, Honig W, Dederen PJ, *et al.* Pulsed and continuous radiofrequency current adjacent to the cervical dorsal root ganglion of the rat induces late cellular activity in the dorsal horn. *Anesthesiology* 2005;102:125-31.
15. Wang QX, Wang XY, Fu NA, Liu JY, Yao SL. Stellate ganglion block inhibits formalin-induced nociceptive responses: Mechanism of action. *Eur J Anaesthesiol* 2005;22:913-8.

**How to cite this article:** Roy C, Chatterjee N. Radiofrequency ablation of stellate ganglion in a patient with complex regional pain syndrome. *Saudi J Anaesth* 2014;8:408-11.

**Source of Support:** Nil, **Conflict of Interest:** None declared.

## Announcement

### iPhone App



A free application to browse and search the journal's content is now available for iPhone/iPad. The application provides "Table of Contents" of the latest issues, which are stored on the device for future offline browsing. Internet connection is required to access the back issues and search facility. The application is Compatible with iPhone, iPod touch, and iPad and Requires iOS 3.1 or later. The application can be downloaded from <http://itunes.apple.com/us/app/medknow-journals/id458064375?ls=1&mt=8>. For suggestions and comments do write back to us.