




# Internal Offloading or Surgical Offloading Adjuvant Techniques in the Reconstruction of Diabetic Plantar First Metatarsal Head Ulcer For Lasting Results

Thalaivirithan Margabandu Balakrishnan<sup>1</sup>  Srividya Madhurbootheswaran<sup>1</sup> Vanya Butcha<sup>1</sup>  
Anjana Elangovan<sup>1</sup> J. Jaganmohan<sup>1</sup>

<sup>1</sup>Department of Plastic, Reconstructive and Faciomaxillary Surgery, Madras Medical College, Chennai, Tamil Nadu, India

Indian J Plast Surg 2022;55:339–350.

Address for correspondence Thalaivirithan Margabandu Balakrishnan, MBBS, MS, FRCS, DNB, DNB, MCh, Department of Plastic and Faciomaxillary Surgery, Madras Medical College, Old No. 15/ New No. 10, Thiruvalluvar Street, Kodambakkam, Chennai 600003, Tamil Nadu, India (e-mail: thalaiviri.b@gmail.com).

## Abstract

**Introduction** Management of diabetic foot ulcers (DFUs) is subverted by recurrences. The main cause for the recurrence of DFUs is the failure to recognize and address all the faulty biomechanics precipitating and perpetuating the ulcer. So, we have devised a protocol for treating the diabetic plantar first metatarsal head ulcer (DPFMHUs) incorporating structured internal offloading procedures in conjunction with reconstruction.

**Aim** The aim of this study was to evaluate our protocol in the management of DPFMHUs.

**Materials and Methods** Fifty-one patients (31 males and 20 females) with DPFMHUs were managed with our protocol in this prospective cohort study conducted from March 2015 to March 2020. All the faulty biomechanics were addressed by tailored internal offloading procedure as per the protocol.

**Results** All patients were followed up for an average period of 23.7 months. Early complications were in the form of wound infection (3 patients, 5.9%) and seroma/hematoma (2 patients, 3.9%). Late complication in the form of recurrence was seen only in one patient (1.9%); rest of the patients had no recurrence (98%). Transfer lesions were noted in six patients (11.8%).

**Conclusion** Our tailored protocol, which addresses all the faulty biomechanics associated with the DPFMHU, may be very helpful in preventing the recurrence and to give lasting results. It is imperative to design a tailored internal/surgical offloading procedure for all deforming forces that are responsible for precipitation and perpetuation of DPFMHUs, in addition to like tissue reconstruction.

## Keywords

- ▶ diabetic foot
- ▶ diabetic foot ulcers
- ▶ plantar first metatarsal head ulcers
- ▶ internal or surgical offloading

## Introduction

One of the most common types of diabetic foot ulcer (DFU) encountered is the diabetic plantar first metatarsal head ulcers

(DPFMHUs).<sup>1–3</sup> Despite efforts by various health departments all over the world, the epidemic of diabetes mellitus (DM) a noncommunicable disease is sadly growing unabated. The most important and burgeoning locoregional complication

article published online  
October 31, 2022

DOI <https://doi.org/10.1055/s-0042-1756135>.  
ISSN 0970-0358.

© 2022. Association of Plastic Surgeons of India. All rights reserved. This is an open access article published by Thieme under the terms of the Creative Commons Attribution-NonDerivative-NonCommercial-License, permitting copying and reproduction so long as the original work is given appropriate credit. Contents may not be used for commercial purposes, or adapted, remixed, transformed or built upon. (<https://creativecommons.org/licenses/by-nc-nd/4.0/>)  
Thieme Medical and Scientific Publishers Pvt. Ltd., A-12, 2nd Floor, Sector 2, Noida-201301 UP, India

of DM—the DFU—is also on the rise.<sup>4,5</sup> DFUs are a common complication of DM that can severely affect a patient's quality of life and may lead to lower limb amputation.<sup>6–11</sup> There exist inordinate interactions between the various components of diabetic peripheral neuropathy culminating in the DFUs. In the pathogenesis of DPFMHUs, all the following are incriminated: (1) sensory neuropathy that causes loss of protective sensation and joint sensation which predispose to repeated microtrauma and undue pressure,<sup>12,13</sup> (2) motor neuropathy that predisposes to deformity due to muscle imbalances,<sup>12,13</sup> and (3) autonomic neuropathy that precipitates hyperemic bony demineralization and redundancy of ligaments.<sup>12,13</sup> All these contribute to the seven different deforming forces at the hallucial MTPJ (metatarsophalangeal joint) region that culminate in Charcot's neuroarthropathy or generate an abnormal pressure point which in turn precipitates and perpetuates DPFMHUs<sup>14</sup> (►Table 1). Surgical or internal offloading is defined as surgical correction of faulty biomechanics—the static and mobile deformities responsible for the generation of deforming forces and abnormal pressure points.<sup>14</sup> It is speculated that in DPFMHUs, when all these associated faulty biomechanics and deformities are addressed by the appropriate adjuvant surgical internal offloading procedures, it will provide lasting results without recurrence. The prevention of the recurrence of DPFMHUs is the biggest challenge in this era of collateral epidemic of DFUs. The prevention of recurrence is the prevention of amputation indirectly. The main cause for the recurrence of DFUs is the failure to recognize and address all the faulty biomechanics precipitating and perpetuating the ulcer.<sup>14,15</sup> So, we have devised a protocol for treating the DPFMHUs incorporating structured internal offloading procedures in conjunction with reconstruction (►Table 1). So far in the literature, no study exists that comprehensively incorporates the internal offloading procedure for each faulty biomechanics responsible for the DFUs. Our protocol incorporates ways and means of diagnosing each faulty biomechanics that is responsible for precipitating and perpetuating the DPFMHUs and how to address each one of them individually. In this study, we evaluated the effectiveness of our protocol in the management of DPFMHUs.

## Materials and Methods

This prospective cohort study was conducted from March 2015 to March 2020 in 51 patients (31 males and 20 females) with DPFMHUs. Institutional ethics committee approval was obtained for this study. Informed consent was obtained from all the patients including their permission for using clinical photographs for research and publication purposes.

### Inclusion Criteria

1. Diabetic patients with unilateral DPFMHU with University of Texas<sup>16</sup> Grade 3AB/Grade 2 AB and more than 6 weeks' ulcer duration.
2. Those who followed foot care advice including the use of proper foot wear in the perioperative period.

### Exclusion Criteria

1. Peripheral vascular disease and ischemic component.
2. Severe secondary infection leading to compromise of the overlying soft tissues and tarsal skin.
3. Dialysis dependent patients with severe Monckeberg's sclerosis and atherosclerosis.
4. Mentally unstable and un-cooperative patients.
5. Patients who were lost to follow-up in the postoperative period.
6. Patients with other types of Charcot's (Brodsky) in combination with other ulcers.

## Surgical Technique

### Preoperative Education and Preparation

All these patients attended the diabetic foot clinic of our institution twice weekly. They had undergone foot care education about external offloading and usage of proper footwear. Those cases with infection and deep loculation had undergone a preliminary debridement and wounds were prepared with topical negative pressure dressings and directive antibiotic therapy. Those on anticoagulants and antiplatelet for coexisting ischemic heart disease were changed to appropriate bridge anticoagulation therapy before surgery and their coagulation profile was optimized with parenteral vitamin K. Their glycemic status was optimized. All patients were subjected to clinical examination, gait assessment, X-rays, magnetic resonance imaging (MRI), and pedobarogram assessments. The peak plantar pressure (PPP) and the pressure time integral (PTI) were noted in all patients. Then a proper diagnosis for each case of DPFMHU was arrived incorporating all the faulty biomechanics, underlying static and mobile deforming forces. Then the tailored reconstructive plans integrating the internal offloading procedures addressing all deforming forces were drawn for each patient. Proper high-risk informed consent was taken for surgery explaining all procedures and its possible complications.

### Surgical Technique

Under regional block, DPFMHUs were reconstructed incorporating the appropriate surgical (Internal) offloading procedures (►Tables 1 and 2). Those who presented with invasive infection initially underwent debridement, and subsequently with improved wound and general condition patients were taken up for reconstruction in a similar fashion. A Segmuller drain was kept in the reconstructed area.

### Postoperative Follow-Up

Posterior plaster of Paris (POP) slab was used to immobilize the foot and leg in all cases with cotton fluffy dressing. After 24 hours, all were mobilized with walker under supervision, with protective footwear for the contralateral foot and nonweight bearing for the operated foot. Patients were allowed to weight bear on the operated foot after 8 weeks with proper locoregional offloading prosthesis (extra depth footwears with silicone gel socks). All cases

**Table 1** Faulty biomechanics, their diagnosis, and tailored internal offloading procedure

Sl. No.	Faulty biomechanics in the precipitation and perpetuation of the DPFMHUs and its pathogenesis	Type of deforming forces	Clinical and laboratorial diagnosis	Surgical offloading procedure
1.	Instabilities of hallucial metatarsophalangeal joint (resulting in the plantar luxing head of hallucial metatarsal bone) due to Charcot's degeneration and aggravated by FHL and PL muscles recruitment	Vertical deforming force	Clinically the probe to bone test positive Laboratory tests: 1. PBG; PTI and hypertriphied abnormal high pressure at the ball of great toe 2. Superimposed skiagrams of the straight lateral view of the foot on weight bearing and nonweight bearing (→ <b>Fig. 4A–C</b> )	Gap arthroplasty if the head of the hallucial MTB is destroyed or if it is normal DMDO of hallucial MTB (→ <b>Fig. 2</b> ) with arthroeresis of the hallucial metatarsophalangeal joint with distally based ABH muscle flap (→ <b>Fig. 3</b> )
2	Contracted tendoachilles causing increased fore foot pressure	Vertical deforming force	Clinically the equinus is diagnosed by Siff-verskiold test Laboratory tests: PBG during walking cycle contributes to the diagnosis	Percutaneous tendoachilles lengthening (→ <b>Video 1</b> , online only)
3	Recruitment of PL causing plantar luxing and tibial rotating (along its long axis) of hallucial metatarsal bone head	Vertical and oblique (shear) deforming forces	Clinically the passive and active inversion at subtalar joint is reduced Laboratory tests: PBG—PTI and PPP at the ball of great toe	PL recruitment addressed by PL to PB tendon transfer lengthening (→ <b>Fig. 4</b> )
4	Hypertrophy of sesamoids and their subluxations	Horizontal, oblique (shear) and vertical deforming forces	Clinically there are large sesamoids on palpation Laboratory tests: Skiagrams of foot antero-posterior, lateral and oblique views (→ <b>Fig. 5A and E</b> )	Sesamoidectomy (→ <b>Fig. 5</b> )
5	Recruitment of extrinsic flexors and extensors (FHL and EHL)—secondarily plantar luxing the hallucial metatarsal head	Vertical deforming force	Clinically there is subluxating FHL on passive extension of hallucial metatarsophalangeal joint from the sesamoid box. Clawing of great toe reveals EHL recruitment Laboratory test: PBG	FHL and EHL tenotomy (→ <b>Fig. 6</b> )
6	Flexor Hallucis brevis (FHB)/paralytic contracture—secondarily plantar luxing the hallucial metatarsal head with subluxating sesamoids	Vertical deforming force	Clinically the clawing of hallux (→ <b>Fig. 6A</b> ) Laboratory test: PBG	Closed capsulotomy of the hallucial Interphalangeal joint after above procedures (→ <b>Fig. 6</b> )
7	Atrophy and distal displacement of fat pads of ball of great toe—atrophic skin rendered directly beneath the luxating sesamoid metatarsal head complex	Absence of buffer for shear and vertical forces.	Clinically the atrophy or distal displacement of fat pad at the ball of great toe Laboratory test: Soft tissue shadow in lateral skiagrams of foot compared with normal side and MRI confirm diagnosis	Fat injection at the reconstructed ball of great toe area (→ <b>Fig. 7</b> ) (→ <b>Video 2</b> , online only)

Abbreviations: ABH, abductor hallucis; DMDO, distal metatarsal diaphyseal oblique osteotomy; DPFMHUs, diabetic plantar first metatarsal head ulcer; FHB, flexor hallucis brevis; FHL, flexor Hallucis longus; MRI, magnetic resonance imaging; MTB, metatarsal bone; PB, peroneus brevis; PBG, pedobarogram; PL, peroneus longus; PPP, peak plantar pressure; PTI, pressure time integral.

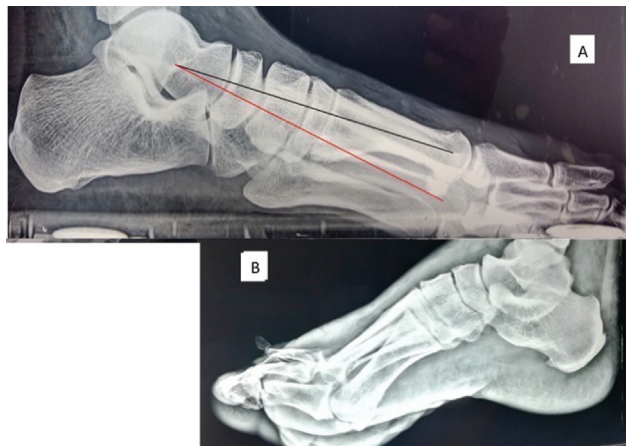**Table 2** Patient details

Sl. no.	Age	Sex	Dimension Of ulcer (in cm)	Surface area of ulcer (cm <sup>2</sup> )	Adjunct internal offloading procedure								Type of reconstruction	Pedobarogram			Follow-up (in months)	Complication	Transfer lesions		
					FHL/EHL tenotomy	Percutaneous TA lengthening	PL tenotomy or PL to PB (peroneus brevis) tendon transfer	Arthrodesis with distally based ABH muscle flap	Gap arthroplasty/DMDO	Fat injection	Avg preop PPP at ball of great toe (N/cm <sup>2</sup> )	Cap		Avg post-op PPP at ball of great toe (N/cm <sup>2</sup> )	Avg post-op PTT at ball of great toe (-N/cm <sup>2</sup> S)	Avg post-op PTT (N/cm <sup>2</sup> S)					
1	68	M	2 × 1	2	+	+	+								60	18	32	10	28		
2	70	M	2 × 3	6	+	+	+								67	17	35	9	24		
3	60	F	2.5 × 1.5	3.75	+	+	+						+		69	19	30	11	29	Wound infection	
4	52	M	3 × 2	6	+	+	+					+			72	18	31	9	22		
5	56	M	1.5 × 1.5	2.25	+	+	+					+			61	17	34	12	30		
6	63	F	2.5 × 3.5	8.75	+	+	+					+			60	19	30	10	21		Calcaneal ulcer
7	49	F	3.5 × 2	7	+	+	+					+			58	20	29	12	26		
8	68	F	2 × 3	6	+	+	+					+			68	16	33	10	20		
9	65	M	2 × 2.5	5	+	+	+					+			66	21	43	19	21	Recurrence	
10	71	M	1.5 × 1	1.5	+	+	+					+			70	20	30	9	27		
11	54	F	3.5 × 1	3.5	+	+	+					+			62	19	31	11	18		
12	56	M	3 × 1.5	4.5	+	+	+					+			71	17	36	10	25		5th MTP J ulcer
13	53	M	2 × 2.5	5	+	+	+					+			70	19	35	12	20		
14	49	M	3 × 3	9	+	+	+					+			61	16	32	8	19		
15	73	M	2 × 3	6	+	+	+					+			66	17	28	9	23		
16	77	F	2.5 × 3.5	8.75	+	+	+					+			65	18	28	10	24		
17	54	F	1.5 × 2	3	+	+	+					+			60	21	31	12	20		
18	60	M	2.5 × 2.5	6.25	+	+	+					+			64	20	33	10	25		
19	50	M	3.5 × 3	10.5	+	+	+					+			69	20	40	13	23		
20	48	M	1.5 × 3.5	5.25	+	+	+					+			63	18	32	11	22		
21	54	F	3.5 × 1.5	5.25	+	+	+					+			59	19	36	12	20		Calcaneal ulcer
22	55	M	2 × 3.5	7	+	+	+					+			64	21	34	13	22		
23	52	F	1.5 × 3	4.5	+	+	+					+			62	17	31	10	23		
24	66	M	3.5 × 3.5	12.25	+	+	+					+			65	19	30	8	24		
25	69	F	1.5 × 2.5	3.75	+	+	+					+			67	20	29	11	26		
26	61	F	2.5 × 2	5	+	+	+					+			72	18	33	9	30	Seroma	Calcaneal ulcer
27	73	M	2.5 × 3	7.5	+	+	+					+			66	17	36	8	18		
28	63	M	1.5 × 1.5	2.25	+	+	+					+			68	17	37	10	24		
29	74	M	2 × 2.5	5	+	+	+					+			62	18	27	10	27		
30	55	F	2.5 × 2.5	6.25	+	+	+					+			63	19	31	9	22		
31	59	F	3.5 × 3	10.5	+	+	+					+			64	20	33	12	23		
32	63	M	2 × 1.5	3	+	+	+					+			61	21	34	12	22		

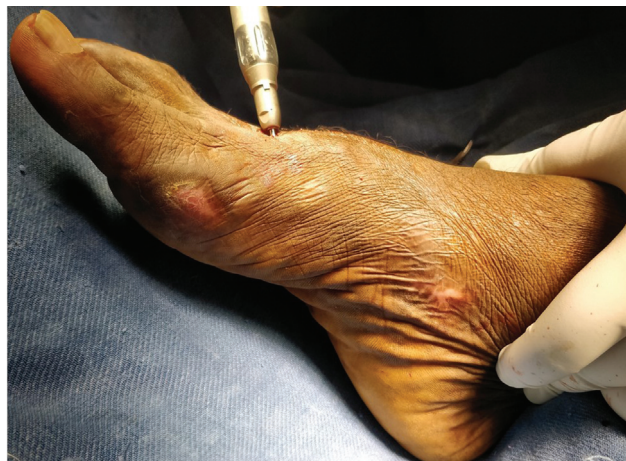Table 2 (Continued)

Sl. no.	Age	Sex	Dimension Of ulcer (in cm)	Surface area of ulcer (cm <sup>2</sup> )	Adjunct internal offloading procedure								Type of reconstruction	Pedobarogram			Follow-up (in months)	Complication	Transfer lesions	
					FHL/EHL tenotomy	Percutaneous TA lengthening	PL tenotomy or PL to PB (peroneus brevis) tendon transfer	Arthrodesis with distally based ABH muscle flap	Gap arthroplasty/ DMDO	Fat injection	Avg preop PPP at ball of great toe (N/cm <sup>2</sup> )	Avg preop PPI at ball of great toe (-N/cm <sup>2</sup> .S)		Avg post-op PPP at ball of great toe (N/cm <sup>2</sup> )	Avg post-op PPI (N/cm <sup>2</sup> .S)					
33	74	M	3.5 × 3.5	12.25	+	+	+	+	+	+	+	+	+	65	17	35	10	26		
34	71	F	2 × 2	4	+	+	+							67	18	29	9	29		Calcaneal ulcer
35	65	M	2.5 × 1.5	3.75	+	+	+							72	19	27	7	25		
36	50	M	3.5 × 2.5	8.75	+	+	+							63	17	36	7	21		
37	47	M	2.5 × 1	2.5	+	+	+							59	19	35	9	24		
38	76	F	2 × 2.5	5	+	+	+							62	20	36	10	28		Hematoma/Seroma
39	64	M	1.5 × 3	4.5	+	+	+							66	21	30	11	23		
40	60	M	3 × 2	6	+	+	+							68	16	35	8	23		
41	61	F	2 × 3	6	+	+	+							69	18	34	12	26		
42	53	M	2 × 2.5	5	+	+	+							61	20	28	12	22		Wound infection
43	57	F	2 × 3.5	7	+	+	+							64	19	35	10	27		
44	49	M	2 × 1	2	+	+	+							65	18	34	11	26		
45	45	F	2.5 × 2.5	6.25	+	+	+							65	22	30	13	29		
46	52	F	2 × 2	4	+	+	+							64	16	33	10	24		
47	65	M	1.5 × 2.5	3.75	+	+	+							59	19	28	13	21		Wound infection
48	68	M	1.5 × 1.5	2.25	+	+	+							60	17	30	9	25		
49	62	M	3 × 3	9	+	+	+							62	19	31	10	22		5th MT ulcer
50	70	F	3.5 × 3.5	12.25	+	+	+							63	20	35	8	23		
51	71	M	2.5 × 1.5	3.75	+	+	+							61	19	32	10	18		

Abbreviations: ABH, abductor Hallucis; DMDO, distal metatarsal diaphyseal oblique osteotomy; EHL, extensor hallucis longus; FHL, flexor hallucis longus; MT, metatarsal bone; MTPJ, metatarsophalangeal joint; PB, peroneus brevis; PBG, pedobarogram; PL, peroneus longus; PPI, pressure time integral; TA, tendoachilles.

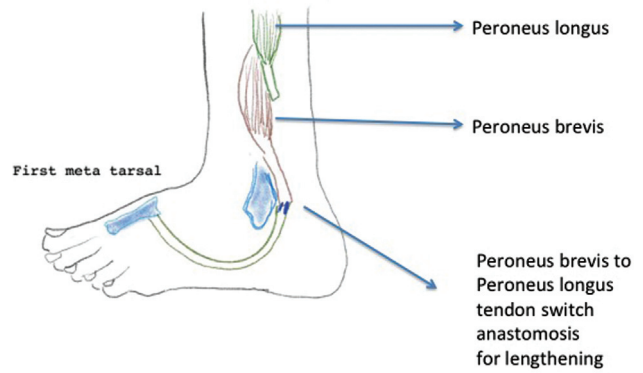


**Fig. 1** (A) Superimposed straight lateral weight bearing (red line) and nonweight bearing (black line) X-ray foot showing plantar luxation of metatarsal head (a mobile deformity). (B) Computed tomography para sagittal section showing the plantar luxation of the head of the first metatarsal bone. X-ray showing the plantar subluxation of the head of the first metatarsal bone on weight bearing.



**Fig. 2** Intraoperative picture showing distal metatarsal diaphyseal oblique osteotomy.

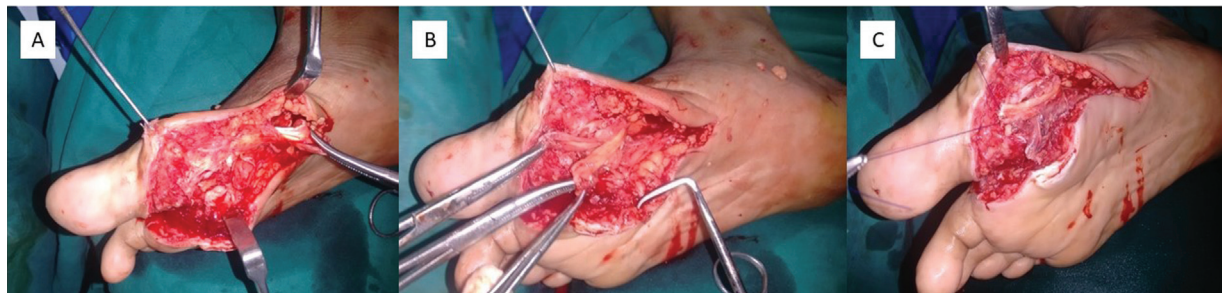were followed up monthly with gait assessment and corrections. At 12 and 18 months, patients were subjected to pedobarogram assessment with measurements of PPP and PTI under the head of hallucial metatarsal bone.



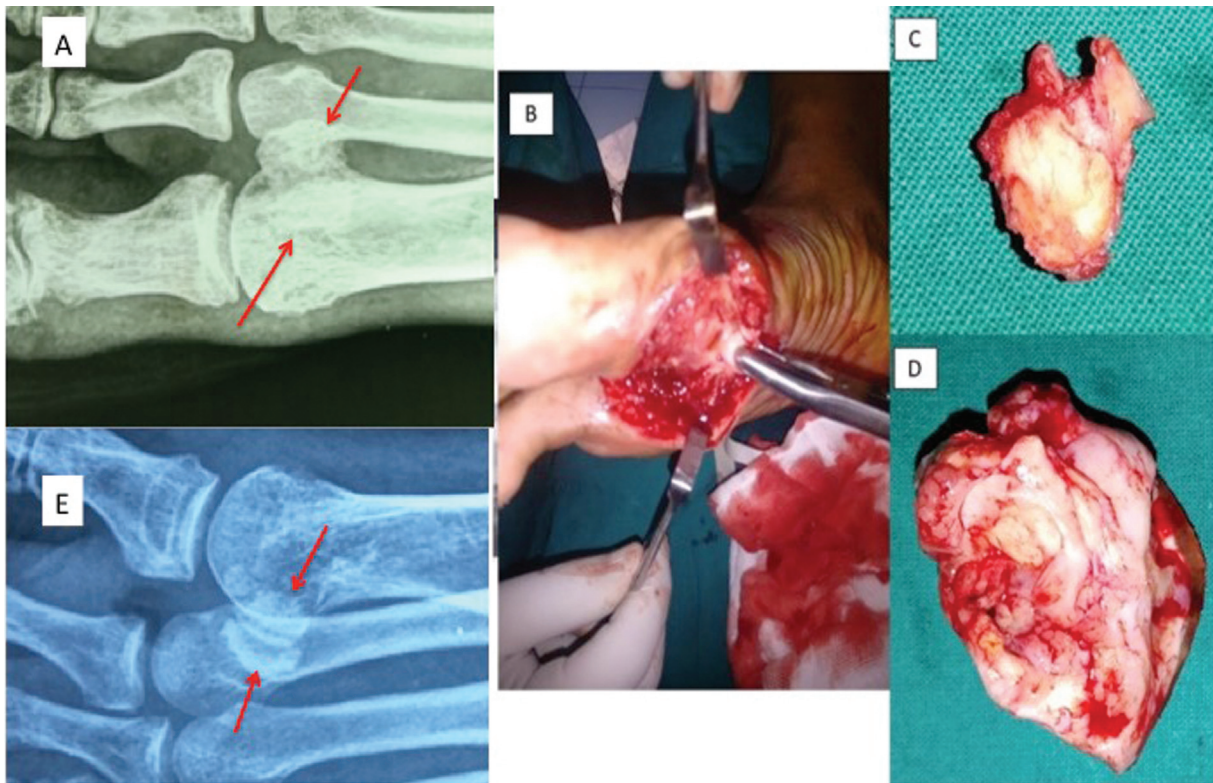
**Fig. 4** Schematic diagram showing peroneus longus to peroneus brevis tendon switch operation to negate the peroneus recruitment.

**Case 1**

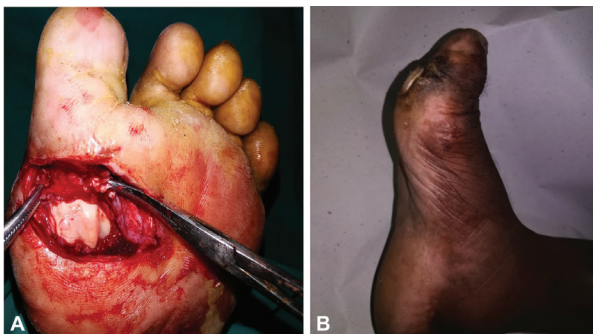A 49-year-old female, known diabetic case, presented with infected ball of great toe ulcer left foot with suppuration extending onto first web space with large loculation. She underwent early debridement. Her wound was prepared with negative pressure dressing for 10 days (→ Fig. 8A–C). She had bounding pedal pulses. Probe to bone test was positive. After optimized general condition and wound condition, she was found to have the following mobile deformities gleaned from clinical examination, superimposed weight bearing and nonweight bearing straight/lateral digital radiograph, MRI (→ Fig. 9), and pedobarogram (→ Fig. 10). She had plantar luxing first metatarsal head (→ Fig. 1) with hypertrophied sesamoids and recruitment<sup>17</sup> of extensor hallucis longus (EHL)/peroneus/flexor hallucis longus (FHL) with weak intrinsics. There was equinus deformity with passive and active dorsiflexion falling short of 10-degree of plantigrade posture (→ Fig. 8B). There was atrophy of ball of great toe fat with minimal distal displacement (→ Fig. 9). Under regional nerve block tendoachilles (TA) percutaneous lengthening (Hoke’s percutaneous triple hemisection of the tendon) was done that resulted in 40-degree dorsiflexion (→ Fig. 8F). Next through retromalleolar peroneal access, peroneus longus to peroneus brevis switch was done. With FHL/EHL tenotomy, sesamoidectomy was performed. With the proximal extension of incision along the foot, distally based abductor hallucis (ABH) was harvested and was wound around hallucial MTPJ. Fat was harvested from lower abdomen and after purification it was injected into



**Fig. 3** (A, B) Distally based abductor hallucis (ABH) flap being raised for arthroeresis of hallucial metatarsophalangeal joint. (C) Fixation of ABH after winding around the hallucial metatarsophalangeal joint.



**Fig. 5** (A) Hypertrophied sesamoids (within arrows). (B) Sesamoidectomy in progress. (C, D) Sesamoidectomy specimen. (E) Comparative X-ray of the contralateral foot for assessing the hypertrophied sesamoids (within arrows).

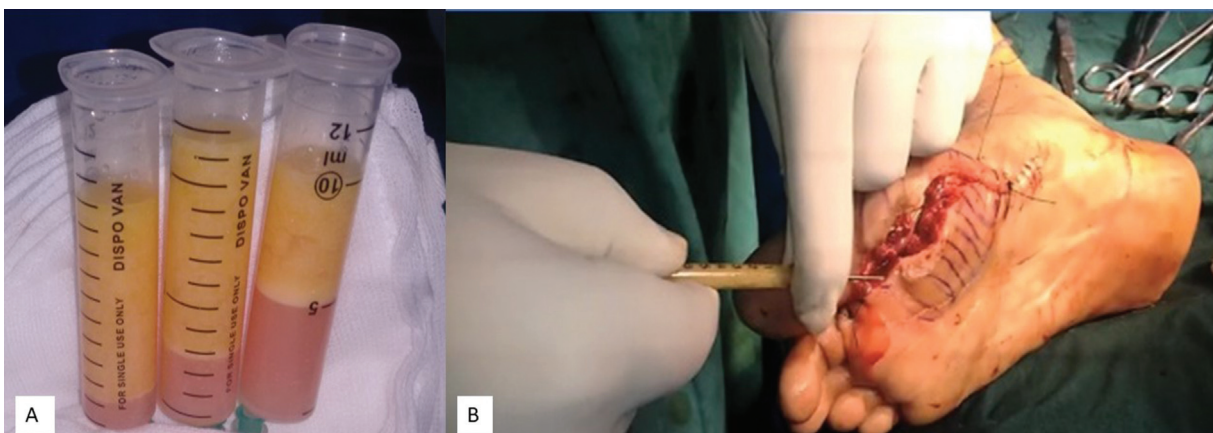


**Fig. 6** (A) Flexor hallucis longus (tenotomy). (B) Another representative case with hallux clawing with plantar first metatarsal head ulcer.

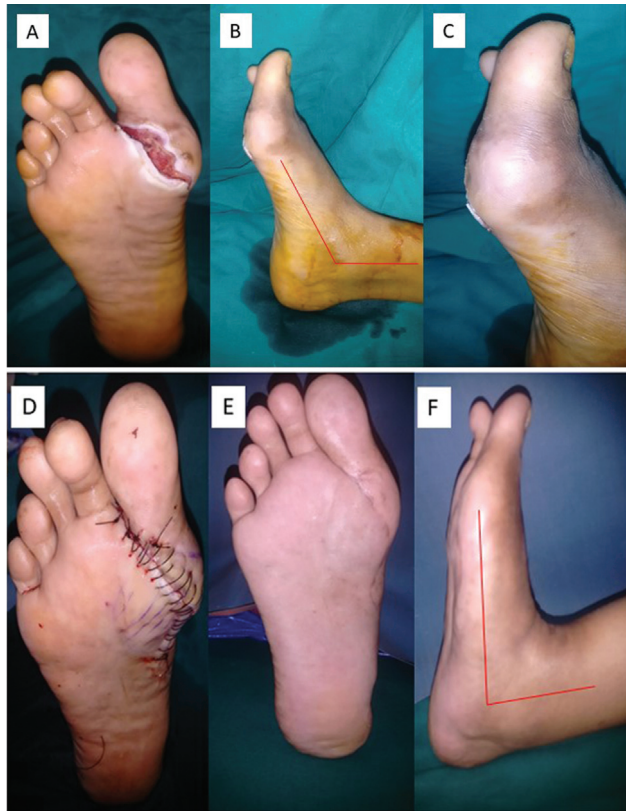the subcutaneous plane in multilevel, crisscross pattern (→Video 2, online only). The wound was closed by a local advancement flap (→Fig. 8D). Patient was followed up for 26 months and she had no recurrence or transfer lesions (→Fig. 8E). At the end of the follow-up, MRI examination showed congruent hallucial MTPJ with retained ABH muscle mass with good subcutaneous fat pad retention (→Fig. 9B). Follow-up pedobarogram also showed significant decrease in PPP and PTI parameters (→Fig. 10B).

**Case 2**

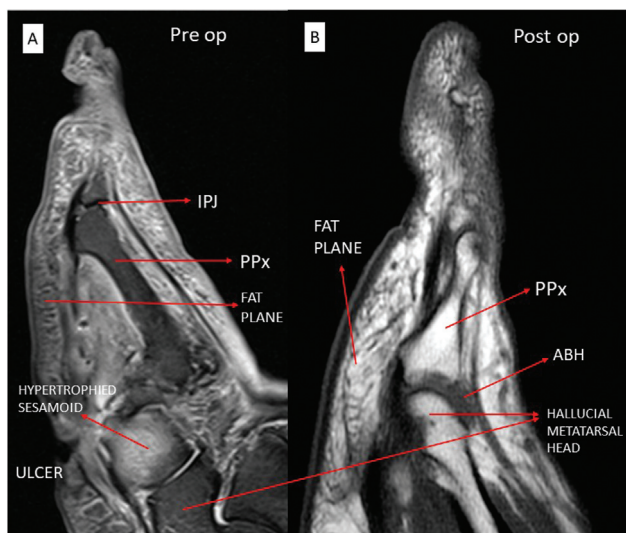
A 50-year-old male, known diabetic case, presented with chronic ulcer over ball of left great toe with no signs of



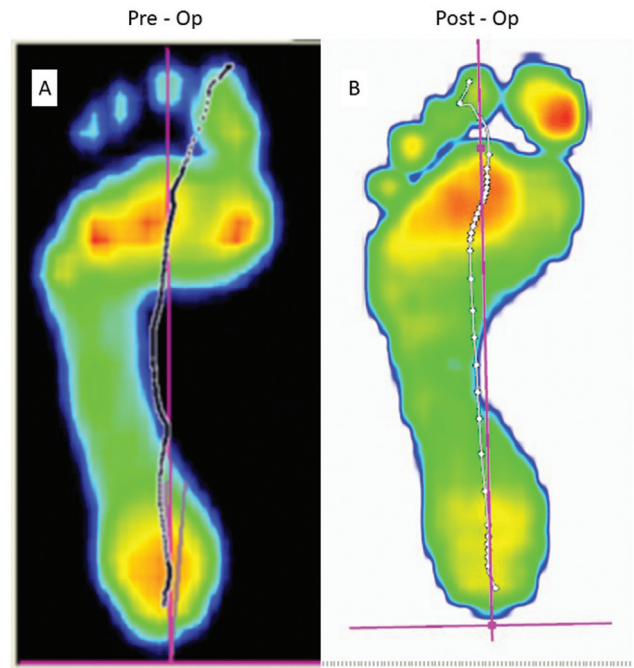
**Fig. 7** (A) Standing gravitation assisted purification of fat. (B) Multilaminar multilevel crisscross fat injection in progress.



**Fig. 8** Illustration of case 7. (A) Wound after debridement after topical negative pressure dressing. (B) Equinus deformity due to tendoachilles contracture. (C) Recruitment of extensor hallucis longus and clawing of toe. (D) Immediate postoperative image. (E) Stable result of 26 months. (F) Postoperative active dorsiflexion restored.



**Fig. 9** (A, B) Sagittal view of preoperative and postoperative magnetic resonance imaging along the axis of hallucial metatarsophalangeal joint (MTPJ) showing good retention of fat in the plantar aspect of ball of great toe (B). Maintenance of abductor hallucis (ABH) muscle mass around the joint restoring the congruent position of hallucial MTPJ, (B) when compared with preoperative image (A). IPJ, interphalangeal joint



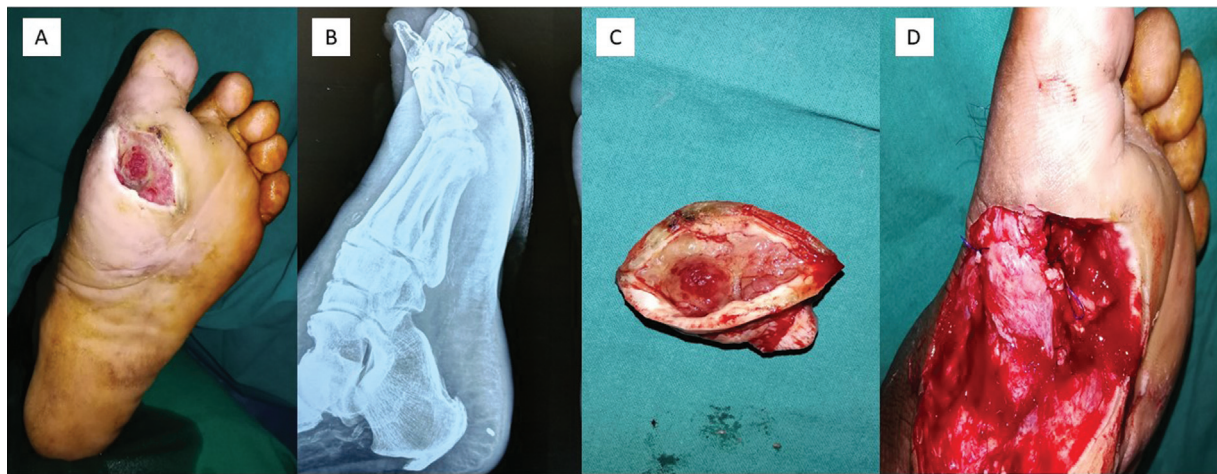**Fig. 10** (A) Preoperative pedobarogram (PBG) showing increased peak plantar pressure at the head of first metatarsal bone. (B) Postoperative PBG showing eschewing of abnormal pressure point beneath the head of first metatarsal bone.

localized infection (►Fig. 11A). His glycemic control was optimized. He had the following static deformities—plantar luxing first metatarsal head with hypertrophied sesamoids and recruitment of EHL/FHL with weak intrinsics. He had equinus deformity with passive and active dorsiflexion falling short of neutral posture. Under regional nerve block, TA percutaneous lengthening was done that resulted in 25-degree dorsiflexion (►Fig. 12A). Ulcer was excised with FHL/EHL tenotomy, and sesamoidectomy (►Fig. 11C) done. Both distal metatarsal diaphyseal osteotomy (DMDO—an oblique osteotomy at the neck with dorsal distal and proximal plantar orientation) and ABH arthroereisis were done. Our new procedure established the congruent relationship of the articular surfaces distal articular surface of head of metatarsal bone with base of hallucial proximal phalanx in the absence of sesamoid capsular complex of the hallucial MTPJ. Arthroereisis with ABH flap and distal metatarsal diaphyseal oblique osteotomy were done as there was a fixed plantar luxated hallucial metatarsal bone head (►Fig. 11D). The wound was closed by a double rotation flap (►Fig. 12A, B). Patient was followed up for 21 months and he had no recurrence or transfer lesions (►Fig. 12C). At the end of the follow-up, pedobarogram also showed significant decrease in PPP and PTI parameters.

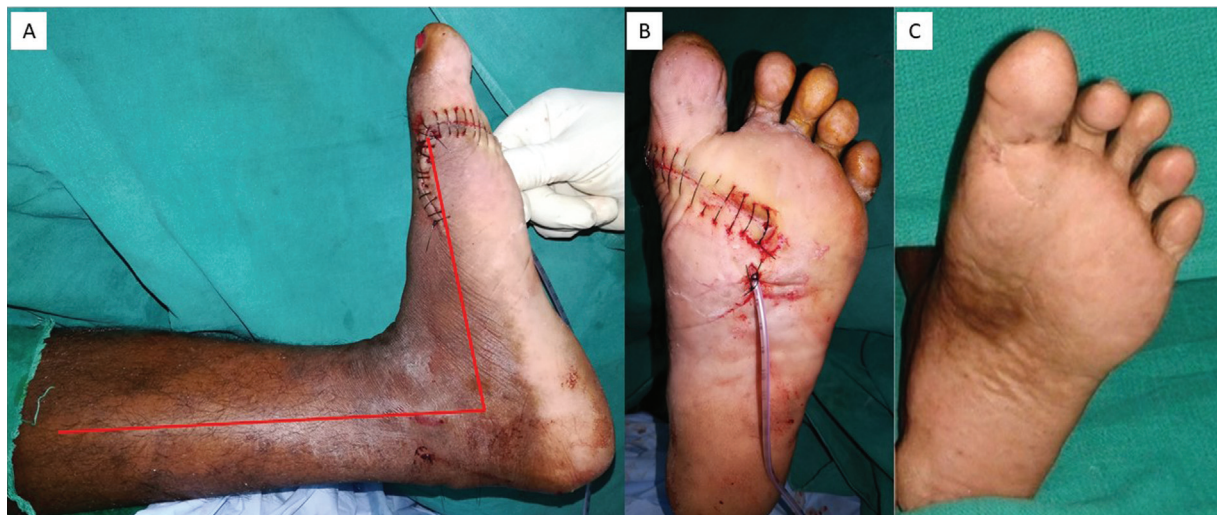**Results**

Age of the patients varied from 45 to 77 years and the average age was 60.7 years. Results of the study are given in ►Table 3, ►Figs. 13 and 14. The transfer lesions were subsequently





**Fig. 11** Illustration of case 36. (A) Preoperative chronic plantar ulcer at ball of great toe. (B) Clawing of great toe (fixed plantar luxated head of hallucial metatarsal bone) in straight lateral nonweight bearing view. (C) Ulcer excision with sesamoidectomy. (D) Abductor hallucis arthroeresis in progress.



**Fig. 12** (A) A 25-degree dorsiflexion attained on table with percutaneous tendoachilles lengthening. (B) Double rotation flap. (C) Stable result at 21 months follow-up.

managed as per the institutional protocol. These transfer lesions were again analyzed for new regional recurring faulty biomechanics (like flexor recruitment and plantar luxating head of metatarsals) and they were addressed accordingly. A 65-year-old male patient had late recurrence ( $n = 1$ ) (1.9%) after ulcer free quiescent period for 15.5 months with development of chronic limb-threatening ischemia.

## Discussion

DFUs are the leading cause of nontraumatic amputation in both developed and developing countries.<sup>18</sup> One major challenge lies in the prevention of the recurrence of the DFUs.<sup>19</sup> Ulcer recurrence is a relatively common event, with rates of 35 to 40% over 3 years, increasing to 70% over 5 years.<sup>7,20</sup> The 5-year mortality for DFUs and minor and

major amputations were recently reported to be 30.5, 46.2, and 56.6%, respectively.<sup>21</sup> So, it is obvious that the recurrence leads to further burden in the management of DFUs.<sup>10,22–25</sup> There is consensus among the surgeons dealing with the DFUs that the internal or surgical offloading procedures must be an integral part of the reconstruction plan to prevent any recurrence and to give lasting results. The integrated diabetic foot care treatment encompassing structured patient education, surgical offloading procedures, tailored reconstruction, proper footwear, and most importantly patient's full compliance are essential for the prevention of DFUs.<sup>26</sup> Dayer and Assal<sup>27</sup> and other studies<sup>28–31</sup> established that multiple tendon balancing procedures promote rapid healing of ball of great toe ulcers in diabetics. Dayer and Assal<sup>27</sup> had managed only the extrinsics induced deforming forces at the

**Table 3** Results of the study

Parameters studied	Results
Age range	45 to 77 years
Average age	60.7 years
Average size of ulcer	5.69 cm <sup>2</sup>
Average duration of DPFMHUs prior to surgical intervention	8.5 weeks
EHL/FHL tenotomy	All patients (100%)
Sesamoidectomy	All patients (100%)
Hoke's percutaneous triple hemisection TA lengthening	All patients (100%)
PL to PB switch	15 patients (29.4%)
Distally based ABH flap arthrodesis	48 patients (94.1%)
DMDO with ABH arthrodesis	5 patients (9.8%).
Fat injection	15 patients (29.6%)
Average follow-up period	23.7 months
Average PPP and PTI reduction following surgical intervention (at the end of follow-up) compared with preoperative values	79.5% ( $p = 0.025$ )
Early complications	5 patients (9.8%)
Wound infection	3 patients (5.9%)
Hematoma/seroma	2 patients (3.9%)
Recurrence rate	1 patient (1.96%)
Successful healing rate of DPFMHUs	50 patients (98.03%)
Transfer lesions	6 patients (11.8%)
Transfer calcaneal ulcer	4 patients (7.8%)
Transfer 5 <sup>th</sup> MTP joint ulcer	2 patients (3.9%)

Abbreviations: ABH, abductor hallucis; DMDO, distal metatarsal diaphyseal oblique osteotomy; DPFMHUs, diabetic plantar first metatarsal head ulcer; EHL, extensor hallucis longus; FHL, flexor hallucis longus; MTP, metatarsophalangeal; PB, peroneus brevis; PL, peroneus longus; PPP, peak plantar pressure; PTI, pressure time integral; TA, tendoachilles.

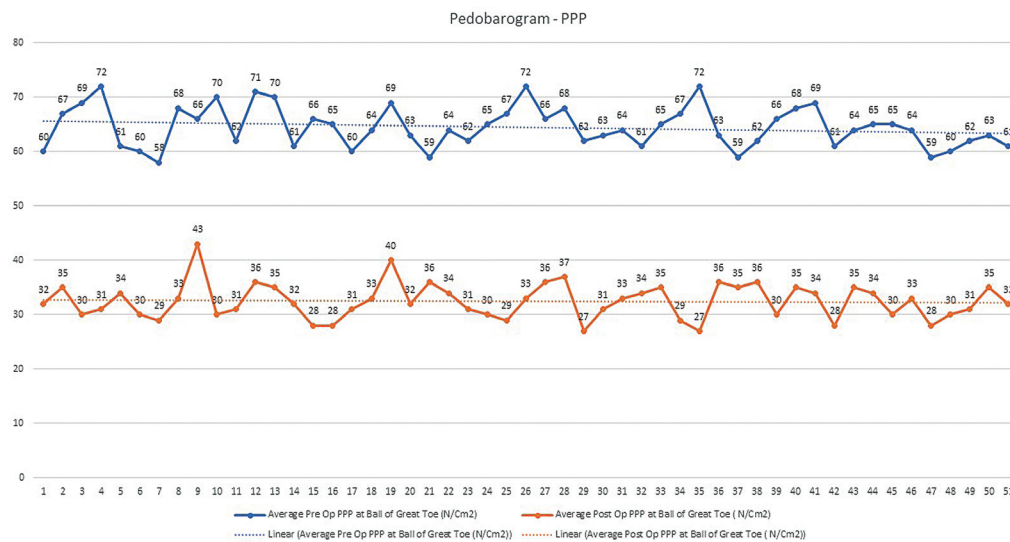
hallucial MTPJ and allowed the ball of great toe ulcers to heal by secondary intention. We have established in this relatively larger study that, when “like tissue” reconstruction using the local flaps with integrated internal offloading procedures like DMDO, hypertrophied sesamoidectomy, arthroeresis with ABH flap and fat injection along with tendon balancing procedures can give a stable and lasting results with prevention of recurrences. In addition, in our study, we have established that PPP and PTI parameters were significantly reduced. The limitation of our study is the small size of the study population. But the strength of our study is tailored internal offloading procedures addressing all the faulty biomechanics that are responsible for precipitating and perpetuating the DPFMHUs. A large-scale study will be helpful in establishing the versatility of our protocol.

## Conclusion

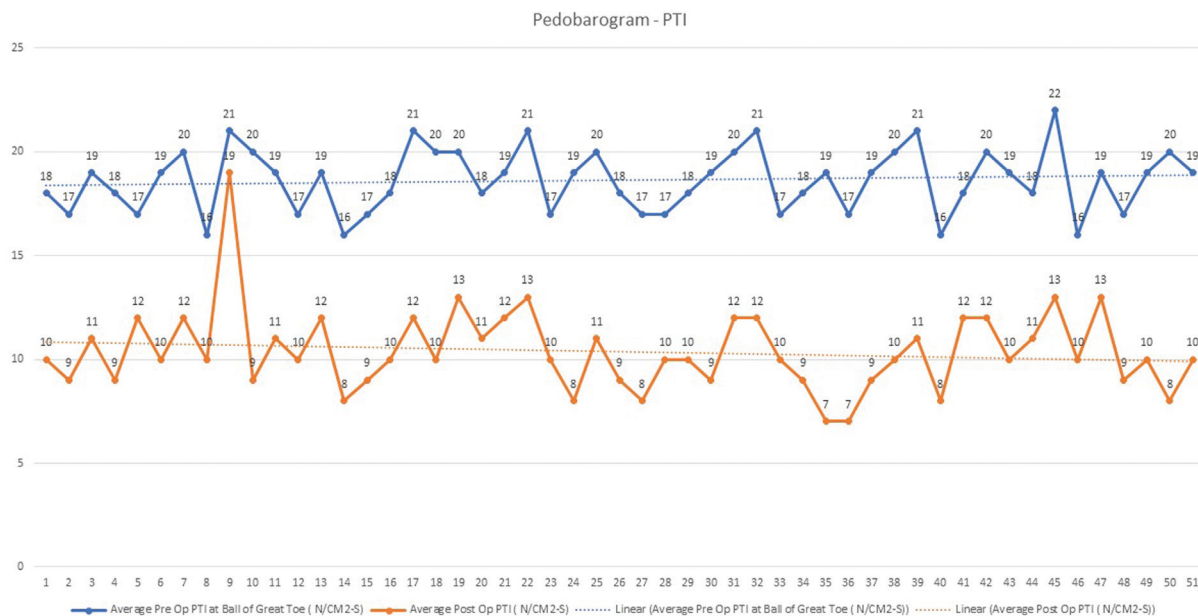
Our tailored protocol, which addresses all the faulty biomechanics associated with the diabetic plantar first metatarsal head ulcer, may be very helpful in preventing recurrence and to give lasting results. It is imperative to design a tailored internal surgical offloading procedure for all deforming forces that are responsible for the precipitation and perpetuation of diabetic plantar first metatarsal head ulcers, in addition to like tissue reconstruction.

### Video 1

Percutaneous lengthening of tendoachilles. Online content including video sequences viewable at: <https://www.thieme-connect.com/products/ejournals/html/10.1055/s-0042-1756135>.



**Fig. 13** Graphic line chart analysis of peak plantar pressure (PPP)—preoperative (blue line) and postoperative (orange line) analysis in 51 patients.



**Fig. 14** Graphic line chart analysis of pressure time integral (PTI)—preoperative (blue line), postoperative (orange line) analysis in 51 patients.

## Video 2

Fat injection into the peri-wound flaps. Online content including video sequences viewable at: <https://www.thieme-connect.com/products/ejournals/html/10.1055/s-0042-1756135>.

## Conflicts of Interest

None declared.

## References

- Oliver TI, Mutluoglu M. Diabetic Foot Ulcer. [Updated 2020 Sep 15]. In: StatPearls [Internet]. Treasure Island (FL): Stat Pearls Publishing; 2021 Jan-. Accessed March 27, 2022 from: <https://www.ncbi.nlm.nih.gov/books/NBK537328/>
- Galea AM, Springett K, Bungay H, Clift S, Fava S, Cachia M. Incidence and location of diabetic foot ulcer recurrence. *Diabet Foot J* 2009;12(04):181
- Pit'hová P, Pátková H, Galandáková I, Dolezalová L, Kvapil M. [Differences in ulcer location in diabetic foot syndrome]. *Vnitr Lek* 2007;53(12):1278–1285
- Trautner C, Haastert B, Spraul M, Giani G, Berger M. Unchanged incidence of lower-limb amputations in a German City, 1990–1998. *Diabetes Care* 2001;24(05):855–859
- Almaraz MC, González-Romero S, Bravo M, et al. Incidence of lower limb amputations in individuals with and without diabetes mellitus in Andalusia (Spain) from 1998 to 2006. *Diabetes Res Clin Pract* 2012;95(03):399–405
- WHO. Global report on diabetes. WHO. Accessed March 27, 2022 <http://www.who.int/diabetes/global-report/en/>
- Armstrong DG, Boulton AJM, Bus SA. Diabetic foot ulcers and their recurrence. *N Engl J Med* 2017;376(24):2367–2375
- Skrepnek GH, Mills JL Sr, Lavery LA, Armstrong DG. Health care service and outcomes among an estimated 6.7 million ambulatory care diabetic foot cases in the U.S. *Diabetes Care* 2017;40(07):936–942
- Zhang Y, Lazzarini PA, McPhail SM, van Netten JJ, Armstrong DG, Pacella RE. Global disability burdens of diabetes-related lower-extremity complications in 1990 and 2016. *Diabetes Care* 2020;43(05):964–974
- Lazzarini PA, Pacella RE, Armstrong DG, van Netten JJ. Diabetes-related lower-extremity complications are a leading cause of the global burden of disability. *Diabet Med* 2018;35:1297–1299
- Pecoraro RE, Reiber GE, Burgess EM. Pathways to diabetic limb amputation. Basis for prevention. *Diabetes Care* 1990;13(05):513–521
- Birke JA, Franks BD, Foto JG. First ray joint limitation, pressure, and ulceration of the first metatarsal head in diabetes mellitus. *Foot Ankle Int* 1995;16(05):277–284
- Boulton AJM. Peripheral neuropathy and the diabetic foot. *Foot* 1992;2:67–72
- Balakrishnan TM, Pakkiri S, Nagalingam A, Selvaraj R, Jaganmohan J. Distally based pedicled fibula flap for reconstruction of infected Charcot's midtarsal collapse-diabetic rocker bottom foot. *Indian J Plast Surg* 2021;54(01):20–28
- Sabapathy SR, Periasamy M. Healing ulcers and preventing their recurrences in the diabetic foot. *Indian J Plast Surg* 2016;49(03):302–313
- Oyibo SO, Jude EB, Tarawneh I, Nguyen HC, Harkless LB, Boulton AJM. A comparison of two diabetic foot ulcer classification systems: the Wagner and the University of Texas wound classification systems. *Diabetes Care* 2001;24(01):84–88
- Bowker JH, Pfeifer MA. Levin and O'Neal's *The Diabetic Foot*. China: Mosby Elsevier; 2008:33–75
- Jeffcoate WJ, Harding KG. Diabetic foot ulcers. *Lancet* 2003;361(9368):1545–1551
- McInnes A. Footwear – the Achilles heel of diabetic foot care. *Diabet Foot J* 2003;4:56–60
- Apelqvist J, Larsson J, Agardh CD. Long-term prognosis for diabetic patients with foot ulcers. *J Intern Med* 1993;233(06):485–491
- Armstrong DG, Swerdlow MA, Armstrong AA, Conte MS, Padula WV, Bus SA. Five year mortality and direct costs of care for people with diabetic foot complications are comparable to cancer. *J Foot Ankle Res* 2020;13(01):16

- 22 Pound N, Chipchase S, Treece K, Game F, Jeffcoate W. Ulcer-free survival following management of foot ulcers in diabetes. *Diabet Med* 2005;22(10):1306–1309
- 23 Jupiter DC, Thorud JC, Buckley CJ, Shibuya N. The impact of foot ulceration and amputation on mortality in diabetic patients. I: from ulceration to death, a systematic review. *Int Wound J* 2016;13(05):892–903
- 24 Kerr M, Rayman G, Jeffcoate WJ. Cost of diabetic foot disease to the National Health Service in England. *Diabet Med* 2014;31(12):1498–1504
- 25 IWGDF guidelines on the prevention and management of diabetic foot disease (2019). Accessed March 27, 2022 <https://iwgdfguidelines.org>
- 26 Willrich A, Angirasa AK, Sage RA. Percutaneous tendo Achillis lengthening to promote healing of diabetic plantar foot ulceration. *J Am Podiatr Med Assoc* 2005;95(03):281–284
- 27 Dayer R, Assal M. Chronic diabetic ulcers under the first metatarsal head treated by staged tendon balancing: a prospective cohort study. *J Bone Joint Surg Br* 2009;91(04):487–493
- 28 Delbridge L, Ctercteko G, Fowler C, Reeve TS, Le Quesne LP. The aetiology of diabetic neuropathic ulceration of the foot. *Br J Surg* 1985;72(01):1–6
- 29 Faris I. Foot lesions in diabetic patients: pathogenesis and management. *Med J Aust* 1977;1(17):628–633
- 30 Katsilambros N, Tentolouris N, Tsapogas P, Dounis E. Atlas of the diabetic foot. Chichester: John Wiley & Sons Ltd; 2003
- 31 Robertson DD, Mueller MJ, Smith KE, Commean PK, Pilgram T, Johnson JE. Structural changes in the forefoot of individuals with diabetes and a prior plantar ulcer. *J Bone Joint Surg Am* 2002;84(08):1395–1404