



# Current Update in Asian Rhinoplasty

Clyde H. Ishii, MD, FACS

**Summary:** There has been a tremendous growth of cosmetic surgery among Asians worldwide. Rhinoplasty is second only to blepharoplasty in terms of popularity among Asians regarding cosmetic surgical procedures. Most Asians seek to improve their appearance while maintaining the essential features of their ethnicity. There are considerable ethnic nasal and facial variations in this population alone. Successful rhinoplasty in Asians must take into account underlying anatomic differences between Asians and whites. Due to ethnic variations, cultural differences, and occasional language barriers, careful preoperative counseling is necessary to align the patient's expectations with the limitations of the procedure. This article will review the many facets of Asian rhinoplasty as it is practiced today. (*Plast Reconstr Surg Glob Open* 2014;2:e133; doi: 10.1097/GOX.000000000000081; Published online 11 April 2014.)

Cosmetic surgery is very popular in certain parts of Asia and is becoming much more accepted by Asians in other continents as well. The tremendous growth of cosmetic surgery in the Asian population is largely due to Western influence and the strength of native economies along with globalization. Rhinoplasty and blepharoplasty are two of the most common cosmetic surgical procedures among Asians.<sup>1</sup> Since the first report of rhinoplasty in Asians by Khoo<sup>2</sup> in 1964, the popularity of this operation has skyrocketed and many technical refinements have occurred. This article will review various facets of Asian rhinoplasty as it is practiced today.

Asia is the largest of the continents and has numerous ethnic groups.<sup>1</sup> More than half of the world's population resides in Asia. Although many countries use the term "Asian" referring to people living on

that continent, in reality, Asian usually refers to people of East, Southeast, and South Asia. Inhabitants of Southwest Asia, such as Arabs and Iranians, are more commonly designated Middle Easterners.<sup>3</sup> The term Asian as used in this article refers to people from Asia who have a Mongoloid background (Chinese, Japanese, Koreans, Vietnamese, Filipinos, Indonesians, and others).

Asians tend to be stereotyped, especially by Westerners, as people with thick yellow skin, black hair, a wide nose with a low dorsum, and narrow puffy eyes.<sup>4</sup> However, considerable ethnic nasal and facial variations exist among the people of Asia. For instance, people of Japanese ancestry tend to have noses with adequate dorsal height, angularity, and even dorsal convexity, whereas Chinese noses tend to be flatter with minimal projection.<sup>5,6</sup> Migration of people with marriage between races has also resulted in further ethnic variations. Therefore, each Asian patient undergoing rhinoplasty must be properly evaluated as the vital components for a successful outcome will vary from patient to patient.

The Asian concept of beauty has changed over the years largely due to the influence of Western culture.<sup>1</sup> Many females, especially in East Asia, seek larger eyes, a higher nose with more definition, and a smaller face. However, they still want to preserve their ethnic identity by refining their Asian features

*From the Department of Surgery, University of Hawaii John A. Burns School of Medicine, Honolulu, Hawaii.*

*Received for publication November 19, 2014; accepted February 11, 2014.*

*Copyright © 2014 The Authors. Published by Lippincott Williams & Wilkins on behalf of The American Society of Plastic Surgeons. PRS Global Open is a publication of the American Society of Plastic Surgeons. This is an open-access article distributed under the terms of the Creative Commons Attribution-NonCommercial-NoDerivatives 3.0 License, where it is permissible to download and share the work provided it is properly cited. The work cannot be changed in any way or used commercially.*

DOI: 10.1097/GOX.000000000000081

**Disclosure:** *The authors have no financial interest to declare in relation to the content of this article. The Article Processing Charge was waived at the discretion of the Editor-in-Chief.*

rather than totally Westernizing their appearance.<sup>7,8</sup> Therefore, surgeons performing Asian rhinoplasty must seek to deliver the ideals of this procedure while still maintaining the essential features of each ethnic group.

### **NASAL ANATOMIC DIFFERENCES BETWEEN ASIANS AND WHITES**

Although there are anatomic variations among different Asian populations, most Asians have noses with thicker skin and a lower dorsum. Their nasal bones tend to be smaller in height and width compared with that of whites.<sup>1,9</sup> The Asian nasal tip is usually underprojected and lacking in definition due to abundant fibrofatty tissue, weaker lower lateral cartilages, and a short columella. The nasolabial angle tends to be acute due to a retracted columella and premaxillary hypoplasia. The alar lobules are thick, and the alar bases are usually wide.<sup>7</sup> Finally, the radix in Asians usually is lower compared with that in whites.<sup>10</sup>

### **DIFFERENCES IN RHINOPLASTY BETWEEN ASIANS AND WHITES**

Although some Asians are candidates for a classic reduction rhinoplasty, the underlying anatomic differences dictate that the goals of rhinoplasty in most Asians are different from those in whites.<sup>4</sup> The key components in most Asian rhinoplasties are augmentation of the nasal dorsum and tip.<sup>1</sup> Each patient seeks a different degree of nasal "refinement." Therefore, the preoperative consultation is vital for the surgeon to properly understand the patient's vision of the final result. Sometimes, there may be a language barrier which further complicates the matter. Finally, many Asians may be reluctant to overtly state their wishes as this may be in conflict with their cultural beliefs. To fully understand the patient's desires, many experienced surgeons ask the patient to bring in photographs of models or refer to their own collection of preoperative and postoperative photographs. Computer imaging may also aid communication.

### **ASIAN RHINOPLASTY: CHALLENGES AND SURGICAL APPROACHES**

#### **Low Nasal Dorsum**

For Asian patients with a low nasal dorsum, there is consensus that dorsal augmentation is necessary. However, the augmentation method remains controversial and for most part is geographically related.<sup>4</sup> Worldwide, silicone implants or some other type of alloplastic material is used in the majority of Asian rhinoplasties. This is due to the fact that most Asian

rhinoplasties are performed in Asia and with rare exceptions, surgeons in Asia feel most comfortable using alloplasts for dorsal augmentation. In the West, most surgeons prefer autogenous augmentation and shun alloplastic materials in the nose due to its associated complications (infection, displacement, extrusion, and capsular contracture). Although complications are less common with autografts, many proponents of alloplastic augmentation have been able to produce favorable results with an acceptable complication rate by modifying their technique and careful patient selection. They further cite the downside of autogenous augmentation (limited donor material, donor site morbidity, increased operative time, resorption, and warping).<sup>11</sup>

#### **Alloplasts**

Alloplastic materials for dorsal augmentation include silicone, expanded polytetrafluoroethylene (PTFE), and porous polyethylene (Medpor).<sup>7,10,11</sup> As previously noted, silicone is the most widely used nasal augmentation material in Asia. Silicone's popularity is due to its ease of use, relatively low cost, minimal operative time, and absence of donor site morbidity.<sup>12</sup> Also, many surgeons find that dorsal augmentation with silicone implants produces a superior aesthetic result when compared with readily available septal or conchal cartilage. Advocates of silicone note that the incidence of complications with this material can be lowered by using newer versions of the implant which are softer and less excessive in size than earlier implants.<sup>4</sup> In addition, complications such as translucency and extrusion are usually less common in most Asians as their skin is thicker. Silicone nasal implants come in 2 shapes: L-shaped and straight<sup>1,12</sup> (Fig. 1). Although L-shaped implants provide both dorsal and tip augmentation, this type of implant is more commonly associated with pressure necrosis and extrusion at the tip area. Therefore, many surgeons prefer using a straight silicone implant to augment only the dorsum. The tip is then augmented using septal and/or conchal cartilage<sup>1</sup> (Fig. 2).

Expanded PTFE is the second most commonly used alloplastic implant in Asian rhinoplasty.<sup>10</sup> PTFE is supplied in sheets and must be carved before implantation. As each sheet is thinner than a silicone implant, major augmentations require stacking of PTFE sheets.<sup>12</sup> Due to its porous nature, PTFE allows tissue ingrowth, which may result in greater stability and less likelihood of forming capsular contractures. However, this porous nature makes removal of the implant more difficult and potentially more prone to infection.<sup>10</sup> Porous polyethylene (Medpor) has also been used for dorsal augmentation.<sup>11,13</sup> Like



**Fig. 1.** Straight and L-shaped silicone nasal implants. Reprinted with permission from Jang YJ. Asian rhinoplasty. In: Papel ID, Frodel JL, Holt GR, eds. *Facial Plastic and Reconstructive Surgery*. 3rd ed. New York: Thieme Medical Publishers; 2009:619–637.

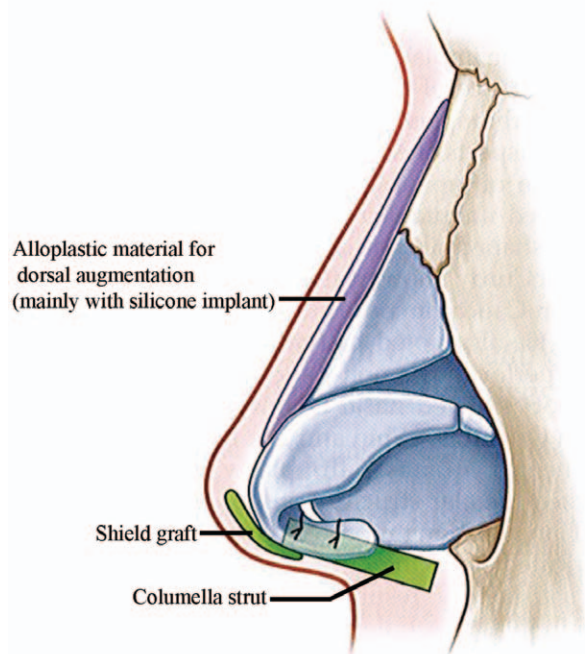
PTFE, removal of the implant may be difficult especially when complicated by infection.<sup>14</sup>

### Homografts

Many surgeons have used cadaver costal cartilage for dorsal augmentation because it is readily available and without donor site morbidity or additional operative time.<sup>10,15</sup> However, warping is still a problem even when balanced cross-sections are used.<sup>16</sup> Finally, graft resorption remains a significant problem making this tissue very unpredictable.<sup>10,15–18</sup> Perhaps, this homograft may have a place in revision cases where the augmentation needs are great, patients are reluctant to use their own costal cartilage, and the surgeon is not experienced in other autograft techniques.

### Autografts

For dorsal nasal augmentation, many surgeons feel that autografts hold distinct advantages over other materials provided one takes into account tissue availability, donor site morbidity, possible additional operative time, and surgeon experience. Autografts are well tolerated by the body and have been shown to survive long term. Finally, when compared with other materials, autografts have the lowest risk of infection.<sup>10,19</sup> Autologous cartilage may be obtained from the septum, conchae, or rib. Septal cartilage is often used when only a minor dorsal augmentation is needed. The supply is limited as the cartilage por-



**Fig. 2.** Two piece augmentation rhinoplasty. Reprinted with permission from Koh SK, Choi JW, Ishii CH. Asian facial cosmetic surgery. In: Neligan PC, ed. *Plastic Surgery*. Vol. 2, 3rd ed. London: Elsevier; 2013:163–183.

tion of the septum in Asians tends to be smaller than that in whites.<sup>7</sup> Also, an adequate amount of septal cartilage may not be available in secondary cases.<sup>10,20</sup> Like septal cartilage, conchal cartilage may be used for minimal dorsal augmentation cases.<sup>21</sup> The curved conchal cartilage must be modified to fit the nasal dorsum. Conchal cartilage is more commonly used to augment the nasal tip.

For most Asian rhinoplasties, the tissue requirements for dorsal augmentation exceed the volume and strength of septal or conchal cartilage. Therefore, one must resort to using the patient's costal cartilage if autogenous cartilage is preferred. Many patients are reluctant to use their own costal cartilage due to the additional scar and other issues regarding the donor site. If this objection is not an issue, then one must take into account the additional operative time and carving techniques involved. Because warping of the graft can still occur even when concentric carving or laminated cartilage is employed, some surgeons utilize internal K-wires to stabilize the graft.<sup>17,22</sup>

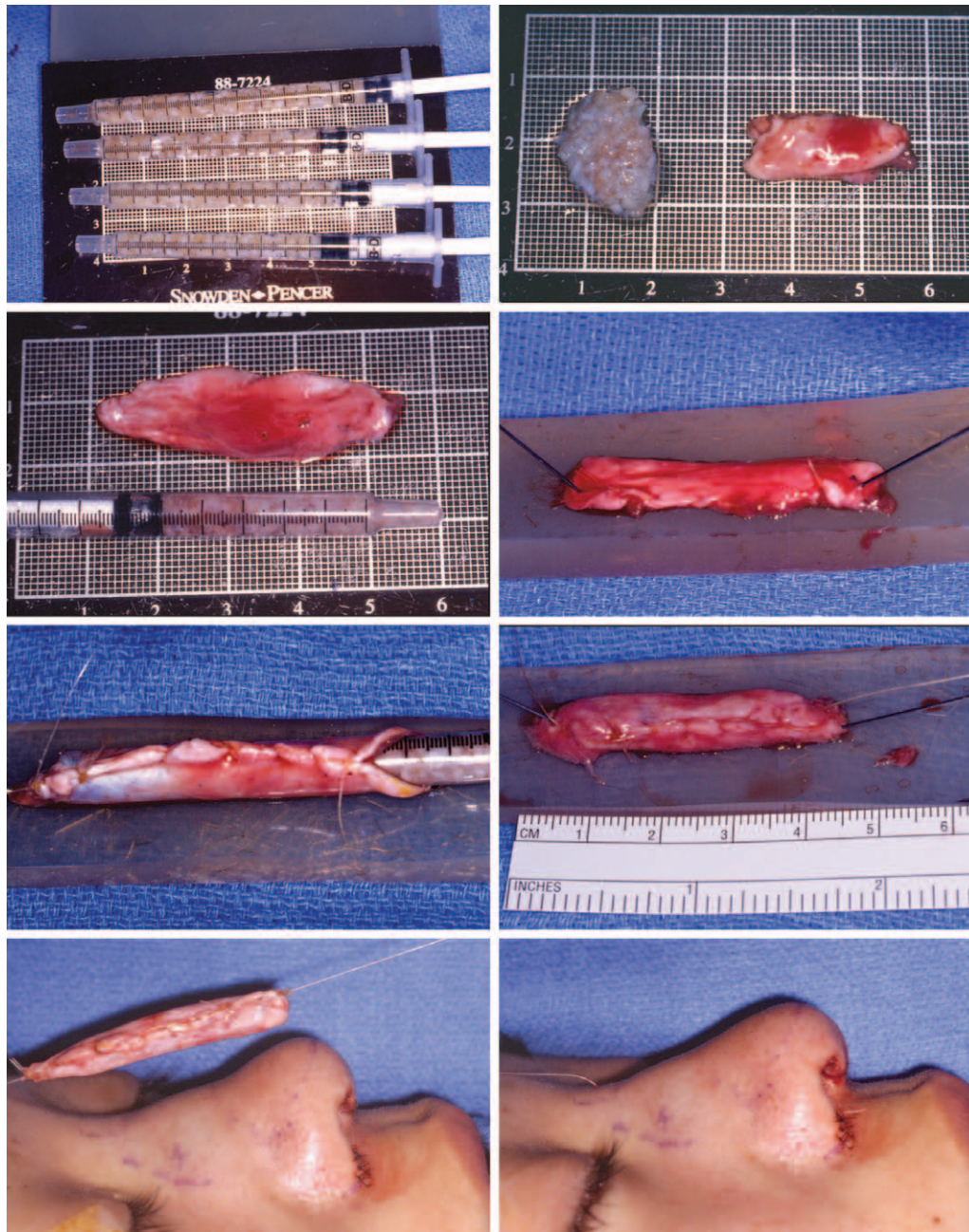
Temporalis fascia and fascia lata have been used for patients with minor dorsal augmentation needs. This tissue is also useful to salvage the nasal dorsum in cases of failed alloplastic materials.<sup>10</sup> In recent years, temporalis fascia has been used in combination with diced cartilage to augment the nasal dor-

sum.<sup>19,23-25</sup> Autologous cartilage (septal, conchal, costal) is diced into 0.5- to 1-mm cubes and loaded into a fashioned tube of fascia. This construct is then used as a dorsal onlay graft<sup>26</sup> (Fig. 3). Histologic studies have confirmed the long-term survival of diced cartilage.<sup>27,28</sup> Diced cartilage can also be used without fascia to fill in smaller defects and for minor dorsal augmentations.<sup>25,29</sup>

Split calvarial bone and bone from other anatomic regions have been used to augment the nose.<sup>30</sup>

Although long-term survival is good, the associated donor site morbidity has made these grafts less popular than other autografts.

As noted above, a variety of implants and tissues have been used to augment the nasal dorsum, and each has its own limitations, advantages, and disadvantages. The aesthetic goal must be balanced against the risks of using any particular implant/graft. History has taught us that complications are likely to occur when large alloplasts of any type are placed under



**Fig. 3.** Diced cartilage covered with fascia. Reprinted with permission from Daniel RK. Diced cartilage grafts in rhinoplasty surgery: current techniques and applications. *Plast Reconstr Surg.* 2008;122:1883-1891.

thin tissues. When performing dorsal augmentation, one must first determine the amount of augmentation that is needed to achieve the desired end result. Placing a straight edge which extends from the patient's lash line to the supratip will reveal the underlying gap to the native dorsum.<sup>9,29</sup> For up to a 2- to 3-mm augmentation, septal cartilage with or without stacking, diced cartilage alone, or possibly thickened fascia may suffice. Augmentations of 3–5 mm necessitate the use of an alloplasts, diced cartilage in fascia, or costal cartilage. Autografts are safer for patients with thin skin. Autogenous costal cartilage is preferred for augmentations greater than 5 mm. Finally, autografts should be considered in all secondary cases and any case involving a failed implant.

#### Underprojection of the Nasal Tip

The tip of the Asian nose tends to be underprojected and lacking in definition due to weaker lower lateral cartilages, a short columella, and abundant fibrofatty tissue. The usual maneuvers that are successful in improving nasal tip projection in whites are far less effective in Asians. The underlying supporting structures simply do not have the strength to provide projection and definition through the overlying thick tissue. Therefore, improvement in tip projection requires adding structural support by way of cartilage grafts.<sup>4,29</sup> Columella struts combined with tip cartilage grafts from the septum or concha can provide such needed support<sup>8</sup> (Figs. 4, 5). The addition of lateral crural strut grafts can further strengthen the cartilaginous framework.<sup>7,14</sup>

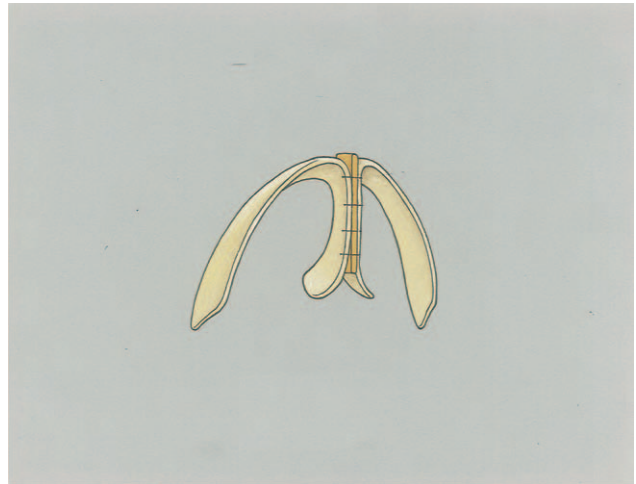#### The Bulbous Nose

The typical Asian nose is bulbous, is flat, and lacks angularity or definition.


Thick skin is very limiting even when the cartilaginous support is bolstered. Many surgeons recommend defatting the tip skin by dissecting in the subdermal plane and then removing the fat that is adherent to the alar cartilages.<sup>14</sup> The patient must be informed preoperatively that prolonged swelling of the tip may occur with such defatting.<sup>8</sup>

#### Radix Augmentation

In addition to concerns about a low nasal dorsum and underprojected tip, many Asians are also bothered by flatness in the radix area. The radix can be augmented using a variety of tissues, including fascia, conchal cartilage, and diced cartilage with or without fascia. Before proceeding with radix augmentation, one needs to assess the patient's nasofrontal angle and determine the correct location of the nasion as surgery on the radix may affect the nasion level.<sup>10,14</sup>



**Fig. 4.** Columella strut. Reprinted with permission from Matory WE, ed. *Ethnic Considerations in Facial Aesthetic Surgery*. Philadelphia: Lipincott-Raven; 1998. Color images provided courtesy of Dr. Marco Rizzo.



**Fig. 5.** Columella strut and tip shield grafts. Reprinted with permission from Matory WE, ed. *Ethnic Considerations in Facial Aesthetic Surgery*. Philadelphia: Lipincott-Raven; 1998. Color images provided courtesy of Dr. Marco Rizzo.

#### Osteotomy

Osteotomies are commonly performed as part of the standard reduction rhinoplasty in whites. Osteotomies may be needed in Asians if bony deviation is noted or if the dorsum is too wide and dorsal augmentation is not required. However, if the bony dorsum is free of deviation and dorsal augmentation is planned, then osteotomies may not be necessary as the bony base should be wider than the dorsal graft.<sup>7</sup> Also, imprudent use of osteotomies may result in relative overnarrowing of the bony base thereby making the wide Asian face appear even wider.<sup>5</sup>

### Dorsal Hump Reduction

Although dorsal augmentation is necessary in most Asian rhinoplasties, this is not always the case. In fact, some Asians actually have a convex dorsum and may benefit from dorsal reduction with or without tip augmentation.<sup>4,10</sup> On the other hand, there are patients who have a dorsal hump but still need dorsal augmentation. In this latter group of patients, failure to remove the dorsal hump may result in a rocker-like instability of the dorsal graft or implant.<sup>31</sup>

### Alar Base Surgery

Modification of the alar base should be done selectively in patients undergoing Asian rhinoplasty. The benefits of alar base surgery must be balanced against the possibility of prominent scars and asymmetry. Furthermore, augmentation of the nasal tip may in itself narrow or give the illusion of a narrower alar base. If needed, surgery on the alar base should be done after completion of any dorsal or nasal tip augmentation. The goal is to narrow the wide nasal alae, so they are closer in width to the nasal lobule and change the configuration of the nostril from round or a horizontal oval to one that is more vertical medially.<sup>14,32</sup> If the alar base appears wide for the patient's face, one needs to determine if there is alar flaring, wide nostrils, or a combination of these elements. Flaring of the alae accompanied by acceptable nostril configuration and size can be addressed by an inverted V or elliptical alar skin excision without extension into the sill. For best results, the incision should be made just above the alar crease.<sup>10,29</sup> For wide nostrils, nostril sill excision with extension of the incision to the alar crease is preferred.<sup>10</sup> Treatment of the patient who exhibits both alar flaring and wide nostrils involves a combination of sill and alar skin excision<sup>10,33</sup> (Fig. 6).

### Premaxillary Augmentation

The premaxillary area is hypoplastic in many Asians and this deficiency, along with a retracted

columella, often results in an acute nasolabial angle.<sup>4</sup> Mild and moderate degrees of premaxillary deficiency have been addressed with alloplasts or autografts of bone or cartilage. Major retrusion including those with associated malocclusion may necessitate orthognathic surgery.<sup>4</sup>

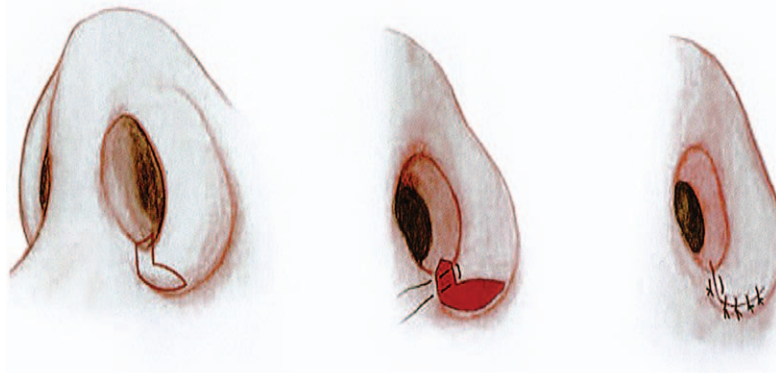
### Postoperative Management

Except for a few differences, postoperative care of the Asian rhinoplasty patient is similar to that for whites undergoing rhinoplasty. Most patients are placed on oral antibiotics for up to a week following surgery. Nasal packing of the petrolatum gauze variety is usually removed on the first postoperative day. If internal silicone splints are used instead of nasal packing, then these splints may be left in place for 4–7 days. The dorsal splint and skin sutures are removed about 1 week after surgery. Diced cartilage with or without fascia may be molded in the first several weeks following surgery.<sup>14</sup> Prolonged swelling may occur especially if the tip has been defatted. Taping of the nose for 4–6 weeks is often used for edema control.<sup>6,14</sup> Patients must have realistic expectations to avoid postoperative disappointment. As noted earlier, proper preoperative counseling is vital.

Revisions are occasionally needed but should be delayed for many months to allow for adequate healing.<sup>6</sup> On occasion, revisions may be performed earlier if the surgeon feels that the revision is straightforward and the likelihood of success is high.

### Complications

A discussion of Asian rhinoplasty complications can be broken down into 2 categories: (1) complications generic to all Asian patients undergoing rhinoplasty and (2) complications directly related to silicone implants. Asian patients undergoing rhinoplasty are more prone to hyperpigmentation, hypertrophic scarring, and prolonged edema than their



**Fig. 6.** Combined sill/alar excision. Reprinted with permission from Jang YJ. Asian rhinoplasty. In: Papel ID, Frodel JL, Holt GR, eds. *Facial Plastic and Reconstructive Surgery*. 3rd ed. New York: Thieme Medical Publishers; 2009:619–637.

white counterparts. Preoperatively, patients must be informed of these risks along with risks specific to the procedure. Although the nasal skin is quite thick in most Asians, graft visibility may be a problem. In addition, asymmetry involving the dorsum, alae, or nostrils may occur. Finally, the possibility of infection, autograft resorption, and problems related to the donor site should be discussed with the patient before surgery.

Technical refinements have occurred with regard to surgery involving silicone nasal implants. However, these implants still carry a higher risk of major complications compared with autografts. One large study involving silicone implants in Asian rhinoplasties revealed a 16% complication rate including infection in 5.3% of cases and an extrusion rate of 2.8%.<sup>12</sup> Other complications related to silicone implants include translucency, mobility, displacement, capsular contracture, skin discoloration, and calcification.<sup>1,4,29,34</sup> It appears that most of problems involving silicone implants are due to excessive implant size and improper placement of the implant. Although some silicone implants involved with infection may be salvaged with antibiotic therapy, many such cases eventually require implant removal. Following removal of the implant, most surgeons recommend either a delayed insertion of the implant 3–6 months later or immediate replacement of the implant with an autograft.<sup>1,4,10,29</sup>

## CONCLUSION

Asian rhinoplasty remains a very popular procedure and has undergone numerous technical refinements over the years. Due to underlying anatomic differences the goals of rhinoplasty in most Asians are different from those in whites. Although there are exceptions, most Asian rhinoplasties require some augmentation of the nasal dorsum and tip. Because each patient seeks a different degree of nasal refinement, careful preoperative consultation is needed to understand the patient's vision of the final result and discuss the surgical goals as well as the limitations of the procedure.

Clyde H. Ishii, MD, FACS

1329 Lusitana Street  
Suite 304  
Honolulu  
HI 96813

E-mail: cishii@ishiiplasticsurgery.com

## REFERENCES

1. Koh SK, Choi JW, Ishii CH. Asian facial cosmetic surgery. In: Neligan PC, ed. *Plastic Surgery*. Vol. 2, 3rd ed. London: Elsevier; 2013:163–183.
2. Khoo BC. Augmentation rhinoplasty in the orientals. *Plast Reconstr Surg*. 1964;34:81–88.
3. *The American Heritage Dictionary*. 2009. Available at: <http://www.thefreedictionary.com/Asian>. Accessed October 15, 2013.
4. McCurdy JA, Lam SM. *Cosmetic Surgery of the Asian Face*. 2nd ed. New York: Thieme Medical Publishers; 2005.
5. Shirakabe Y, Suzuki Y, Lam SM. A systematic approach to rhinoplasty of the Japanese nose: a thirty-year experience. *Aesthetic Plast Surg*. 2003;27:221–231.
6. Hoefflin SM. *Ethnic Rhinoplasty*. New York: Springer; 1998.
7. Toriumi DM, Pero CD. Asian rhinoplasty. *Clin Plast Surg*. 2010;37:335–352.
8. Matory WE, ed. *Ethnic Considerations in Facial Aesthetic Surgery*. Philadelphia: Lipincott-Raven; 1998.
9. Zingaro EA, Falces E. Aesthetic anatomy of the non-Caucasian nose. *Clin Plast Surg*. 1987;14:749–765.
10. Jang YJ. Asian rhinoplasty. In: Papel ID, Frodel JL, Holt GR, eds. *Facial Plastic and Reconstructive Surgery*. 3rd ed. New York: Thieme Medical Publishers; 2009: 619–637.
11. Karnes J, Salisbury M, Schaeferle M, et al. Porpus high-density polyethylene implants (Medpor) for nasal dorsum augmentation. *Aesthet Surg J*. 2000;20:26–30.
12. Bergeron L, Chen PK. Asian rhinoplasty techniques. *Semin Plast Surg*. 2009;23:16–21.
13. Scalfani AP, Romo T. Alloplasts for nasal augmentation. *Facial Plast Surg Clin North Am*. 1999;7:43–54.
14. Kim EK, Daniel RK. Operative techniques in Asian rhinoplasty. *Aesthet Surg J*. 2012;32:1018–1030.
15. Velidedeoğlu H, Demir Z, Sahin U, et al. Block and Surgicel-wrapped diced solvent-preserved costal cartilage homograft application for nasal augmentation. *Plast Reconstr Surg*. 2005;115:2081–2093; discussion 2094.
16. Adams WP Jr, Rohrich RJ, Gunter JP, et al. The rate of warping in irradiated and nonirradiated homograft rib cartilage: a controlled comparison and clinical implications. *Plast Reconstr Surg*. 1999;103:265–270.
17. Toriumi DM. Discussion: use of autologous costal cartilage in Asian rhinoplasty. *Plast Reconstr Surg*. 2012;130: 1349–1350.
18. Welling DB, Maves MD, Schuller DE, et al. Irradiated homologous cartilage grafts. Long-term results. *Arch Otolaryngol Head Neck Surg*. 1988;114:291–295.
19. Daniel RK, Calvert JW. Diced cartilage grafts in rhinoplasty surgery. *Plast Reconstr Surg*. 2004;113:2156–2171.
20. Jung DH, Choi SH, Moon HJ, et al. A cadaveric analysis of the ideal costal cartilage graft for Asian rhinoplasty. *Plast Reconstr Surg*. 2004;114:545–550.
21. Endo T, Nakayama Y, Ito Y. Augmentation rhinoplasty: observations on 1200 cases. *Plast Reconstr Surg*. 1991;87: 54–59.
22. Gunter JP, Clark CP, Friedman RM. Internal stabilization of autogenous rib cartilage grafts in rhinoplasty: a barrier to cartilage warping. *Plast Reconstr Surg*. 1997;100: 161–169.
23. Yilmaz S. Diced cartilage grafts in rhinoplasty. *Plast Reconstr Surg*. 2005;116:678.
24. Daniel RK. The role of diced cartilage grafts in rhinoplasty. *Aesthet Surg J*. 2006;26:209–213.
25. Calvert J, Brenner K. Autogenous dorsal reconstruction: maximizing the utility of diced cartilage and fascia. *Semin Plast Surg*. 2008;22:110–119.
26. Daniel RK. Diced cartilage grafts in rhinoplasty surgery: current techniques and applications. *Plast Reconstr Surg*. 2008;122:1883–1891.

27. Brenner KA, McConnell MP, Evans GR, et al. Survival of diced cartilage grafts: an experimental study. *Plast Reconstr Surg*. 2006;117:105–115.
28. Calvert JW, Brenner K, DaCosta-Iyer M, et al. Histological analysis of human diced cartilage grafts. *Plast Reconstr Surg*. 2006;118:230–236.
29. Lee CS. Asian rhinoplasty treatment and management. Medscape emedicine. Available at: <http://emedicine.medscape.com/article/1293426-treatment>. Accessed September 17, 2013.
30. Parsa FD. Nasal augmentation with split calvarial grafts in Orientals. *Plast Reconstr Surg*. 1991;87:245–253.
31. Lam SM, Kim YK. Augmentation rhinoplasty of the Asian nose with the “bird” silicone implant. *Ann Plast Surg*. 2003;51:249–256.
32. Lam SM. Asian rhinoplasty. *Semin Plast Surg*. 2009;23:215–222.
33. Daniel RK. *Mastering Rhinoplasty*. London, England: Springer; 2010.
34. Jung DH, Kim BR, Choi JY, et al. Gross and pathologic analysis of long-term silicone implants inserted into the human body for augmentation rhinoplasty: 221 revision cases. *Plast Reconstr Surg*. 2007;120:1997–2003.