

# Clinical evaluation of “componeers” and direct composite veneers using minimally invasive enamel preparation technique: *In vivo* study

Parag Dua, Sanjay Manohar Londhe<sup>1</sup>, Gaurav Dua<sup>2</sup>, Atul Kotwal<sup>3</sup>, Sachin Gupta<sup>4</sup>

Division of Prosthodontics, AFMC, Pune, Maharashtra, <sup>1</sup>Division of Orthodontics, ADC (Research and Referral), Delhi, <sup>2</sup>Dental Centre, Bhatinda, Punjab, <sup>3</sup>Department of Community Medicine, ACMS, Delhi, <sup>4</sup>Dental Centre, Amritsar, Punjab, India

## Abstract

**Aim:** The aim of this study was to evaluate the clinical behavior of prefabricated componeers and direct composite veneering. The objective of the study was to compare the changes in color, surface texture, marginal integrity, and gingival response for componeers and direct composite veneers.

**Settings and Study Design:** This was an *in vivo*, comparative study.

**Materials and Methods:** Ten patients indicated for anterior veneers were selected and divided into Groups A and B of five patients each. Group A was restored with componeers and Group B with direct composite veneers. Both the groups were compared for color changes, surface textural changes, marginal integrity, and gingival response, starting immediately post veneering and at 3, 6, 9, and 12 months subsequently.

**Statistical Analysis Used:** Friedman’s two-way analysis of variance and Mann–Whitney test were used for statistical analysis.

**Results:** Results for color ranged from excellent to good with minimal color changes post veneering. Overall, “gingival response,” in both the groups, showed statistically significant differences in mean rank scores ( $P \leq 0.05$ ). The data depicted an improvement in gingival response for all patients during the period of the study. Surface textural changes were significant only for maxillary right canine and maxillary left lateral incisor ( $P = 0.024$  and  $0.039$ , respectively) in both the groups. Maxillary right canine in both the groups showed significant changes in marginal integrity. Intergroup comparison of gingival response, surface texture, and marginal integrity depicted no significant difference between the groups ( $P > 0.05$ ).

**Conclusions:** This study concluded that the intergroup comparison of componeers and direct composite veneers for the parameters, gingival response, surface texture, and marginal integrity did not depict any significant differences. Both the groups displayed minimal changes in color, surface texture, and marginal integrity and improved gingival response.

**Keywords:** Color, componeers, gingival response, marginal integrity, surface texture

**Address for correspondence:** Dr Parag Dua, Dept of Dental Surgery, Div of Prosthodontics, Armed Forces Medical College, Pune - 411 040, Maharashtra, India. E-mail: duaparag@gmail.com

**Submitted:** 07-Mar-2020, **Revised:** 15-Sep-2020, **Accepted:** 25-Sep-2020, **Published:** 08-Oct-2020

Access this article online	
Quick Response Code:	Website: www.j-ips.org
	DOI: 10.4103/jips.jips_95_20

This is an open access journal, and articles are distributed under the terms of the Creative Commons Attribution-NonCommercial-ShareAlike 4.0 License, which allows others to remix, tweak, and build upon the work non-commercially, as long as appropriate credit is given and the new creations are licensed under the identical terms.

**For reprints contact:** reprints@medknow.com

**How to cite this article:** Dua P, Londhe SM, Dua G, Kotwal A, Gupta S. Clinical evaluation of “componeers” and direct composite veneers using minimally invasive enamel preparation technique: *In vivo* Study. J Indian Prosthodont Soc 2020;20:424-30.

## INTRODUCTION

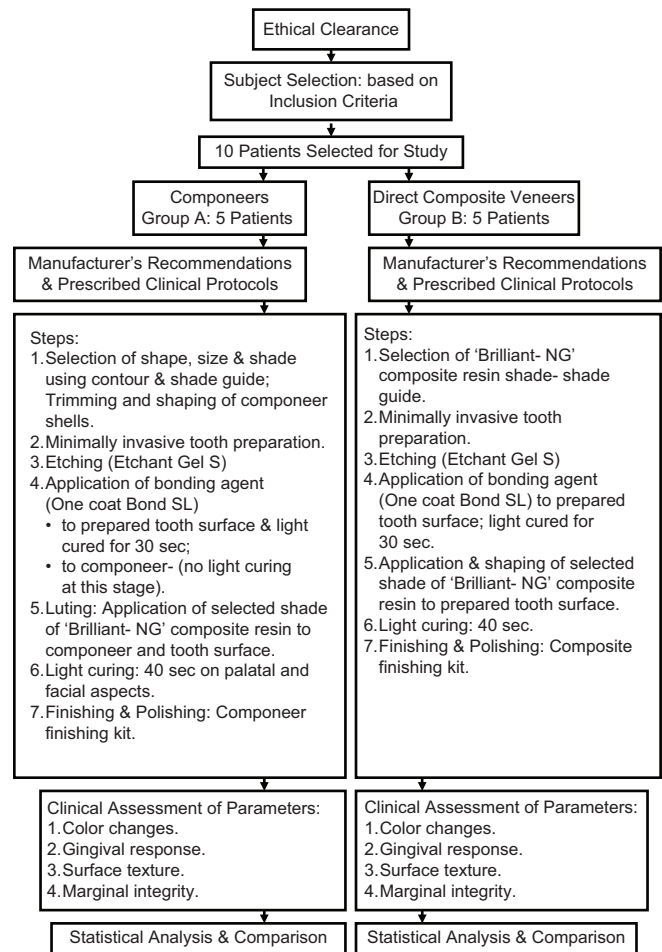
Conscious and educated demand for esthetics by the patients has led to development of esthetic restorations such as all ceramic veneers, crowns, inlays, and onlays. A parallel advancement in this sphere was the advent of new generation laboratory fabricated composite veneers (componeers) with improved wear resistance, toughness, and esthetics.<sup>[1,2]</sup> Recently introduced veneer manufacturing techniques such as laser vitrification and heat and pressure molding have rejuvenated the utility of these prefabricated composite veneers. They combine the esthetics of ceramic veneers and the bondability to tooth structure of composite veneers. They are not as expensive as ceramic veneers, require minimal equipment, and are repairable intraorally. They are cemented with the same composite resin they are made from, thus forming a “monobloc” restoration.<sup>[3]</sup> These are available as nanohybrid composite shells and have established themselves as more conservative veneering modality. Their clinical behavior had not been researched for essential characteristics such as color changes, surface texture, marginal integrity, and gingival response, and studies in this respect were scanty. These factors affect the longevity of the veneer and biologic response of surrounding periodontal structures.

The aim of this study was to evaluate the clinical behavior of componeers and its comparison with direct composite veneering. The objective of this study was to estimate and compare the changes in color, surface texture, marginal integrity, and gingival response for componeers and direct composite veneers. These clinical parameters were evaluated for a 1-year period starting immediately postoperative and at intervals of 3, 6, 9, and 12 months.

## MATERIALS AND METHODS

Brief summary of the methodology is depicted in Flow Chart 1. Subject participation was with informed consent and clearance was obtained from the institutional ethical committee for conducting the study (Letter no. 15965/52/09/2014/DG-3B, dated May 15, 2013).

Patients included in the study were between 25 and 50 years of age having good oral hygiene, requiring correction of malposed anterior teeth not indicated for extensive orthodontic treatment; traumatized anterior teeth correctable by veneers; nonvital discolored teeth with mismatched shade or fractured veneers or composite restorations; discolored teeth (tetracycline and fluorosis stains) and mild-to-moderate diastema correctable by veneering; and extended tooth dysplasia and hypoplasia. Individuals who were excluded



**Flow Chart 1:** Brief summary of methodology

from the study were those requiring extensive orthodontic treatment for correction of diastema, malalignment, and deep bite; severe untreated bruxism; active caries; and poor oral hygiene and chronic smokers.

Ten patients indicated for veneering of maxillary and mandibular anterior teeth were selected for the study after considering the inclusion and exclusion criteria. Parameters evaluated were color changes, gingival response, surface texture, and marginal integrity. The patients were randomly divided into Groups A and B consisting of five patients each. Group “A” patients were restored with componeers and Group “B” restored with direct composite veneering. In addition to routine instruments, the specific armamentarium included Williams’ periodontal probe and manual Vita shade guide; componeer shade and contour guide; componeer shells and blister packs [Figures 1 and 2]; componeer preparation and finishing kit; and “Brilliant-NG” composite resin.

Manufacturer’s recommendations and prescribed clinical protocols<sup>[4]</sup> were followed for both the veneering techniques.

Veneering was kept supragingival for both the groups. The shape, size, and shade of the componeers were customized using a contour guide, so as to match the contour and size of patient's existing teeth and cosmetic requirements. The contour guides were available in 36 different shapes and small, medium, large, and extra large sizes. The assessment was done by placing the contour guide over the tooth to be restored and assessing the mesiodistal and incisocervical fit [Figure 3]. The color of the guide was transparent blue, which enabled optimum contrast on the tooth. Facial aspect of componeers, being extremely thin (0.3 mm), was not altered. Only their proximal and cervical margins were minimally trimmed to custom fit the proximal and cervical aspects of the prepared tooth surface. The clinical performance of componeers in Group A and direct composite veneers in Group B was evaluated and compared for the aforementioned parameters at 0- (immediately post veneering) 3-, 6-, 9-, and 12-month interval. Figure 4a-d depicts a "Group A" case rehabilitated with componeers.



Figure 1: Nano-hybrid componeer shells

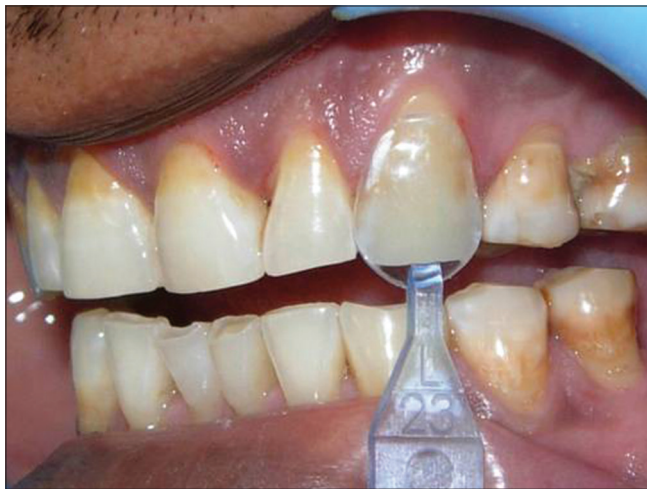

Figure 3: Assessment of mesiodistal and incisocervical fit of the componeer using the componeer contour guide

Figure 5a-d depicts a "Group B" case rehabilitated with direct composite veneers.

Color changes were assessed at baseline and at intervals of 3, 6, 9, and 12 months by the same clinician and in a clinical scenario where the patients were asked to opine on their acceptability of the color. The scales of evaluation were excellent, good, and satisfactory. Shade selection was done under natural broad daylight or fluorescent and incandescent light with the componeer shade guide. First, the dentin shade and then the enamel shade were determined. Tint selection was done keeping the eye-object distance approximately 30 cm and observation time maximum up to 5 s. The wetted componeer sample was held above or below the moist tooth surface in a gray-blue or a natural background. The comparison was repeated three times. Eye object distance was kept at approximately 60 cm for selecting the brightness. After selecting the base shade of enamel and dentin, the enamel guide was superimposed upon the dentin sample to confirm the correct shade selection. Patients' opinion and the clinician's judgment was primarily the basis for final shade selection.

Tooth preparation was minimally invasive for both the groups and in accordance with prescribed guidelines for

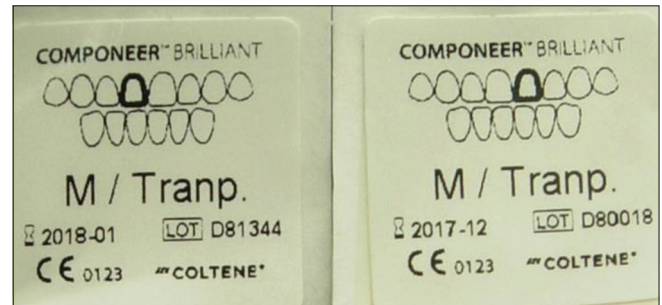

Figure 2: Componeer blister packs depicting the tooth number, size, and shade

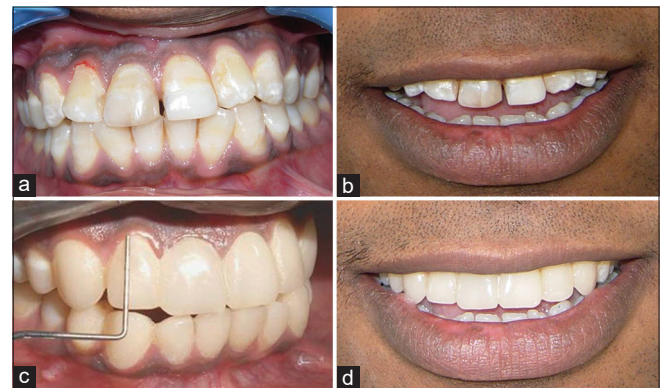
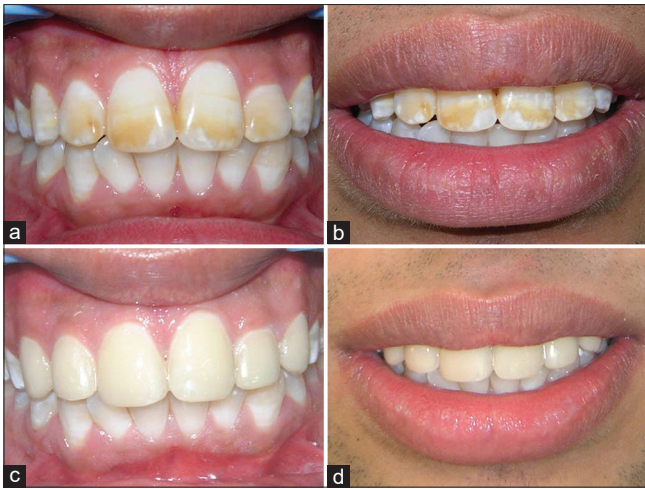
Figure 4: Group A – rehabilitation with componeers. (a) Preoperative intraoral labial view. (b) Preoperative extraoral labial view. (c) Postoperative clinical evaluation. (d) Postoperative extraoral labial view



**Figure 5:** Group B – patient rehabilitation with direct composite veneers. (a) Preoperative intraoral labial view. (b) Preoperative extraoral labial view. (c) Postoperative intraoral labial view. (d) Postoperative extraoral labial view

veneer preparation.<sup>[4,5]</sup> Etchant Gel S (phosphoric acid 35%) was applied to prepared tooth surface for 30–60 s, followed by water spray for 20 s. Excess water was removed with oil-free air. Interdental matrices were placed and “One Coat Bond SL” (single-component bonding agent) was applied to the prepared tooth, left for 20 s, blow dried with oil-free air, and light cured for 30 s. The same was applied on the contact side of the componeer also, left for 20 s, and blow dried with oil-free air but not light cured (to ensure wettability). The selected composite resin shade was applied with the “MB5” modeling instrument to the contact side of the componeer and to the tooth to prevent air inclusions. Componeer was positioned on the tooth under gentle pressure using a placer instrument. Excess material and interdental matrices were removed and light curing done for 40 s on palatal and facial aspects, respectively. Margins were trimmed with flame-shaped diamond points. Finishing and polishing strips were used for the proximal regions, flexible discs for incisal angles, and silicone rubber polishers for obtaining high gloss. Cervical margins were thoroughly polished to prevent plaque accumulation.

The Gingival Bleeding Index<sup>[6]</sup> was used to record the gingival response at three sites, i.e., mesiobuccal, midbuccal, and distobuccal areas of each tooth post veneering. It was recorded by gently probing the orifice of gingival crevice with Williams’ periodontal probe. A score of 0 was awarded for no bleeding on gentle probing and 1 for bleeding on gentle probing. Bleeding index was calculated for each tooth by dividing the total score at bleeding sites by three. Surface texture was evaluated by gently running an explorer on the veneered labial surface and visual examination after air-drying under the dental light. The tactile scores were

awarded as 0 for original gloss unchanged, 1 for moderate dullness in patches, 2 for whole surface moderate dullness, and 3 for very dull surface. Marginal integrity was assessed by running the explorer along the margins of the veneer down to the root surface. A score of 0 indicated no discernible catches, 1 for occasional slight catches, 2 for marked catches in a number of areas, and 3 for marked catches in almost all areas.

The parameters (gingival response, surface texture, and marginal integrity) were subjected to Friedman’s two-way analysis of variance. An  $\alpha$ -level of  $\leq 0.05$  was used to be able to state that the two groups were significantly different from each other. Further, to compare intergroup parameters, Group A and B variables were subjected to Mann–Whitney test.

## RESULTS

The distribution of participants is depicted in Table 1. The results of statistical analysis, comparing the mean ranks of the parameters (of Groups A and B), are depicted in Table 2. Among the color changes, two cases showed discoloration. In the first case (from Group A), a spot discoloration was observed on the maxillary right lateral incisor after 3 months. The componeer was replaced by a new one. In the second case (from Group B), a mild stain was visible at 6-month evaluation. This was corrected by re-veneering with direct composite resin. No further change of color was observed during the study. Patients of both the groups exhibited excellent-to-good responses with minimal color changes post veneering.

For the parameter of gingival response [Tables 2 and 3] for both the groups, the pre- and postresults in case of all maxillary and mandibular anterior teeth showed statistically significant differences in mean rank scores ( $P \leq 0.05$ ) for the stipulated time intervals, except for maxillary right central incisor ( $P = 0.255$ ). Overall, this parameter exhibited the most significant changes for both maxillary and mandibular teeth. For Group A, the scores ranged from 0 to 1 and that too for the initial baseline period and decreased back to 0 by the end of 3 months. This was due to improved gingival response. In case of maxillary teeth, statistically significant changes in gingival response were observed starting from the baseline period. Their gingival response also reduced from 1 to 0 till the end of 12 months. Comparatively, more statistically significant changes were observed in the mandibular anterior teeth. The gingival response in all mandibular anterior teeth gradually reduced to 0 over the stipulated period of evaluation. The data on gingival response depicted a vast improvement in the

**Table 1: Distribution of study teeth and evaluation parameters**

Evaluation parameters	Group A	Group B	Total
Number of patients (random selection)	5	5	10
Distribution of study teeth	60	60	120
3←1 1→3			
3←1 1→3			
Number of veneers placed	60	60	120
Veneering techniques	Prefabricated veneers	Direct composite veneering	2
Restorative material used	Componeer	Composite resin	2
Operator/clinician (same operator for both groups)	1	1	1
Periods of assessment	Baseline (immediately postoperatively)	Baseline (immediately postoperatively)	5
	3 months	3 months	
	6 months	6 months	
	9 months	9 months	
	12 months	12 months	

Group A: Veneering by prefabricated veneers, Group B: Veneering by "direct composite veneering"

**Table 2: Friedman's two-way ANOVA test: P value comparison between evaluation parameters (combined for Groups A and B)**

Tooth nomenclature	Gingival response	Surface texture	Marginal integrity
URC	0.017	0.024	0.023
URLI	0.004	0.406	0.406
URCI	0.255	0.406	0.160
ULCI	0.013	0.406	-*
ULLI	0.000	0.039	0.406
ULC	0.010	0.406	0.406
LLC	0.024	0.406	0.121
LLLI	0.001	0.406	0.092
LLCI	0.000	0.406	0.406
LRCI	0.000	-*	0.287
LRLI	0.001	-*	0.406
LRC	0.000	0.096	0.147

-\*"Not Observed" because all mean ranks are same, hence, non-significant changes. URC: Upper right canine, URLI: Upper right lateral incisor, URCI: Upper right central incisor, ULCI: Upper left central incisor, ULLI: Upper left lateral incisor, ULC: Upper left canine, LLC: Lower left canine, LLLI: Lower left lateral incisor, LLCI: Lower left central incisor, LRCI: lower right central incisor, LRLI: Lower right lateral incisor, LRC: Lower right canine

gingival response for all patients during the period of the study.

For both the groups, surface textural changes [Tables 2 and 3] were significant for maxillary right canine and maxillary left lateral incisor ( $P = 0.024$  and  $0.039$ , respectively). In Group A, the maximum score of 1 was recorded. In Group B, a score of 1 and 3 were recorded for two different patients. In the rest, no significant change was observed in either of the groups. All the rest displayed a score of 0. Overall, for both the groups, the results indicated no change in the original gloss of the veneering material. Maxillary right canine in both the groups showed significant changes in marginal integrity over a period of 12 months ( $P = 0.023$ ). In Group A, the maximum score of 1 was recorded for two different patients. In Group B also, the maximum score of 1 was recorded for three different patients. The rest of the teeth showed no statistically significant change for both the groups.

An intergroup comparison of gingival response, surface texture, and marginal integrity depicted no significant difference between the groups ( $P > 0.05$  for all).

## DISCUSSION

Jensen and Soltys conducted an *in vivo* study on prefabricated veneers.<sup>[7]</sup> They found shade matching and retention to be adequate with clinically inconsequential deterioration of marginal integrity. The gingival response to the veneer restorations was uniformly satisfactory. They concluded that preformed veneers with minimal enamel reduction provided an esthetic, conservative, and functional alternative to fixed prosthodontic therapy. The present study also evaluated componeers for similar parameters as carried out by Jensen and Soltys<sup>[7]</sup> and displayed vastly improved results. They stated that prefabricated composite veneer was easier to modify and provided better esthetics if luted with the same material as used for its fabrication. The present study on componeers is also based on the same facet wherein the componeer was luted with a similar nanohybrid composite resin.

Studies assessing periodontal response to resin composite veneers are few. Mangani *et al.*, based on their work on anterior adhesive restorations, stated that the presence of good oral hygiene and precisely contoured, supragingival veneer margins guarantees a good future periodontal health.<sup>[2]</sup> The nanohybrid composite resins, used in the present study, exhibit enhanced polishability and surface textural characteristics, thus achieving excellent periodontal compatibility. Any marginal inaccuracies or fractures in componeers can be effectively repaired intraorally, because their surface finishing and polishing is simpler than ceramic veneers. Srinivasan had authored a multistep disk-based "Rainbow technique" for achieving high polish in composite veneer restorations. He concluded that

**Table 3: Gingival response, surface texture, and marginal integrity**

Gingival response			Surface texture			Marginal integrity		
Evaluation scores	Number of teeth		Evaluation scores	Number of teeth		Evaluation scores	Number of teeth	
	Group A	Group B		Group A	Group B		Group A	Group B
0	48	48	0	58	40	0	55	44
1	12	12	1	02	07	1	04	08
			2	0	07	2	01	08
			3	0	06	3	00	00

accomplishing high polish is highly critical for the esthetic outcome and a good future gingival response resulting in increased longevity of the composite veneer restoration.<sup>[8]</sup>

D'Souza and Kumar conducted a study to compare the clinical effect of new generation indirect veneering composites with that of direct composite veneer restorations. Forty patients were clinically evaluated for esthetics and periodontal health. Statistical analysis showed that there were no significant effects on periodontal health and both direct and indirect composite materials had clinically acceptable outcomes. The improvement in oral health indices used in the study indicated biocompatibility of both the materials with the periodontal tissues.<sup>[9]</sup> These results can be closely correlated with our present study, wherein highly acceptable results for esthetics and improvement in gingival response were observed for componeers as well as direct composite veneer restorations.

The authors, Dietschi and Devigus, in their extensive study on composite resins, strongly supported the employability of prefabricated composite veneers in the context of "bio-esthetics," a minimally invasive concept, and outlined a very useful spectrum of noninvasive and minimally invasive techniques.<sup>[10,11]</sup> The application of componeers fits aptly into this. A European think tank introduced the highly filled nanohybrid, prefabricated composite enamel shells known as Edelweiss Direct "Veneers," which also exhibited monobloc properties.<sup>[12]</sup> The monobloc concept has been utilized in "componeers" also, where these are luted with "Brilliant-NG" composite resin, thus enhancing the componeers' fracture toughness.<sup>[13]</sup> The thickness of the componeers is very minimal (approximately 0.3 mm). They do not extend inter-proximally, thus allowing composite to be easily shaped in this area. Unlike ceramic veneers, these can be placed under finger pressure, thus allowing the luting composite to flow freely and ensuring close adaptation of the composite to the veneer.

Componeer is fabricated from pure Synergy D6 nanohybrid composite (Coltene) under high pressure (500 Kg mechanical press) and temperature molding process, followed by laser surface vitrification, thus affording it high surface hardness, flexural strength, and maximum homogeneity

under pressure. Its compressive strength (392 MPa) is almost similar to that of enamel (384 MPa). In an *in vitro* microshear test study conducted by Perdiago *et al.*, componeers displayed higher bond strength compared to Cerinate 1-h veneers.<sup>[11]</sup> The direct composite veneering material used in this study was also fabricated from pure Synergy D6 nanohybrid composite (Coltene).

The "Gingival Bleeding Index" used in this study depicted a vast improvement in the gingival response for all patients. This was due to institution of meticulous oral hygiene measures. It further substantiates that precise veneering, direct or indirect, has no detrimental effect on the gingival tissues. Almost similar facts were observed in a study conducted by Barham TP Jr. *et al.*,<sup>[14]</sup> wherein the results indicated that the veneers have no adverse effect on the gingival health if the application protocols and oral hygiene measures are properly adhered to. Overall, no significant change in the surface texture was observed for both materials. Moreover, a veneer with dull surface can easily be replaced by a new one, as was done in this study also. The collective results of marginal integrity also indicated that marginal failures are easily avoidable if veneering is precise and involves sound enamel adhesion. Marginal adaptation and smooth transition of the composite resin to the prepared tooth surface ensures a plaque-free surface. Improper margins and loss of marginal integrity can lead to marginal leakage, veneer discoloration, plaque accumulation, and development of caries. This negative potential must always be weighed against the esthetic benefits of veneers. Therefore, in the present study, this factor was also evaluated.

Peumans *et al.* evaluated the "marginal qualities" of direct composite additions in a 5-year clinical study. They concluded that marginal adaptation varied according to the location of the restoration margins, cervical area being the most difficult to adapt to.<sup>[15]</sup> These results can be correlated with our present study and the one by Jensen and Soltys,<sup>[7]</sup> wherein shade matching and retention were found to be adequate and marginal integrity changes were inconsequential. In another *in vivo* study, the authors, Jain *et al.*, evaluated effects of bleaching on color stability and marginal adaptation of discolored direct and indirect

composite laminate veneers.<sup>[16]</sup> They concluded that indirect composites have better color stability while direct composite veneers displayed better marginal adaptation and bleaching should be avoided in patients with composite restorations. They too, like Peumans *et al.*, stated that marginal adaptation of veneers, especially in the CE region, is difficult. In the present study also, a similar inference was drawn.

The results of the present study can be further corroborated with the results of another 5-year study conducted by Peumans *et al.*, wherein researchers evaluated “esthetic qualities” of ultrafine midway-filled densified composites.<sup>[17]</sup>

Componeers and advanced generation nanohybrid composites are the latest milestones in direct veneering techniques as highlighted by Chandramouli in his work on componeers.<sup>[18]</sup> The results on esthetic and marginal qualities and gingival and periodontal responses have shown improvements over results of certain landmark studies carried out earlier by Barham *et al.* and Peumans *et al.*

## CONCLUSIONS

The intergroup comparison of componeers and direct composite veneers for the parameters, gingival response, surface texture, and marginal integrity did not depict any significant differences. Based on clinical results and statistical analysis, the study concluded that both “componeers” and direct composite veneers showed minimal changes in color, surface texture, and marginal integrity and displayed excellent gingival response. The gingival responses improved over the period of study. Surface textural changes were significant only for maxillary right canine and maxillary left lateral incisor. Changes in marginal integrity were significant only for maxillary right canine. Componeers present a conservative veneering modality and remarkable advancement due to superior esthetics and monobloc properties. A limitation of this study was its short duration, and therefore, studies spanning for longer durations are recommended to obtain better results.

## Financial support and sponsorship

This study was financially supported by Office of The Director General Armed Forces Medical Services.

## Conflicts of interest

There are no conflicts of interest.

## REFERENCES

1. Perdiago J, Sezinando A, Munoz MA, Martinez L, Loguercio AD. Prefabricated veneers-bond strengths and ultramorphological analyses. *J Adhes Dent* 2014;16:137-46.
2. Mangani F, Cerutti A, Putignano A, Bollero R, Madini L. Clinical approach to anterior adhesive restorations using resin composite veneers. *Eur J Esthet Dent* 2007;2:188-209.
3. Panteqi S, Meto A, Simeon O. Componeers vs porcelains. *Int J Sci Res* 2018;7:1680-2.
4. Malone WF, Koth DL. Tylman's Theory and Practice of Fixed Prosthodontics. 8<sup>th</sup> ed. Tokyo, St Louis: Ishiyaku Euro America, Inc.; 1997.
5. Rosenstiel SF, Land MF, Fujimoto J. Contemporary Fixed Prosthodontics. 3<sup>rd</sup> ed. Missouri: Mosby, Inc.; 2002.
6. Ainamo J, Bay I. Problems and proposals for recording gingivitis and plaque. *Int Dent J* 1975;25:229-35.
7. Jensen OE, Soltys JL. Six months clinical evaluation of prefabricated veneer restorations after partial enamel removal. *J Oral Rehabil* 1986;13:49-55.
8. Srinivasan M. Finishing composite veneer restorations: The rainbow technique. *J Indian Prosthodont Soc* 2007;7:95-101.
9. D'Souza DS, Kumar M. Esthetics and biocompatibility of composite dental laminates. *Med J Armed Forces India* 2010;66:239-43.
10. Dietschi D. Current status and future perspectives for the use of composite resins in the smile frame-methods following the “bio-esthetic concept”. *J Cosmet Dent* 2011;27:112-27.
11. Dietschi D, Devigus A. Prefabricated composite veneers: Historical perspectives, indications and clinical application. *Eur J Esthet Dent* 2011;6:178-87.
12. Novelli C. Esthetic treatment of a periodontal patient with prefabricated composite veneers and fiber-reinforced composite: Clinical considerations and technique. *J Esthet Restor Dent* 2015;27:4-12.
13. Albuquerque PP, Nishida AC, Francci CE. Is the color stability of resin-based composites affected by the shade of prefabricated composite resin veneer? *Acta Sci Dent Sci* 2019;3:74-7.
14. Barham TP Jr., Mayhew RB, Cowan RD, Lubow RM, Pierson WP, Voss JE. Gingival response to laminate veneer restorations. *Oper Dent* 1983;8:122-9.
15. Peumans M, van Meerbeek B, Lambrechts P, Vanherle G. The 5-year clinical performance of direct composite additions to correct tooth form and position. II. Marginal qualities. *Clin Oral Investig* 1997;1:19-26.
16. Jain V, Das TK, Pruthi G, Shah N, Rajendiran S. Comparative evaluation of effects of bleaching on color stability and marginal adaptation of discolored direct and indirect composite laminate veneers under *in vivo* conditions. *J Indian Prosthodont Soc* 2015;15:46-52.
17. Peumans M, van Meerbeek B, Lambrechts P, Vanherle G. The 5-year clinical performance of direct composite additions to correct tooth form and position. I. Esthetic qualities. *Clin Oral Investig* 1997;1:12-8.
18. Chandramouli MK. Componeers. *Int J Prev Clin Dent Res* 2017;4:232-4.