

## CASE REPORT

# Oro-facial-digital syndrome type II with otolaryngological manifestations

Havle A, Shedge S<sup>1</sup>, Malashetti S, Jain V

Departments of ENT and <sup>1</sup>Anatomy, Krishna Institute of Medical Sciences University, Karad, Maharashtra, India

## Address for correspondence:

Dr. Havle Abhay D,  
Department of ENT, Krishna Institute of Medical  
Sciences University,  
Karad - 415 110, Maharashtra, India.  
E-mail: entpubkimsu@gmail.com

Received: 25-05-2014

Accepted: 07-07-2015

## ABSTRACT

We present a case of oro-facial-digital syndrome type II (Mohr's syndrome) which is characterized by malformations of the oral cavity, face and digits. The facial and oral features include tongue nodules, cleft or high-arched palate, missing teeth, broad nose; cleft lip. The digital features include clinodactyly, polydactyly, syndactyly, brachydactyly and duplication of the hallux.

**Key words:** Duplication of hallux, oro-facial-digital syndrome, polysyndactyly, tongue nodules

## INTRODUCTION

Oro-facial-digital syndromes (OFDS) are a rare heterogeneous group of development disorders in which at least nine different forms have been described. OFD II Mohr's syndrome is transmitted as an autosomal recessive condition characterized by malformations of the oral cavity, face and digits.<sup>[1]</sup> Facial and oral features include tongue nodules, cleft or high-arched palate, missing teeth, broad nose and cleft lip. Digital features include clinodactyly, polydactyly, syndactyly, brachydactyly and duplication of the hallux. Other systemic features include conductive deafness, choroidal coloboma, renal and congenital heart defects in variable combination. Diagnosis is mainly clinical. The incidence of Mohr's syndrome is very rare and occurs in one in 3 lakh live births.

We report a case of young Indian female suffering from OFD type II (Mohr's syndrome) with otolaryngological manifestations.

## CASE REPORT

A 15-year-old Indian female from Western Maharashtra born out of consanguineous marriage at full term presented with difficulty in speech and decreased hearing in both ears since birth. There was no family history of genetic disease. Her mother had a first pregnancy with premature delivery at 7 months and child died immediately after birth. She has two siblings who are normal. During infancy, she had

difficulty in feeding due to the high arched palate and tongue nodules. There was no history of radiation exposure or any significant drug intake or any trauma or any major illness during pregnancy period of her mother. No history of delayed milestones in development. Vital signs revealed pulse 90/min, regular in nature, blood pressure: 120/80 mmHg right arm supine position. Clinical examination revealed mild pallor, bilateral polysyndactyly with duplicated thumbs on both hands and bilateral polysyndactyly of halluces [Figures 1 and 2], missing central incisors, broad nose, high arched palate, ocular hypertelorism and unusual presentation low set ears [Figure 3] and tongue nodules [Figure 4].

Cardiac, respiratory, abdominal, neurological examinations were unremarkable and intelligence was normal. The female external genitalia and secondary sexual characteristics were normal. Ophthalmic examination revealed normal fundus.

On investigations, hemoglobin - 10.4 g%, total leukocyte count - 7900 cells/mm<sup>3</sup>, DLC- P-79%, L-13%, E-08%, platelets - 275,000/cumm. Peripheral smear showed microcytic hypochromic red blood cells with anisocytosis. Liver function test, renal function test and serum proteins were normal. Erythrocyte sedimentation rate: 20 mm/1<sup>st</sup> h. Urine examination was normal. Electrocardiogram and two-dimensional echo were normal.

This is an open access article distributed under the terms of the Creative Commons Attribution-NonCommercial-ShareAlike 3.0 License, which allows others to remix, tweak, and build upon the work non-commercially, as long as the author is credited and the new creations are licensed under the identical terms.

**For reprints contact:** reprints@medknow.com

**How to cite this article:** Havle A, Shedge S, Malashetti S, Jain V. Oro-facial-digital syndrome type II with otolaryngological manifestations. J Oral Maxillofac Pathol 2015;19:266.

## Access this article online

### Quick Response Code:

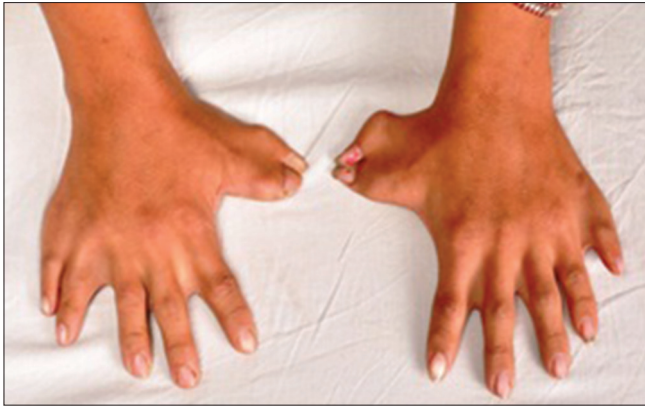

### Website:

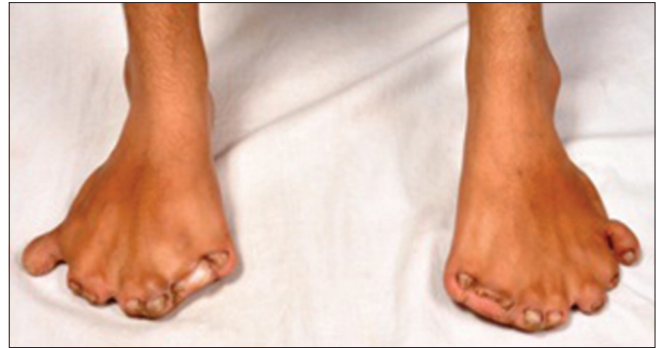www.jomfp.in

### DOI:

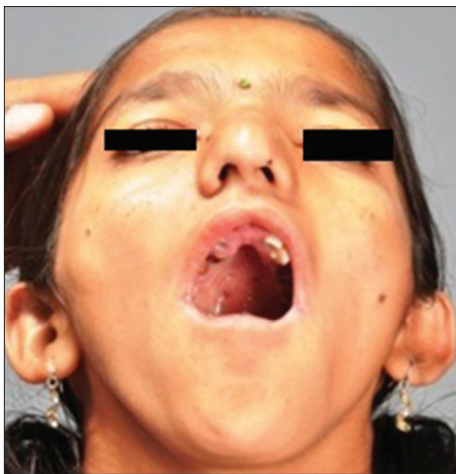10.4103/0973-029X.164553



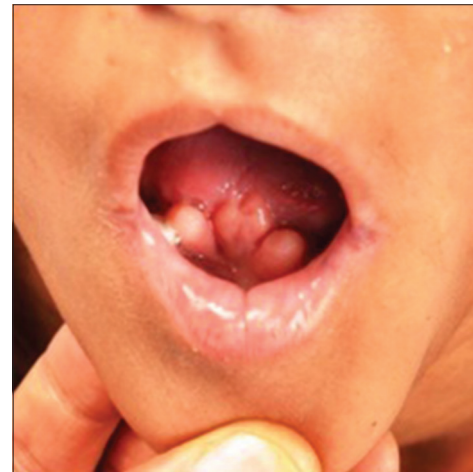
**Figure 1:** Clinical image shows bilateral polysyndactyly of hand, bilateral duplicated thumbs



**Figure 2:** Clinical image shows bilateral polysyndactyly of halluces



**Figure 3:** Clinical image shows missing central incisors and broad nose and high arched palate and low set ears



**Figure 4:** Clinical image shows tongue nodule

An x-ray of both hands with forearms anteroposterior (AP) view [Figure 5] revealed six metacarpals in right hand showing fusion proximally of third and fourth metacarpals. Little fingers show accessory phalanges on both sides with bilateral duplication of thumbs. An x-ray of both feet AP view [Figure 6] revealed seven metatarsals on the right side and six metatarsals on the left side. The large great toe on the right is formed by two metatarsals. Pure tone audiometry revealed the mild conductive type of deafness.

## DISCUSSION

OFDS are a heterogeneous group of rare malformative diseases, characterized by abnormalities of the oral cavity, maxillo-facial region and digits. Such phenotypical pattern was first described by Mohr in 1941<sup>[1]</sup> and later defined as oro-digital-facial dysostoses by Papillon-Léage and Psaume in 1954<sup>[2]</sup> and finally named OFDS in 1967 by Rimoin and Engerton.

The brachydactyly characters observed in the patient, which is one of the major symptoms of Mohr syndrome is explained by Norwegian geneticist Mohr.<sup>[3]</sup>

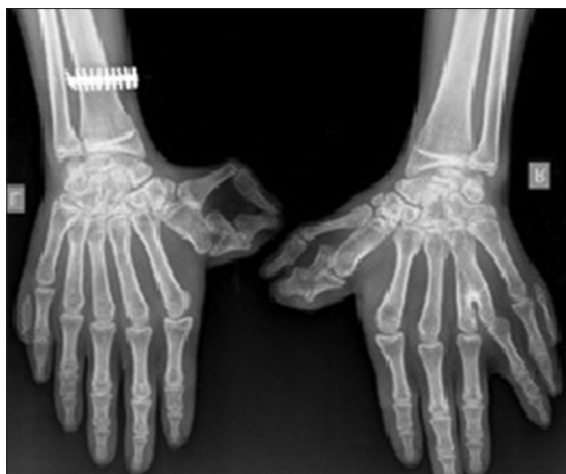There are at least nine different forms of OFDS on the basis of inheritance transmission pattern and phenotypical spectrum, of which the first two types are of common occurrence as compared with other varieties.<sup>[4,5]</sup>

OFDS II is a rare autosomal recessive disease whose diagnosis is based only on clinical evidence. Frequency is rare, one in 3 lakhs live births. The molecular genetic basis is still unknown.<sup>[6]</sup>

Because of the variable clinical expression, even intrafamilial, the attribution of the correct diagnosis among the several forms of OFDS is often difficult.<sup>[7]</sup> In addition, the molecular genesis is still unknown for all OFDS except for the OFD I which is related to the CXORF 5 gene (Xp22.2–22.3) coding for OFD 1 protein.<sup>[8]</sup>

OFD II (Mohr syndrome) is similar to OFD I in that affected individuals usually have hand abnormalities, lobulated tongues and cleft abnormalities. However, a broad nose with a bifid tip is seen in OFD II instead of the alar hypoplasia which characterizes OFD I.<sup>[8]</sup>

The bilateral hallux, polysyndactyly when present is strongly suggestive of OFD II. OFD II is characterized by distinct tongue nodules, rather than the bifid tongue more commonly seen in



**Figure 5:** X-ray of hand shows polysyndactyly and bilateral duplication of thumbs

OFD I. The histopathology of tongue nodules of OFD II would be either hamartoma or lipoma. Although both OFD I and OFD II may present with porencephaly, corpus callosum agenesis is not seen in OFD II. Conductive hearing loss, typically not seen in OFD I, has been reported in OFD II.<sup>[9]</sup> OFD I is the only type in which renal cysts occur which grossly resemble adult polycystic kidney disease, although sometimes types VI and VII may also manifest with renal abnormalities.<sup>[10]</sup>

Laryngeal hypoplasia and tracheal stenosis have also been described in a small subset of individuals with OFD II.<sup>[11]</sup> Cowden syndrome is the only other syndrome in which multiple tongue hamartomas are present. However, Cowden syndrome is characterized by multiorgan hamartomas,<sup>[12]</sup> whereas in OFD the hamartomas are limited to the tongue alone.

Unique and uncommon features noted in this case:

- Bilateral duplication of thumbs
- Low set ears.

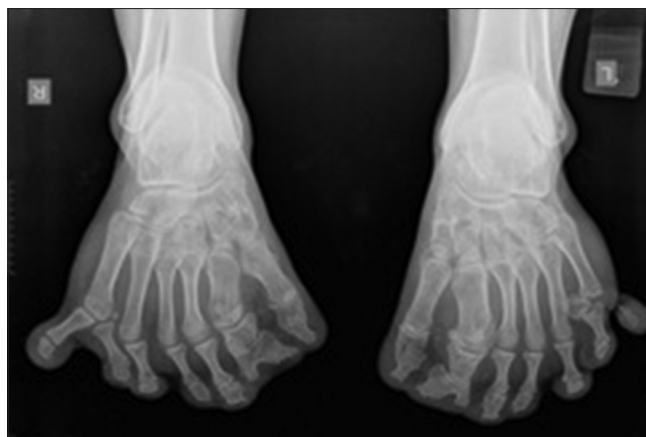With the clinical knowledge and typical radiological appearance, we diagnosed this case as Mohr's syndrome type II OFDS.

## CONCLUSION

OFD type II Mohr's syndrome is rarer than OFD I and gets easily confused with, therefore distinctive features and clinico-radiological knowledge between these two is essential and be considered prior to its implications in genetic counseling of such patients.

## Declaration of patient consent

The authors certify that they have obtained all appropriate patient consent forms. In the form the patient(s) has/have given his/her/their consent for his/her/their images and other clinical information to be reported in the journal. The patients understand that their names and initials will not be published and due efforts will be made to conceal their identity, but anonymity cannot be guaranteed.



**Figure 6:** X-ray of foot shows polysyndactyly and bilateral duplication of hallux

## Financial support and sponsorship

Nil.

## Conflicts of interest

There are no conflicts of interest.

## REFERENCES

1. Kenneth LJ. Smith's Recognizable Patterns of Human Malformation. 5<sup>th</sup> ed. Lyon: WB Saunders Company; 1997. p. 264.
2. Papillon-L, Psaume J. Hereditary abnormality of the buccal mucosa: Abnormal bands and frenula. *Revue Stomatol* 1954;55:209-27.
3. Mohr OL. A hereditary lethal syndrome in man. *Avh Norwegian Videnska. Akad. Oslo* 1941;14:1-18
4. Toriello HV. Oral-facial-digital syndromes. *Clin Dysmorphol* 1993;2:95-105.
5. al-Qattan MM, Hassanain JM. Classification of limb anomalies in oral-facial-digital syndromes. *J Hand Surg Br* 1997;22:250-2.
6. Annerén G, Arvidson B, Gustavson KH, Jorulf H, Carlsson G. Oro-facio-digital syndromes I and II: Radiological methods for diagnosis and the clinical variations. *Clin Genet* 1984;26:178-86.
7. Sakai N, Nakakita N, Yamazaki Y, Ui K, Uchinuma E. Oral-facial-digital syndrome type II (Mohr syndrome): Clinical and genetic manifestations. *J Craniofac Surg* 2002;13:321-6.
8. Ferrante MI, Giorgio G, Feather SA, Bulfone A, Wright V, Ghiani M, *et al.* Identification of the gene for oral-facial-digital type I syndrome. *Am J Hum Genet* 2001;68:569-76.
9. Prpic I, Cekada S, Franulovic J. Mohr syndrome (oro-facial-digital syndrome II) – A familial case with different phenotypic findings. *Clin Genet* 1995;48:304-7.
10. Sugarman GI, Katakia M, Menkes J. See-saw winking in a familial oral-facial-digital syndrome. *Clin Genet* 1971;2:248-54.
11. Steichen-Gersdorf E, Gassner I, Covi B, Fischer H. Oral-facial-digital syndrome II. Transitional type between Mohr and Majewski syndrome: Report of a new case with congenital stenosis of the trachea. *Clin Dysmorphol* 1994;3:245-50.
12. Swart JG, Lekkas C, Allard RH. Oral manifestations in Cowden's syndrome. Report of four cases. *Oral Surg Oral Med Oral Pathol* 1985;59:264-8.