

# Gestational Primary Hyperparathyroidism Due to Ectopic Parathyroid Adenoma: Case Report and Literature Review

William B. Horton,<sup>1</sup> Meaghan M. Stumpf,<sup>1</sup> Joseph D. Coppock,<sup>2</sup> Luke Lancaster,<sup>3</sup>  
Alan C. Dalkin,<sup>1</sup> Zhenqi Liu,<sup>1</sup> Christian A. Chisholm,<sup>4</sup> Philip W. Smith,<sup>5</sup>  
and Susan E. Kirk<sup>1</sup>

<sup>1</sup>Division of Endocrinology and Metabolism, Department of Medicine, University of Virginia Health System, Charlottesville, Virginia 22903; <sup>2</sup>Department of Pathology, University of Virginia Health System, Charlottesville, Virginia 22903; <sup>3</sup>Division of Nuclear Medicine, Department of Radiology and Medical Imaging, University of Virginia Health System, Charlottesville, Virginia 22903; <sup>4</sup>Division of Maternal-Fetal Medicine, Department of Obstetrics and Gynecology, University of Virginia Health System, Charlottesville, Virginia 22903; and <sup>5</sup>Division of General Surgery, Department of Surgery, University of Virginia Health System, Charlottesville, Virginia 22903

---

Gestational primary hyperparathyroidism (GPHPT) is a rare condition with fewer than 200 cases reported. We present the case of a 21-year-old woman who presented at 10 weeks' gestation with severe hypercalcemia. Laboratory investigation was consistent with primary hyperparathyroidism. Neck ultrasound did not reveal any parathyroid enlargement. Due to the persistence of severe hypercalcemia, she was treated with 4 weeks of cinacalcet therapy, which was poorly tolerated due to nausea and vomiting. At 14 weeks' gestation, she underwent neck exploration with right lower, left upper, and partial right upper parathyroid gland excision. Intra- and postoperative parathyroid hormone (PTH) and calcium levels remained elevated. After a thorough discussion of risks/benefits, the patient requested further treatment. A parathyroid sestamibi scan (PSS) revealed an ectopic adenoma in the left mediastinum. The adenoma was removed via video-assisted thorascopic parathyroidectomy with intraoperative PTH declining to nearly undetectable levels. She ultimately delivered a physically and developmentally normal infant at 37 weeks' gestation.

Appropriate treatment of severe GPHPT may prevent the maternal and fetal complications of hypercalcemia. This case, in which cinacalcet therapy and PSS were used, adds to the body of literature regarding treatment of severe GPHPT.

Copyright © 2017 Endocrine Society

This article has been published under the terms of the Creative Commons Attribution Non-Commercial, No-Derivatives License (CC BY-NC-ND; <https://creativecommons.org/licenses/by-nc-nd/4.0/>).

**Freeform/Key Words:** hypercalcemia, primary hyperparathyroidism, pregnancy, technetium Tc 99m sestamibi

---

Gestational primary hyperparathyroidism (GPHPT) is a rare condition with prevalence of 0.15% to 1.4% [1–3] and fewer than 200 cases reported. Unlike gestational diabetes or thyrotoxicosis, which are pathologic conditions associated with physiologic changes of pregnancy, GPHPT is only incidentally associated with pregnancy due to the fact that women are seeking obstetrical care. It often goes unrecognized, as patients may be asymptomatic or exhibit mild symptoms that are considered normal in pregnancy [4]. Indeed, most women complete pregnancy without biochemical analysis of their calcium levels. GPHPT is a treatable cause of fetal and maternal morbidity and mortality [5]; thus,

---

Abbreviations: 4DCT, four-dimensional computed tomography; GPHPT, gestational primary hyperparathyroidism; IVF, intravenous fluid; MEN, multiple endocrine neoplasia; PSS, parathyroid sestamibi scan; PTH, parathyroid hormone.

early diagnosis and appropriate management are vital strategies for avoiding obstetrical complications.

## 1. Case Presentation

A 21-year-old female (gravida 2, para 1) presented at 10 weeks' gestation with headache, intractable vomiting, and polydipsia. Laboratory investigation revealed elevated levels of serum calcium (13.5 mg/dL), ionized calcium (1.69 mmol/L), intact postoperative parathyroid hormone (PTH; 254.3 pg/mL), and 1,25-dihydroxyvitamin D (268 pg/mL), consistent with primary hyperparathyroidism. All other laboratory results were unremarkable (Table 1). She denied any personal or family history of hypercalcemia or endocrine neoplasia. Intravenous fluid (IVF) therapy was initiated, but she continued to experience vomiting and hypercalcemia.

Ultrasound confirmed a viable intrauterine pregnancy. Aggressive IVF therapy was continued, but calcium remained elevated (Table 2). She had no palpable neck mass, and neck ultrasound revealed no evidence of parathyroid enlargement. Due to the degree and persistence of hypercalcemia, we planned for neck exploration in the second trimester. As a bridge, the risks/benefits of medical therapy were discussed and cinacalcet was started at 30 mg twice daily. Calcium levels normalized thereafter (Table 2). Once stable, the patient was discharged home.

She continued to experience intractable vomiting leading to sporadic compliance with cinacalcet. At one stage, she was unable to tolerate cinacalcet for 2 days, which led to worsening hypercalcemia and readmission for IVF therapy (day 11 in Table 2).

At 14 weeks' gestation, she underwent four-dimensional computed tomography (4DCT) of the neck (with fetal shielding) with and without contrast for preoperative localization, which revealed two normal sized glands (one  $\sim 2 \times 1 \times 3$  mm in the posterior midline and another  $2 \times 1 \times 5$  mm just cranial to the left inferior thyroid artery on the left). No candidate parathyroid adenoma in the neck or anterior mediastinum was identified. Endocrine surgery then performed bilateral neck exploration with right lower, left upper, and partial right upper parathyroid gland excision. The left lower parathyroid gland could not be identified. Intraoperative PTH levels steadily increased from 209 to 252 pg/mL over 5 hours. Histologic examination identified normal parathyroid tissue weighing 0.03 g. After extensive discussion of the risks/benefits of additional imaging and a potential second surgery, as well as the option of delaying further tests or treatment until after delivery, the patient opted for and consented

**Table 1. Laboratory Values at Time of Initial Presentation**

Laboratory Test	Reference Range	Initial Value
Glucose (mg/dL)	74–99	108
Sodium (mmol/L)	136–145	137
Potassium (mmol/L)	3.4–4.8	3.2
Chloride (mmol/L)	98–107	106
Bicarbonate (mmol/L)	22–29	21
Blood urea nitrogen (mg/dL)	7.0–18.7	5
Creatinine (mg/dL)	0.6–1.1	0.5
Calcium (mg/dL)	8.5–10.7	13.5
Magnesium (mg/dL)	1.6–2.6	1.6
Phosphorus (mg/dL)	2.3–4.7	2.3
Total protein (g/dL)	6.0–8.3	6.3
Albumin (g/dL)	3.2–5.2	3.7
Total bilirubin (mg/dL)	0.3–1.2	0.2
PTH (pg/mL)	9.2–79.5	254.3
PTH-related peptide (pg/mL)	14–27	12
25-Hydroxyvitamin D (ng/mL)	30–100	19
1,25-Dihydroxyvitamin D (pg/mL)	18–78	268
Ionized calcium (mmol/L)	1.13–1.32	1.69
24-Hour urine calcium (mg/day)	100–250	361

**Table 2. Serum Calcium, Ionized Calcium, and PTH Levels Throughout Treatment Course**

Laboratory Test	Reference Range	Day 0	Day 1	Day 3	Day 4	Day 5	Day 6	Day 11	Day 13	Day 16	Day 33	Day 34	Day 35	Day 38	Day 50
		IVF Started			Cinacalcet Started		Discharged				PES	VATP		Discharged	
Serum calcium (mg/dL)	8.5–10.5	12.0	10.8	11.2	12.8	11.0	10.7	13.5	10.4	10.4	11.4	11.3	9.1	7.4	8.6
Ionized calcium (mg/dL)	4.4–5.5	6.2	6.2	6.0	6.5	6.1	6.0	6.1				5.6	4.4	3.7	4.9
PTH (pg/mL)	9–77	191.0		190.2						217	209.8	188.7	1.9	26.6	20

Abbreviations: PES, parathyroid exploration surgery; VATP, video-assisted thorascopic parathyroidectomy.

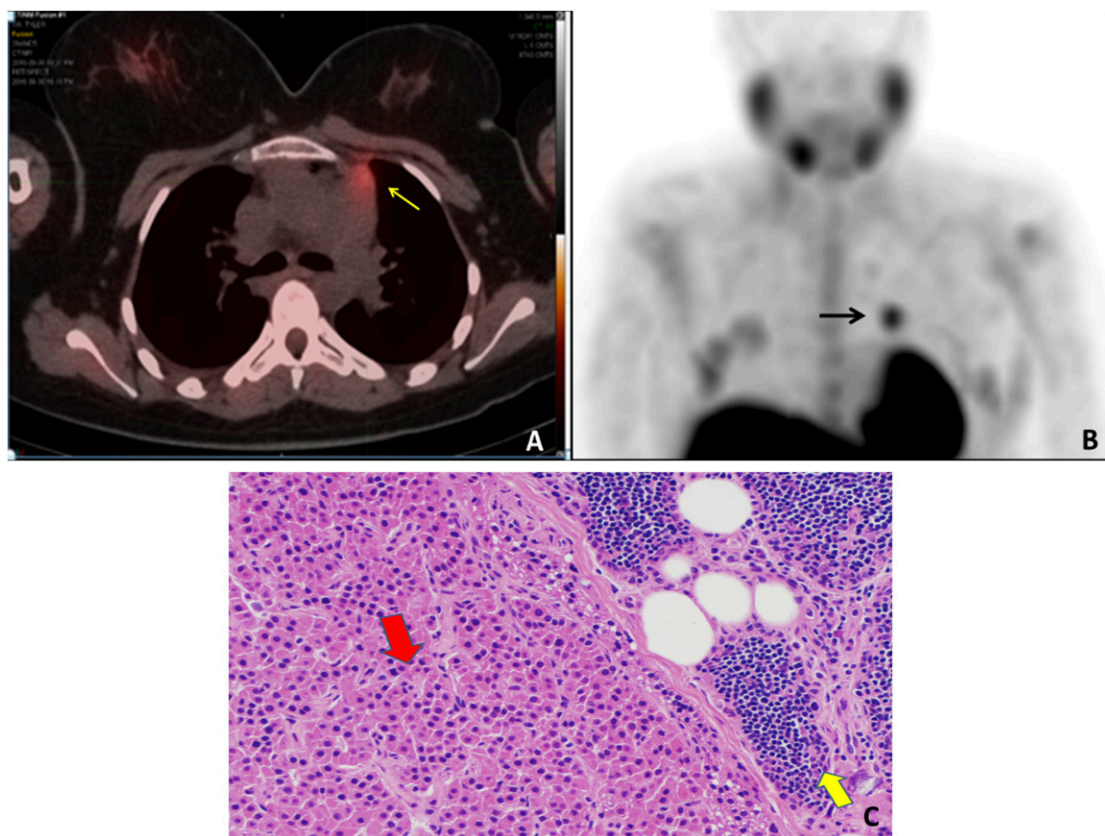
to further diagnostic studies. Parathyroid sestamibi scan (PSS) identified an ectopic adenoma low in the left mediastinum [Fig. 1(A) and 1(B)]. The ectopic gland weighed 3.1 g and was removed via video-assisted thorascopic parathyroidectomy. Intraoperative PTH levels were not obtained, as surgery was performed on a weekend, but intact PTH levels decreased from 188.7 pg/mL on day of surgery to 1.9 pg/mL the following morning (Table 2). Histologic examination revealed hypercellular parathyroid tissue, consistent with an adenoma [Fig. 1(C)]. She declined genetic testing for multiple endocrine neoplasia (MEN) syndromes. During the initial postoperative period, she was started on 2 g calcium carbonate daily but developed persistent hypocalcemia with perioral paresthesia, necessitating intravenous calcium gluconate 2 g every 6 hours for approximately 36 hours. PTH and calcium levels slowly normalized (Table 2), and she was transitioned to 0.25 mcg calcitriol twice daily and 2000 mg/400 IU calcium/vitamin D daily. She was discharged home in stable condition and able to discontinue calcium supplementation 4 weeks later. She was later admitted to another facility for pre-eclampsia without severe features at 36 weeks' gestation with biochemistry showing serum calcium of 7.5 mg/dL with albumin of 2.3 g/dL (corrected calcium within normal limits at 8.9 mg/dL). She ultimately gave birth to a healthy male infant (height 17.5 inches; weight 2.763 kg; Apgar score 8) at 37 weeks via spontaneous vaginal delivery. Calcium levels were not drawn on the infant postpartum, but neither neonatal seizures nor tetany were observed prior to discharge home. At 2-months' follow-up, he was growing appropriately (height 21.25 inches; weight 4.649 kg; head circumference 15 inches) and met all developmental milestones.

## 2. Discussion

The physiology of fetal calcium homeostasis is complex. Fetal parathyroid development occurs after the first trimester; therefore, maternal calcium status plays a fundamental role in fetal homeostasis (Fig. 2). Maternal calcium is actively transported across the placenta into the fetal circulation. Placental PTH-related peptide easily enters the fetal circulation as well. In contrast, both maternal PTH and 1,25-dihydroxyvitamin D are prevented from transfer. Maternal 25-hydroxyvitamin D does reach the fetus, but as PTH-related peptide only minimally increases 1- $\alpha$  hydroxylation, its contribution to calcium regulation is limited until fetal PTH production ensues later in gestation.

This regulatory pathway has clinical implications, as elevated maternal calcium levels transfer directly to the fetus in whom counter-regulatory responses (such as inhibition of PTH) are ineffective or do not exist, especially during the first trimester. Later in gestation, maternal hypercalcemia may cause fetal hypercalcemia with suppression of fetal PTH. At delivery, maternal calcium transfer ceases, which predisposes the baby to postpartum hypocalcemia.

Data regarding outcomes of GPHPT are limited to case reports or small case series. One recent study examining pregnancy outcomes in women with primary hyperparathyroidism found that most patients have only mild hypercalcemia, which is generally not associated with obstetrical complications [6]. Conversely, 67% to 80% of pregnancies with severe

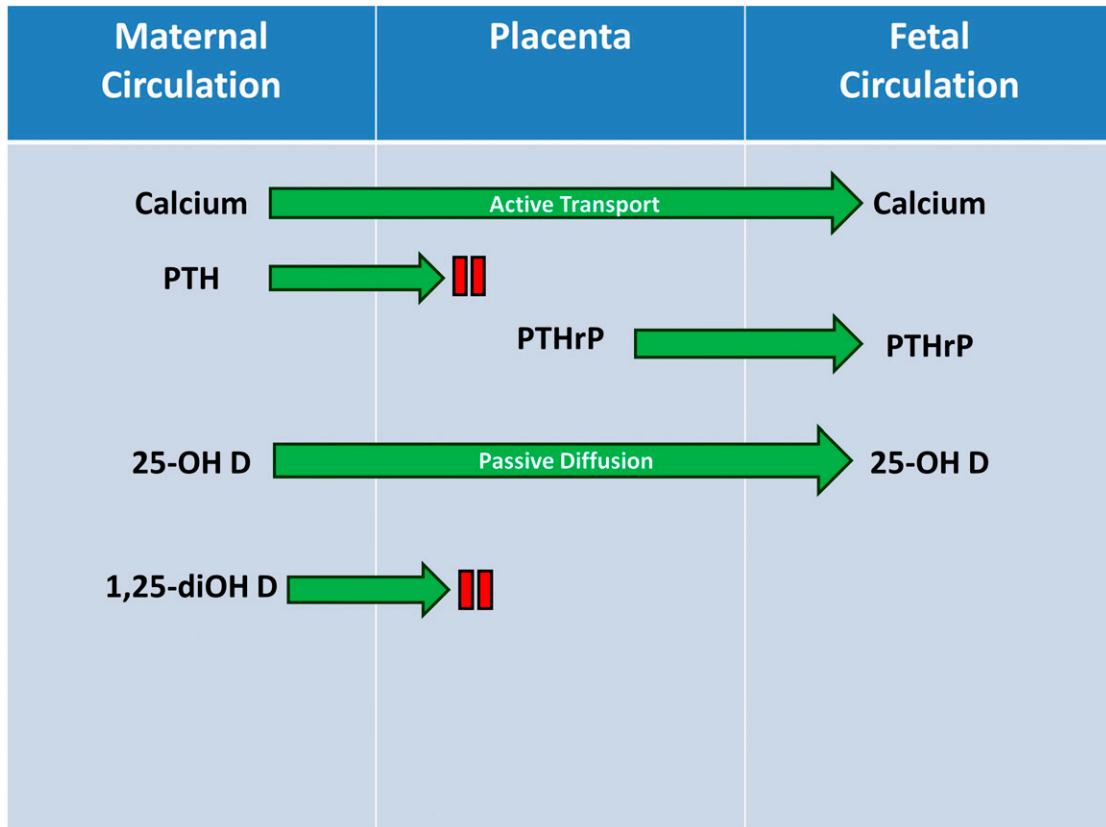


**Figure 1.** (A) Axial single photon emission computed tomography slice through the mid chest, with tracer activity in orange. The focus of intense activity in the left anterior mediastinum (yellow arrow) corresponds to the ectopic parathyroid adenoma, contiguous with thymus. (B) Maximal intensity projection image of the single photon emission computed tomography data. There is normal uptake of sestamibi in salivary glands, heart, liver, and lactating breasts. The round spot above the heart (black arrow) is abnormal and represents the patient's ectopic parathyroid adenoma. (C) Benign hypercellular parathyroid tissue (red arrow) with adjacent thymic tissue (yellow arrow) at total magnification of  $\times 200$ .

hypercalcemia may experience poor fetal and maternal outcomes [3], underscoring the need for timely diagnosis and treatment.

Treatment should be individually tailored by gestational age, severity of hypercalcemia, and risk–benefit analysis [7]. Treatment may be challenging, as some therapies are contraindicated (*e.g.*, bisphosphonates) and practitioners may be reluctant to suggest surgery during pregnancy, particularly outside the second trimester [8]. Mild asymptomatic hypercalcemia may be treated conservatively. Patients with severe hypercalcemia (symptomatic and/or ionized serum concentration 5.6 to 8 mg/dL) are appropriate surgical candidates [8]. Failure of medical therapy in symptomatic patients is an indication for surgery regardless of gestational age [8]. As with most surgical procedures during pregnancy, the optimal time for intervention is during the second trimester [8]. Preoperative localization facilitates successful surgical intervention, as up to 2% of patients will have ectopic parathyroid tissue [8]. We could find no epidemiological data regarding the prevalence of MEN syndromes in GPHPT, but one case series demonstrated that two of eight patients (25%) were found to have MEN1 gene mutations [4]. Younger age at diagnosis or parathyroid gland hyperplasia on histologic examination increases the likelihood of a genetic syndrome.

This case adds to the body of evidence regarding cinacalcet and PSS during pregnancy. To our knowledge, this is only the eighth report of cinacalcet use [9–13] and sixth report of PSS [1, 8, 14] during gestation. Cinacalcet is a calcimimetic agent that binds the calcium-sensing receptor, ultimately leading to decreased PTH secretion [9]. Data on cinacalcet use in human



**Figure 2.** Regulation of calcium during gestation. Maternal calcium is actively transported across the placenta into the fetal circulation. Placental PTH-related peptide (PTHrP) also rapidly enters the fetal circulation. Conversely, both maternal PTH and 1,25-dihydroxyvitamin D (1,25-diOH D) are prevented from transfer. Maternal 25-hydroxyvitamin D (25-OH D) reaches the fetus via passive diffusion. During the second and third trimester, fetal parathyroid development results in fetal circulation of PTH.

pregnancy are limited to a small number of case reports, in which no teratogenic or other adverse fetal effects were observed and all mothers remained pregnant to term and delivered healthy infants (although two infants experienced transient neonatal hypocalcemia [10, 13] and one pregnancy was terminated prior to delivery for reasons unrelated to cinacalcet use [9]). Although it was unclear whether our patient's persistent vomiting was worsened by cinacalcet, the health of her infant reinforces these positive reports. It should be noted that our patient received cinacalcet for only 4 weeks and, due to nausea and vomiting, was only able to take ~50% of prescribed doses.

Nuclear imaging during pregnancy remains controversial. Radiation risks throughout pregnancy are related to the stage of pregnancy and the absorbed dose. These risks are more substantial during organogenesis and in the early fetal period, somewhat less in the second trimester, and least in the third trimester [15]. Provided there is strong clinical justification and effort to use nonionizing radiation, pregnancy itself is not a contradiction, especially when using short-lived radionuclides [8]. The estimated fetal radiation dose from Tc-99m PSS is 2 to 4 mGy, which is well below the threshold of concern (100 to 200 mGy) for adverse fetal effects from radiation exposure [15]. Precautionary measures should include maternal hydration and frequent voiding after administration of radionuclides to avoid pooling of the radionuclide in the maternal bladder and subsequent fetal exposure. Longer imaging times may also help reduce fetal exposure [8]. All cases referenced in which PSS was used during pregnancy demonstrated no teratogenic effects. The mother also received 4DCT of the neck with fetal shielding for preoperative localization. Computed tomography examinations in areas of the



body other than the abdomen and pelvis deliver minimal radiation doses to the fetus [16]. Moreover, fetal radiation doses from computed tomography examinations of the abdomen and pelvis rarely exceed 25 mGy (which would also be below the reported threshold of concern) [16]. In this case, the radiation risk to fetus was low given 4DCT of the neck was performed and fetal shielding was in place before imaging began.

### 3. Conclusion

GPHT due to ectopic parathyroid tissue is rare, and its management can be challenging. This report adds to the literature regarding treatment of this condition, detailing the use of cinacalcet as a bridge to surgery and PSS for localization of ectopic parathyroid tissue.

### Acknowledgments

We thank the patient for allowing us to share her story with the medical community.

Address all correspondence to: William B. Horton, MD, 415 Ray C. Hunt Drive, Charlottesville, Virginia 22903. E-mail: [WBH2N@hscmail.mcc.virginia.edu](mailto:WBH2N@hscmail.mcc.virginia.edu).

Disclosure Summary: The authors have nothing to disclose.

---

### References and Notes

1. McMullen TP, Learoyd DL, Williams DC, Sywak MS, Sidhu SB, Delbridge LW. Hyperparathyroidism in pregnancy: options for localization and surgical therapy. *World J Surg*. 2010;**34**(8):1811–1816.
2. Kelly TR. Primary hyperparathyroidism during pregnancy. *Surgery*. 1991;**110**(6):1028–1033, discussion 1033–1034.
3. Schnatz PF, Curry SL. Primary hyperparathyroidism in pregnancy: evidence-based management. *Obstet Gynecol Surv*. 2002;**57**(6):365–376.
4. Stringer KM, Gough J, Gough IR. Primary hyperparathyroidism during pregnancy: management by minimally invasive surgery based on ultrasound localization. *ANZ J Surg* (in press). 10.1111/ans.13378.
5. Gokkaya N, Gungor A, Bilen A, Bilen H, Gviniashvili D, Karadeniz Y. Primary hyperparathyroidism in pregnancy: a case series and literature review. *Gynecol Endocrinol*. 2016;**32**(10):783–786.
6. Hirsch D, Kopel V, Nadler V, Levy S, Toledano Y, Tsvetov G. Pregnancy outcomes in women with primary hyperparathyroidism. *J Clin Endocrinol Metab*. 2015;**100**(5):2115–2122.
7. Kamenický P, Lecoq AL, Chanson P. Primary hyperparathyroidism in pregnancy. *Ann Endocrinol (Paris)*. 2016;**77**(2):169–171.
8. Saad AF, Pacheco LD, Costantine MM. Management of ectopic parathyroid adenoma in pregnancy. *Obstet Gynecol*. 2014;**124**(2 Pt 2, Suppl 1):478–480.
9. Rey E, Jacob CE, Koolian M, Morin F. Hypercalcemia in pregnancy - a multifaceted challenge: case reports and literature review. *Clin Case Rep*. 2016;**4**(10):1001–1008.
10. Nadarasa K, Bailey M, Chahal H, Raja O, Bhat R, Gayle C, Grossman AB, Druce MR. The use of cinacalcet in pregnancy to treat a complex case of parathyroid carcinoma. *Endocrinol Diabetes Metab Case Rep*. 2014;**2014**:140056.
11. Edling KL, Korenman SG, Janzen C, Sohsman MY, Apple SK, Bhuta S, Yeh MW. A pregnant dilemma: primary hyperparathyroidism due to parathyromatosis in pregnancy. *Endocr Pract*. 2014;**20**(2):e14–e17.
12. Horjus C, Groot I, Telting D, van Setten P, van Sorge A, Kovacs CS, Hermus A, de Boer H. Cinacalcet for hyperparathyroidism in pregnancy and puerperium. *J Pediatr Endocrinol Metab*. 2009;**22**(8):741–749.
13. Vera L, Oddo S, Di Iorgi N, Bentivoglio G, Giusti M. Primary hyperparathyroidism in pregnancy treated with cinacalcet: a case report and review of the literature. *J Med Case Reports*. 2016;**10**(1):361.
14. Baretić M, Tomić Brzac H, Dobrenić M, Jakovčević A. Parathyroid carcinoma in pregnancy. *World J Clin Cases*. 2014;**2**(5):151–156.
15. Shaw P, Duncan A, Vouyouka A, Ozsvath K. Radiation exposure and pregnancy. *J Vasc Surg*. 2011;**53**(1, Suppl):28S–34S.
16. McCollough CH, Schueler BA, Atwell TD, Braun NN, Regner DM, Brown DL, LeRoy AJ. Radiation exposure and pregnancy: when should we be concerned? *Radiographics*. 2007;**27**(4):909–917, discussion 917–918.