



Case report

Laparoscopic cholecystectomy for the treatment of acute cholecystitis in a Vietnamese male patient with ankylosing spondylitis combined with chronic obstructive pulmonary disease: A rare case report

Tran Que Son^{a,b,*},¹ Tran Hieu Hoc^{a,1}

^a Department of Surgery, Hanoi Medical University, 1 Ton That Tung Street, Khuong Thuong Ward, Dong Da District, Hanoi, Viet Nam

^b Emergency Center (A9), Bachmai Hospital, 78 Giai Phong street, Dong Da District, Hanoi, Viet Nam

ARTICLE INFO

Keywords:

Laparoscopic cholecystectomy
COPD
Ankylosing spondylitis
Surgical procedure
Vietnam

ABSTRACT

Introduction: Ankylosing spondylitis (AS) presents with difficulty in intubation, restricted ventilatory abnormalities, and frequent cardiac involvement. However, with improvements in anaesthesiology and surgical expertise, laparoscopic cholecystectomy can be extended to individuals with kyphoscoliosis caused by AS.

Case presentation: We report the case of a 68-year-old man who had severe AS for more than 30 years following necrosis acute cholecystitis. Signs of severe AS included the patient's inability to lie down and difficulty in breathing. We utilised four trocars but changed the placement positions and used suction tubes during laparoscopic cholecystectomy. The patient was discharged from the hospital after 14 days.

Discussion: Severe AS is not a contraindication to laparoscopic surgery. However, patients with AS or kyphosis must be carefully assessed for respiratory dysfunction, cardiac impairment, difficult airway, and other special conditions. Anaesthesiologists and surgeons should collaborate with surgical decisions in patients with severe respiratory limitations.

Conclusion: Laparoscopic cholecystectomy can be performed effectively in patients with severe AS. With the use of a laparoscopic hook and suction equipment, it is possible to easily dissect the Calot triangle during acute cholecystitis.

1. Introduction

The 2018 Tokyo Guidelines (TG18) suggest laparoscopic cholecystectomy (LC) over open cholecystectomy for acute cholecystitis due to shorter postoperative hospital stay and decreased risk of complications [1–3]. LC is now considered the gold standard for symptomatic cholelithiasis, as well as for chronic and acute cholecystitis [4].

Ankylosing spondylitis (AS) is a cause of kyphosis, a chronic inflammatory illness that develops into AS over time and affects the mobility of the spine, resulting in kyphosis and respiratory limitations. Laparoscopic surgery has several advantages in this situation, including providing care with relieving pain, early movement, and preventing lung infections and pressure ulcers. However, a low-lying costal arch in the AS covers the liver entirely, causing difficulties in the LC due to the restricted working space. The placement of the trocar must be changed to achieve a favourable surgical field.

Herein, we report a rare case of acute cholecystitis with AS. The patient had fixed rigidity of the cervical spine and accentuated thoracic kyphosis, resulting in severe restrictive lung disease, and underwent LC.

This report can be used for educational purposes and clinical practice. This case report was drafted and submitted according to the CARE guidelines [5].

2. Presentation of case

A 68-year-old man presented to our hospital with fever, dyspnoea, and abdominal pain. The patient had a history of severe AS for more than 30 years, and difficulty in breathing showed signs of severe chronic obstructive pulmonary disease (COPD) with formal diagnosis and treatment. He denied any other medical history such as hypertension or coronary heart disease and had no history of smoking, drinking, or abdominal surgery.

* Corresponding author at: Ton That Tung Street, Khuong Thuong Ward, Dong Da District, Hanoi city, Viet Nam.

E-mail addresses: tranqueson@hmu.edu.vn (T.Q. Son), tranhieuhoc@hmu.edu.vn (T.H. Hoc).

¹ Tran Que Son and Tran Hieu Hoc contributed equally to this work.

His blood pressure, pulse rate, and body temperature were 110/70 mmHg, 80/min, and 38.6 °C, respectively. The oxygen saturation of the peripheral arteries was 85%. His height and weight were 160 cm and 40 kg, respectively. Physical examination revealed pain and tenderness in the right upper abdominal region. The patient was unable to lie supine because of the presence of significant kyphoscoliosis. He had difficulty breathing for the last 7–8 years due to COPD, which was treated at home with inhalers and bronchodilators. Laboratory examination results were as follows: white blood cell counts 20,000/L; haemoglobin, 13.5 g/dL; prothrombin 78%, IRN 1.18, fibrinogen 7.76 g/mL, red blood cell counts 4.32 T/L, PLT 195 G/L, total bilirubin 23.3 µmol/L, amylase 43.3 U/L.

Chest radiography did not show an enlarged cardiac shadow, the interfacial space was thickened on both sides, and the pleural space was fluid-free. The sacrum and pelvis were fused at the two joints. Two hip joints showed significant degenerative joint facet loss (grade IV). Ultrasonography and computed tomography of the abdomen revealed a necrosis acute gallbladder with 60 mm in transverse diameter of 8 mm, wall thickness, and peri-gallbladder omental infiltrate. Numerous stones were localised in a 30 × 28 mm cluster inside the gallbladder, accompanied by blood clots in the gallbladder lumen measuring 28 × 25 mm. No stones were found in the common bile duct (Fig. 1).

These findings were consistent with a diagnosis of acute cholecystitis due to gallstones according to the TG18 at Grade II (moderate) [4], Charlson Comorbidity Index = 4, the American Society of Anaesthesiology score was III, SpO₂ = 92% and limited neck flexion.

Under endotracheal anaesthesia, the patient was placed in Fowler's position with thick pillows beneath his head and body (Fig. 2A). For conscious sedation, an intravenous midazolam (0.5 mg) (Teva Pharmaceutical Works Private Limited Company, Hungary), fentanyl 20 mg (Rotexmedica GmbH Arzneimittelwerk, Germany) bolus, and propofol 200 mg (Fresenius Kabi Deutschland GmbH) bolus was administered as a rapid bolus followed by an infusion at 10 mg/h. A 60-mg bolus of propofol (Atracurium-Hameln®) 25 mg/2,5 mL, and fentanyl (60 mg) was used to induce the patient.

Surgery was performed by a hepatobiliary surgeon with over 10 years of experience who had performed over 300 LCs, 30 laparoscopic pancreaticoduodenectomies [6], 400 laparoscopic appendectomies, and the first ten patients underwent single-port laparoscopic appendectomy.

Four trocars were purchased. A 10-mm trocar was inserted at the

navel of the camera. Subsequently, CO₂ was injected intra-abdominally at a pressure of 8 mmHg. The following three trocars were placed directly in front of the camera: 10 mm below the left costal border of the midclavicular line, 5 mm right iliac fossa, and 5 mm right ribs (Fig. 2B).

The distended gallbladder was located below the costal margin, with a necrotic point that was covered by the great omentum and seemed to be sensitive to bleeding (Fig. 3A). First, the gallbladder was deflated by bile emptying (Fig. 3B). The peritoneum above and below the cystic duct was opened using electrocautery. The connective tissue surrounding the cystic duct was dissected using a suction instrument to determine the Calot's triangle area (Fig. 3C). Two hem-o-lok clamps secured the cystic duct, and a hem-o-lok clamp was used for the gallbladder artery (Fig. 3D). The gallbladder was released from the liver. The specimen was removed from the umbilical location. The total time for surgery was 60 min, and intraoperative blood loss was 350 mL. However, no intraoperative blood transfusion was required.

The patient was admitted to the intensive care unit for 10 days. The following antibiotics were administered: Meropenem Kabi 1 g (Facta Farmaceutici S.p.A Nucleo Industriale S. Atto, S. Nicolo a Tordino, 64,100 Teramo) × 3 vials 1 g per 8 h/day, Metronidazole Kabi 0.5 g (Fresenius Kabi Bidiphar) × 2 vials/day. For the first 3 days, complete parenteral nutrition was provided by Nutriplex *peri* 1000 mL (B. Braun Medical AG) × 1 bag and glucoyte 500 mL (Otsuka Pharmaceutical Co., Ltd. Tokushima Itano Factory, Japan) × 2 bottles/day; oral refeeding began on the fourth day in collaboration with intravenous nutrition. Additionally, we indicated respiratory medication in the form of Symbicort 160/4.5 mg (AstraZeneca) × 120 doses/spray vial. In addition, we prevented anticoagulation with Lovenox 40 mg/0.4 mL (Aventis Pharma Specialities, France) × 1 pump subcutaneously administered daily and decreased gastric secretion with Pantoloc 40 mg (Nycomed GmbH, Germany) × 1 vial daily.

During the treatment period, the patient's blood cells, liver enzymes (GOT, GPT), and total bilirubin levels were reduced to normal levels, and CRP levels decreased (Table 1). After 14 days of treatment, the patient was discharged without any abdominal complications due to pneumonia. Histopathological examination revealed necrotising cholecystitis due to the stones.

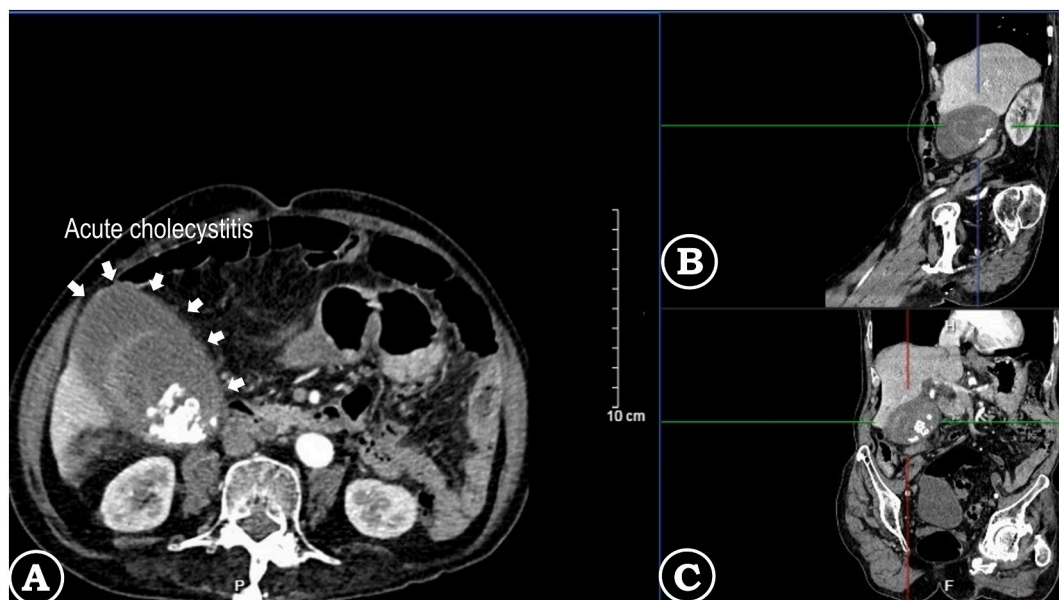


Fig. 1. Abdominal computed tomography.

A-acute cholecystitis is related to the presence of numerous gallstones (white arrow). B, C-The gallbladder is dilated to a diameter of 6 cm, and the fundus of the gallbladder reaches the level of the iliac crest.

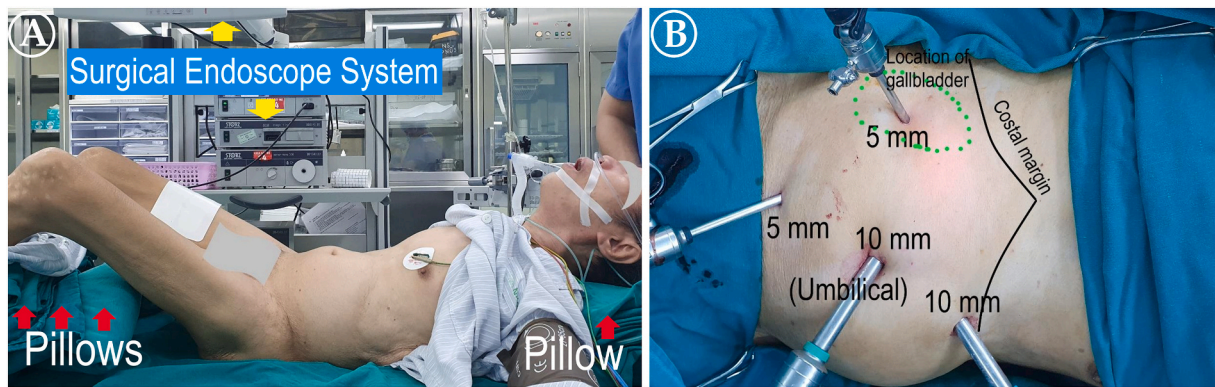


Fig. 2. Position of the patient and placement of the trocar for laparoscopic surgery.

A- The surgical endoscope system is positioned on the patient's right side (yellow arrow) and in the supine position with a pillow under the neck and legs (red arrow). B- Trocar placement (10 mm at the navel for camera placement, 10 mm below the left flank, 5 mm of the right groin, and 5 mm of the right flank), and gallbladder location (blue dot). (For interpretation of the references to colour in this figure legend, the reader is referred to the web version of this article.)

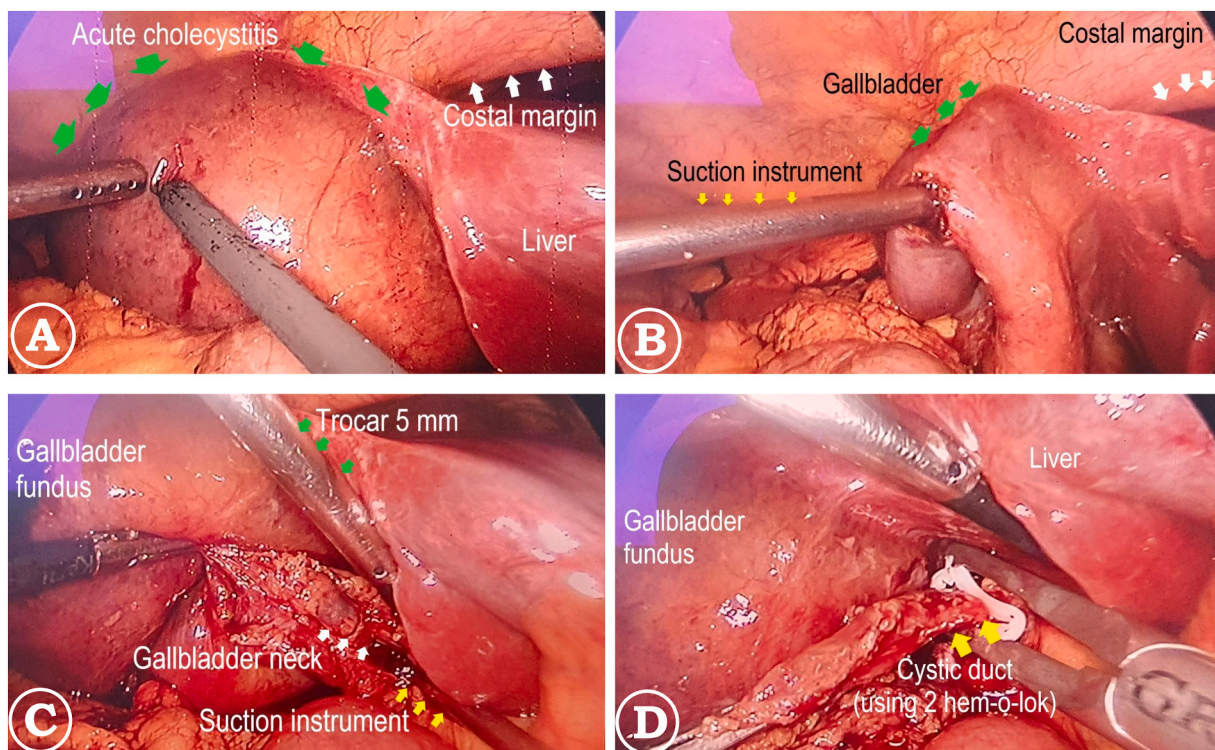


Fig. 3. Acute cholecystitis and cholecystectomy technique.

A- acute cholecystitis (blue arrow), B- Suction deflates the gallbladder, C-using a suction instrument (yellow arrow), dissection of the tissue surrounding the gallbladder neck (white arrow), and D- using hem-o-lok to clamp the cystic duct and gallbladder artery (yellow arrow). (For interpretation of the references to colour in this figure legend, the reader is referred to the web version of this article.)

3. Discussion

AS affects 0.4% of men and 0.05% of women, with a maximum incidence between 25 and 40 years [7–9]. Restrictive ventilatory defects and potential airway problems associated with this condition are of particular interest to the anaesthesiologist [9,10]. In addition, all joints are brittle and predisposed to easy fracture [7]. A detailed preoperative examination is warranted to identify cardiovascular, pulmonary, and haematological abnormalities [8,9]. Pneumoperitoneum and changes in position during the procedure can cause haemodynamic instability in patients with cardiopulmonary dysfunction [10]. However, even in high-risk patients, LC under general anaesthesia has been reported to be safe and feasible [11].

Our patient had been suffering from AS for more than 30 years. Shortness of breath and inability to extend the legs were common symptoms of this condition. Patient positioning is important because the head and neck must be held in place on pillows to achieve the finest feasible neutral position within the comfort range. As a result of their changed body habitus, individuals with AS are at a higher risk of vascular and visceral damage when pneumoperitoneum is created with the Veress needle or during primary port insertion. According to some authors, it is critical to use an open technique with the Hasson technique to avoid vascular complications. An intra-abdominal pressure of 8 mmHg was maintained throughout the surgery to avoid the haemodynamic implications of pneumoperitoneum. LC has been found to be safe at 8 mmHg intraabdominal pressure [10].

Table 1
Blood test characteristics of the patient.

Day	RBC	WBC	PLT	Proth%	IRN	Fibrinogen	Ure	Cre	Glu	GOT	GPT	Bil TP	Amyl	Albumin	Kali	CRP
D1	3.76	25.51	167	78	1.18	7.76	5.5	73	6.46	88	58	23.3	43.3		4.65	–
D2	3.58	18.08	199	66	1.33	7.68	11.6	71	5.5	242	90	46.2	–	31.9	4.4	–
D3	–	–	–	–	–	–	11.6	71	5.6	74	70	8	–	–	–	11.569
D4	–	–	–	–	–	–	9.3	61	–	–	–	–	–	31.5	–	2.24
D6	–	–	–	–	–	–	9.4	69	–	–	–	–	–	–	–	–
D7	3.53	11.1	289	70	–	–	8.9	75	–	–	–	–	–	–	–	–
D8	–	–	–	–	–	–	8.4	67	–	–	–	–	–	–	–	–
D9	–	–	–	–	–	–	5.8	65	–	–	–	–	–	–	4.3	–
D10	3.92	17.83	392	79	–	–	5.6	70	–	32	29	–	–	33.6	–	–
D14	4.25	18.83	433	84	–	–	5.4	69	5.2	30	25	8.9	–	32.9	5	2.257

RBC red blood cell, WBC white blood Cell, PLT platelet count, Proth% prothrombin %, IRN International Normalized Ratio, Cre creatinine, Glu glucose; GOT glutamat Oxaloacetat Transaminas, GPT glutamat pyruvat transaminase, Bil bilirubin, Amyl amylase, CRP C-reactive protein.

The findings revealed that the majority of blood biochemical values were within the standard parameters at the time of hospitalisation. The CRP level was significantly lower, but the white blood cell count remained higher than normal.

However, when the gallbladder is severely inflamed, dividing it to expose the Calot triangle is quite difficult. Surgeons must be extremely proficient in LC to avoid serious biliary tract injury, conversion to open surgery, or prolonged surgery. During laparoscopic surgery, it is essential to establish the critical view of safety (CVS), the gold standard, when performing LC. According to Nijssen et al., 8.8% of LCs developed complications (average age 51 years) and 1.7% had bile duct injuries [six patients (0.6%) had a major bile duct injury, type B, D, or E injury] [12]. Achieving the CVS before transection of the cystic artery and duct is important for reducing biliary duct injury in LC. However, according to Ahmad and Nassar, approximately 15.8% of CVS patients are unidentifiable [13]. However, in acute cholecystitis, the connective tissue around the gallbladder infiltrates with inflammatory fluid, making it more prone to bleeding. Therefore, we dissected it using a laparoscopic hook and suction and irrigation tube during surgery. First, we empty the gallbladder to make it easier to hold during the operation. The connective tissue surrounding the lower gallbladder was removed using a suction instrument (Fig. 3C). When accomplished, this method allows for easy exposure of the cystic duct without damaging the main biliary tract or tearing the cystic artery, which is a common problem when hooks are used for dissection. According to TG18, when the CVS cannot be obtained, open cholecystectomy should be considered [1].

Many surgical challenges are related to kyphoscoliosis due to low-lying costal arches, such as restricted abdominal working space and

reduced controllability of surgical equipment in AS patients [3,14]. However, several recent articles have demonstrated that LC can be successfully performed in patients with kyphoscoliosis [3,10,14,15]. This procedure creates a surgical field suitable for cholecystectomy using the traditional four-port technique [15]. However, this technique is not always effective. Three of seven patients with a crucial low-lying costal arch who had LC using rib rifting required conversion to laparotomy (Table 2) [3]. Preoperative MDCT images can be used to detect the operative difficulty associated with a low-lying costal arch, which can be controlled with careful preparation and the correct use of the rib lifting technique. Modification of the operative technique was made, adhering to the basic principles of LC. Because of the restricted abdominal cavity’s prognosis, we placed a 10-mm trocar extensively deviated to the left (typically, one 10-mm epigastric port) and a 5-mm trocar in the left iliac fossa, but the instrument’s flexion was not restricted to the patient’s leg. Placing three or four trocars is a personal preference for the surgeon. We suggest that one should not hesitate to install extra ports to facilitate safe surgical access. Severe senile kyphosis is not a contraindication to laparoscopic surgery, as evidenced by seven successful procedures with no intra- or postoperative complications [10]. However, patients with AS or kyphosis must be carefully assessed for respiratory dysfunction, cardiac impairment, difficult airway, and other special conditions. Anaesthesiologists and surgeons should collaborate with surgical decisions in patients with severe respiratory

Table 2
Clinical characteristics of 12 patients in the literature.

Author (year)	Chowbe (1) (2005)	Tajima and Kuroki (2) (2011)				Kim B-S (3) (2013)		Takayama (2016) (4)		Our (2021)			
		1	2	3	4	5	6	7	8	9	10	11	12
Case number	1	2	3	4	5	6	7	8	9	10	11	12	12
Pathology of the gallbladder	GB stone	GB stone	GB stone	GB torsion	GB torsion	GB torsion	GB stone	GB stone	GB stone	AC	AC	AC	AC
Age (years)	52	69	94	83	84	85	84	83	42	54	92	68	68
Sex	Female	Female	Female	Female	Female	Female	Female	Female	Male	Female	Female	male	male
Height (cm)	148	152	142	144	146	132	140	141	173.6	140	140	160	160
Body weight (kg)	63	36	40	48	43	34	35	41	68.9	45.6	48.2	40	40
Kyphoscoliosis	Yes	Yes	Yes	Yes	Yes	Yes	Yes	Yes	Yes	Yes	Yes	Yes	Yes
Liver edge above the costal arch ^a	Yes	Yes	Yes	Yes	Yes	Yes	Yes	Yes	Yes	No	Yes	Yes	No
Operative procedure	LC	LC- > OC	LC- > OC	LC- > OC	LC	LC	LC	LC	LC	LC	LC	LC	LC
Reason for laparotomy conversion	–	Small WS	Small WS	Small WS	–	–	–	–	–	–	–	–	–
Retraction of the costal arch	No	No	No	No	Yes	Yes	Yes	Yes	Yes	No	No	No	No
Operative time (min)	–	114	128	125	235	113	105	132	–	–	236	60	60
Blood loss (g)	–	45	60	160	20	120	15	76	–	–	A little	350	350
Days of hospital	2	–	–	–	–	–	–	–	3	5	9	14	14

GB Gallbladder, LC laparoscopic cholecystectomy, OC open cholecystectomy, WS working space, AC acute cholecystitis.

Most of them underwent LC complicated by a low-lying costal arch that limited the available working space required for open cholecystectomy.

^a The location of the lower liver edge against the costal arch was examined using multidetector computed tomography (MDCT) or intra-operation.

limitations.

Our patient benefitted from the remaining abdominal space, as the liver and gallbladder were not restricted by the costal margin. On contrary, dyspnoea caused by COPD is occasionally a contraindication to laparoscopic surgery. In our opinion, close monitoring of breathing, reduction of intra-abdominal inflating pressure, and proficient surgical technique were the variables that contributed to the success of laparoscopic surgery. In this condition, laparoscopic surgery benefits the patient by decreasing discomfort. Getting up early and performing breathing exercises also help the patient avoid respiratory infections and pressure ulcers.

The present study has certain limitations. First, the patient continues to have several comorbidities, including COPD, and restricted movement. Additional time is required to assess the quality of life and evaluate the liver and main biliary tract following surgery. Second, trocar placements such as in the present case can be extremely difficult to manage in cases of kyphosis due to the limited range of motion of the instrument. Therefore, either single-port laparoscopic surgery or the rib lift technique is an effective approach.

4. Conclusion

LC can be performed effectively in patients with severe AS, even with kyphosis and COPD. Four trocars should be placed effectively, and the surgeon should be proficient. Laparoscopic hook and suction instruments are simple techniques to use while dissecting the Calot triangle.

5. Consent

Doctor Son informs us of this disorder, which requires urgent surgery. Laparoscopic surgery is a challenging procedure that may require conversion to open surgery due to kyphosis or respiratory failure. We aimed to understand and approve LC. We understand and accept the risks associated with the procedure, including morbidity and mortality. We confirmed our informed consent by signing it.

Abbreviations

AS	Ankylosing spondylitis
CRP	C-reactive protein
TG18	Tokyo Guideline 2018
CCI	Charlson Comorbidity Index
ASA	American Society of Anesthesiology
COPD	Chronic Obstructive Pulmonary Disease
LC	Laparoscopic cholecystectomy
CVS	The critical view of safety

Informed consent

Written informed consent was obtained from the patient for publication of this case report and any accompanying images. A copy of the written consent is available for review by the Editor-in-Chief of this journal.

Sources of funding

None.

Ethical approval

Consent of the patient and the patient's wife. The director of the emergency center agreed to publish this clinical case.

Research registration

N/A.

Guarantor

Tran Que. Son, MD, PhD.

ORCID iD authorship contribution statement

Tran Que. Son, MD, PhD and Tran Hieu Hoc, Assoc. MD, PhD: study concept, data collection, data analysis, writing the paper, and final editing manuscript.

Declaration of competing interest

The authors declare that they have no competing interests.

Acknowledgements

We many thanks to Bui Thi Minh Hue - anesthesiologist, Dr. Nguyen Chien Quyet, Luong Cong Dinh – resident doctor who participated in surgery. We also many thanks Bhavana (Editage) for editing English language of this manuscript.

Provenance and peer review

Not commissioned, externally peer-reviewed.

References

- [1] G. Wakabayashi, Y. Iwashita, T. Hibi, T. Takada, S.M. Strasberg, H.J. Asbun, et al., Tokyo guidelines 2018: surgical management of acute cholecystitis: safe steps in laparoscopic cholecystectomy for acute cholecystitis (with videos), *J. Hepatobiliary Pancreat. Sci.* 25 (1) (2018) 73–86.
- [2] A.E. Giles, S. Godzisz, R. Nenshi, S. Forbes, F. Farrokhyar, J. Lee, et al., Diagnosis and management of acute cholecystitis: a single-Centre audit of guideline adherence and patient outcomes, *Can. J. Surg.* 63 (3) (2020) E241–E249.
- [3] Y. Tajima, T. Kuroki, A. Kitasato, T. Adachi, T. Kosaka, T. Okamoto, et al., Prediction and management of a low-lying costal arch which restricts the operative working space during laparoscopic cholecystectomy, *J. Hepatobiliary Pancreat. Sci.* 18 (1) (2011) 60–66.
- [4] F. Miura, K. Okamoto, T. Takada, S.M. Strasberg, H.J. Asbun, H.A. Pitt, et al., Tokyo guidelines 2018: initial management of acute biliary infection and flowchart for acute cholangitis, *J. Hepatobiliary Pancreat. Sci.* 25 (1) (2018) 31–40.
- [5] R.A. Agha, T. Franchi, C. Sohrabi, G. Mathew, A. Kerwan, Group S, The SCARE 2020 guideline: updating consensus Surgical Case Report (SCARE) guidelines, *Int. J. Surg.* 84 (2020) 226–230.
- [6] T.Q. Son, T.H. Hoc, N.T. Quyet, T.B. Giang, N.N. Hung, T.T. Tung, et al., Efficacy of laparoscopic-assisted pancreaticoduodenectomy in vietnamese patients with periampullary of Vater malignancies: a single-institution prospective study, *Ann. Med. Surg. (Lond.)* 69 (2021), 102742.
- [7] P. Thumbikat, R.P. Hariharan, G. Ravichandran, M.R. McClelland, K.M. Mathew, Spinal cord injury in patients with ankylosing spondylitis: a 10-year review, *Spine (Phila Pa 1976)* 32 (26) (2007) 2989–2995.
- [8] M.M. Ward, A. Deodhar, E.A. Akl, A. Lui, J. Ermann, L.S. Gensler, et al., American College of Rheumatology/Spondylitis Association of America/Spondyloarthritis research and treatment network 2015 recommendations for the treatment of ankylosing spondylitis and nonradiographic axial spondyloarthritis, *Arthritis Care Res.* 68 (2) (2016) 151–166.
- [9] P.K. Chowbey, R. Panse, R. Khullar, A. Sharma, V. Soni, M. Bajjal, Laparoscopic cholecystectomy in a patient with ankylosing spondylitis with severe spinal deformity, *Surg. Laparosc. Endosc. Percutan. Tech.* 15 (4) (2005) 234–237.
- [10] B.S. Kim, S.H. Joo, J.H. Joh, J.W. Yi, Laparoscopic cholecystectomy in patients with anesthetic problems, *World J. Gastroenterol.* 19 (29) (2013) 4832–4835.
- [11] A.M. Koivusalo, P. Pere, M. Valjus, T. Scheinin, Laparoscopic cholecystectomy with carbon dioxide pneumoperitoneum is safe even for high-risk patients, *Surg. Endosc.* 22 (1) (2008) 61–67.
- [12] M.A. Nijssen, J.M. Schreinemakers, Z. Meyer, G.P. van der Schelling, R.M. Crolla, A.M. Rijken, Complications after laparoscopic cholecystectomy: a video evaluation study of whether the critical view of safety was reached, *World J. Surg.* 39 (7) (2015) 1798–1803.

- [13] A.H.M. Nassar, H.J. Ng, A.P. Wysocki, K.S. Khan, I.C. Gil, Achieving the critical view of safety in the difficult laparoscopic cholecystectomy: a prospective study of predictors of failure, *Surg. Endosc.* 35 (11) (2020) 6039–6047.
- [14] T. Kuroki, Y. Tajima, N. Tsuneoka, T. Adachi, T. Kanematsu, Rib-lifting method for retraction of the low-lying costal arch in laparoscopic cholecystectomy of gallbladder torsion with kyphoscoliosis, *Hepato-Gastroenterology* 56 (94–95) (2009) 1268–1269.
- [15] T. Takayama, S. Yamamura, T. Obana, S. Yamasaki, K. Nishio, Successful laparoscopic cholecystectomy for acute cholecystitis with kyphoscoliosis by the devised placement of trocar ports: a case report, *Int. J. Surg. Case Rep.* 28 (2016) 88–92.