

# Application of pigtail catheter tailing combined with long-wire swapping technique in cerebral angiography via the right radial artery

Dan Yan, MD, Bifeng Zhu, MD, Qin Li, MD, Tao Peng, MD, Jingfang Jiang, MD, Jianlin Liu, MD, Bitang Dan, PhD\*

## Abstract

The safety and feasibility of transradial approach for cerebral angiography has been confirmed previously. However, this approach has been limited used due to the difficulty during the procedure. This study aimed to introduce a pigtail catheter tailing and long-wire swapping technique to improve the success rate without increasing complications.

From August 2015 to December 2018, 560 patients who underwent cerebral angiography via transradial approach were recruited. The data including the type of aortic arch, type of Simmon catheter were collected.

The loop was successfully constructed in 553 patients using Simmon-2 or Simmon-1 catheter. Of these patients, 72 patients successfully underwent cerebral and renal angiography, while 481 patients underwent cerebral angiography. The time for angiography was  $52.87 \pm 11.23$  minutes and  $47.8 \pm 11.8$  minutes, respectively. There were 369 (66.7%), 135 (24.4%), and 49 (8.9%) patients with type I, type II, and type III aortic arches, respectively, and their success rates of looping using Simmon-2 catheter were 97.8%, 97.0%, and 89.8%, respectively. The success rates of angiography in the right internal carotid artery, right vertebral artery, left internal carotid artery, and left vertebral artery were 100%, 100%, 98.9%, and 98.9%, respectively. No serious complications were observed in all patients.

The pigtail catheter tailing and long guidewire swapping is considered as a safe procedure with high success rate for loop construction using a Simmon-2 catheter through the right radial artery, subsequently improving the success rate as well as the efficiency of angiography.

**Abbreviation:** CTA = computed tomographic angiography.

**Keywords:** cerebral angiography, long guidewire swapping, pigtail catheter tailing, right radial artery

## 1. Introduction

In the past 20 years, the transfemoral approach of cerebral angiography has been gradually changed to transradial approach due to its safety and feasibility.<sup>[1–5]</sup> The radial artery puncture

angiography has been accepted by more and more patients for the fewer complications, shorter hospital stay, privacy, etc.<sup>[6–9]</sup> However, cerebral angiography via transradial approach requires construction of a loop, which is relatively difficult, especially for patients with type II and III aortic arches. This approach assists in directly determining the success rate of selective angiography for vessels in superior arches,<sup>[1,5]</sup> thus limiting the wider application of transradial approach. Currently, there are few studies regarding the details of catheter-looping techniques. In the last 3 years, more than 500 cases of cerebral angiography via right radial artery were performed in our center, and the pigtail catheter tailing and long-wire swapping technique improved the success rates of looping as well as shorten the angiography time. Hence, this study aimed to introduce pigtail catheter tailing and long-wire swapping technique, and explored the application of this technique in patients undergoing cerebral angiography via the right radial artery.

## 2. Methods

This study was approved by the Institutional Review Board of the hospital and was in compliance with the Health Insurance Portability and Accountability Act regulations and the Declaration of Helsinki. The Institutional Review Board waived off the need for individual patient consent. The inclusion criteria for cerebral angiography or/and renal angiography via right radial artery were as follows: patients aged  $\geq 18$  year; and successful

Editor: Marco Onofri.

DY and BD contributed equally to this work.

This work was supported by Hubei Provincial Health Commission guidance Project (WJ2019F177).

The authors have no funding and conflicts of interest to disclose.

Supplemental Digital Content is available for this article.

Department of Neurology, Hubei No.3 People's Hospital of Jiangnan University, Wuhan, China.

\* Correspondence: Bitang Dan, Department of Neurology, Hubei No.3 People's Hospital of Jiangnan University, No.26 Zhongshan Avenue, Hankou District, 430022 Wuhan, P.R. China (e-mail: 124263296@qq.com)

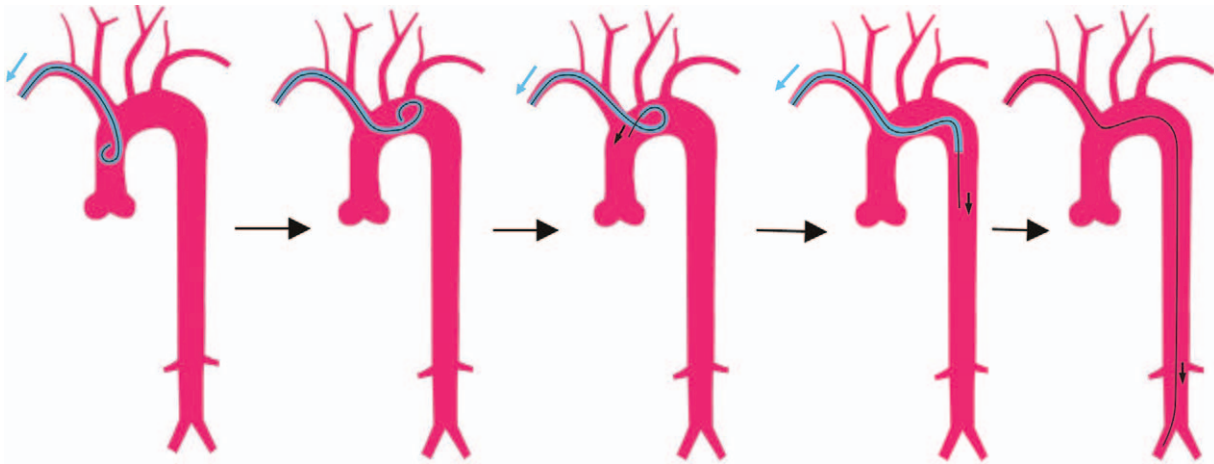
Copyright © 2020 the Author(s). Published by Wolters Kluwer Health, Inc. This is an open access article distributed under the terms of the Creative Commons Attribution-Non Commercial License 4.0 (CCBY-NC), where it is permissible to download, share, remix, transform, and buildup the work provided it is properly cited. The work cannot be used commercially without permission from the journal.

How to cite this article: Yan D, Zu B, Li Q, Peng T, Jiang J, Liu J, Dan B. Application of pigtail catheter tailing combined with long-wire swapping technique in cerebral angiography via the right radial artery. *Medicine* 2020;99:39(e22309).

Received: 9 October 2019 / Received in final form: 6 December 2019 /

Accepted: 21 August 2020

<http://dx.doi.org/10.1097/MD.00000000000022309>



**Figure 1.** Technique of pigtail catheter tailing. Black arrow=long guidewire direction, Black=long guidewire, Blue arrow=pig tail catheter direction, Blue=pig tail catheter, Green arrow=SIM catheter direction, Green=SIM catheter.

puncturing via the right radial artery. Exclusion criteria were as follows: patients with iodine allergy; negative Allen test; who do not operate with cerebral angiography due to systemic diseases or mental illnesses; and in emergency cerebral angiography or cerebral angiography with intervention therapy or coronary angiography. Between August 2015 and December 2018, 560 patients undergoing cerebral angiography or/and renal angiography by the right radial artery were included. All angiograms were performed by two physicians from the same team. Data including the basic information, type of aortic arch, type of Simmon catheter, topical and systemic complications were collected.

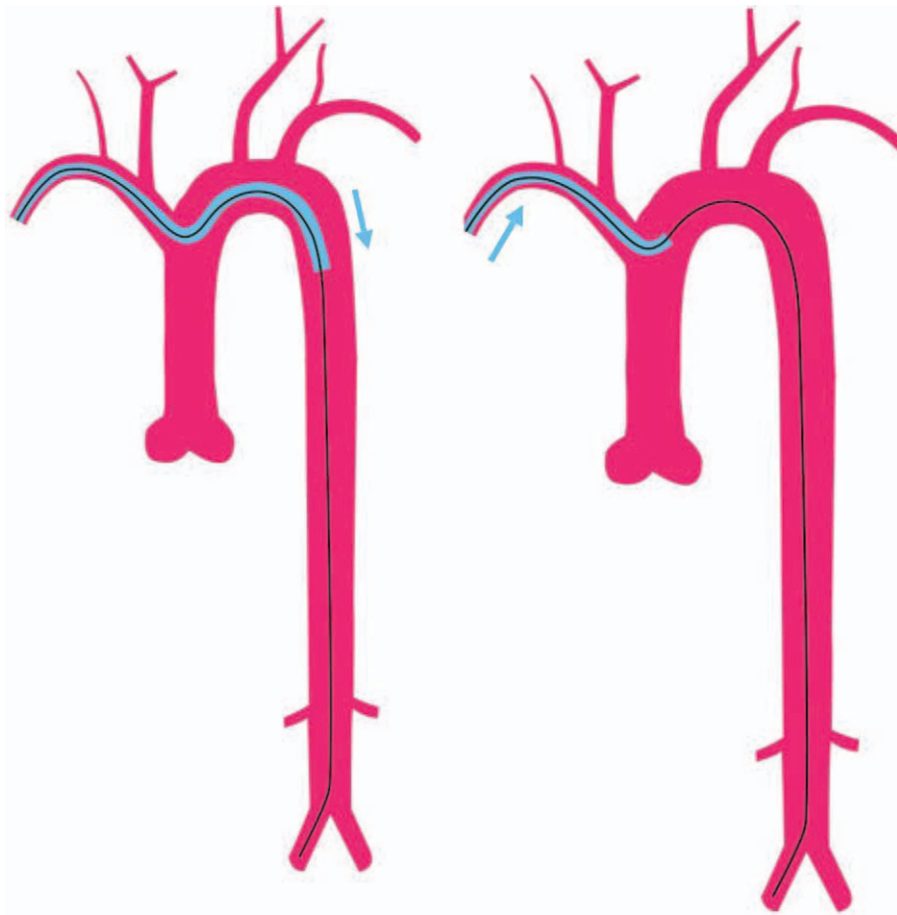
### 3. Technique

1. Bilateral blood pressure and Allen test were performed in patients before the procedure. Usually, the right radial artery was target vessel. The radial artery was punctured by Seldinger method after infiltration with 2% lidocaine. The straight guide-wire with soft head (RS A50G16SQZ, TERUMO Tokyo, Japan) was inserted through the cannula, followed by injection of 0.2 mg nitroglycerin through the lateral tube of the sheath tube, and an intravenous injection of 2500 IU heparin for heparinization.
2. Aortic arch angiography: The 5 F pigtail catheter (Tempo Angiographic Catheter: 451531H5 Cordis Corporation, USA) was driven into the ascending aorta under the guidance of long guide wire (260 cm, RF GA35263 M, TERUMO, Tokyo, Japan). The aortic arch angiography was then performed after the alignment.
3. Technique of pigtail catheter tailing
  - a. After the aortic arch angiography was performed by the pigtail catheter tailing, the catheter was slowly withdrawn from the horizontal portion of the aortic arch near the opening of the innominate artery (the head facing up).
  - b. A long guide-wire was then passed through the pigtail catheter, extended to 3-5 mm, and then was fixed. The pigtail catheter was slowly withdrawn, and the guide-wire was placed in the descending aorta by utilizing the swinging force of the instantaneous oscillation of the pigtail catheter

- c. The guidewire was placed at the distal end of the left or right iliac artery along the thoracic and abdominal aortas (Fig. 1 and video1 {Video 1: Technique of pigtail catheter tailing <http://links.lww.com/MD/E917>})
4. "Pigtail catheter pass test": An attempt was made to insert the pigtail catheter from the ascending aorta to the descending aorta. Simmon-2 catheter (Tempo Angiographic Catheter: 451503HO, Cordis Corporation, USA) was selected if the attempt was successful, while Simmon-1 catheter (Tempo Angiographic Catheter: 451503HO, Cordis Corporation, USA) was selected directly if the attempt was unsuccessful. (Fig. 2)
  5. Loop: The pigtail catheter was exchanged with a Simmon-2 or Simmon-1 catheter, followed by insertion to reach the horizontal portion of the aortic arch and the descending aorta. The guidewire was withdrawn and then the catheter was pushed forward to construct a loop. The "U" loop was constructed by withdrawing the guidewire and delivering the Simmon catheter into the ascending aorta (Fig. 3 and Video 2 {Video 2. The "U" loop was constructed by the Simmon catheter <http://links.lww.com/MD/E918>.}).
  6. Angiography: In patients with vasospasm, anatomical abnormality or failure of the looping was changed to perform the puncture via the right femoral artery or left radial artery. The patients then sequentially underwent angiography in the left vertebral artery, the left internal carotid artery, the right internal carotid artery and the right vertebral artery, which were performed in the anteroposterior and lateral positions. (Fig. 4).
  7. Delivering the guidewire and Compressing: After the end of the angiography, the guidewire was delivered, with its head pointing into the descending aorta. The Simmon catheter was removed after its head was straightened, and the sheath of the radial artery was then directly removed, followed by the application of compression bandage with elastic bandage for 6 hour. The topical and systemic complications from surgery till discharge were observed.

#### 3.1. Data management and statistical analysis

The data were managed and analyzed by using SPSS18.0. Data are expressed as means±standard deviation for continuous variables and as median and range for categorical variables.



**Figure 2.** Pigtail catheter pass test<sup>®</sup>: An attempt was made to insert the pigtail catheter from the ascending aorta to the descending aorta. Simmon-2 catheter or Simmon-1 catheter was used during the procedure.

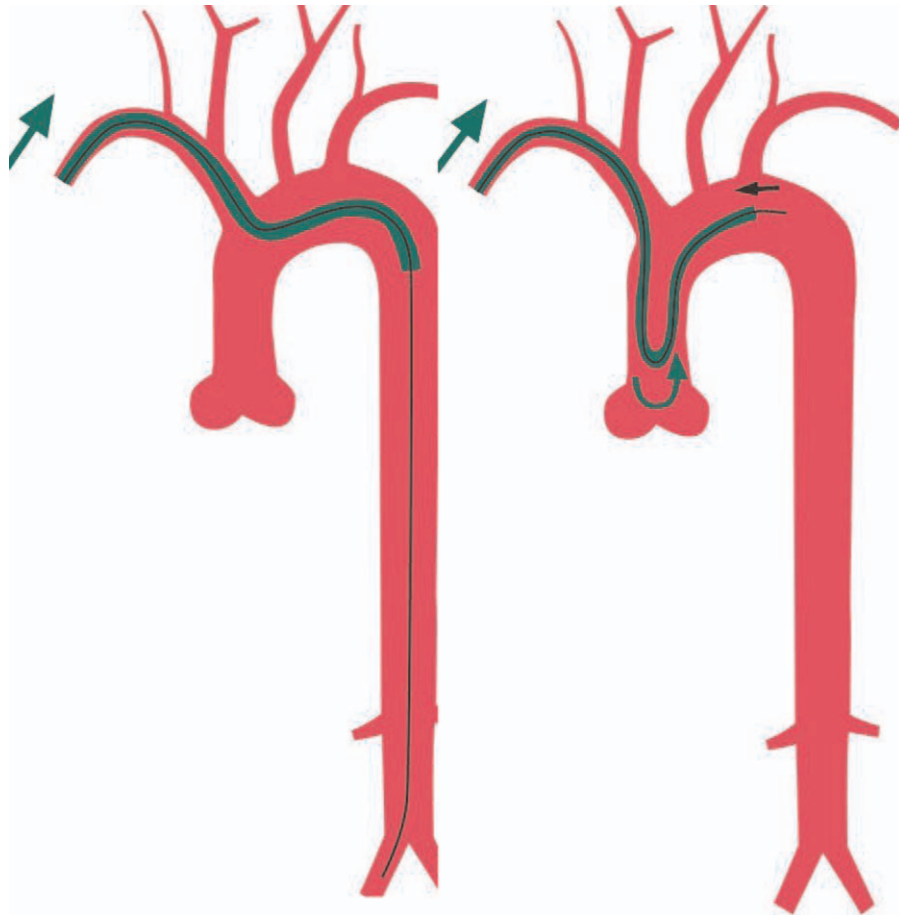
#### 4. Results

Five hundred sixty patients were included to this study. Seven patients were excluded as pigtail catheter failed to reach the aortic arch due to vasospasm or severe tortuosity of the right radial artery. The loop was successfully constructed in 553 patients using a Simmon-2 or Simmon-1 catheter, including 355 males with an average age of 62.1 (26–87 y) and 198 females with an average age of 62.9 (30–82 yr). Of the 553 patients, 72 had successful cerebral and renal angiography, and 481 patients had successful cerebral angiography. The time for angiography was  $52.87 \pm 11.23$  minutes and  $47.8 \pm 11.8$  minutes, respectively. The success rate of looping using Simmon-2 catheter was 96.9%, while 17 (3.1%) patients changed to looping using Simmon-1 catheter due to difficulty in looping with Simmon-2 catheter or directly underwent looping using Simmon-1 catheter after assessment with “pigtail catheter pass test.” There were 369 (66.7%), 135 (24.4%), and 49 (8.9%) patients with type I, type II, and type III aortic arches, respectively. The success rates of looping using Simmon-2 catheter in these patients were 97.8%, 97.0%, and 89.8%, respectively. Meanwhile, the success rates of angiography in the right internal carotid artery, right vertebral artery, left internal carotid artery and left vertebral artery were 100%, 100%, 98.9%, and 98.9%, respectively (Fig. 5) No local

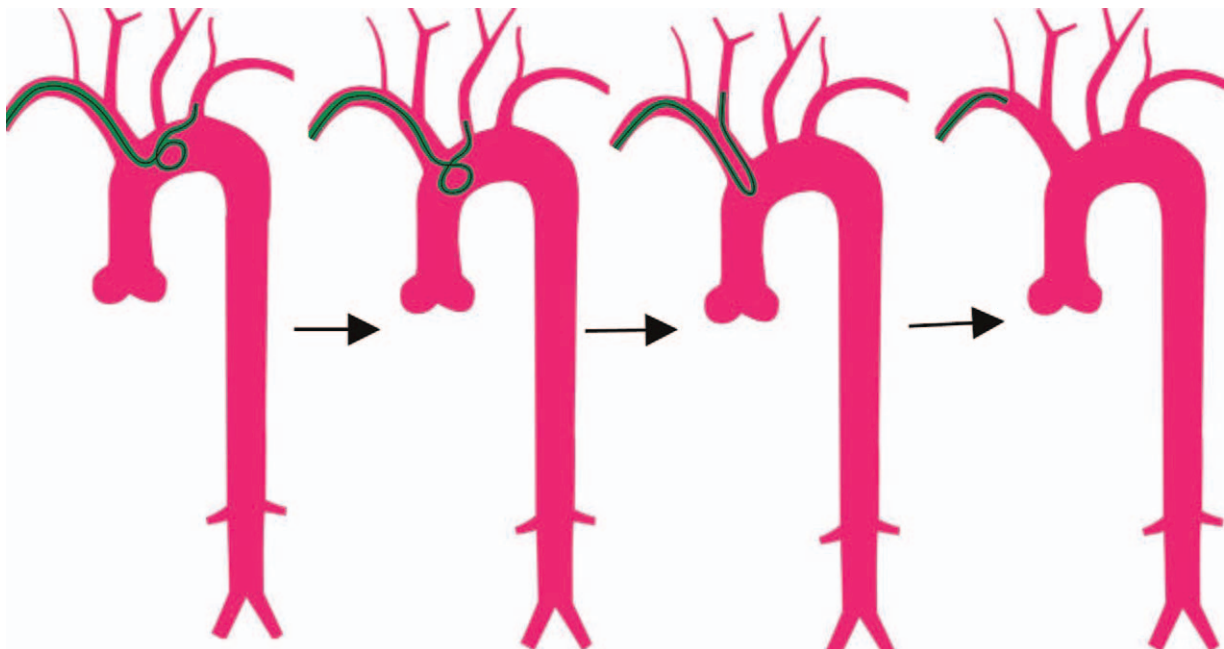
serious complications were observed, and there was one case with serious systemic complication of acute myocardial infarction (Tables 1 and 2).

#### 5. Discussion

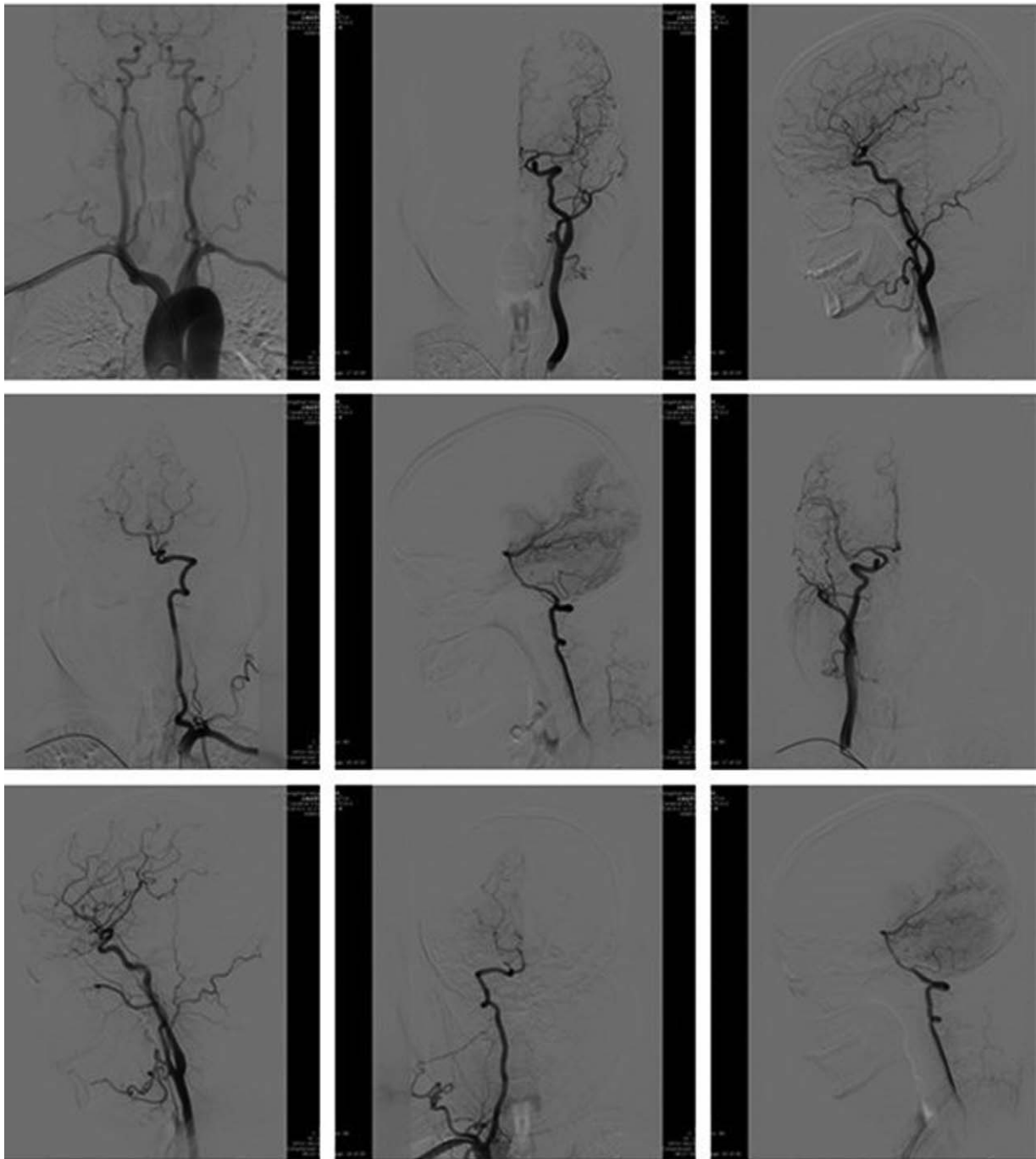
Transradial approach cerebral angiography has been a successful procedure clinically due to its safety and feasibility. The key procedure of this approach was constructing a loop with the catheter above the arch.<sup>[10,11]</sup> At present, looping in the descending aorta is the most common and safe procedure due to its high successful rate, short operation time, and no passing of the catheter through heart. However, this conventional technique is suitable only for patients with type I aortic arch or type II aortic arch. In patients with tortuous type II and type III aortic arches, this technique is not suitable for difficult delivering the guidewire from the ascending aorta to the descending aorta.<sup>[5]</sup> As Simmon-1 catheter has a short head end that cannot reach the origin of left vertebral artery and left internal carotid artery, the success rate of catheterization via these arteries remained low. Hence, a Simmon-2 catheter was used for constructing loop during the procedure. In our center, Simmon-2 catheter was directly implemented in patients with type I and II aortic arch. In patients with type III aortic arches, the catheter was determined



**Figure 3.** Loop. The “U” loop was constructed by withdrawing the guidewire and delivering the Simmon catheter into the ascending aorta.



**Figure 4.** Angiography: The patients then sequentially underwent angiography in the left vertebral artery, the left internal carotid artery, the right internal carotid artery and the right vertebral artery, which were performed in the anteroposterior and lateral positions.



**Figure 5.** The figures of successful angiography in the right internal carotid artery, the right vertebral artery, the left internal carotid artery and the left vertebral artery.

by the pigtail catheter passing test, which may decrease the time and materials. Simmon-I catheter was selected in patients with the pigtail catheter difficultly reaching the descending aorta, while Simmon-II catheter was selected in type III patients with the pigtail catheter reaching the descending aorta. In this study, looping was successfully constructed by a Simmon-2 catheter in 96.9% of patients, the success rates using Simmon-2 catheter were specifically observed in patients with type II and type III aortic arches (97.0% and 89.8%, respectively). This significantly improved the success rates of left superior arch angiography in

patients with type II and type III aortic arches. Yang Haihua et al<sup>[11]</sup> demonstrated the long-wire swapping technique in patients with type II or type III aortic arches, achieving a 97.8% success rate of looping with Simmon-2 catheter, while a 72.9% success rate of looping without the long-wire swapping technique. A 260cm long-guidewire and the pigtail tailing technique could improve the constructing looping with Simmon-2 catheter. The long guidewire was passed through the pigtail catheter and extended 3 to 5mm; and then the pigtail catheter was slowly withdrawn. The guide-wire was delivered to the

**Table 1**  
**Demographic data.**

Variable	N=553
Gender (M/F)	355/198
Age (yr.)[range]	62.41 ± 9.69 (26–87)
Types of aortic arch	
I	369 (66.7%)
II	135 (24.4%)
III	49 (8.9%)
Successful Simmon-2 looping	
I	361 (97.8%)
II	131 (97.0%)
III	44 (89.8%)
Time of angiography (mins)	
Cerebral angiography	47.8 ± 11.8 (15–90)
Cerebral + renal angiography	52.87 ± 11.23 (22–80)

descending aorta by oscillating the pigtail catheter, and delivering the guidewire slowly into the iliac artery, which guiding the Simmon catheter to the descending aorta and providing a good support, improving constructing the looping with catheters.

Successful looping of the catheter remains the cornerstone of supra-aortic angiography. Previous studies have reported that looping in the descending aorta with Simmon-1 or Simmon-2 catheter and non-swapping guidewire (150 cm). The success rates in the right vertebral artery, right internal carotid artery, left internal artery, and left vertebral artery were respectively 96.1%, 98.6%, 82.6%, and 52.2%.<sup>[11]</sup> In this study, all patients who underwent the right carotid artery and right vertebral artery angiography had successful outcomes, which was similar with the results. However, the success rates of both left carotid artery and left vertebral artery angiography in our study were 96.9%, notable improvement compared with the results. This might be associated with high successful rates using Simmon-2 catheter as mentioned above. The head and neck CTA may be used before the procedure to identify the aortic arch type, which may be rational for the puncturing artery and improving the successful rates.

**Table 2**  
**Complications.**

Variables	N=553
Partial complications (trivial)	25 (4.5%)
Cyanotic	12
Callosity	5
Pain of right upper limb	6
Radial artery spasm	14
Partial complications (serious)	2 (0.4%)
Radial artery rupture	0
Partial hematoma	0
Radial artery occlusion	1
Persistent paralysis of right upper limb	2
Systemic complications	21 (3.8%)
Acute cardiovascular disease	1
Acute cerebrovascular disease	0
Arrhythmia	0
Injury of celiac artery	0
Allergy	16
Others	4

The safety of transradial cerebral angiography has also been confirmed.<sup>[1–5]</sup> In this study, 4.5% of patients had mild local complications, which was similar to the reported results (6.75%).<sup>[5]</sup> Fourteen cases (2.5%) had radial spasm, which was lower than the prevalence of 6% to 10% in patients receiving anticonvulsant therapy.<sup>[12]</sup> Long guidewire swapping technique avoids vascular vasospasm and radial artery occlusion caused by re-stimulation of radial artery during the guidewire swapping. In this study, two patients were detected with right upper limb weakness. One case diagnosed with occlusion of the right radial artery with good collateral circulation by Doppler sonography. The Meta analysis conducted by Muhammad et al showed that the incidence of radial occlusion ranged from less than <1% to 30%, and no clinical symptoms observed.<sup>[13]</sup> Asymptomatic vascular complications (9.6%) could be found by preoperative and postoperative puncture of arteries in the upper extremities and ultrasound examination.<sup>[14]</sup> Doppler ultrasound of the radial artery was not routine used in our center, which may miss the asymptomatic patients with radial artery occlusion. In future, the routine radial artery ultrasonography should be used during angiography, which may improve the diagnostic rate of radial artery occlusion and vasospasm. Sixteen patients had rash, nausea, and chest tightness during or after angiography, and all of which occurred due to iodine allergy (even if the iodine allergy test was negative before angiography). The long guidewire was fixed when delivering it to the iliac artery or femoral artery, avoiding damage to the celiac artery. The technique of placing a long guidewire in the iliac artery or femoral artery not only improves the constructing loop but also reduces the probability of celiac artery injury.

However, this study has some limitations. First, this is a retrospective study, and data was obtained from electronic medical record system. Some minor complications might not be recorded. But this study mainly focused on the pigtail tailing and long guidewire swapping technique in constructing the loop with little complications. Second, there is no randomized control trials data to compare the cerebral angiography via femoral and radial approach.

## 6. Conclusion

The results of this study showed that the pigtail catheter tailing and long guidewire swapping technique is safe in patients underwent transradial approach cerebral angiography, which may improve the success rate of constructing loop with Simmon-2 catheter. This subsequently improved the success rate and efficiency of angiography, which may be worth promoting clinically.

## Author contributions

**Conceptualization:** Jianlin Liu.

**Data curation:** Dan Yan.

**Formal analysis:** Bifeng Zu.

**Investigation:** Dan Yan.

**Resources:** Tao Peng.

**Software:** Tao Peng.

**Validation:** Jingfang Jiang.

**Visualization:** Jingfang Jiang.

**Writing – original draft:** Dan Yan.

**Writing – review & editing:** Jianlin Liu.

## References

- [1] Jo KW, Park SM, Kim SD, et al. Is transradial cerebral angiography feasible and safe? A single Center's experience. *J Korean Neurosurg Soc* 2010;47:332–7.
- [2] Park JH, Kim DY, Kim JW, et al. Efficacy of transradialcerebralangiography in the elderly. *J Korean Neurosurg Soc* 2013;53:213–7.
- [3] Mitchell MD, Hong JA, Lee BY, et al. Systematic review and cost-benefit analysis of radial artery access for coronary angiography and intervention. *Circ Cardiovasc QualOutcomes* 2012;5:454–62.
- [4] Hamon C, Pristipino C, Di Mario C. Consensus document on the radial approach in percutaneous cardiovascular interventions: position paper by the European Association of Percutaneous Cardiovascular Interventions and Working Groups on Acute Cardiac Care and Thrombosis of the European Society of Cardiology. *J Euro Intervention* 2013;8:1242–51.
- [5] Snelling BM, Sur S, Shah SS, et al. Transradial cerebral angiography: techniques and outcomes. *J NeuroIntervent Surg* 2018;0:1–9.
- [6] Mattea V, Salomon C, Menck N, et al. Low rate of access site complications after transradial coronary catheterization: a pro-spective ultrasound study. *Int J Cardiol Heart Vasc* 2016;14:46–52.
- [7] Bhat FA, Chagal KH, Raina H, et al. Transradial versus transfemoral approach for coronary angiography and angioplasty—a prospective, randomized comparison. *BMC Cardiovasc Disord* 2017;17:23.
- [8] Satti SR, Vance AZ, Golwala SN, et al. Patient preference for transradial access over transfemoral access for cerebrovascular procedures. *J Vasc Interv Neurol* 2017;9:1–5.
- [9] Kok MM, Weernink MGM, von Birgelen C, et al. Patient preference for radial versus femoral vascular access for elective coronary procedures: the PREVAS study. *Catheter Cardiovasc Interv* 2018;91:17–24.
- [10] Jianhu L, Chuan L, Huajun B, et al. Application of transradial artery approach in cerebral angiography. *Chin J Neurosurg* 2017;33:1153–6.
- [11] Yang H, Zhou X, Liu L. Application of long guidewire exchange technique in cerebral angiography via radial artery access. *J Interv Radiol* 2017;26:676–80.
- [12] Caputo RP, Tremmel JA, Rao S, et al. Transradial arterial access for coronary and peripheral procedures: executive summary by the Transradial Committee of the SCAI. *Catheter Cardiovasc Interv* 2011;78: 823–39.
- [13] Muhammad R, Chun SK, Samir P, et al. Radial artery occlusion after transradial interventions: a systematic review and meta-analysis. *J Am Heart Assoc* 2016;5:e002686.
- [14] Wonki Y, Woo-Keun K, Omar C, et al. Complications following transradial cerebral angiography: an ultrasound follow-up study. *J Korean Neurosurg Soc* 2018;61:51–9.