

This is an Open Access article licensed under the terms of the Creative Commons Attribution-NonCommercial-NoDerivs 3.0 License (www.karger.com/OA-license), applicable to the online version of the article only. Distribution for non-commercial purposes only.

IGF-II Producing Hepatocellular Carcinoma Treated with Sorafenib: Metabolic Complications and a Foresight to Molecular Targeting Therapy to the IGF Signal

Kazuya Okushin^a Yoshinari Asaoka^a Izumi Fukuda^b
Naoto Fujiwara^a Tatsuya Minami^a Masaya Sato^a
Shintaro Mikami^a Koji Uchino^a Kenichiro Enooku^a
Yuji Kondo^a Ryosuke Tateishi^a Tadashi Goto^a
Shuichiro Shiina^a Haruhiko Yoshida^a Kazuhiko Koike^a

^aDepartment of Gastroenterology, Graduate School of Medicine, The University of Tokyo, and ^bDepartment of Medicine II, Tokyo Women's Medical University, Tokyo, Japan

Key Words

IGF-II · Hepatocellular carcinoma · Sorafenib · Metabolic complications · Molecular targeting therapy · IGF signal · Hypoglycemia

Abstract

Hypoglycemia is a rare paraneoplastic manifestation of patients with neoplasms. Hypoglycemia can be induced by several causes, including an aberrant increase of hypoglycemic agents and adrenal insufficiency. Sorafenib is the first agent to demonstrate a survival benefit in the treatment of advanced hepatocellular carcinoma (HCC). This small molecule inhibits serine/threonine kinase RAF in tumor cells and tyrosine kinases VEGFR/PDGFR in tumor vasculature and decreases tumor growth and angiogenesis. In this paper, we report a case of HCC who was treated with sorafenib and showed severe hypoglycemia. This hypoglycemia might be induced by two causes, both adrenal insufficiency as an adverse effect of sorafenib and activation of the insulin-like growth factor (IGF) signal by excessive secretion of incompletely processed precursors of IGF-II. Although the IGF signal is suggested to be involved in aberrant growth of HCC in some cases, there is no other report showing the influence of sorafenib on HCC with active IGF signal. Unfortunately, the effect of sorafenib was limited in the present case. However, emerging drugs that directly inhibit the IGF signal can be expected to be highly effective in the treatment of HCC with hypoglycemia.

Introduction

Hypoglycemia is a rare but well-known paraneoplastic manifestation of patients with neoplasms, including hepatocellular carcinoma (HCC), which is referred to as non-islet cell tumor-induced hypoglycemia (NICTH) [1]. Excessive secretion of incompletely processed precursors of insulin-like growth factor-II (termed the 'big' IGF-II) has been suggested to cause NICTH. The IGF signal is involved in both glucose metabolism and cellular proliferation [2]. The 'big' IGF-II excessively stimulates both IGF-I and the insulin receptor, inducing hypoglycemia and tumor growth. In the era of molecular-targeted therapy, agents targeting the IGF signal are being developed to treat lung and pancreatic cancers [3]. Although this signal is suggested to be involved in aberrant growth of HCC [4], clinical trials using these agents against HCC have been initiated only recently.

Sorafenib is the first agent to demonstrate a survival benefit in the treatment of advanced HCC [5]. This small molecule inhibits serine/threonine kinase RAF in tumor cells and tyrosine kinases vascular endothelial growth factor receptor (VEGFR)/platelet-derived growth factor receptor (PDGFR) in the tumor vasculature, decreasing tumor growth and angiogenesis.

In this paper, we report a case of HCC that showed severe hypoglycemia and was treated with sorafenib. Since RAF is one of the downstream components of the IGF signal, sorafenib may be effective against tumors with an activated IGF signal. Although the effect was limited in the present case, emerging drugs that directly inhibit the IGF signal can be expected to be highly effective in the treatment of HCC with NICTH.

Case Report

A 77-year-old male patient with HCC was referred to the authors' hospital. As he had no previous episodes of liver disorders, no imaging procedures had been performed. In February 2010, he was first admitted to another hospital due to bleeding gastric ulcers induced by non-steroidal anti-inflammatory drugs. During hospitalization, an abdominal CT scan showed multiple liver tumors and multiple lung nodules (fig. 1a, b). Based on elevated serum AFP (897 ng/ml) and typical CT scan images as HCC, he was diagnosed as advanced HCC and referred to our hospital in March 2010.

Administration of sorafenib was initiated at a dosage of 800 mg b.i.d. On day 7, pleural effusion was detected and his serum potassium concentration was elevated to 5.5 mEq/l. His general condition declined and he was unable to stand by day 11. On day 14, he was hospitalized because of hyperpotassemia (6.7 mEq/l) and hypoglycemia (27 mg/dl). Hyperpotassemia improved by the administration of an intravenous drip infusion of glucose and furosemide, but hypoglycemia continued at a level of 40 mg/dl. Although the basal levels of adrenal hormones were normal, ACTH and cortisol did not increase at the time of hypoglycemia. This suggested that the relative adrenal insufficiency exerted some influence on the hypoglycemia. We started to administer a short-acting corticosteroid (hydrocortone), and the blood glucose level increased rapidly to around 150 mg/dl.

However, several days later, the patient's morning fasting blood glucose level decreased to around 20 mg/dl. We administered a longer-acting corticosteroid and the patient also began to have late evening snacks. Although a sufficient amount of cortisol (prednisolone 10 mg/day) was administered, his hypoglycemia continued. We suspected that other factors were involved in the hypoglycemia, but the serum levels of insulin and IGF-I were lower than the normal limits. We assayed the patient's serum using immunoblotting with an anti-IGF-II antibody. The 'big' IGF-II was detected in the serum (fig. 2, lane 2) similarly to the serum of a patient with NICTH (lane 4). Only mature IGF-II was detected in the serum of the normal control (lane 3). Lane 1 was recombinant IGF-II.

By day 14 of sorafenib administration, though the number of lung metastases had increased (fig. 1d), the size of the liver tumors had not changed (fig. 1c) and the tumor marker levels had decreased (AFP from 4,112 to 2,381 ng/ml and PIVKA-II from 4,645 to 952 mAU/ml) (fig. 3). We concluded that sorafenib was effective. The dose of sorafenib was decreased to half (400 mg b.i.d.), and the patient was discharged. Ten days later, he was hospitalized because of unconsciousness caused by hypoglycemia. Though the hypoglycemia improved with treatments, sadly the patient died 6 days later of respiratory failure due to advanced lung metastases.

Discussion

We treated a case of IGF-II producing HCC with sorafenib. Several previous reports have shown NICTH as a rare paraneoplastic manifestation of advanced HCC with a poor prognosis [6]. As far as we are aware, there are no reports describing HCC with NICTH treated with this novel molecular targeted agent, sorafenib. The present case showed interesting endocrine abnormalities such as hypoglycemia and hyperpotassemia due to relative adrenal insufficiency. The possibility that sorafenib suppressed adrenal function must be considered, since there were no other factors known to affect adrenal function such as metastasis to the adrenal glands. No reports have been identified that describe adrenal insufficiency due to sorafenib, while the drug is reported to affect thyroid functions. The possibility that sorafenib played a role in adrenal insufficiency is also supported by the fact that there are some reports of adrenal dysfunction caused by a similar molecular agent, sunitinib, targeting VEGFR/PDGFR [7].

The IGF signal is related to cell proliferation and tumor growth of HCC through the IGF-I receptor [4]. Kaseb et al. [8] reported that lower plasma IGF-I levels are correlated with advanced HCC and poor overall survival. Reactivation of IGF-II, including the 'big' IGF-II, is one of the most frequent mechanisms of IGF signal activation in HCC. Expression of IGF-I may be suppressed by a negative feedback of IGF-II overexpression, resulting in lower plasma IGF-I levels.

The 'big' IGF-II is suggested to induce hypoglycemia through IGF-I and the insulin receptor. Usually, hypoglycemia due to the 'big' IGF-II is not controllable with continuous infusion of glucose. Reduction of tumor volume by surgical operation [9], transarterial chemoembolization or systemic chemotherapy [1] is sometimes effective. Palliative treatments, including administration of hyperglycemic hormones such as corticosteroids and growth hormones, are performed, but the effects are transient and limited.

When the IGF-I receptor is stimulated, the downstream signaling pathways, including PI3K-AKT-TOR and RAF-MEK-ERK, are activated [2]. Sorafenib inhibits the activation of RAF. However, the efficacy of sorafenib was limited in the present case (fig. 3). Several drugs that target the IGF signal are under development [3]. Such drugs directly inhibit intracellular kinase activities or block the binding of IGF to the receptors. We suggest that these agents will likely be effective in NICTH cases. In particular, use of antibodies against IGF-II will probably be selective and safe in such cases.

Acknowledgements

This work was supported in part by Health Sciences Research Grants of The Ministry of Health, Labor and Welfare of Japan (Research on Hepatitis).

Disclosure Statement

The authors have no competing interests to disclose.

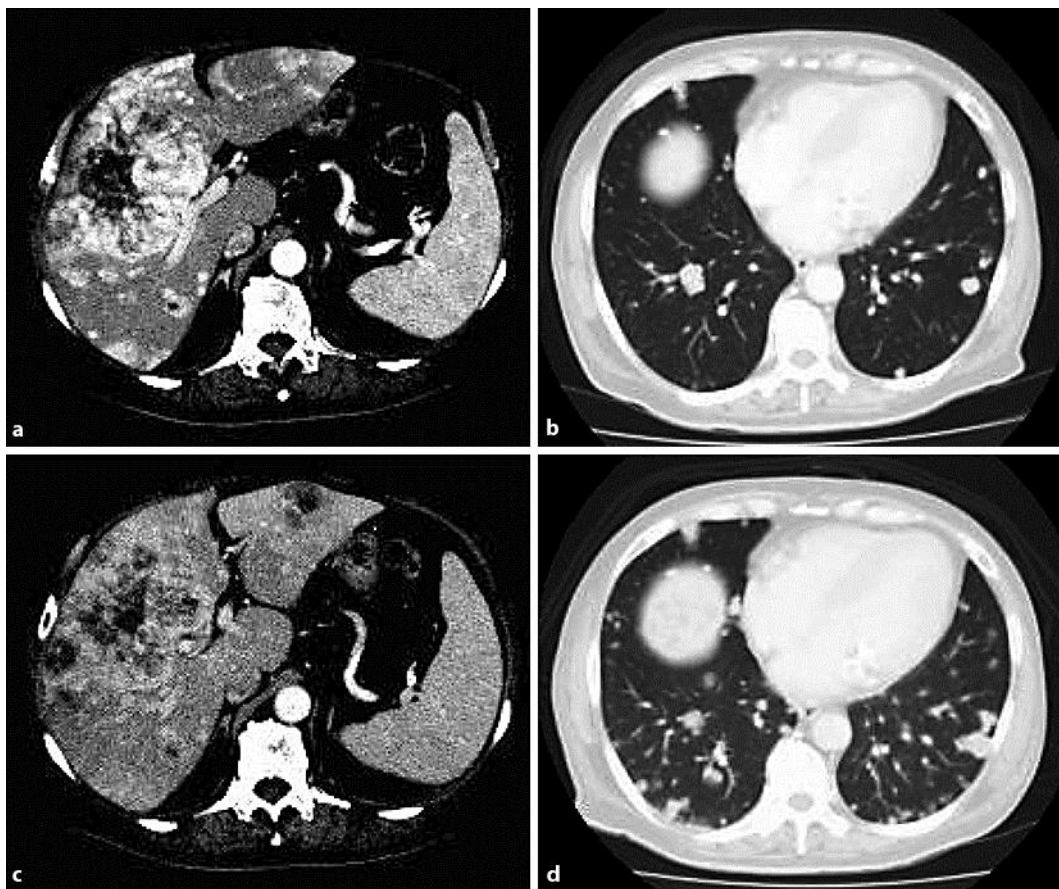


Fig. 1. CT scan images before and after the administration of sorafenib. **a, b** Images before therapy. **c, d** Images after therapy. By the administration of sorafenib, the size of the liver tumors had not changed (**a** to **c**), but the number of lung metastases had increased (**b** to **d**).




Fig. 2. Immunoblotting images of the patient's serum with an anti-IGF-II antibody. The 'big' IGF-II was detected in the patient's serum (lane 2, asterisk) similarly to the serum of a patient with NICTH (lane 4). Only mature IGF-II was detected in the serum of the normal control (lane 3). Lane 1 is recombinant IGF-II.

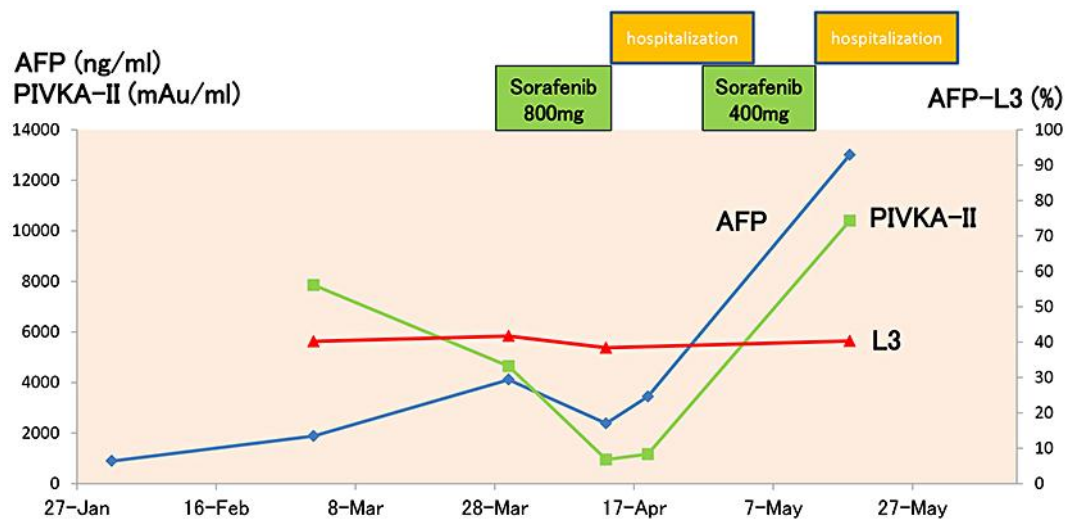


Fig. 3. Changes in the tumor marker levels before and after the administration of sorafenib. By day 14 of sorafenib administration, the tumor marker levels had decreased (AFP from 4,112 to 2,381 ng/ml and PIVKA-II from 4,645 to 952 mAU/ml). However, the effects were transient and the tumor marker levels increased again in spite of the administration of sorafenib.

References

- 1 de Groot JW, Rikhof B, Van Doorn J, Bilo HJ, Alleman MA, Honkoop AH, Van Der Graaf WT: Non-islet cell tumour-induced hypoglycaemia: a review of the literature including two new cases. *Endocr Relat Cancer* 2007;14:979–993.
- 2 Pollak M: Insulin, insulin-like growth factors and neoplasia. *Best Pract Res Clin Endocrinol Metab* 2008;22:625–638.
- 3 Gualberto A, Pollak M: Emerging role of insulin-like growth factor receptor inhibitors in oncology: early clinical trial results and future directions. *Oncogene* 2009;28:3009–3021.
- 4 Scharf JG, Dombrowski F, Ramadori G: The IGF axis and hepatocarcinogenesis. *Mol Pathol* 2001;54:138–144.
- 5 Llovet JM, Ricci S, Mazzaferro V, Hilgard P, Gane E, Blanc JF, de Oliveira AC, Santoro A, Raoul JL, Forner A, Schwartz M, Porta C, Zeuzem S, Bolondi L, Greten TF, Galle PR, Seitz JF, Borbath I, Haussinger D, Giannaris T, Shan M, Moscovici M, Voliotis D, Bruix J: Sorafenib in advanced hepatocellular carcinoma. *N Engl J Med* 2008;359:378–390.
- 6 Fukuda I, Hizuka N, Ishikawa Y, Yasumoto K, Murakami Y, Sata A, Morita J, Kurimoto M, Okubo Y, Takano K: Clinical features of insulin-like growth factor-II producing non-islet-cell tumor hypoglycemia. *Growth Horm IGF Res* 2006;16:211–216.
- 7 Rock EP, Goodman V, Jiang JX, Mahjoob K, Verbois SL, Morse D, Dagher R, Justice R, Pazdur R: Food and Drug Administration drug approval summary: Sunitinib malate for the treatment of gastrointestinal stromal tumor and advanced renal cell carcinoma. *Oncologist* 2007;12:107–113.
- 8 Kaseb AO, Morris JS, Hassan MM, Siddiqui AM, Lin E, Xiao L, Abdalla EK, Vauthey JN, Aloia TA, Krishnan S, Abbruzzese JL: Clinical and prognostic implications of plasma insulin-like growth factor-1 and vascular endothelial growth factor in patients with hepatocellular carcinoma. *J Clin Oncol* 2011;29:3892–3899.
- 9 Renard E, Langbour-Remy C, Klein M, Le Bouc Y, Weryha G, Cuny T: Severe hypoglycemia with 'Big'-IGF-2 oversecretion by a giant phyllode tumor of the breast: a rare case of non-islet cell tumor-induced hypoglycemia (NICTH). *Ann Endocrinol* 2012;73:488–491.