

## Case Report

# Laparoscopic Appendectomy for Acute Appendicitis Complicated by Pancytopenia in Two Patients with Hematologic Diseases

Keita Kojima<sup>1)</sup>, Takatoshi Nakamura<sup>1,2)</sup>, Takeyoshi Habiro<sup>1)</sup>, Mina Waraya<sup>1)</sup>, Keiko Hayashi<sup>1)</sup> and Ken-Ichiro Ishii<sup>1)</sup>

1) Department of Surgery, Japan Community Health care Organization Sagamino Hospital, Sagamihara, Japan

2) First Department of Surgery, Dokkyo Medical University, Shimotsuga, Japan

### Abstract

A 25-year-old male (Case 1) was waiting for a bone marrow transplant for myelodysplastic syndrome. Due to acute appendicitis, he was advised to undergo gastroenterological surgery. After blood transfusion, he underwent an emergency laparoscopic appendectomy, as no blood cell recovery was expected. The postoperative course was uneventful, and he was discharged. A 71-year-old female (Case 2) developed acute appendicitis during chemotherapy for acute myeloid leukemia (AML). At the time of onset, since her myelosuppression was expected to improve in approximately 1 week, a conservative treatment was administered. However, due to the progression of AML, the expected blood cell recovery did not occur. Therefore, laparoscopic appendectomy was performed 25 days after onset. She was discharged without postoperative adverse events. In cases of acute appendicitis in patients with hematologic disease accompanied by pancytopenia, it is important to establish a careful treatment plan considering the possibility of recovery from myelosuppression and the need to control an intraperitoneal infection in conjunction with a hematologist. Laparoscopic surgery, which is minimally invasive, was an effective surgical procedure.

### Keywords

acute appendicitis, laparoscopic appendectomy, pancytopenia

J Anus Rectum Colon 2021; 5(2): 188-191

## Introduction

Currently, there is no consensus as to whether emergency surgery should be performed for acute abdomen in patients with pancytopenia due to cancer chemotherapy or hematological disorders. Thus, gastroenterological surgeons are often forced to make urgent and difficult decisions. In fact, during leukemia treatments, some cases require gastroenterological surgery[1,2]. Here, we report two cases of acute appendicitis accompanied by pancytopenia due to myelodysplastic syndromes (MDS) and pancytopenia that occurred during chemotherapy for acute myeloid leukemia (AML).

## Case Report

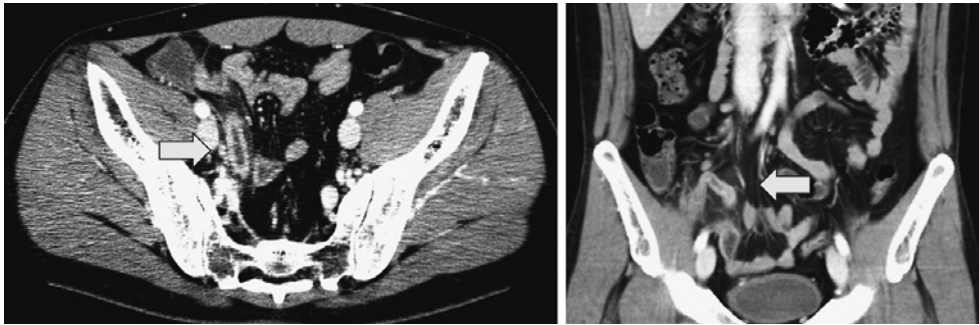
Case 1: A 25-year-old male.

Chief complaint: Chills, lower abdominal pain.

Past history: No special notes.

History of present illness: The patient was diagnosed with MDS and was waiting for a bone marrow transplant. At the time of the first visit, he was referred for chills and lower abdominal pain. He was diagnosed with acute appendicitis and then further referred for surgery.

Present medical condition: The patient's height is 176.4 cm; weight, 71.2 kg; body temperature, 39.6°C; blood pressure, 109/53 mmHg; and pulse, 80/min. Abdominal examination revealed tenderness in the lower right abdomen.



**Figure 1.** Abdominal contrast-enhanced computed tomography images of Case 1. The appendix was swollen, and disproportionate fat stranding was observed (arrows).

However, there were no signs of peritoneal irritation.

Blood test findings: White blood cell (WBC) count was  $900/\mu\text{L}$ ; neutrophil count,  $335/\mu\text{L}$ ; hemoglobin concentration,  $6.8\text{ g/dL}$ ; platelet count,  $2.7 \times 10^4/\mu\text{L}$ ; and C-reactive protein (CRP) concentration,  $13.8\text{ mg/dL}$ .

Abdominal contrast-enhanced computed tomography (CT) (Figure 1): The appendix wall was thickened and swollen and the surrounding fat concentration increased. Moreover, a small amount of ascites was observed. There was no perforation of the appendix or abscess.

Based on the above, we diagnosed the patient with acute appendicitis complicated by MDS. We planned an emergency surgery as recovery of the bone marrow function was not possible. The surgery was planned to be performed after red blood cell and platelet transfusion for pancytopenia. However, allergies (urticaria and pharyngeal pruritus) were observed during transfusion. The day after onset, the allergic symptoms resolved; thus, laparoscopic appendectomy was performed.

Surgical findings: A small amount of bloody ascites accumulated in the abdominal cavity, which resulted in the congestion of the mesoappendix. The appendix had no noticeable adhesions; appendectomy was then performed. The operation time was 1 h and 7 min, and there was almost no bleeding.

Histopathological findings: Neutrophils infiltrated into all layers of the appendix, suggesting phlegmonous appendicitis.

Postoperative course: The patient was treated with antibiotics in addition to the use of an immunoglobulin preparation, as is normally done for severe infections. The postoperative course was uneventful. He was discharged 8 days following the operation, after which he underwent bone marrow transplant.

Case 2: A 71-year-old female.

Chief complaint: Diarrhea and right lower abdominal pain.

Past history: Anti-human leukocyte antigen antibody posi-

tive and platelet transfusion refractory state.

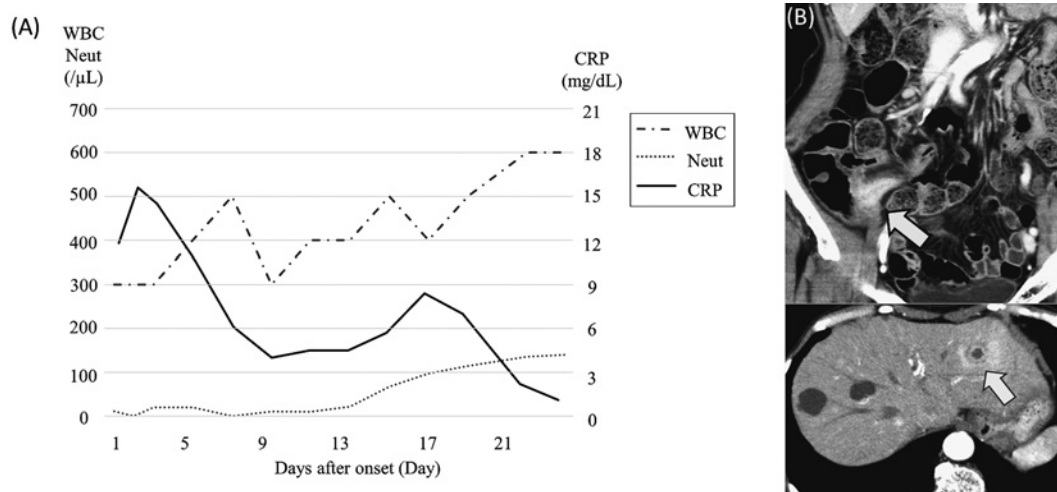
History of present illness: The patient had been receiving idarubicin/cytosine arabinoside remission induction therapy for AML. She had diarrhea and right lower abdominal pain on the 13th day of the treatment. Upon further examination, she was diagnosed with acute appendicitis. She was referred for surgery.

Present medical condition: The patient's height is 162 cm; weight, 46.7 kg; body temperature,  $38.6^\circ\text{C}$ ; blood pressure,  $102/52\text{ mmHg}$ ; and pulse,  $90/\text{min}$ . Abdominal examination revealed rebound tenderness in the lower right abdomen.

Blood test findings: WBC count was  $300/\mu\text{L}$ ; neutrophil count,  $11/\mu\text{L}$ ; hemoglobin concentration,  $8.6\text{ g/dL}$ ; platelet count,  $0.4 \times 10^4/\mu\text{L}$ ; and CRP concentration,  $11.8\text{ mg/dL}$ .

Abdominal contrast-enhanced CT: Swelling and thickening of the appendix wall, which had a contrast effect, were observed. No perforation or abscess formation was noted.

Based on the above, the patient was diagnosed with acute appendicitis associated with pancytopenia due to AML chemotherapy. Her attending physician, a hematologist, expected that bone marrow function recovery would be achieved in approximately 1 week. Considering the perioperative complications, we administered conservative treatment under strict control and planned the surgery to be performed after the bone marrow function has recovered. The patient's abdominal findings gradually improved, and CRP demonstrated a decreasing trend (Figure 2-A). However, 2 weeks after the onset of appendicitis, her WBC count remained at around  $500/\mu\text{L}$ . Therefore, bone marrow examination was conducted 17 days after the onset. The examination revealed that the AML had not responded to chemotherapy and that the disease had progressed. Abdominal contrast-enhanced CT performed 23 days after the disease onset revealed residual inflammation of the appendix and a liver abscess (Figure 2-B). We speculated that the liver abscess was caused by appendicitis. Since her blood cells did not recover, she underwent laparoscopic appendectomy on the 25th day with the hope of continuing AML chemotherapy.



**Figure 2.** A: After conservative treatment, the C-reactive protein (CRP) level tended to decrease. However, the white blood cell (WBC) count increased to approximately 500, even at 2 weeks after the onset of appendicitis. Neut: neutrophil  
 B: This figure presents the findings of abdominal contrast-enhanced computed tomography of Case 2 at 23 days after the onset. The swelling of the appendix remained, and an amount of abscess formed in the liver (arrows).

**Surgical findings:** Due to severe inflammation of the appendix, partial resection of the cecum was performed. The operation time was 1 h and 12 min, and there was almost no bleeding.

**Histopathological findings:** Inflammatory cells had infiltrated into the submucosa, a finding associated with gangrenous inflammation. No atypical cells were observed.

**Postoperative course:** The patient received antibiotics and immunoglobulin preparations. The postoperative course was uneventful. She was discharged 21 days after surgery. On imaging, although the liver abscess had shrunk, it still remained. However, as her physical findings improved and the CRP became negative, she has continued chemotherapy for AML.

### Discussion

Of the acute abdominal issues that occur in patients with leukemia, the frequency of acute appendicitis is reported to be about 0.5%[3,4]. We searched for case reports in Japan from the Japan Medical Abstracts Society during the period 1990-2019 using the keywords “appendicitis,” “leukemia,” and “MDS” (excluding the proceedings). Out of the 31 case reports discovered, 29 cases of acute appendicitis were found to be associated with leukemia treatment and 2 cases with MDS. Emergency surgery was performed in 17 cases at the time of diagnosis, with the main reason being that myelosuppression was prolonged. Contrarily, conservative treatment had been administered to 14 patients. Among them, 57% (8/14) successfully responded to the treatment;

however, 50% (4/8) had a relapse. The major reasons for proceeding with the conservative treatment were mild abdominal symptoms and increased postoperative complications due to myelosuppression. In patients with improved abdominal symptoms, surgery was performed after waiting for bone marrow function recovery. The use of laparoscopic appendectomy as an operative procedure for patients with hematologic disease has been reported in 10 cases in Japan.

When using component transfusions and antibiotic treatments, perioperative complications need to be appropriately managed. Due to the fear of postoperative infections[5], we have commonly used gamma globulin. However, in the above conditional search, we found that only 5 of the 31 cases reported in Japan used gamma globulin. Also, we did not use the granulocyte colony-stimulating factor (G-CSF) formulation, although it has been reportedly used in 6 of the 31 cases in Japan. As it has been pointed out that the use of G-CSF for leukemia could possibly result in leukemic cell proliferation[6], this treatment should only be used under the guidance of a hematologist. Furthermore, a facility with a bio-clean operating room may be the best place to perform this procedure[7]. However, the use of such a facility will only help prevent airborne infections. This is because, as has been observed in implant surgeries, the appropriate use of antibiotics is important to prevent postoperative infections[8]. Therefore, we consider that a bio-clean room is not essential when treating acute appendicitis in patients with myelosuppression.

One of the most annoying aspects of these treatment choices is that patients exhibit reduced bone marrow func-

tion. The difference between the two cases reported here was whether or not the blood cells were likely to recover at the time of diagnosis of acute appendicitis. Because the patient with MDS was waiting for a bone marrow transplant, blood cell recovery was not expected over the short term. In contrast, in patients with AML, cytopenia due to chemotherapy is normally expected, as well as blood cell recovery at the time of diagnosis. Therefore, emergency surgery was performed in the current patient with MDS, while conservative treatment was prioritized for the patient with AML in conjunction with a strict follow-up. We believe that an environment wherein bone marrow biopsy can be performed in a timely manner to evaluate the disease progression in patients with delayed blood cell recovery, such as in Case 2, is meaningful with regard to the determination of the treatment strategies.

The treatment principle for acute appendicitis is surgery. But from the viewpoint of the underlying disease along with treatment continuation for patients with hematological disorders, resection is also desirable. However, in patients with pancytopenia, the timing of the surgery becomes a problem from the viewpoint of the risk of perioperative systemic complications and susceptibility to infection. In conclusion, we propose the following as a treatment strategy for patients with myelosuppression accompanied by acute appendicitis. Emergency surgery should only be considered under strict control if severe intraperitoneal infection becomes difficult to control or blood cell recovery is not expected. Contrarily, if blood cell recovery is expected in the short term and the infection is controllable, a conservative treatment should be prioritized to avoid perioperative complications. However, after a conservative treatment is administered, interval appendectomy should be considered due to the high incidence of appendicitis in patients with leukemia[9]. In addition, it has been found that laparoscopic surgery for appendicitis is useful in reducing the incidence of wound infections[10]. The findings in the 10 patients with leukemia who underwent laparoscopic appendectomy and our two case study patients indicate that there is no significant difference in the surgical procedure for laparoscopic appendectomy between general patients and patients with myelosuppression. Therefore, laparoscopic surgery should be aggressively considered as a less-invasive treatment in patients with pancytopenia.

#### Conflicts of Interest

There are no conflicts of interest.

#### Author Contributions

All authors have contributed to this manuscript and reviewed and approved the current form of the manuscript to be submitted.

#### Informed Consent

Written informed consent was obtained from the patients.

#### References

- Wallace J, Schwaitzberg S, Miller K. Sometimes it really is appendicitis: case of a CML patient with acute appendicitis. *Ann Hematol* 1998 Jul-Aug; 77(1-2): 61-4.
- Chirletti P, Barillari P, Sammartino P, et al. The surgical choice in neutropenic patients with hematological disorders and acute abdominal complications. *Leuk Lymphoma*. 1993 Feb; 9(3): 237-41.
- Angel CA, Rao BN, Wrenn E Jr, Lobe TE, Kumar AP. Acute appendicitis in children with leukemia and other malignancies: still a diagnostic dilemma. *J Pediatr Surg*. 1992 Apr; 27(4): 476-9.
- Hunter TB, Bjelland JC. Gastrointestinal complications of leukemia and its treatment. *Am J Roentgenol* 1984 Mar;142: 513-8.
- Negi VS, Elluru S, Sibéiril S, et al. Intravenous immunoglobulin: an update on the clinical use and mechanisms of action. *J Clin Immunol* 2007 May; 27(3): 233-45.
- Takamatsu H, Nakao S, Ohtake S, et al. Granulocyte colony-stimulating factor-dependent leukemic cell proliferation in vivo in acute promyelocytic leukemia. *Blood* 1993 Jun 15; 81(12): 3485-6.
- Sakamoto K, Fukuchi T. Two cases of acute celiopathy which occurred in the bone marrow inhibition stage during the treatment of leukemia and performed surgical treatment. *Jpn J Gastroenterol Surg*. 1996; 29(5): 1064-8.
- Lidwell OM, Elson RA, Lowbury EJ, et al. Ultraclean air and antibiotics for prevention of postoperative infection. A multicenter study of 8,052 joint replacement operations. *Acta Orthop Scand*. 1987 Feb; 58(1): 4-13.
- Wiegering VA, Kellenberger CJ, Bodmer N, et al. Conservative management of acute appendicitis in children with hematologic malignancies during chemotherapy-induced neutropenia. *J Pediatr Hematol Oncol*. 2008 Jun; 30(6): 464-7.
- Wang D, Dong T, Shao Y, Gu T, Xu Y, Jiang Y. Laparoscopy versus open appendectomy for elderly patients, a meta-analysis and systematic review. *BMC Surg*. 2019 May; 19(1): 54.

Journal of the Anus, Rectum and Colon is an Open Access journal distributed under the Creative Commons Attribution-NonCommercial-NoDerivatives 4.0 International License. To view the details of this license, please visit (<https://creativecommons.org/licenses/by-nc-nd/4.0/>).