

Outcomes and Return to Sport and Work After Open Bankart Repair for Recurrent Shoulder Instability

A Systematic Review

Khalid AlSomali,^{*†} MD, Erica Kholinne,^{†‡} MD, PhD, Thanh Van Nguyen,^{†§} MD, Chang-Ho Cho,[†] MD, Jae-Man Kwak,[†] MD, Kyoung-Hwan Koh,[†] MD, PhD, and In-Ho Jeon,^{†||} MD, PhD

Investigation performed at Asan Medical Center, Seoul, Republic of Korea

Background: Open Bankart repair provides surgeons and patients with an alternative solution for managing recurrent instability in young athletes with or without minimal bone loss. Despite many studies that have reported low recurrence rates and good functional outcomes after open Bankart repair, we have limited knowledge about the return to sport and work for high-demand populations.

Purpose: To assess the return to sport and work for high-demand populations after open Bankart repair for recurrent anterior shoulder instability, outcomes of open Bankart repair with regard to recurrence, and development of osteoarthritic (OA) changes.

Study Design: Systematic review; Level of evidence, 4.

Methods: We searched PubMed, EMBASE, Cochrane Library, Scopus, and Google Scholar databases using keywords as well as Medical Subject Headings terms and Emtree using “(Open Bankart OR Bankart surgery) (NOT arthroscopy NOT revision)” for English-language studies. We conducted a systematic review in accordance with the PRISMA (Preferred Reporting Items for Systematic Reviews and Meta-Analyses) guidelines.

Results: In total, 11 articles (10 with level 4 and 1 with level 3 evidence) including 563 patients (566 shoulders) were identified. The majority of patients were male (82%), the average age at the time of surgery was 27.4 years, and the mean follow-up was 11.5 years (range, 2.5-29 years). The most common functional score used was the Rowe score (95%) for the reported outcome measures, which showed good to excellent results (mean, 88.5 points). The overall recurrent instability rate, including dislocation and subluxation as a postoperative complication, was 8.5%. A total of 87% of patients were able to return to sport and work postoperatively. Overall, OA changes were reported in 33% of the patients, and the overall revision rate was 1%.

Conclusion: Open Bankart repair exhibited favorable results, with a low postoperative instability rate. It is a reliable surgical procedure that allows high-demand patients to return to sport and work.

Keywords: Bankart repair; anterior instability; shoulder joint instability; systematic review; treatment outcome

Traumatic, recurrent, unidirectional anterior shoulder dislocation frequently occurs in young adults and athletes.¹⁰ Different procedures have been described for the stabilization of the glenohumeral joint. Of these procedures, the open Bankart repair is associated with a low recurrence rate (2%)²⁴ and a high percentage (>90%) of good to excellent outcomes.^{5,18,20,24}

However, some surgeons consider bony procedures, such as the Latarjet, as the standard procedure for recurrent

anterior shoulder instability in athletes.^{17,29} This procedure is indicated for patients with >15% glenoid bone loss and in patients with high risk of recurrence.³⁰ The overall complication rate for the Latarjet procedure has been reported between 15% and 30%¹¹ including hardware problems, non-union, and neurovascular damage.^{1,7,11} Arthroscopic Bankart repair is widely performed for anterior shoulder instability; however, complications have been reported in the literature.²¹ Recurrent instability after arthroscopic repair remains one of the biggest concerns for shoulder surgeons, especially in contact athletes.^{26,28} Many systematic reviews have reported that open and arthroscopic Bankart repair have similar postoperative outcomes (ie, recurrence

The Orthopaedic Journal of Sports Medicine, 9(10), 23259671211026907
DOI: 10.1177/23259671211026907
© The Author(s) 2021

This open-access article is published and distributed under the Creative Commons Attribution - NonCommercial - No Derivatives License (<https://creativecommons.org/licenses/by-nc-nd/4.0/>), which permits the noncommercial use, distribution, and reproduction of the article in any medium, provided the original author and source are credited. You may not alter, transform, or build upon this article without the permission of the Author(s). For article reuse guidelines, please visit SAGE's website at <http://www.sagepub.com/journals-permissions>.

rate, range of motion, and complications).^{9,13,25,31} Murphy et al²³ published a recent systematic review focused on arthroscopic Bankart repair, but there is no recent systematic review on open Bankart repair.

Open Bankart repair provides surgeons and patients with an alternative option to Latarjet and arthroscopic Bankart repair procedures for managing recurrent instability in young athletes with minimal to no glenoid bone loss.⁶ The return to sport and work is an important outcome that needs to be investigated after open Bankart repair, especially for high-demand populations. Other important outcomes of open Bankart repair are recurrence rate and development of glenohumeral osteoarthritic (OA) changes.

The purpose of this systematic review was to assess the return to sport and work for high-demand populations (athletes and people who work in heavy labor) after open Bankart repair for recurrent anterior shoulder instability, outcomes of open Bankart repair with regard to recurrence, and development of OA changes. Our hypothesis was that the open Bankart repair would result in a low rate of recurrence, a low rate of postoperative OA changes, and a high rate of return to sport and work.

METHODS

Search Strategy and Study Selection

This systematic review was performed according to the PRISMA (Preferred Reporting Items for Systematic Reviews and Meta-Analyses) guidelines. PubMed, EMBASE, Cochrane Library, Scopus, and Google Scholar databases were searched using keywords conforming to Medical Subject Headings and Emtree to identify relevant articles. Natural keywords were chosen to increase sensitivity: “(Open Bankart OR Bankart surgery) (NOT arthroscopy NOT revision).”

The number of studies was limited; thus, there were no restrictions with regard to specific surgical procedures, publication status, or study period. After eliminating duplicate studies, 2 independent reviewers (K.A. and E.K.) screened the titles and abstracts to determine the first round of candidate articles. The final articles were identified via a full-text review. We also conducted citation tracking on the bibliographies of the retrieved studies to identify additional related articles. Any disagreement that arose in the selection process was resolved via group discussion or the intervention of a third reviewer (I.-H.J.).

Inclusion and Exclusion Criteria

All the included studies contained original data published in the English language. Studies on diagnosis, imaging, and treatment of patients undergoing open Bankart repair for recurrent anterior shoulder instability were included. Arthroscopic Bankart repair studies, review studies, biomechanical studies, and cadaveric studies were excluded.

A total of 241 articles were retrieved for initial screening. The titles and abstracts of these articles were examined for duplication. Conference abstracts were excluded from the review. Full-text review of 13 articles resulted in the identification of 11 articles.

Quality Appraisal and Risk of Bias

Two reviewers (K.A. and E.K.) independently reviewed each of the articles that were finally included and decided whether to include or exclude any study based on discussion and consensus. The level of evidence for each study was determined according to the criteria stipulated by the Oxford Centre for Evidence-Based Medicine.¹⁴ Decisions on inclusion or exclusion were discussed with 2 other expert orthopaedic surgeons specializing in shoulder surgery (K.-H.K. and I.-H.J.). The Methodological Index for Non-randomized Studies (MINORS) was used to assess the risk of bias of each study; the evaluation items of the MINORS tool were composed of 8 common items and 4 additional items for studies with a comparative group.³² Each item was scored as 0, 1, or 2, giving a maximum score of 16 points for a noncomparative study and 24 points for a comparative study. A lower risk of bias is indicated by a higher score. There was no consensus regarding the cutoff point for the MINORS assessment. In the current study, studies with a score >60% (14/24 points or 9/16 points) of the total score were determined using the MINORS evaluation tool and were considered as high quality.

Data Extraction and Analysis

Data were extracted from the text, figures, tables, and supplementary material of each of the included studies. These data included (1) article and patient characteristics, (2) preoperative characteristics (radiologic investigations and findings), (3) intraoperative characteristics (type of surgery, intraoperative findings), and (4) postoperative outcomes (recurrence rate, functional outcome assessment, loss of external rotation [ER], return to sports and work,

^{||}Address correspondence to In-Ho Jeon, MD, PhD, Department of Orthopedic Surgery, University of Ulsan, Asan Medical Center, 86 Asanbyeongwon-gil, Songpa-gu, Seoul, Republic of Korea, 138-736 (email: jeonchoi@gmail.com).

^{*}Department of Orthopedic Surgery, King Fahad Military Medical Complex, Dhahran, Saudi Arabia.

[†]Department of Orthopedic Surgery, University of Ulsan, Asan Medical Center, Seoul, Republic of Korea.

[‡]Faculty of Medicine, Universitas Trisakti, Department of Orthopedic Surgery, St. Carolus Hospital, Jakarta, Indonesia.

[§]Department of Orthopedic Surgery, University Medical Center, Ho Chi Minh, Vietnam.

Final revision submitted February 23, 2021; accepted March 4, 2021.

One or more of the authors has declared the following potential conflict of interest or source of funding: This research was supported by Basic Science Research Program through the Asan Institute for Life Sciences funded by Asan Medical Center (2020IL0044). AOSSM checks author disclosures against the Open Payments Database (OPD). AOSSM has not conducted an independent investigation on the OPD and disclaims any liability or responsibility relating thereto.

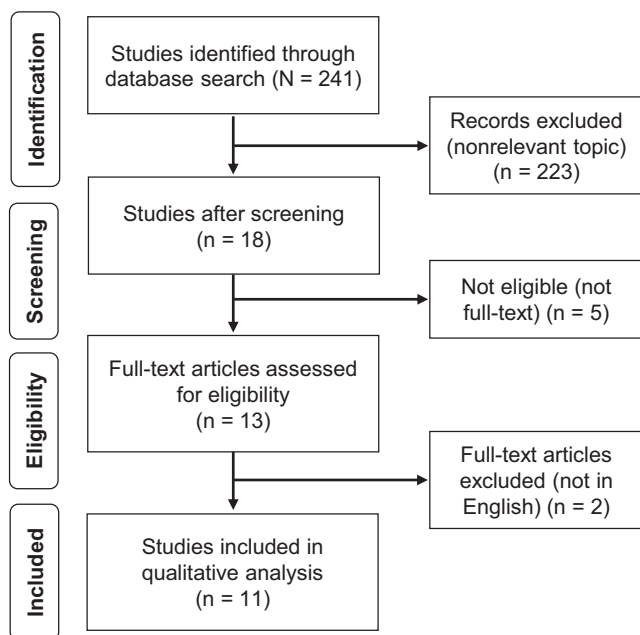


Figure 1. Flowchart of the article inclusion process that adhered to the PRISMA (Preferred Reporting Items for Systematic Reviews and Meta-Analyses) guidelines.²²

and OA changes). We performed a qualitative assessment of all included studies and produced a narrative report. The postoperative functional outcome, recurrence rate, return to sports and work, loss of ER, and OA were compared among the articles. We defined instability rate as dislocation and/or subluxation.² Where possible, data were combined, although this was not always possible because of the low level of evidence and heterogeneity of the studies. Collocated data were summarized in tables using Microsoft Office Excel (2013; Microsoft Corp).

RESULTS

Article Inclusion

Overall, 11 articles (10[¶] with level 4 and 1³⁶ with level 3 evidence) met the criteria for the systematic review. Figure 1 displays the flow of study selection.

Study Quality Assessment

The mean MINORS score for all 11 studies was 8.6 according to the bias risk assessment. There were no comparative studies. Table 1 lists the distribution of the MINORS scores and the range of articles considered high quality. Five articles^{2,6,18,24,33} were considered high-quality studies with a low risk of bias, exceeding 60% of the total points.

TABLE 1
Distribution of MINORS Scores and Articles Considered High Quality

Lead Author (Year)	MINORS Item ^a								Total Score
	1	2	3	4	5	6	7	8	
Berendes (2018) ²	2	0	0	2	2	2	0	1	9
Neviaser (2017) ²⁴	2	2	0	2	2	2	0	0	11
Rahme (2010) ³³	2	2	0	2	2	2	0	0	10
Fabre (2010) ⁶	2	1	0	2	2	2	0	0	9
Cetik (2006) ⁵	2	1	0	2	1	1	0	0	7
Langford (2006) ¹⁹	2	1	0	2	1	2	0	0	8
Pelet (2006) ²⁷	2	1	0	2	1	2	0	0	8
Sachs (2005) ³⁶	2	2	0	2	1	1	0	0	8
Lai (2006) ¹⁸	2	2	0	2	1	2	0	0	9
Jolles (2004) ¹⁶	2	2	0	2	1	1	0	0	8
Magnusson (2002) ²⁰	2	1	0	2	1	2	0	0	8

^a1, clearly stated aim; 2, inclusion of consecutive patients; 3, prospective collection of data; 4, endpoints appropriate to the aim of the study; 5, unbiased assessment of the study endpoint; 6, follow-up period appropriate to the aim of the study; 7, loss to follow-up <5%; 8, prospective calculation of the study size. MINORS, Methodological Index for Non-randomized Studies.

Article and Patient Characteristics

The 11 included articles included 563 patients (566 shoulders) with recurrent anterior shoulder instability (Table 2). The study population included 461 shoulders in men (82%) and 102 in women (18%), and the mean age at the time of surgery was 27.4 years (range, 14-63 years). The dominant extremity was affected in 42% of accessible patients (214/506). Of the 563 patients, 79% (n = 447) were either participating in sports or working in labor jobs and were considered high-demand patients. A total 79% of accessible patients (423/534) were regularly participating in sporting activities; 48% (204/423) of them were participating at a competitive level, 28% (119/423) were participating at a recreational level, and 24% (100/423) did not specify a level. According to the type of sport, 129 of 423 patients were participating in a contact sport, including 31 professional rugby players⁶; 49 of 423, in overhead sport; and 245 of 423, in noncontact nonoverhead sport. Ten percent (55/563) of patients had a high-demand occupation working as military personnel and manual labor. Mean follow-up was 11.5 years (range, 2.5-29 years); 4 studies with 246 shoulders (246/566) had >15 years of follow-up.^{2,6,24,27}

Preoperative Characteristics. Five percent (30/566) of shoulders in 1 study underwent preoperative computed tomography (CT/CT arthrography) and reported Bankart/Hill-Sachs lesions in all patients. None of the studies reported OA in preoperative radiographs. None of the patients in the studies had previous surgery.

Intraoperative Characteristics. Data on intraoperative characteristics are listed in Table 3. Intraoperative findings were extracted in 3 of 11 articles including 231/566 shoulders (41%).^{16,18,24} Hill-Sachs lesions were the most commonly encountered finding in 84% (193/231) of shoulders. Superior labrum anterior to posterior and bony

[¶]References 2, 5, 6, 16, 18, 19, 20, 24, 27, 33.

TABLE 2
Characteristics of Included Studies^a

Lead Author (Year)	Country of Study	Study Type (LOE)	No. of Shoulders	Mean Age, y, (Range or SD)	Male/Female, n	Mean Follow-up, y, (Range)	Sports Activity, P	Contact Sport, P	Overhead Sport, P	Heavy Labor, P	Dominant Hand Affected, P
Berendes (2018) ²	The Netherlands	Case series (4)	39	31 (18-47)	32/7	21 (16-26)	29/39	NA	NA	NA	14/39
Neviaser (2017) ²⁴	USA	Case series (4)	127	31 (15-63)	102/25	17.1 (5-24)	107/127	43/107	29/107	NA	73/127
Rahme (2010) ³³	Sweden	Case series (4)	68	29 (17-47)	54/14	5.25 (2.25-9.1)	41/68	NA	NA	NA	42/68
Fabre (2010) ⁶	France	Case series (4)	50	25 (17-51)	46/3	28 (25-32)	46/49	35/46	NA	NA	24/49
Cetik (2006) ⁵	Turkey	Case series (4)	30	22 (20-30)	NA	2.5 (1.83-3.1)	NA	NA	NA	29/29 (military)	20/29
Langford (2006) ¹⁹	USA	Case series (4)	41	29 (14-52)	35/6	6.5 (1-14.4)	38/41	NA	NA	NA	NA
Pelet (2006) ²⁷	Switzerland	Case series (4)	30	23.6 (14-46)	24/6	29 (20.3-41)	24/30	NA	NA	NA	20/30
Sachs (2005) ³⁶	USA	Cohort study (3)	30	31 (20-50)	25/5	4 (2-6)	30/30	NA	NA	NA	14/30
Lai (2006) ¹⁸	Taiwan	Case series (4)	82	27.3 (9.1)	66/16	4.6 (2-8)	40/82	40/40	NA	25/82	NA
Jolles (2004) ¹⁶	Switzerland	Case series (4)	22	28 (20-46)	19/2	3 (2-4)	21/21	NA	NA	NA	7/21
Magnusson (2002) ²⁰	Sweden	Case series (4)	47	25 (16-56)	29/18	5.75 (4-9.5)	47/47	11/47	20/47	NA	NA

^aF, female; LOE, level of evidence; NA, not available; M, male; P, number of patients.

TABLE 3
Intraoperative Characteristics of the Study Population^a

Lead Author (Year)	Intraoperative Findings	Type of Surgery	Type of Fixation	Suture Anchors, n
Berendes (2018) ²	NA	Open repair, capsular plication (modified Rowe) Rotator interval closure	2.9-mm suture anchor (Mitek GI) 2.4-mm suture anchor (Mitek GII)	3-4
Neviaser (2017) ²⁴	All patients had Bankart, Hill-Sachs by arthroscopy	Open repair; capsular plication (modified Rowe); anchors at 2, 4, 6 o'clock	3-mm anchors (Medtronic)	NR
Rahme (2010) ³³	NA	Open repair, capsular plication (modified Rowe)	Transosseous, 9 2.9-mm suture anchor (Mitek GI), 32 2.4-mm suture anchor (Mitek GII), 28	NA
Fabre (2010) ⁶	NA	Open repair, capsular plication (modified Rowe) Transosseous fixation at 6, 4, and 3 o'clock	Transosseous fixation	NA
Cetik (2006) ⁵	NA	Open repair (modified Rowe)	2.4-mm suture anchor (Mitek GII)	2-5
Langford (2006) ¹⁹	NA	Open repair, capsular plication (modified Rowe)	Transosseous fixation, 60%; anchor (name NR), 40%	NA/NR
Pelet (2006) ²⁷	NA	Open repair, capsular plication	Transosseous fixation	NA
Sachs (2005) ³⁶	NA	Open repair, no capsular plication, rotator interval closure	Anchor (no details)	NR
Lai (2006) ¹⁸	Arthroscopy: Bankart lesion (clock unit on glenoid face): 8 (1-2 o'clock), 21 (2-3 o'clock), 24 (2-4 o'clock), 29 (>4 o'clock)	Open repair, capsular plication (modified Rowe)	2.4-mm suture anchor (Mitek GII)	NR
Jolles (2004) ¹⁶	Hill-Sachs, 49/82; SLAP tear, 24/82 Arthroscopy: Bankart, 22; Hill-Sachs, 17; bony Bankart, 2; partial LHB tear, 1	Open repair, no capsular plication	Anchor (Mitek; model NA)	NR
Magnusson (2002) ²⁰	NA	Open repair, capsular plication (modified Rowe)	Anchor (Smith & Nephew, Mitek; model NA)	NR

^aMitek GI and Mitek GII manufactured by DePuy Mitek. LHB, long head of biceps; NA, not available; NR, not reported; SLAP, superior labrum anterior to posterior.

TABLE 4
Postoperative Characteristics of the Study Population^a

Lead Author (Year)	Outcome Measure	Reported Score, Mean ± SD (Range)	Interpretation of Score	Instability Rate (Dislocation + Subluxation)	Subscapularis Function Intact	Mean Postop Loss of ER	Postop Arthritic Changes	Patient Satisfaction, Yes	Return To Work/ Sport
Berendes (2018) ²	(1) Rowe	(1) 85 (25-100)	NA	23 (9/39)	NA	ERA, 10°	Mild/moderate, 20/39	NR	Sport: 89 (26/29)
	(2) Constant	(2) 92 (70-100)							
	(3) NRS (pain)	(3) 1 (0-6)							
	(4) Constant	(4) 92 (70-100)							
	(5) Dutch simple shoulder	(5) 11 (7-12)							
	(6) Oxford	(6) 16 (11-31)							
Neviaser (2017) ²⁴	(1) ASES	(1) 93.5 (46.7-100)	Rowe: excellent,	2 (2/127)	100 (127/127)	ERA, 4°	Mild/moderate, 28/127;	98 (125/127)	Sport: 91 (98/107)
	(2) Rowe	(2) 91.4 (70-100)	123/127; fair/			ERS, 4°	severe,		
	(3) WOSI	(3) 327.7 (0-1533)	poor, 4/127				none		
Rahme (2010) ³³	(1) Rowe	(1) 88 (44-100)	NA	6 (4/68)	NA	ERA 12° (range, 0° - 50°)	NR	37 (25/68)	NA
	(2) Constant	(2) 93 (48-100)							
Fabre (2010) ⁶	(1) Rowe	(1) 82 (25-97)	Excellent/good,	16 (8/50)	NA	9° (range, 0°-40°)	Mild/moderate, 28/50;	96 (47/49)	Sport: 87 (40/46)
	(2) Duplay score	(2) 81.5 (20-95)	42/49; poor, 7/49				severe, 1/50		
Cetik (2006) ⁵	Rowe	91 (80-100)	Excellent (28/29)	0 (0/30)	NA	NA	NR	NR	Work (military): 100 (30/30)
Langford (2006) ¹⁹	Rowe	96	NA	7 (3/41)	NA	4° (range, 0°-15°)	NR	NR	Sport: 92 (35/38)
Pelet (2006) ²⁷	(1) Rowe	(1) 80 (35-100)	Good (20/30); fair/	10 (3/30)	NA	ERA, 24°	Mild/moderate, 5/30;	NR	Sport: 100 (24/24)
	(2) Constant	(2) 73.4 (31.8-89)	poor (5/30)			ERS, 33°	severe, 7/30		
	(3) ASES	(3) 12.6 (7-14)							
Sachs (2005) ³⁶	(1) Modified ASES	(1) 83	NA	7 (2/30)	76 (23/30)	ERA (2.8°)	NR	Excellent, 17/30;	Sport: 50 (15/30)
	(2) WOSI	(2) 73				ERS (2.3°)		good, 8/30; fair, 4/30; poor, 1/30	
	(3) Constant	(3) 92							
Lai (2006) ¹⁸	Rowe	85.9 ± 12.9 (25-100)	Excellent/good (76/82); fair/ poor (6/82)	8 (7/82)	NA	10°	NR	NR	Sport: 75 (30/40)
Jolles (2004) ¹⁶	(1) Rowe	(1) 93 (60-100)	Rowe: Excellent (19/21); fair/	9.5 (2/21)	NA	ERA 7° (range, -10° to 25°)	0, 0/22	NR	Sport: 90 (19/21)
	(2) ASES	(2) 94 (71-100)	poor (2/21)			ERS 8° (range, -5° to 45°)			
	(3) Constant	(3) 90 (78-98)							
Magnusson (2002) ²⁰	(1) Rowe	(1) 90 (24-100)	NA	17 (8/47)	NA	ERA 15°	NR	NR	Sport: 91 (41/45)
	(2) Constant	(2) 88.5 (41-100)							

^aData are reported as % (n/N), unless otherwise noted. ASES, American Shoulder and Elbow Surgeons; ER, external rotation; ERA, external rotation on abduction; ERS, external rotation at the side; NA, not available; NR, not reported; NRS, Numerical Rating Score; Postop, postoperative; WOSI, Western Ontario Shoulder Instability Index.

Bankart lesions were found infrequently, with an incidence of 10% (24/231) and 0.9% (2/231), respectively.

The surgical technique used for the majority of the studies was consistent with the procedure described by Rowe et al³⁵ with some modifications. The original technique by Rowe et al utilizes coracoid osteotomy for exposure and transosseous repair. The studies included in this review did not use coracoid osteotomy. Transosseous repair was replaced by anchor fixation in most of the studies (80%; 453/566 shoulders). The capsulolabral complex was mobilized medially and then followed by pants-over-vest style of medial capsular/labral reinforcement that is essential in the description by Rowe et al.³⁵ This procedure was done in 86% (484/566) of shoulders. The transosseous repair technique was used in 20% (113/566) of shoulders, whereas anchor repair was used in 80% (453/566) of shoulders. The most commonly used anchor was Mitek GI/GII (DePuy Mitek), utilized in 55% (250/453) of shoulders. The additional procedures were diagnostic arthroscopy (49%; 276/

566 shoulders)^{16,18,20,24} and rotator interval closure (7%; 39/566 shoulders).²

Postoperative Characteristics

Data on postoperative characteristics are displayed in Table 4. The Rowe score was the most common functional outcome tool used. The mean Rowe score was 88.5 out of 100 for 95% (536/566) of the shoulders. Six studies interpreted functional outcomes.^{5,6,16,18,24,27} They reported good to excellent results in 91% (308/340) and fair to poor results in 9% (32/340) of patients.^{5,6,16,18,24,27} Postoperative loss of ER was measured by 10 studies[#] and with a mean of 10.1°. Only 2 studies commented on the integrity of subscapularis function^{24,36} and reported intact function in (96%; 150/157) of shoulders. Five studies reported postoperative OA

[#]References 2, 6, 16, 18, 19, 20, 24, 27, 33, 36.

changes^{2,6,16,24,27} (33%; 89/268) of shoulders as seen on radiographs. They used the Samilson-Prieto classification³⁷ and reported mild to moderate changes in 81 out of 89 shoulders and severe changes only in 8 out of 89 shoulders. The recurrence rate, including recurrent dislocation and subluxation, was reported as 8.5% (48/566 shoulders). Failure was defined as repeated dislocation or subluxation.

Ten studies with 495 patients reported data on the extent to which patients were able to return to sports and work^{**} and revealed that 87% (358/410) returned to their previous sports and work. Only 4 studies with 274 patients^{6,24,33,36} described the satisfaction rate, which revealed that 81% (222/274) were satisfied with the results of the surgical procedures. Two studies mentioned the reason for dissatisfaction as residual instability³³ and subscapularis repair failure.³⁶

DISCUSSION

The current systematic review found that the open Bankart repair procedure results in good to excellent outcomes as demonstrated by statistically significant patient-reported outcome measures (91%). In terms of outcomes, the open Bankart repair resulted in a low instability rate (8.5%) and a high rate of return to sporting activities and work (87%); however, 33% developed OA changes at a mean of 11.5 years of follow-up.

The outcome of the open Bankart procedure can perhaps be predefined by each surgeon and patient in a shared manner. The goal of the open Bankart procedure is mainly to restore stability and function that permits patients to get back to their sports and work. In this systematic review, the open Bankart procedure exhibited a very low percentage of fair to poor functional outcome results (9%). Pelet et al²⁷ reported pain as the main cause for the poor results, whereas Sachs et al³⁶ reported that patients with positive lift-off tests had lower scores. In addition, Rahme et al³³ reported 3 poor results: 1 patient had glenohumeral osteoarthritis, another patient experienced several recurrences, and 1 patient had a postoperative deep infection.

Many studies have reported that open and arthroscopic Bankart repair have similar outcomes.^{3,9,13,25,31} In 2006, a randomized controlled trial involving 64 patients with recurrent anterior instability described that of the 29 patients who received open stabilization showed similar outcomes to the 32 patients treated with arthroscopic stabilization at 32 months of follow-up.³ Arthroscopic shoulder stabilization methods have evolved significantly during the past 20 years. Initial results were disappointing for arthroscopic Bankart repair, and the failure rate for this procedure was significantly high for transglenoid suturing (49%) and for bioabsorbable tack fixation (23%).⁸ However, with the introduction of suture anchors, arthroscopic Bankart repair failure rates dropped to 8% to 11%, combined with capsular plication.⁴ Failure to address capsular laxity using transglenoid suturing and bioabsorbable tack fixation was

overcome by the introduction of suture anchors⁸. Despite similar failure rates between the 2 techniques, some studies have reported that the arthroscopic Bankart repair led to inferior results for patients with high risk for recurrence, such as athletes.^{15,34,39} The ability to restore the capsular tension via capsular plication in open Bankart repair might contribute to the lower failure rate in athletes.²⁶ Another group of patients with high risk for recurrence includes patients with glenoid bone loss. In this group, the Latarjet procedure is preferred, especially if bone loss is >15% to 20%.³⁰ However, arthroscopic Bankart repair and the Latarjet procedure may not be beneficial for athletes with minimal to no glenoid bone loss. Then open Bankart repair may serve as the technique of choice for these patients because it has a lower recurrence rate than the arthroscopic technique has in this specific population^{15,34,39} and it avoids morbidity associated with the Latarjet procedure.^{1,7,11}

Overall, 33% of the total reported data showed OA changes during follow-up. Although 93% of the reported OA changes were mild/moderate changes, the follow-up results were based on radiographs, which might underestimate the extent of OA changes. Fabre et al⁶ and Pelet et al²⁷ reported very long follow-up periods, at 28 years and 29 years, respectively. They found that OA development is associated only with the length of follow-up.

In this systematic review, we defined failure as recurrent dislocation and/or subluxation. Many studies do not consider recurrent subluxation as a failure; however, from a patient's point of view, subluxation can be a failure, especially for athletes. This is why we measured the "instability rate," which is the summation of recurrent dislocation and subluxation. This review set a high threshold for defining failure considering the high percentage (75%) of athletes in this population. In this study, 87% of patients were able to return to sports and work. Neviasser et al²⁴ reported on 9 patients who did not return to sporting activities, and 2 out of 9 of these patients had personal reasons for not returning. Moreover, Berendes et al² reported 10 of 13 patients could not return to sporting activities for reasons other than their shoulder injury. It was reported that some patients did not return to sports because of the increased burden of work and family life and that others had psychological reasons such as fear of reinjury and shifts in priority.^{24,38} This review gives reliable information for surgeons who need to manage high-demand patients with recurrent anterior shoulder instability.²⁶ Open Bankart repair offers the surgeon the ability to perform a pants-over-vest capsular plication by advancing the inferior capsular limb, which can be performed using any fixation method such as transosseous repair and suture anchor.^{6,24} The open Bankart procedure still carries the risk of ER loss, especially with excessive plication of the capsule. In this review, we found that the mean ER loss was 10°, which can still affect an athlete's throwing performance.¹² Subscapularis repair failure is another downside of the open Bankart repair. It was reported that patients with failed subscapularis repair have inferior surgical outcomes and lower satisfaction rates.³⁶ This review reported that in 95.5% of patients who

**References 2, 5, 6, 16, 18, 19, 20, 24, 27, 36.

underwent subscapularis repair, the integrity of the subscapularis was preserved at final follow-up.

A recent systematic review concerning the long-term outcome of arthroscopic Bankart repair was conducted by Murphy et al.²³ This study reviewed 822 shoulders from 9 studies with a mean follow-up of 12 years. Murphy et al reported a 31% instability rate, compared with 8.5% in this review. Return to sports and work was higher for the open Bankart repair (87% vs 77%, open vs arthroscopic). OA changes were higher in arthroscopic studies (59% vs 33%, arthroscopic vs open). The satisfaction rate was higher for the arthroscopic repair (85% vs 81%, arthroscopic vs open). Finally, the revision rate was significantly lower in open repair (1% vs 17%, open vs arthroscopic). The Murphy et al study had a mean follow-up of 12 years, whereas the current systematic review had a mean follow-up of 11.5 years. The length of follow-up might contribute to the difference of results between these 2 studies. Long-term outcomes were reported by 4 articles in this review (44%; 246/566 shoulders).^{2,6,24,27} The mean follow-up was 23.7 years, with all articles having a mean follow-up of >15 years. They reported an 8.9% instability rate, and 31% OA changes. The rate of return to sports was 91%, and the revision rate was 1%. Overall, it may be concluded that the open Bankart repair has a lower instability rate, lower risk of OA change, and lower revision rate. The open Bankart repair provided higher rates of return to sports and work but with lower satisfaction rates.

Limitations

This review has some limitations. First, none of the studies had a control group for the comparison of patients with and without instability. In addition, there was a lack of complete data in the mentioned studies. Second, data from the included studies were collected retrospectively. Third, the outcome measurement tools of the studies were heterogeneously reported, preventing the direct comparison of outcomes, and highlight the need for standardized methods. Fourth, 3 out of 11 studies reported intraoperative findings (41%; 231/566 shoulders), which makes it difficult to conclude the reason behind the development of OA because the existence of OA at the time of surgery was unknown in 60% of the patients. Fifth, only 5 studies were classified as high quality based on the MINORS criteria. The surgical procedure was unequal in terms of technique and fixation. There was no control group for the arthroscopic procedure for each article. Nine out of 11 articles were considered old (published in 2010 and earlier) in relation to the development and advances of arthroscopic techniques.

CONCLUSION

The results of this review indicate that open Bankart repair is a reliable surgical procedure that is associated with low recurrence rate and revision rates, allowing high-demand patients to return to sports and work.

REFERENCES

- Amirthanayagam TD, Emery RJ. Primum non nocere: risk assessment for new surgical procedures. *J Shoulder Elbow Surg.* 2014;23(10):1417-1418.
- Berendes T, Mathijssen N, Verburg H, et al. The open-modified Bankart procedure: long-term follow-up "a 16-26-year follow-up study." *Arch Orthop Trauma Surg.* 2018;138(5):597-603.
- Bottoni CR, Smith EL, Berkowitz MJ, Towle RB, Moore JH. Arthroscopic versus open shoulder stabilization for recurrent anterior instability: a prospective randomized clinical trial. *Am J Sports Med.* 2006;34(11):1730-1737.
- Brophy RH, Marx RG. The treatment of traumatic anterior instability of the shoulder: nonoperative and surgical treatment. *Arthroscopy.* 2009;25(3):298-304.
- Cetik O, Uslu M, Ozsar BK, Eksioğlu F, Cetik G. Open repair of Bankart lesions using suture anchors in hard workers. *Acta Orthop Belg.* 2006;72(6):664.
- Fabre T, Abi-Chahla ML, Billaud A, Geneste M, Durandea A. Long-term results with Bankart procedure: a 26-year follow-up study of 50 cases. *J Shoulder Elbow Surg.* 2010;19(2):318-323.
- Frank RM, Gregory B, O'Brien M, et al. Ninety-day complications following the Latarjet procedure. *J Shoulder Elbow Surg.* 2019;28(1):88-94.
- Freedman KB, Smith AP, Romeo AA, Cole BJ, Bach BR Jr. Open Bankart repair versus arthroscopic repair with transglenoid sutures or bioabsorbable tacks for recurrent anterior instability of the shoulder: a 6-month study. *Am J Sports Med.* 2004;32(6):1520-1527.
- Friedman LGM, Griesser MJ, Miniaci AA, Jones MH. Recurrent instability after revision anterior shoulder stabilization surgery. *Arthroscopy.* 2014;30(3):372-381.
- Gooding BW, Geoghegan JM, Manning PA. The management of acute traumatic primary anterior shoulder dislocation in young adults. *Shoulder Elbow.* 2010;2(3):141-146.
- Gupta A, Delaney R, Petkin K, Lafosse L. Complications of the Latarjet procedure. *Curr Rev Musculoskelet Med.* 2015;8(1):59-66.
- Hatch MD, Hennrikus WL. The open Bankart repair for traumatic anterior shoulder instability in teenage athletes. *J Pediatr Orthop.* 2018;38(1):27-31.
- Hobby J, Griffin D, Dunbar M, Boileau P. Is arthroscopic surgery for stabilisation of chronic shoulder instability as effective as open surgery? A systematic review and meta-analysis of 62 studies including 3044 arthroscopic operations. *J Bone Joint Surg.* 2007;89(9):1188-1196.
- Howick J. The Oxford 2011 levels of evidence. January 7, 2010. Accessed March 4, 2021. <http://www.cebm.ox.ac.uk/resources/levels-of-evidence/ocebml-levels-of-evidence>
- Hubbell JD, Ahmad S, Bezenoff LS, Fond J, Petrone FA. Comparison of shoulder stabilization using arthroscopic transglenoid sutures versus open capsulolabral repairs: a 5-year minimum follow-up. *Am J Sports Med.* 2004;32(3):650-654.
- Jolles BM, Pelet S, Farron A. Traumatic recurrent anterior dislocation of the shoulder: two-to four-year follow-up of an anatomic open procedure. *J Shoulder Elbow Surg.* 2004;13(1):30-34.
- Joshi MA, Young AA, Balestro J-C, Walch G. The Latarjet-Patte procedure for recurrent anterior shoulder instability in contact athletes. *Orthop Clin North Am.* 2015;46(1):105-111.
- Lai D, Ma H-L, Hung S-C, Chen T-H, Wu J-J. Open Bankart repair with suture anchors for traumatic recurrent anterior shoulder instability: comparison of results between small and large Bankart lesions. *Knee Surg Sports Traumatol Arthrosc.* 2006;14(1):82-87.
- Langford J, Bishop J, Lee E, Flatow E. Outcomes following open repair of Bankart lesions for recurrent, traumatic anterior glenohumeral dislocations. *Orthopedics.* 2006;29(11):1008-1013.
- Magnusson L, Kartus J, Ejerhed L, et al. Revisiting the open Bankart experience: a four-to nine-year follow-up. *Am J Sports Med.* 2002;30(6):778-782.
- Matsuki K, Sugaya H. Complications after arthroscopic labral repair for shoulder instability. *Curr Rev Musculoskelet Med.* 2015;8(1):53-58.

22. Moher D, Liberati A, Tetzlaff J, Altman DG; the PRISMA Group. Preferred Reporting Items for Systematic Reviews and Meta-Analyses: the PRISMA statement. *PLoS Med*. 2009;6(7):e1000097.
23. Murphy AI, Hurley ET, Hurley DJ, Pauzenberger L, Mullett H. Long-term outcomes of the arthroscopic Bankart repair: a systematic review of studies at 10-year follow-up. *J Shoulder Elbow Surg*. 2019;28(11):2084-2089.
24. Neviasser RJ, Benke MT, Neviasser AS. Mid-term to long-term outcome of the open Bankart repair for recurrent traumatic anterior dislocation of the shoulder. *J Shoulder Elbow Surg*. 2017;26(11):1943-1947.
25. Ng C, Bialocerkowski A, Hinman R. Effectiveness of arthroscopic versus open surgical stabilisation for the management of traumatic anterior glenohumeral instability. *Int J Evid Based Healthc*. 2007;5(2):182-207.
26. Pagnani MJ, Dome DC. Surgical treatment of traumatic anterior shoulder instability in American football players. *J Bone Joint Surg Am*. 2002;84(5):711-715.
27. Pelet S, Jolles BM, Farron A. Bankart repair for recurrent anterior glenohumeral instability: results at twenty-nine years' follow-up. *J Shoulder Elbow Surg*. 2006;15(2):203-207.
28. Petrera M, Dwyer T, Tsuji MR, Theodoropoulos JS. Outcomes of arthroscopic Bankart repair in collision versus noncollision athletes. *Orthopedics*. 2013;36(5):e621-e626.
29. Privitera DM, Siegel EJ, Higgins LD. Clinical outcomes following the Latarjet procedure in contact and collision athletes. *Orthop J Sports Med*. 2014;2(3)(suppl):2325967114S2325900015.
30. Provencher MT, Bhatia S, Ghodadra NS, et al. Recurrent shoulder instability: current concepts for evaluation and management of glenoid bone loss. *J Bone Joint Surg Am*. 2010;92(suppl 2):133-151.
31. Pulavarti RS, Symes TH, Rangan A. Surgical interventions for anterior shoulder instability in adults. *Cochrane Database Syst Rev*. 2009(4):CD005077.
32. Quigley JM, Thompson JC, Halfpenny NJ, Scott DA. Critical appraisal of nonrandomized studies—a review of recommended and commonly used tools. *J Eval Clin Pract*. 2019;25(1):44-52.
33. Rahme H, Vikersfors O, Ludvigsson L, Elvén M, Michaëlisson K. Loss of external rotation after open Bankart repair: an important prognostic factor for patient satisfaction. *Knee Surg Sports Traumatol Arthrosc*. 2010;18(3):404-408.
34. Rhee YG, Ha JH, Cho NS. Anterior shoulder stabilization in collision athletes: arthroscopic versus open Bankart repair. *Am J Sports Med*. 2006;34(6):979-985.
35. Rowe C, Patel D, Southmayd W. The Bankart procedure: a long-term end-result study. *J Bone Joint Surg*. 1978;60(1):1-16.
36. Sachs RA, Williams B, Stone ML, Paxton L, Kuney M. Open Bankart repair: correlation of results with postoperative subscapularis function. *Am J Sports Med*. 2005;33(10):1458-1462.
37. Samilson R, Prieto V. Dislocation arthropathy of the shoulder. *J Bone Joint Surg*. 1983;65(4):456-460.
38. Tjong VK, Devitt BM, Murnaghan ML, Ogilvie-Harris DJ, Theodoropoulos JS. A qualitative investigation of return to sport after arthroscopic Bankart repair: beyond stability. *Am J Sports Med*. 2015;43(8):2005-2011.
39. Yamamoto N, Kijima H, Nagamoto H, et al. Outcome of Bankart repair in contact versus non-contact athletes. *Orthop Traumatol Surg Res*. 2015;101(4):415-419.