

The Double Volar Flap Technique for Aesthetic Repair of Syndactyly and Polysyndactyly of Toe without Skin Grafting

Toru Miyanaga, MD, PhD
Kenichi Shimada, MD, PhD
Miyuki Kishibe, MD
Masanobu Yamashita, MD, PhD
Akiko Yamashita, MD

Background: Aesthetic repair of syndactyly of the toes is desirable because patients may have psychological concerns about its appearance. There are 2 important factors for the aesthetic repair of syndactyly of the toe. One is to hide the operative scar from the visual site (dorsal site), whereas the other is to create an interdigital space close to the normal anatomical skin characteristics (2 general types of skin: glabrous and hairy).

Methods: In total, 12 patients (4 males and 8 females) with 15 syndactylous webs were operated on by using the double volar flap technique. The following 3 local flaps were designed with this technique: an M-shaped flap designed on the dorsal side of the interdigital region (flap A) and double volar flaps (flaps B and C) designed on the volar side of the interdigital region. Flap A was used for reconstruction of the web slope, whereas flaps B and C were used for reconstruction of the proximal sidewall of toes.

Results: The corrected toes showed a deep and natural interdigital commissure with no exposure of skin grafts or conspicuous scars on the dorsal visible side. The scars on the volar side were also inconspicuous.

Conclusions: The double volar flap method for repair of syndactyly and polysyndactyly of the toes has the same advantages as those of the local flap method, in addition to an optimum aesthetic result through matching with the normal anatomical skin characteristic of the interdigital space and hiding of the operative scar from the visual site. (*Plast Reconstr Surg Glob Open* 2017;5:e1293; doi: 10.1097/GOX.0000000000001293; Published online 19 April 2017.)

INTRODUCTION

Syndactyly of the toes is one of the most common congenital anomalies, with an incidence rate of 1 per 2,000–2,500 live births.¹ Many surgical techniques for syndactyly of the toes have been reported by Japanese authors because Japanese often walk barefoot at home, and syndactyly of the toes is very noticeable and causes discomfort. Recently, European surgeons have reported their surgical experience with toe syndactyly and patient satisfaction after surgical repair.² Their investigation revealed that the patient's psychological concerns about syndactyly were reduced successfully postoperatively.² Therefore, aesthetic repair of syndactyly of the toes is desirable. There are 2

important factors for the aesthetic repair of syndactyly of the toe. One is to hide the operative scar from visual site (dorsal site), whereas the other is to create an interdigital space close to the normal anatomical skin characteristics (2 general types of skin: glabrous and hairy).

Here, we report on the surgical treatment for syndactyly and polysyndactyly using double volar flaps and a dorsal M-shaped flap without skin grafting to hide the operative scar from visual site and match skin characteristics of normal interdigital space.

PATIENTS AND METHODS

Patients

Between September 2013 and January 2016, 12 patients (6 males and 6 females) with 15 syndactylous webs underwent surgery via the double volar flap technique. Patient

From the Department of Plastic Surgery, Kanazawa Medical University Hospital, Ishikawa, Japan.

Received for publication October 14, 2016; accepted February 15, 2017.

Copyright © 2017 The Authors. Published by Wolters Kluwer Health, Inc. on behalf of The American Society of Plastic Surgeons. This is an open-access article distributed under the terms of the Creative Commons Attribution-Non Commercial-No Derivatives License 4.0 (CCBY-NC-ND), where it is permissible to download and share the work provided it is properly cited. The work cannot be changed in any way or used commercially without permission from the journal.

DOI: 10.1097/GOX.0000000000001293

Disclosure: *The authors have no financial interest to declare in relation to the content of this article. The Article Processing Charge was paid for by the authors.*

Supplemental digital content is available for this article. Clickable URL citations appear in the text.

age at operation was in the range of 10–20 months. Six patients had simple syndactylies (9 webs), 5 had polysyndactylies, and 1 had a constriction band syndrome (Table 1).

Surgical Technique

A retrospective case review is presented. Skin incision lines were drawn (Fig. 1), and the following 3 local flaps were designed for this technique: an M-shaped flap on the dorsal side of the interdigital region (flap A) and double volar flaps (flaps B and C) on the volar side of the interdigital region. Flap A was used for reconstruction of the web slope, whereas flaps B and C were used for reconstruction of the proximal sidewall of the toes. The length of flap A (lines a–c and b–d) was the same or shorter than the length from the dorsal proximal interphalangeal crease to the dorsal web baseline (approximately 8mm, the width was approximately 3mm in the case of a year-old child), and the length of 1 distal side of flap A (lines c–e and d–e) was approximately 2mm. A V-shaped incision line matching flap A was designed on the center of the volar interdigital region, so lines h–j and i–j were the same length as lines c–e and d–e. Line e–j was designed on the center line of the volar interdigital region. Lateral base points (points f and g) of flaps B and C were designed at the medial longer axis line of the toes intersecting the volar web baseline. The length of flaps B and C (lines j–k) was the same as the length of flap A. A gentle curve from points f and g to point k was designed for the lateral side of flaps B and C.

Incisions were made along the premarked lines after tourniquet inflation. Flaps A–C were elevated with the subcutaneous fat tissues, and the deep soft tissue at the base of the flaps was kept as a vascular pedicle. Flaps B and C were elevated while avoiding excess removal of fat tissue in the interdigital volar region and injury to the digital neurovascular bundles. Then, the toes were separated, and the interdigital fat tissue (especially dorsal side) was excised. The flexible digital dorsal skin was undermined. Hemostasis was achieved, after which the wound was closed.

Wound closure was performed as follows. First, the sidewall of the toes was sutured from distally to proximally as much as possible without causing excessive suture tension or ischemia of the toes with advancing the undermined digital dorsal skin of the toes (Fig. 2A). Then, flap

A was inserted into the interdigital space to create a web slope. Both sides of the base of flap A and the proximal dorsal skin of the toes were sutured for a few millimeters (Fig. 2B). Finally, flaps B and C were transferred to the remaining skin defects of the web space in the proximal aspect of the toes (Fig. 2C–F).

If the syndactyly was more distal than proximal interphalangeal, additional flaps were designed. (See Figure, Supplemental Digital Content 1, which displays the design of the operation (A), draft of the operation (B), final result of the operation (E), and draft (F), <http://links.lww.com/PRSGO/A407>.) The lengths of flaps A, B, and C were 8mm. Flap D was designed on the distal side of flap A, whereas flap E was designed on the distal side of flap D. Flaps D and E were elevated without the subcutaneous fat tissues. Flap D was used for reconstruction of the distal sidewall of 1 toe, whereas flap E was used for reconstruction of the distal sidewall of the other toe. The lengths of flaps D and E were approximately 3mm. If the syndactyly was severe or complete, 2 additional flaps could be designed.

RESULTS

All 15 web spaces were reconstructed successfully. Direct closure of all incisions around the web space was achieved in all cases. The average surgical time for repair of a simple syndactyly using our method was 77 minutes (range, 56–120 minutes) and polysyndactyly was 99 minutes (range, 85–120 minutes). There were no intraoperative complications and no cases of neurovascular compromise. Postoperatively, no wound infections, wound breakdowns, or flap necrosis occurred. Complete wound healing was experienced in all cases within 10 days. After a minimum follow-up period of 6 months (range, 6–40 months), the reconstructed webs remained satisfactory in appearance and function. The corrected toes showed a deep and natural interdigital commissure, with no exposure of skin grafts or conspicuous scars on the dorsal, visible side. The scars on the volar side also were inconspicuous.

Case 5

A 13-month-old girl had a fourth and fifth toe syndactyly on the right foot (Fig. 3). The double volar flap method was performed with the creation of 2 additional flaps. There

Table 1. Characteristics of Patients

No.	Age (mo)	Sex	Location	Involved Web	Syndactyly Type	Degree of Syndactyly	Follow-up Duration (mo)	Venous Congestion
1	12	M	Left foot	Second	Syndactyly	Incomplete (PIP)	26	None
2	11	F	Both feet	Second	Syndactyly	Incomplete (PIP)	24	None
3	20	F	Left foot	Second	Syndactyly	Incomplete (PIP)	20	None
4	12	F	Left foot	Fourth	Polysyndactyly	Incomplete (DIP)	20	None
5	13	F	Right foot	Fourth	Syndactyly	Incomplete (DIP)	20	None
6	12	M	Left foot	Second	Constriction band syndrome	Incomplete (PIP)	19	None
7	10	M	Right foot	Second	Polysyndactyly	Incomplete (PIP)	17	None
8	10	F	Both feet	Second	Syndactyly	Incomplete (DIP)	15	Mild
9	12	M	Right foot	Fourth	Polysyndactyly	Complete	15	None
10	11	M	Left foot	Fourth	Polysyndactyly	Complete	14	None
11	13	M	Right foot	Fourth	Polysyndactyly	Complete	10	None
12	11	F	Both feet	Second	Syndactyly	Incomplete (DIP)	6	Mild

DIP, distal interphalanx; PIP, proximal interphalanx.

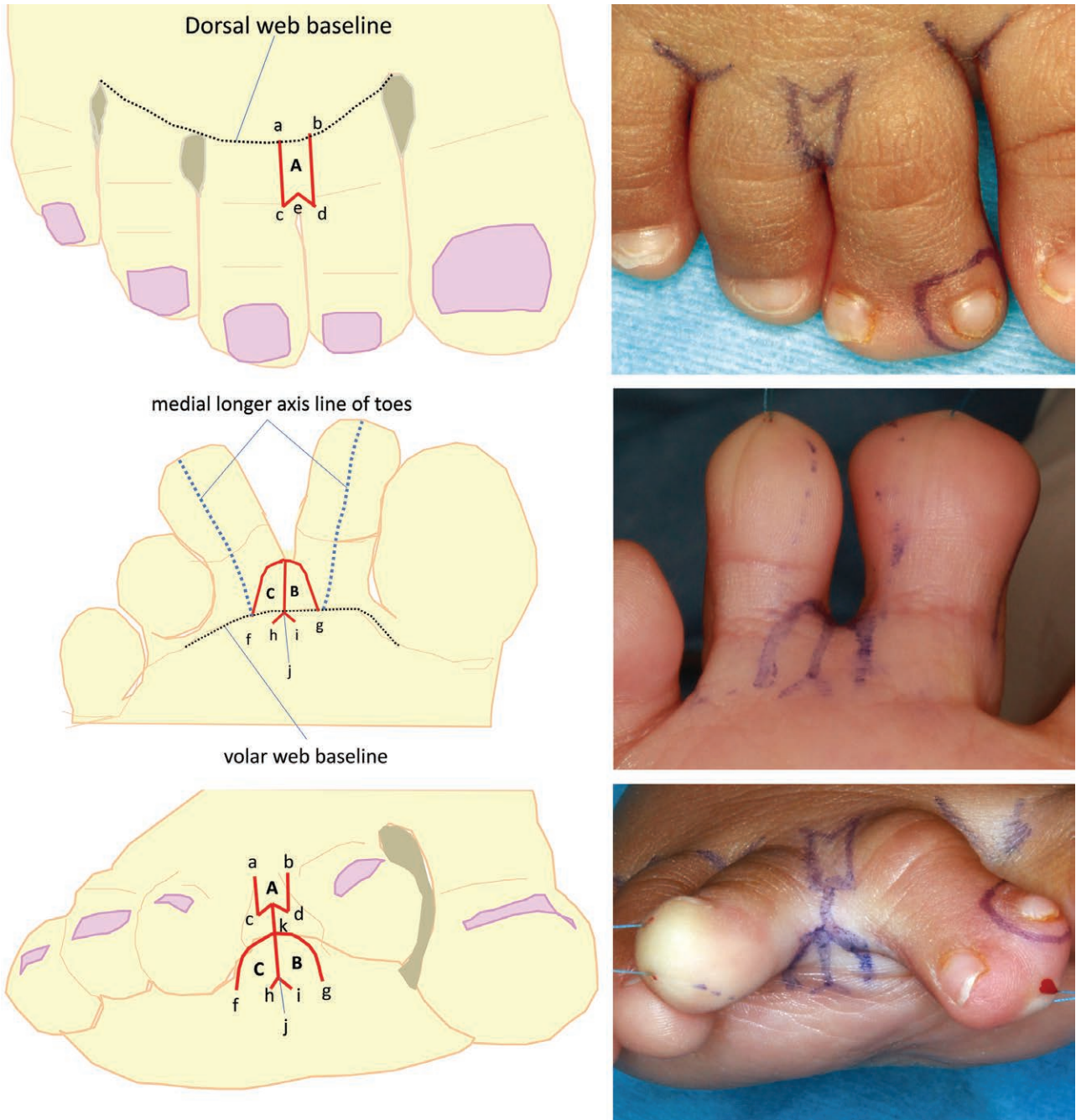


Fig. 1. The polysyndactyly was more proximal than the proximal interphalangeal. Left column, Draft of operation. Right column, Design of operation. Upper row, Dorsal appearance. Middle row, volar appearance. Bottom row, interdigital appearance. The length of flap A (lines a–c and b–d) was the same as or shorter than that of the dorsal proximal interphalangeal crease to the dorsal web baseline (approximately 8 mm, the width was approximately 3 mm in the case of the 1-year-old child), and the length of 1 distal side of flap A (lines c–e and d–e) was approximately 2 mm. A V-shaped incision line matching flap A was designed on the center of the volar interdigital region, so lines h–j and i–j were the same length as lines c–e and d–e. Line e–j was designed on the center line of the volar interdigital region. Lateral base points (points f and g) of flaps B and C were designed at medial longer axis line where the toes intersected the volar web baseline. The length of flaps B and C (lines j–k) was the same as the length of flap A. A gentle curve from points f and g to point k was designed for the lateral side of flaps B and C. Kirschner wire was used to rest the region of distal phalangeal arthroplasty.

was no scar on the dorsal (Fig. 4A) or plantar (Fig. 4B) aspects of the foot 20 months postoperatively. Skin color and texture of the interdigital space was good. The interdigital space showed a deep and natural configuration.

Case 8

A 10-month-old girl had a second and third toe syndactyly on the left foot. (See Figure, Supplemental Digital Content 2, which shows a second and third toe syndactyly on the

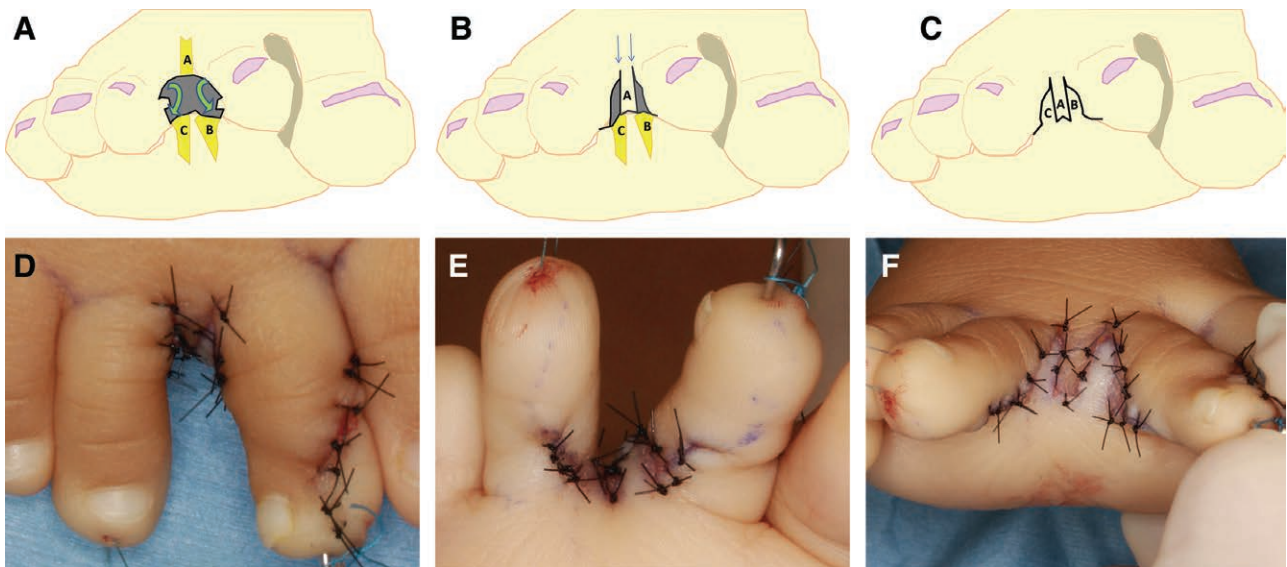


Fig. 2. A, Draft of the interdigital space of the toe after incision and defatting. The sidewall of the toes was sutured from distally to proximally with expanded digital dorsal skin of the toes (arrows). B, Flap A was inserted into the interdigital space to create a web slope. Both sides of the base of flap A and the proximal dorsal skin of the toes (arrows) were sutured for few millimeters. C and D, Draft of the suture line and final appearance of the interdigital space. Final appearance of operation of the dorsal (E) and volar (F) aspects.

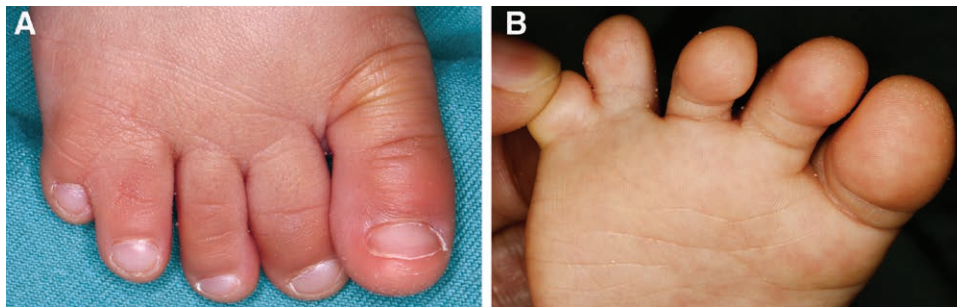


Fig. 3. Case 5. A 10-month-old girl had a fourth and fifth toe syndactyly on the right foot. The syndactyly was more distal than proximal interphalangeal. A, Dorsal appearance. B, Plantar appearance.

left foot. The syndactyly was more distal than distal interphalangeal, (<http://links.lww.com/PRSGO/A408>.) The double volar flap method was performed with the creation of 4 additional flaps (2 dorsal and 2 volar flaps). The scar was nearly invisible on the dorsal and volar sides, and the interdigital space showed a deep and natural configuration 15 months postoperatively. (See Figure, Supplemental Digital Content 3, which shows the postoperative view of the dorsal side (A) and the plantar side (B). The operation scar was inconspicuous, and the interdigital space showed a deep and natural configuration, <http://links.lww.com/PRSGO/A409>.)

DISCUSSION

A multitude of techniques for syndactyly and polysyndactyly release have been described over the years. All techniques used local flaps to create web slope; however, there are differences in the treatment of skin defects in the lateral aspects of the toes.³⁻¹⁰ The techniques may be divided according to the treatment of skin defects in the lateral aspects of the toes into 3 groups: skin grafts, open treatment, and local flaps.

Skin grafting has remained the mainstay of repair of syndactyly and polysyndactyly. However, problems associated with the use of skin grafts include contractures and hypertrophic scars in the case of partial graft loss, pigmentation differences between the donor and recipient sites, suboptimal digital contour, donor-site morbidity, and a time-consuming repair.^{3,4}

In the open technique, residual skin defects of the lateral aspects of the separated toes are intentionally left open and allowed to heal by secondary intention.⁵ This technique shortens the operation time and eliminates the need for postoperative care of the healing grafts. However, the risk of web creep may be increased because of wound scar constriction, and the risk of infection is increased due to open wounds and Kirschner wire insertion in the toe until new epithelialization occurs to prevent contracture and the wound could be well taken care of by the parents at home during the 5 weeks of healing.⁶

The local flap method is theoretically advantageous, resulting in a good color match and contour of the digits, reduced operative time, and avoidance of complications as

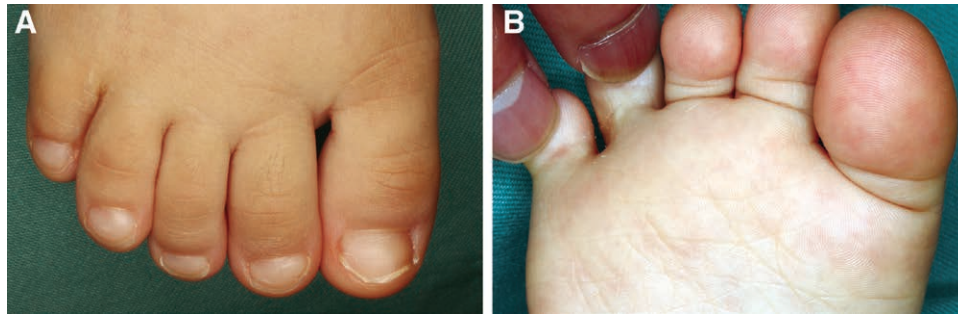


Fig. 4. Appearance of toes 20 months after reconstruction. The double volar flap method was performed with 2 additional flaps. A, Dorsal appearance: the operation scar can hardly be seen, and the interdigital space showed a deep and natural configuration. B, Plantar appearance: the operation scar could hardly be seen, and the interdigital space also showed a deep and natural configuration. Web appearance: skin color and texture of the interdigital space was good.

sociated with the use of skin grafts. However, those skin flaps usually are limited with respect to size and may not provide sufficient skin to create an adequate interdigital space.⁷ Therefore, additional incisions of the dorsal or plantar aspect of the foot were needed to create the flaps. Lim et al.⁴ performed a dorsal pentagonal island flap commissural reconstruction, which achieved functional web creation; however, the dorsal longitudinal scars, continuing from the base of the web to the dorsum of the metatarsal, had an increased tendency for hypertrophic scar or keloid formation. Itoh and Arai⁸ and Park et al.⁷ separately reported a similar procedure in which the flap created in the plantar aspect was moved to the interdigital space, which provided adequate cosmetic results but caused pain during walking due to scarring of the weight-bearing plantar skin.⁹ Hayashi et al.¹⁰ described a 4-flap procedure with the web recreated using a flap supplied via a subcutaneous pedicle without skin grafting, but partial necrosis of the subcutaneous skin flap occurred in 3 of 10 patients. The reason for necrosis of the flaps is that the subcutaneous flap had a more delicate circulation. In short, dorsal flaps may cause conspicuous scarring, and plantar flaps may cause pain by scarring on the plantar surface. An interdigital subcutaneous flap may cause necrosis of the flap.

Our method has 3 advantages of no conspicuous scarring, no pain during walking, and less necrosis of the flaps because the skin flaps are only interdigital flaps without additional incision of the dorsal or plantar aspect of the foot and are not subcutaneous flap but simple skin flap. There were 2 reasons for accelerated cosmetic results of our method. First, the interdigital toes created by our method had a near normal anatomical skin characteristic. It is important to repair syndactyly for aesthetic reasons and to treat the defect after separation of syndactyly by skin of a similar characteristic. There are 2 characteristic skin in the hands and feet: glabrous and hairy skin. The palms, soles, and flexor aspects of the digits and toes consist of glabrous skin, which has no sebaceous glands, fewer pigment cells, thicker epidermis or cuticle, and are less elastic than dorsal hairy skin.¹¹ Interdigital toes are composed of glabrous skin on the volar region and hairy skin on the dorsal region; the midlateral line of the toe is the boundary between the 2 characteristic skin, and most of the web of the toe consists of volar glabrous

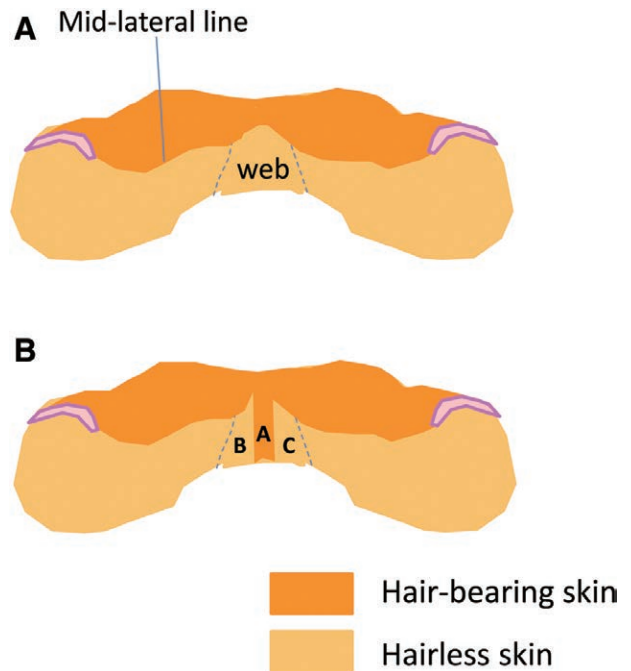


Fig. 5. A, Color coding draft of normal anatomical skin characteristic of the toes and web by 2 skin types; the hairless skin and hair-bearing skin. The midlateral line of the toe is the boundary between the 2 types of skin, and most of web of toe consists of volar hairless skin. B, Color coding draft of normal anatomical skin characteristic created by our method. The scar of the lateral side of the toes coincided with the midlateral line. The skin type of the web with the dorsal M-shaped flap (hair-bearing skin: flap A) and double volar flaps (hairless skin: flaps B and C) was near to normal.

skin (Fig. 5A). The characteristics can be visually distinguished on the basis of the skin color as follows: glabrous skin (light color) and hairy skin (dark color). Our method created the lateral side of the toes from the flexible digital dorsal skin expanded to coincide with the midlateral line to hide the operative scar from visual site (dorsal site) and create close to normal midlateral line, and the web of the toe was created close to characteristic skin using a dorsal M-shaped flap (hair-bearing skin: flap A) and double volar flaps (glabrous skin: flaps B and C; Fig. 5B).

Therefore, our method may create nearly normal anatomical skin characteristics without the part of flap A and thus achieve excellent authentic results. We removed the interdigital fat tissue (especially on the dorsal side) and undermined the dorsal skin of the toes to expand it easily. The toes sometimes were rotated slightly just after the operation but returned easily to a normal state after a few days. Second, the created web was kept deep enough to prevent web creep due to the 3 opposite flaps meshed to each other. Our method has an additional advantage of avoidance of unnecessary materials, such as a Kirschner wire and a cast, to rest the surgical region postoperatively (with the exception of polysyndactyly, which requires arthroplasty). Therefore, the children remained in the hospital for a short period.

The disadvantage of our method is the risk of venous congestion of the toes due to overexpansion of the dorsal skin. Mild venous congestion was restored within several weeks. Monitoring should be done postoperatively at close intervals. There are 2 cases in mild venous congestion of toes in our case series. Both the cases had narrow syndactyly and more distal than proximal interphalangeal. We experienced no cases of excess venous congestion. Should this occur, skin grafting can be performed.

The relatively small number of patients is the limiting aspect of this study. The results obtained were from a limited patient group that showed the factors restricting the use of this method in syndactylies of the finger, complete simple syndactylies with bone fusion, and patients more than 2 years old. This method is not appropriate for syndactyly of the finger because the interdigital space of the hand would be widely opened. Distal limit of syndactyly where this method is applicable is complete syndactyly in polysyndactyly and incomplete syndactyly in simple syndactyly proximal to distal interphalangeal because nail folds can be created with skin of excised redundant toe in polysyndactyly but not in simple syndactyly. Age range where we believe this method is applicable is until a year old because a 2-year-old patient (the degree of syndactyly was distal interphalangeal) needed an additional skin graft in our experience.

The double volar flap method for repair of syndactyly and polysyndactyly of the toes has the same advantages as those of local flap method, in addition to an optimum aesthetic result through matching with the normal anatomical skin characteristic of the interdigital space and the hiding of the operative scar from visual site. The procedure reduces operative time and duration of stay in the hospital and avoids complications associated with the use of skin grafts.

Toru Miyanaga, MD, PhD

Kanazawa Medical University Hospital
1-1 Daigaku, Uchinada-machi, Kahoku-gun
Ishikawa 9200265, Japan
E-mail: miyanaga@kanazawa-med.ac.jp

REFERENCES

1. McDaniel L, Tafuri SA. Congenital digital deformities. *Clin Podiatr Med Surg*. 1996;13:327–342.
2. Marsh DJ, Floyd D. Toe syndactyly revisited. *J Plast Reconstr Aesthet Surg*. 2011;64:535–540.
3. Kawabata H, Ariga K, Shibata T, et al. Open treatment of syndactyly of the foot. *Scand J Plast Reconstr Surg Hand Surg*. 2003;37:150–154.
4. Lim YJ, Teoh LC, Lee EH. Reconstruction of syndactyly and polysyndactyly of the toes with a dorsal pentagonal island flap: a technique that allows primary skin closure without the use of skin grafting. *J Foot Ankle Surg*. 2007;46:86–92.
5. Saito S, Suzuki Y, Suzuki S. Technique of dorsal transversely oriented transposition flap for web reconstruction in toe syndactyly surgery. *J Foot Ankle Surg*. 2015;54:1119–1123.
6. Hikosaka M, Ogata H, Nakajima T, et al. Advantages of open treatment for syndactyly of the foot: defining its indications. *Scand J Plast Reconstr Surg Hand Surg*. 2009;43:148–152.
7. Park S, Eguchi T, Tokioka K, et al. Reconstruction of incomplete syndactyly of the toes using both dorsal and plantar flaps. *Plast Reconstr Surg*. 1996;98:534–537.
8. Itoh Y, Arai K. A new operation for syndactyly and polysyndactyly of the foot without skin grafts. *Br J Plast Surg*. 1995;48:306–311.
9. Iida N, Kotake A. A new surgical procedure for little toe polysyndactyly without skin graft. *Ann Plast Surg*. 2011;67:167–169.
10. Hayashi A, Yanai A, Komuro Y, et al. A new surgical technique for polysyndactyly of the toes without skin graft. *Plast Reconstr Surg*. 2004;114:433–438.
11. Webster JP. Skin grafts for hairless areas of the hands and feet; a preliminary report. *Plast Reconstr Surg (1946)*. 1955;15:83–101.