

Inosine monophosphate dehydrogenase 2 as a marker of aggressive and advanced prostate cancer

Paweł Wieczorek¹, Marta Bałut-Wieczorek¹, Miłosz Jasinski², Waldemar Szabłoński³, Andrzej Antczak³

¹Department of Urology, University Hospital in Zielona Góra, Poland

²Department of Oncological Urology, Oncology Centre in Bydgoszcz, Poland

³Department of Urology, Józef Struś Municipal Hospital in Poznań, Poland

Citation: Wieczorek P, Bałut-Wieczorek M, Jasinski M, Szabłoński W, Antczak A. Inosine monophosphate dehydrogenase 2 as a marker of aggressive and advanced prostate cancer. Cent European J Urol. 2018; 71: 399-403.

Article history

Submitted: April 5, 2018

Accepted: Sept. 2, 2018

Published online: Sept. 24, 2018

Corresponding author

Miłosz Jasinski

Oncology Centre
in Bydgoszcz

Department of Oncological
Urology

85-796 Bydgoszcz, Poland

2 Romanowskiej Street

phone: +48 606 119 821

miloszj@onet.pl

Introduction There is a need for a new biochemical marker of aggressive prostate cancer (PCa). Inosine monophosphate dehydrogenase 2 (IMPDH2) is a candidate for such a marker – its activity is increased in certain tumors and neoplastic cell lines, including PCa, and may correlate with cancer aggressiveness.

Material and methods IMPDH2 levels were measured in blood samples from 34 PCa patients. The results were analyzed and correlated with prostate-specific antigen (PSA), digital rectal examination (DRE), Gleason score, risk groups according to d'Amico and metastatic disease. Twenty healthy (non-PCa) patients served as the control group.

Results There was no significant difference in IMPDH2 level between the PCa and control group, and no significant correlation between PSA and IMPDH2. IMPDH2 levels were significantly higher in the DRE (+) patients (148.5 ± 174.8 vs. 33.4 ± 46.4 , $p < 0.05$), in patients with metastatic disease (100.1 ± 139.0 vs. 25.3 ± 25.9 , $p < 0.05$) and in the high-risk group according to d'Amico (93.4 ± 129.2 vs. 18.8 ± 10.4 , $p < 0.05$). There was a significant correlation between the Gleason score and IMPDH2.

Conclusions These results suggest that IMPDH2 is a promising candidate as a biomarker for those with advanced PCa and those at high risk of progression towards advanced PCa.

Key Words: prostate cancer ◊ biomarker ◊ metastases ◊ inosine monophosphate dehydrogenase 2

INTRODUCTION

Prostate cancer is a serious epidemiological problem. According to the American Cancer Society 161360 new cases and 26730 prostate cancer (PCa) deaths will occur in 2017 in the United States [1]. The progress in diagnostics has increased PCa detection rate, also of the lowest-risk, indolent cases [2, 3, 4]. On the other hand, it is important to identify the patients with advanced disease or patients at high risk of progression.

The prostate-specific antigen (PSA) level, digital rectal examination (DRE), Gleason score of the samples from biopsy and imaging – transrectal ultrasound (TRUS), magnetic resonance (MR), positron emission tomography and bone scan are currently used in PCa detection and staging. All these

methods, however, have significant limitations. Although PSA, DRE and Gleason score have been proved to correlate with the risk of disease progression, they do not allow us to identify all cases of advanced disease [5–9].

While diagnostic imaging is useful in the assessment of disease extent and detection of metastases, its sensitivity in minimally disseminated disease (micrometastases) is insufficient [10, 11, 12].

There is a need for a new biochemical marker allowing for the identification of the aggressive cases as well as to distinguish between localized and metastatic disease [13]. Inosine monophosphate dehydrogenase 2 (IMPDH2), an enzyme involved in guanine nucleotide biosynthesis, is the potential marker that may be used as described previously. The activity of IMPDH2 has been shown to be increased

in certain tumors and neoplastic cell lines [14–17]. IMPDH2 is overexpressed in PCa cells and both its expression in PCa tissue and concentration in serum may correlate with PCa aggressiveness [18, 19]. Its enhanced expression in PCa tissue has been found to correlate with the clinical stage and Gleason score [20]. The aim of this study was to investigate the correlation of IMPDH2 with known markers of aggressive or advanced PCa.

MATERIAL AND METHODS

There were 34 patients from the Department of Urology, Provincial Specialist Hospital in Zielona Gora, who were included in the study conducted in 2013–2014. Inclusion criteria included newly diagnosed prostate cancer via biopsy, no previous treatment, and completed diagnostic imaging for suspected metastatic disease. Patients were interviewed for concomitant diseases and urological history. DRE was performed, while PSA and IMPDH2 level was measured in blood samples. Patients were qualified for the prostate biopsy according to the European Association of Urology (EAU) guidelines [21]. Transrectal ultrasound (TRUS) biopsy was performed using the 2101 Falcon ultrasound (B-K Medical) according to EAU guidelines, with at least 5 samples from each lobe. Patients were assigned to risk groups according to d'Amico [22]. The characteristics of the group are presented in Table 1.

The control group included 20 male patients admitted to the Department of Urology, Provincial Specialist Hospital in Zielona Gora due to non-neoplastic, non-inflammatory urological disorders (short frenulum, phimosis). Chronic diseases, past urological treatment and tobacco smoking were considered the exclusion criteria. DRE was performed, while PSA and IMPDH2 level was measured in blood samples. All patients underwent TRUS to exclude abnormalities in the prostate.

IMPDH2 levels were measured in the Central Laboratory of Provincial Specialist Hospital in Zielona Gora using Cusabio® Human Inosine-5'-monophosphate dehydrogenase 2 (IMPDH2) Elisa Kit.

The study was approved by the local ethical committee. Written informed consent was obtained from all patients.

Excel 2013 (Microsoft), SPSS Statistics 24 (IBM) and Statistica 12 was used for statistical analysis. Variables were presented as mean \pm standard deviation. Statistical analysis was performed using Mann-Whitney U test. The Kendall's tau and Spearman's rho correlation coefficients were used to test the strength of associations between the variables.

Table 1. The characteristics of patients included in the study

	n	34
Age (years)		68.2 \pm 6.5
PSA (ng/ml)		139.4 \pm 355.3
Digital rectal examination	+	8
	–	26
Gleason score	≤ 6	8
	3+4	9
	4+3	4
	8	8
	9	4
Metastatic disease	+	16
	–	18
Risk group according to d'Amico	Low	6
	Medium	9
	High	19

Values of $p < 0.05$ were considered statistically significant.

RESULTS

Although IMPDH2 level in PCa patients was higher than in the control group (60.5 \pm 102.8 vs. 24.9 \pm 15.6), the difference was not statistically significant ($p = 0.774$, Mann-Whitney). There was no significant correlation between PSA and IMPDH2 in the studied group ($r = 0.296$, $p = 0.089$, Spearman rho).

IMPDH2 level in patients with abnormal DRE was significantly higher (148.5 \pm 174.8 vs. 33.4 \pm 46.4, $p = 0.043$, Mann-Whitney) (Figure 1).

A significant difference in IMPDH2 was also observed between patients with and without diagnosed metastatic disease (100.1 \pm 139.0 vs. 25.3 \pm 25.9, $p = 0.017$, Mann-Whitney) (Figure 2).

There was also a significant difference between low-together with intermediate- and high-risk groups according to d'Amico (93.4 \pm 129.2 vs. 18.8 \pm 10.4, $p = 0.020$, Mann-Whitney) (Figure 3).

Patients have been stratified according to the Gleason score into five groups: 1 – Gleason ≤ 6 , 2 – Gleason 3+4, 3 – Gleason 4+3, 4 – Gleason 8, 5 – Gleason 9. A positive correlation between the Gleason group and IMPDH2 level was found ($\tau = 0.368$, $p = 0.005$, Kendall tau), and higher levels of IMPDH2 were associated with higher Gleason groups. The same analysis was performed separately for patients with and without diagnosed metastatic disease. A positive correlation was found in the metastatic group ($\tau = 0.390$, $p = 0.043$, Kendall tau), while no significant correlation was found in the group with-

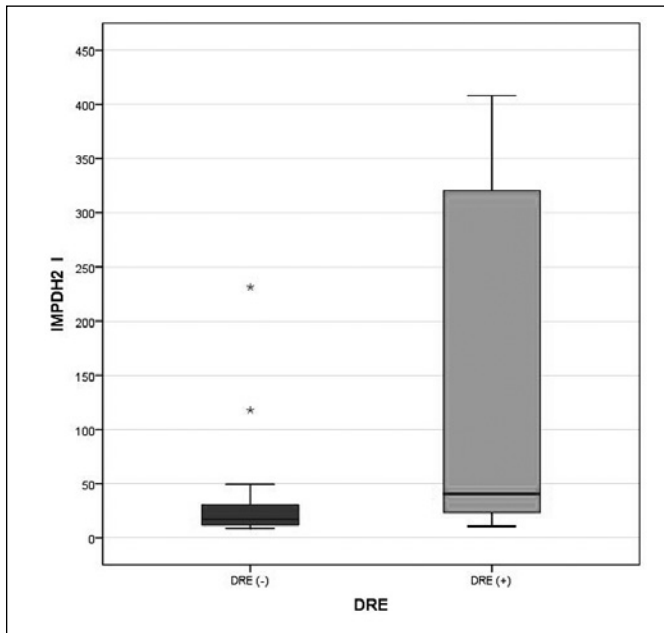


Figure 1. Inosine monophosphate dehydrogenase 2 according to digital rectal examination.

IMPDH2 – inosine monophosphate dehydrogenase 2

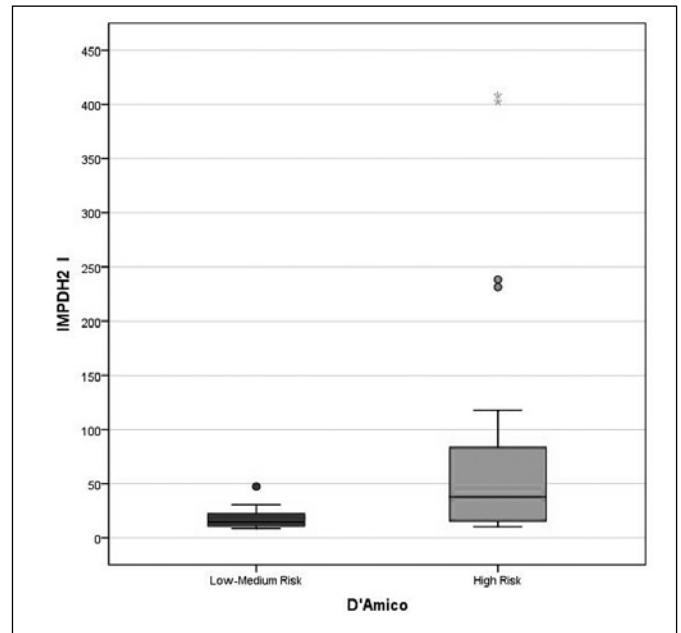


Figure 3. Inosine monophosphate dehydrogenase 2 according to d'Amico risk group.

IMPDH2 – inosine monophosphate dehydrogenase 2

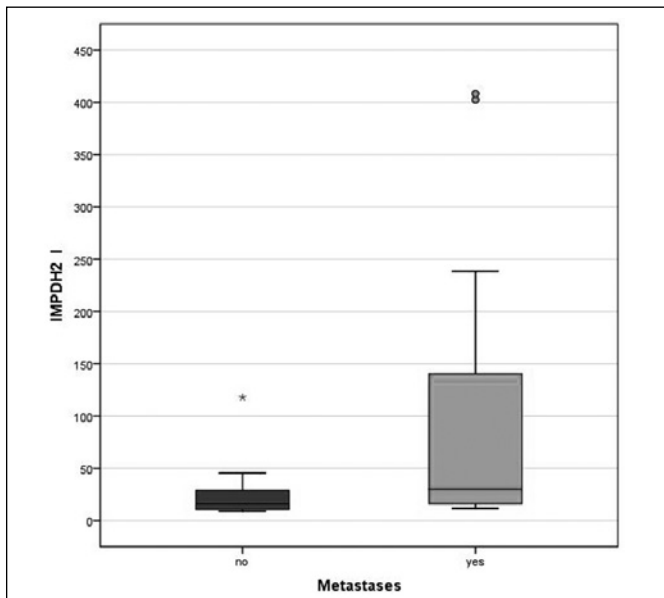


Figure 2. Inosine monophosphate dehydrogenase 2 according to presence of metastases.

IMPDH2 – inosine monophosphate dehydrogenase 2

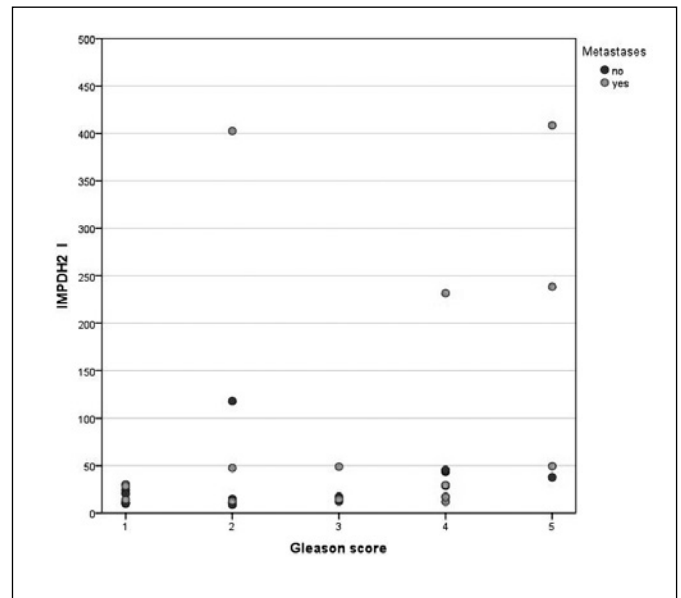


Figure 4. Inosine monophosphate dehydrogenase 2 according to Gleason score and presence of metastases.

IMPDH2 – inosine monophosphate dehydrogenase 2

out metastases ($\tau = 0.293$, $p = 0.137$, Kendall tau) (Figure 4).

DISCUSSION

It is important to identify early the PCa patients in whom the disease will progress or disseminate.

However, in spite of several clinical parameters, such as PSA and Gleason score, it is still difficult to reliably predict the tumor behavior of PCa and its response to therapy [7, 23]. This explains the need for new biochemical markers.

IMPDH2 has been suggested to play an important role in tumorigenesis of various cancer types

[16, 18]. Its expression is elevated in PCa tissue and its level has been found to correlate with the Gleason score and presence of metastases, which makes it an attractive candidate as a marker of PCa progression or dissemination [18, 20].

Our results did not confirm the difference in IMPDH2 level between PCa and control groups, described by Han et al. [18]. There was also no significant correlation with the PSA level. It can be explained by the fact that, despite the significance of PSA, there is in certain cases no clear correlation between the PSA level and advanced disease [24, 25, 26]. In our material, IMPDH2 correlates with the Gleason score and the presence of metastases, as described by Han et al. and Zhou et al. [18, 20].

IMPDH2 levels in DRE positive patients were significantly higher – it is an interesting finding, because positive DRE PCa cases are often more advanced, with a higher Gleason score and an increased risk of capsular infiltration [15, 16]. Unfortunately, there are no magnetic resonance (MR) results or any other data about capsular invasion available for the investigated group.

Furthermore, IMPDH2 levels were significantly higher in the high-risk group according to d'Amico than in the low- and medium-risk groups. There was another interesting finding – the IMPDH2 level correlated with the Gleason score in the non-metastatic group, but in the group with metastatic disease there was no significant correlation. It may be explained by the fact that patients with metastatic disease had elevated IMPDH2 because of metastases, irrespective of the Gleason score, but also it may indicate that some patients with higher IMPDH2 in the non-metastatic group may already harbor not yet detectable micrometastases.

These results indicate that IMPDH2 may be an interesting candidate as a marker of advanced or at high risk of progression PCa. There are, however, some issues that require further investigation.

It would be interesting to find if and how the level of IMPDH2 correlates with MR results – extracapsular extension and lymph node involvement. Another issue is the ability to detect undergrading in prostate biopsy. It should be investigated whether higher Gleason score in a specimen from a radical prostatectomy than in prostate biopsy correlates with an increased IMPDH2. The patients with elevated IMPDH2 and without detectable metastases should be carefully followed to find if they develop metastatic disease. Finally, it should be investigated if elevated IMPDH2 correlates with lymph node involvement, especially the ones not visible in MR. The nomograms used to estimate the risk of lymph node metastasis have been validated over 10 years ago and there is currently no reliable marker of lymph node involvement [27]. If IMPDH2 could improve the reliability of lymph node metastasis detection, it would be an important finding.

This study has two main limitations: the small size of the group, which was, however, enough to achieve statistically significant results, and the lack of a longer follow-up.

IMPDH2 has one another advantage – the test does not require any special equipment, other than those commonly available in diagnostic laboratories, and is relatively inexpensive – the cost of a measurement kit is less than 9 € per one measurement.

CONFLICTS OF INTEREST

The authors declare no conflicts of interest.

COMPLIANCE WITH ETHICAL STANDARDS

All procedures performed in studies involving human participants were in accordance with the ethical standards of the institutional and/or national research committee and with the 1964 Helsinki declaration and its later amendments or comparable ethical standards.

Informed consent was obtained from all individual participants included in the study.

References

1. American Cancer Society. <https://www.cancer.org/cancer/prostate-cancer.html>
2. Wilt TJ, Brawer MK, Jones KM, et al. Radical prostatectomy versus observation for localized prostate cancer. *N Engl J Med.* 2012; 367: 203-213.
3. Bill-Axelson A, Holmberg L, Ruutu M, et al. Radical prostatectomy versus watchful waiting in early prostate cancer. *N Engl J Med.* 2011; 364: 1708-1717.
4. Bruinsma SM, Roobol MJ, Carroll PR, et al. Expert consensus document: Semantics in active surveillance for men with localized prostate cancer- results of a modified Delphi consensus procedure. *Nat Rev Urol.* 2017; 14: 312-322.
5. Catalona WJ, Richie JP, Ahmann FR, et al. Comparison of digital rectal examination and serum prostate specific antigen in the early detection of prostate cancer: results of a multicenter clinical trial of 6,630 men. *J Urol.* 1994; 151: 1283-1290.
6. Chodak GW, Keller P, Schoenberg HW. Assessment of screening for prostate cancer using the digital rectal examination. *J Urol.* 1989; 141: 1136-1138.
7. Cohen MS, Hanley RS, Kurteva T, et al. Comparing the Gleason prostate biopsy and Gleason prostatectomy grading system: the Lahey Clinic Medical Center experience and an international meta-analysis. *Eur Urol.* 2008; 54: 371-381.

8. Corcoran NM, Hong MK, Casey RG, et al. Upgrade in Gleason score between prostate biopsies and pathology following radical prostatectomy significantly impacts upon the risk of biochemical recurrence. *BJU Int.* 2011; 108: E202-210.
9. Corcoran NM, Hovens CM, Hong MK, et al. Underestimation of Gleason score at prostate biopsy reflects sampling error in lower volume tumours. *BJU Int.* 2012; 109: 660-664.
10. Zacho HD, Barsi T, Mortensen JC, et al. Prospective multicenter study of bone scintigraphy in consecutive patients with newly diagnosed prostate cancer. *Clin Nucl Med.* 2014; 39: 26-31.
11. Budiharto T, Joniau S, Lerut E, et al. Prospective evaluation of 11C-choline positron emission tomography/computed tomography and diffusion-weighted magnetic resonance imaging for the nodal staging of prostate cancer with a high risk of lymph node metastases. *Eur Urol.* 2011; 60: 125-130.
12. Hövels AM, Heesakkers RA, Adang EM, et al. The diagnostic accuracy of CT and MRI in the staging of pelvic lymph nodes in patients with prostate cancer: a meta-analysis. *Clin Radiol.* 2008; 63: 387-395.
13. D'Amico AV. Active Surveillance Versus Treatment of Prostate Cancer: Should Metastasis Be the Primary End Point? *J Clin Oncol.* 2017; 35: 1638-1640.
14. Collart FR, Chubb CB, Mirkin BL, Huberman E: Increased Inosine-5'-phosphate Dehydrogenase gene expression in solid tumor tissues and tumor cell lines. *Cancer Res.* 1992; 52: 5826.
15. Balzarini J, Karlsson A, Wang L, et al. Eicar (5-ethynyl-1-beta-D-ribofuranosylimidazole-4-carboxamide). A novel potent inhibitor of inosinate dehydrogenase activity and guanylate biosynthesis. *J Biol Chem.* 1993; 268: 24591-24598.
16. Zou J, Han Z, Zhou L, et al. Elevated expression of IMPDH2 is associated with progression of kidney and bladder cancer. *Med Oncol.* 2015; 32: 373.
17. Floryk D, Tollaksen LS, Giometti C. Differentiation of human prostate cancer PC-3 cells induced by inhibitors of Inosine 5'-monophosphate Dehydrogenase. *Cancer Res.* 2004; 64: 9049-9056.
18. Han ZD, Zhang YQ, He HC, et al. Identification of novel serological tumor markers for human prostate cancer using integrative transcriptome and proteome analysis. *Med Oncol.* 2012; 29: 2877-2888.
19. Guyon I, Fritsche H, Choppa P, Yang Li-Ying, Barnhill S. A Four-Gene Expression Signature for Prostate Cancer Cells Consisting of UAP1, PDLIM5, IMPDH2, and HSPD1. *UroToday Int J.* 2009; 2: 3834-3844.
20. Zhou L, Xia D, Zhu J, et al. Enhanced expression of IMPDH2 promotes metastasis and advanced tumor progression in patients with prostate cancer. *Clin Transl Oncol.* 2014; 16: 906-913.
21. Guidelines on Prostate Cancer. In: EAU Guidelines, edition presented at the 32nd EAU Annual Congress, London 2017. ISBN 978-90-79754-91-5.
22. D'Amico AV, Whittington R, Malkowicz SB, et al. Biochemical outcome after radical prostatectomy, external beam radiation therapy, or interstitial radiation therapy for clinically localized prostate cancer. *JAMA.* 1998; 280: 969-974.
23. Eisenberger MA, Blumenstein BA, Crawford ED, et al. Bilateral orchiectomy with or without flutamide for metastatic prostate cancer. *N Engl J Med.* 1998; 339: 1036-1042.
24. Schröder FH, van der Crujisen-Koeter I, de Koning HJ, Vis AN, Hoedemaeker RF, Kranse R. Prostate cancer detection at low prostate specific antigen. *J Urol.* 2000; 163: 806-812.
25. Izumi K, Ikeda H, Maolake A, et al. The relationship between prostate-specific antigen and TNM classification or Gleason score in prostate cancer patients with low prostate-specific antigen levels. *Prostate.* 2015; 75: 1034-1042.
26. Izumi K, Lin WJ, Miyamoto H, et al. Outcomes and predictive factors of prostate cancer patients with extremely high prostate-specific antigen level. *J Cancer Res Clin Oncol.* 2014; 140:1413-1419.
27. Briganti A, Chun FK, Salonia A, et al. Validation of a nomogram predicting the probability of lymph node invasion among patients undergoing radical prostatectomy and an extended pelvic lymphadenectomy. *Eur Urol.* 2006; 49: 1019-1026. ■