

# Bilateral compressive optic neuropathy secondary to sphenoid sinus mucocele mimicking bilateral retrobulbar neuritis

Amit K. Deb, Aswathi Neena, Sandip Sarkar, Athira Devraj, Gayathri Panicker, A. Mary Stephen

<b>Access this article online</b>
Quick Response Code:

Website: www.saudijophthalmol.org
DOI: 10.4103/1319-4534.347312

## Abstract:

Sphenoid sinus mucoceles (SSMs) can rarely cause acute bilateral vision loss. We, hereby, report such a rare case of SSM in a 20-year-old female who presented with sudden onset bilateral diminution of vision. The best-corrected visual acuity was 20/400 in the right eye (RE) and hand movements in the left eye (LE). Both eyes had sluggish pupillary reactions. Both eyes had normal fundus. Initial treatment was started with a provisional diagnosis of bilateral retrobulbar neuritis, but imaging revealed a large SSM compressing bilateral optic nerves. The patient underwent urgent surgical decompression. Vision in RE improved to 20/20 and LE to 20/400. A high index of clinical suspicion for compressive lesions is needed in all cases of atypical optic neuritis.

## Keywords:

Atypical optic neuritis, bilateral compressive optic neuropathy, sphenoid sinus mucocele

## INTRODUCTION

Paranasal sinus mucoceles are encapsulated benign cystoid lesions with respiratory epithelial lining. They are most prevalent in the frontal and ethmoidal sinuses.<sup>[1,2]</sup> Sphenoid sinus mucoceles (SSMs) are of rare occurrence comprising of only 1%–2% of paranasal sinus mucoceles. The most common presenting symptoms in SSM are frontal or retro-bulbar pain, visual impairment, ocular palsy (3<sup>rd</sup> and 6<sup>th</sup> cranial nerve palsy), diplopia, proptosis, and endocrine abnormalities secondary to pituitary gland dysfunction.<sup>[1,3]</sup> Bilateral acute vision loss in SSM has been reported very rarely. Diagnosis is often missed in such cases and requires a high clinical suspicion index to ensure early imaging and surgical intervention.<sup>[3-5]</sup> We, hereby, report such a rare case of bilateral SSM masquerading as bilateral retrobulbar neuritis with unilateral complete visual recovery following surgical intervention.

## CASE REPORT

A 20-year-old female presented to us with a history of sudden-onset gross diminution

of vision in the left eye (LE) for 9 days and right eye (RE) for 5 days duration. Visual loss was associated with headache and bilateral mild retro-orbital pain at the onset. No history suggestive of sinusitis, nasal discharge, or any other systemic or ocular comorbidities could be elicited. On examination, the best-corrected visual acuity (BCVA) was 20/400 in RE and hand movements in LE. Pupils were 4 mm in size with sluggish reactions in both eyes. Anterior segment examination was normal in both eyes. Fundus examination in both eyes showed normal optic disc (no pallor, hyperemia, or edema) and normal macula [Figures 1a and b]. A provisional diagnosis of bilateral retrobulbar neuritis was made. Intravenous methylprednisolone 1 g daily was given for 3 days, but there was no improvement of vision. Cerebrospinal fluid (CSF) studies including anti-aquaporin-4 and anti-myelin oligodendrocyte glycoprotein antibodies were normal. Contrast magnetic resonance imaging (MRI) showed a normal study of the brain and spine. However, MRI images of the orbit and the paranasal sinuses (PNS) revealed a mucocele of the sphenoid sinus causing a direct compression on bilateral optic nerves in the optic canals [Figure 2a and b]. An immediate

Department of Ophthalmology,  
Jawaharlal Institute of  
Postgraduate Medical  
Education and Research,  
Puducherry, India

### Address for correspondence:

Dr. Sandip Sarkar,  
Department of  
Ophthalmology, Jawaharlal  
Institute of Postgraduate  
Medical Education and  
Research, Gorimedu,  
Puducherry - 605 006, India.  
E-mail: drsandip19@gmail.  
com

Submitted: 10- May-2020

Revised: 17-Dec-2020

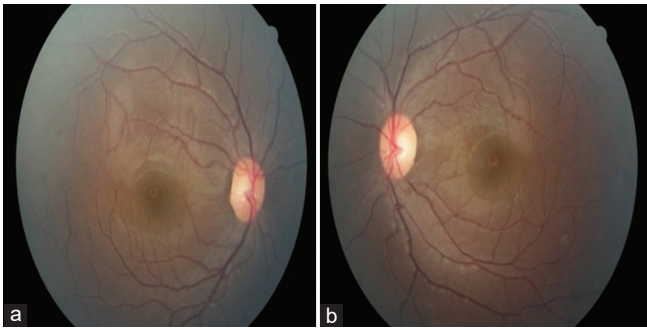
Accepted: 17-Dec-2020

Published: 13-Jun-2022

This is an open access journal, and articles are distributed under the terms of the Creative Commons Attribution-NonCommercial-ShareAlike 4.0 License, which allows others to remix, tweak, and build upon the work non-commercially, as long as appropriate credit is given and the new creations are licensed under the identical terms.

For reprints contact: WKHLRPMedknow\_reprints@wolterskluwer.com

**How to cite this article:** Deb AK, Neena A, Sarkar S, Devraj A, Panicker G, Stephen AM. Bilateral compressive optic neuropathy secondary to sphenoid sinus mucocele mimicking bilateral retrobulbar neuritis. Saudi J Ophthalmol 2021;35:368-70.



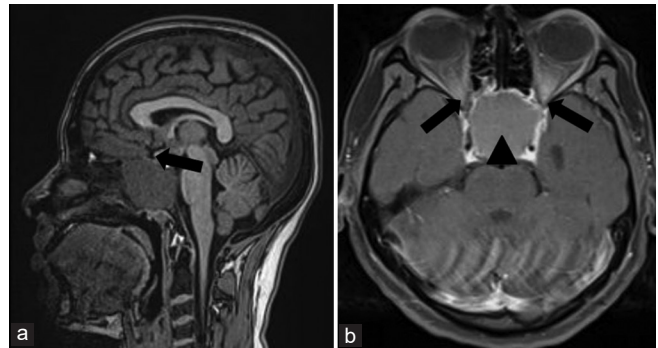
**Figure 1:** (a) Fundus image of right eye showing normal colour disc at presentation, (b) Fundus image of left eye showing normal colour disc at presentation

consultation was obtained from an otorhinolaryngologist. The patient underwent an emergency decompression of the sphenoid sinus through a transsphenoidal approach with marsupialization of the mucocele under general anesthesia. Sphenoid sinus fluid cytology showed features suggestive of a benign cyst. On postoperative day 1, BCVA improved to 20/32 in RE and 20/500 in LE. The patient was started on oral steroids following the decompression procedure. Steroids were tapered over the next 2 weeks and stopped. At 3 months, BCVA was 20/20 in RE and 20/400 in LE. Fundus examination of RE showed normal disc color while LE showed mild temporal disc pallor.

## DISCUSSION

SSM is quite rare. Although rare, they often pose a serious threat due to misdiagnosis and proximity to vital structures of the brain, orbit, cavernous sinus, carotid arteries, pituitary gland, and the optic nerve.<sup>[5,6]</sup> They have varied clinical features including headache, orbital pain, visual disturbance, visual field defect, cranial nerve palsies secondary to cavernous sinus involvement, endocrine abnormalities, proptosis, etc.,. Most of the visual symptoms are unilateral.<sup>[2,3]</sup> Our case was unique in terms of sudden onset bilateral visual impairment which is rare in the case of a SSM. Optic nerve involvement in paranasal sinus mucoceles can be due to optic neuritis (direct inflammation spread to the optic nerve sheath) or due to compressive optic neuropathy. Compressive optic neuropathy in an SSM can again be due to direct compression of the enlarging mucocele on the optic canal or due to disruption or compromise of the blood supply to the optic nerve.<sup>[2,5]</sup> In our case, the visual loss was secondary to bilateral compressive optic neuropathy. Compressive optic neuropathy classically presents with gradual progressive visual loss.<sup>[1,5]</sup> However, our patient had sudden onset bilateral diminution of vision. Literature review on SSM has shown that compressive optic neuropathy secondary to SSM can rarely present with acute vision loss-unilateral or bilateral as seen in our case.<sup>[2-4,6-9]</sup>

The patient was initially treated as retrobulbar neuritis based on features such as acute visual loss, preceding history of fever, retrobulbar pain; sluggish pupillary reactions, and



**Figure 2:** T1 sagittal (a) and axial (b) magnetic resonance imaging images of brain, spine and orbit showing mucocele of sphenoid sinus (arrowhead) compressing bilateral optic nerves in the optic canals (arrows)

normal fundus. However, bilateral presentation and no apparent clinical response to intravenous steroids suggested the possibility of atypical optic neuritis or an alternative diagnosis. Normal MRI study of the brain and spine and normal CSF studies ruled out demyelinating aetiologies such as multiple sclerosis, neuromyelitis optica, etc.,. However, MRI images of PNS and orbit confirmed the diagnosis of a SSM. Findings of this case, therefore, highlight the importance of maintaining a high index of clinical suspicion for compressive lesions in all cases of optic neuritis with atypical features. Early imaging and early intervention can prevent irreversible vision loss in such cases. Optic neuropathy secondary to compressive lesions seldom recovers if intervention is delayed by more than 7–10 days.<sup>[7]</sup> Treatment of a large compressing mucocele involves decompression and marsupialization or surgical removal of the mucocele. Prompt surgical decompression can ensure complete recovery of vision as seen in the RE of our patient.<sup>[7,8]</sup> However, other factors such as preoperative visual acuity (VA), duration of compression, and degree of compression on the optic nerve also determine the final visual prognosis. This may explain poor visual recovery in the LE due to poorer preoperative VA and longer duration of compression compared to the RE.

Systemic steroids in a mucocele may be beneficial in reducing any associated tissue edema in the optic canal. Steroids can also treat any associated optic neuritis. However, they can flare up any underlying occult infection. Steroids should, therefore, be withheld in any case of suspected infective etiologies.<sup>[9]</sup> In our case, intravenous steroids were initially administered for 3 days before the surgical intervention. This was followed by a course of oral steroids in tapering doses. Although steroids did not cause any clinical improvement in vision initially, the course of steroids would have probably prevented any further worsening of vision by reducing edema in the optic canal secondary to compression. However, it is prudent to always perform imaging first in all cases of suspected optic neuritis and rule out any compressive lesion before starting systemic steroids.

In conclusion, compressive optic neuropathy secondary to SSM can occur, albeit, rare. Prompt diagnosis by imaging and timely intervention can prevent irreversible vision

loss. Neuroimaging should, therefore, be routinely advised in retrobulbar neuritis with an atypical presentation to rule out compressive optic neuropathy. Furthermore, a multidisciplinary approach involving the ophthalmologist, otolaryngologist, and radiologist is needed in such a scenario to ensure prompt intervention and appropriate management.<sup>[2,5,7]</sup>

### **Declaration of patient consent**

The authors certify that they have obtained all appropriate patient consent forms. In the form the patient (s) has/have given his/her/their consent for his/her/their images and other clinical information to be reported in the journal. The patients understand that their names and initials will not be published and due efforts will be made to conceal their identity, but anonymity cannot be guaranteed.

### **Financial support and sponsorship**

Nil.

### **Conflicts of interest**

There are no conflicts of interest.

## **REFERENCES**

1. Razavi ME, Khalifeh M, Astaneh MR, Mazuchi M. Sphenoid sinus mucocele: report of a unique presentation and partial improvement of vision from no light perception to counting fingers after treatment. *Iran J Ophthalmol* 2010;22:77-80.
2. Bhattacharjee H, Soibam R, Deori N. Sphenoethmoidal mucocele presenting with unilateral visual loss. *Eye Brain* 2010;2:117-20.
3. Selvakumar A, Mahalaxmi B, Ananth V, Gautam C. Sphenoidal mucocele causing bilateral optic neuropathy and ophthalmoplegia. *Indian J Ophthalmol* 2014;62:515-7.
4. Levy J, Monos T, Puterman M. Bilateral consecutive blindness due to sphenoid sinus mucocele with unilateral partial recovery. *Can J Ophthalmol* 2005;40:506-8.
5. Kaveh AA, Mahya GA, Amin Z, Mostafa SS. Sphenoid sinus mucocele masquerading as retrobulbar optic neuritis: A case report. *Rom J Ophthalmol* 2018;62:312-6.
6. Nugent GR, Sprinkle P, Bloor BM. Sphenoid sinus mucoceles. *J Neurosurg* 1970;32:443-51.
7. Gupta AK, Menon V, Sharma P, Saxena R, Kumaran S. A sphenoid sinus mucocele simulating as retro bulbar optic neuritis. *Indian J Ophthalmol* 2012;60:216-8.
8. Sharifi G, Jalessi M, Erfanian D, Farhadi M. Sudden blindness due to isolated sphenoid sinus mucocele and retention cyst. *Braz J Otorhinolaryngol* 2013;79:120.
9. Mowatt L, Foster T. Sphenoidal sinus mucocele presenting with acute visual loss in a scuba diver. *BMJ Case Rep* 2013;2013:bcr2013010309.