

Hyperbaric oxygen treatment in three cases of necrotizing infection of the neck

Torbjørn Nedrebø,^{1,2} Trond Bruun,^{3,4}
Rune Skjåstad,⁵ Gunhild Holmaas,⁶
Steinar Skrede^{3,4}

¹Hyperbaric Medical Unit, Dept of Occupational Medicine, Haukeland University Hospital; ²Department of Biomedicine, University of Bergen; ³Department of Medicine, Haukeland University Hospital; ⁴Institute of Medicine, University of Bergen; ⁵Department of Microbiology, Haukeland University Hospital; ⁶Department of Anaesthesia and Intensive Care, Haukeland University Hospital, Norway

Abstract

Necrotizing infections of the head and neck are rare conditions in our hospital. Clinical and microbiological characteristics of three consecutive cases treated in Haukeland University Hospital in western Norway in the year 2010 are described. Two cases of Lemierre's syndrome and one case with a descending necrotizing mediastinitis (DNM) were diagnosed. All three cases were treated with broad spectrum antibiotics and in two cases surgery was possible. Hyperbaric oxygen treatment (HBOT) with intensive care facilities became recently available at our hospital, and this treatment was used in all these patients regardless of surgery. In one case we describe the use of HBOT on the basis of strong clinical suspicion of anaerobic infection only. Bacterial identification by partial sequencing of the 16SrDNA gene proved to be a useful supplement to conventional culture techniques. All the cases all demonstrated a significant clinical improvement after introduction of HBOT. When HBOT is available, it should be considered as adjunctive treatment in extensive infections with anaerobes.

Introduction

Severe skin and soft tissue infections of the head and neck are rare conditions that may emerge secondarily to oropharyngeal infections. Anaerobic bacteria are often involved and may contribute to extensive inflammation, necrosis, and abscess formation. Secondary focal complications as bacterial invasion of vasculature, venous or arterial septic embolisation to the brain, spine or thorax may appear. Descending

spread to the mediastinum may also occur.

Differences in bacterial aetiology and pathogenesis give rise to different syndromes. Lemierre's syndrome (LS) is a manifestation with anaerobic aetiology and septic thrombophlebitis of the internal jugular vein.¹ Cervicocranial necrotizing fasciitis (CNF) is a more superficial infection,^{2,4} and descending necrotizing mediastinitis (DNM) is a deep manifestation of this group of diseases.⁵ The diagnostic and therapeutic approach to the patients is multidisciplinary. Broad-spectrum antibiotics are the basis of treatment, and early surgery is often necessary, especially in NF and DNM. The role of adjuvant treatment with hyperbaric oxygen (HBOT) in these conditions is controversial. Especially for infections with anaerobic microbes, other than in NF, reliable data for the effect of HBOT are scarce.⁶⁻⁹ Knowledge of the possible benefit of adjuvant treatment is important for this group of patients. Here we present three cases with definite or probable involvement of anaerobic bacteria, where HBO was used with a favourable outcome.

Case Report #1

A 67-year-old man in previously good condition, experienced a sore throat and dysphagia for 5 days. On admission to hospital he appeared acutely ill. Temperature was 38,1°C, heart rate (HR) 125/min, blood pressure (BP) 110/59 mm Hg, respiratory rate (RR) 30/min, and SaO₂ 87% with 12 l O₂/min supplement via a non-rebreather mask. On clinical examination the neck was asymmetric with an enlarged mass on the left side, and crepitus was felt by palpation. Laboratory studies revealed a white blood cell count of 34.1×10⁹/L with 98% neutrophils. Other laboratory data are given in Figure 1. A CT-scan demonstrated soft tissue swelling, subcutaneous gas (Figure 2), and a muscle abscess in the neck. Antibiotic treatment was initiated, and he had to undergo immediate surgery with drainage of the abscess. Mixed anaerobic microbes were identified (Table 1). Due to the foci of infection, gas-production in the tissue and positive cultures for anaerobic bacteria, it was decided to start with hyperbaric oxygen treatment (HBOT) for 90 min sequences at 3 atmosphere absolute (ATA). HBOT at 3 ATA was chosen based on the recommendation for treatment of clostridial myonecrosis from *Undersea and Hyperbaric Medical Society* (UHMS).¹⁰ A total of 5 HBOT were performed in the next 2.5 days, the first starting a few hours after the initial surgery. Already after 3 HBOTs the surgeon reported a halt of the ongoing necrotizing infection in the area. After 5 HBOTs the patients condition was reported to be under control and stabilized, and HBOT was discontinued. During HBO-treatment the Sequential Organ Failure Assessment (SOFA) score decreased from 12 to

Correspondence: Torbjørn Nedrebø, Hyperbaric Medical Unit, Haukeland University Hospital, 5021 Bergen, Norway.
Tel. + 47.55.97.39.75.
E-mail: neto@helse-bergen.no

Key words: hyperbaric, necrotizing, anaerobic, Lemierre.

Contributions: TN, writing the manuscript, contact with the patients, CT and MRI figures; TB, focus on the three patients treatment; RS, discussion of microbiology and Table 1; GH, all figures of SOFA scores and laboratory investigation; SS, writing the manuscript.

Received for publication: 19 October 2011.

Revision received: 29 December 2011.

Accepted for publication: 8 January 2012.

This work is licensed under a Creative Commons Attribution NonCommercial 3.0 License (CC BY-NC 3.0).

©Copyright T. Nedrebø et al., 2012
Licensee PAGEPress srl, Italy
Infectious Disease Reports 2012; 4:e21
doi:10.4081/idr.2012.e21

5, and vasopressor was ceased (Figure 1). Although the condition improved, another CT-scan of the neck and chest demonstrated thrombosis of the left jugular vein and an additional abscess in the upper mediastinum. Treatment with low molecular weight heparin (LMHW) was introduced. The abscess was removed by thoracoscopy and mediastinotomy. Eight teeth were extracted upon discovery of infection. After 27 days in the ICU, the patient was transferred to the medical ward, where he stayed another 36 days before he was discharged from hospital to home. He is suffering of a minor sequela in his upper right extremity.

Case Report #2

A healthy 53 year old man with psoriatic disease experienced 6 days of sore throat. Due to sudden onset of chest pain a coronary event was suspected. On admittance to hospital he was in reduced general state with a temperature of 37, 3°C, HR 90/min, RR 26/min, and hypoxia was noted (PaO₂ 8 kPa). The patient had redness in pharynx, but no obvious clinical tonsillitis. A CT-scan of neck and chest showed inflammation of the upper and lower mediastinum, involving the pericardium, and gas was seen in deep tissue layers. He was diagnosed with tonsillitis and mediastinitis (Figure 3).

After start of antibiotics, surgical treatment with sternotomy and mediastinotomy was done. Fat tissue in the mediastinum was found

infected and/or necrotic. Mixed anaerobic bacteria were identified (Table 1). It was decided to treat the surgical wound with vacuum assisted closure (VAC), and initially not by HBOT. However, over the next 5 days his condition did not improve, a CT-scan demonstrated bilateral empyema, significant inflammation in soft tissue of the neck and mediastinum, and gas surrounding the heart. Due to the foci of infection, gas-production in the tissue and identification of anaerobic pathogens, HBOT then was started. He underwent a total of 5 HBO-treatments the next 3 days, as described in case 1. Upon HBOT, the patient improved, vasopressors were ceased, and CRP decreased from 285 to 116 mg/L (Figure 4). Four days after the last HBO-treatment his sternum was closed. After a total of 21 days in ICU he was discharged to the ear-nose-and throat ward (ENT). He stayed another 25 days in hospital before he could go home. He is not suffering from any sequela.

Case Report #3

A previously healthy woman, age 22, had a history of 6 days with progressive dysphagia. She was admitted to the local hospital due to increasing systemic signs of infection, accompanied by tenderness of the neck and chest pain. A CT-thorax demonstrated an abscess of the upper mediastinum. She received treatment with antibiotics for one day, before she was transferred to the regional hospital. She then had a temperature of 38.3°C and HR 100/min. At clinical examination, distinct tenderness on the left side of the neck was found, as well as discrete oedema. Crepitus in left supraclavicular space was suspected. On inspection of the oropharynx, slight elevation of the left side of the lateral pharyngeal wall was seen. Laboratory results are given in Figure 5. A new CT-scan and an MRI confirmed the findings of inflammatory

changes in the neck as well as an mediastinal abscess, together with thromboses of the left jugular and subclavian veins. The abscess was not suited for surgical drainage due to difficult access; small volume and density measured by CT. Blood cultures and other bacteriological investigations were negative. She was treated with antibiotics and LMHW in the infectious diseases ward. In an attempt to reduce further progression of inflammation and pus formation, HBOT was started (3 ATA, 90 min) whereby the patient's condition improved shortly after this treatment was introduced (Figure 5). Three days after discontinuation of HBOT she was transferred to her local hospital for further conservative measures. After two weeks she was discharged from the local hospital, where treatment was continued with antibiotics for another 2 weeks and anticoagulation for 3 months. She is now back at school, suffering no sequela.

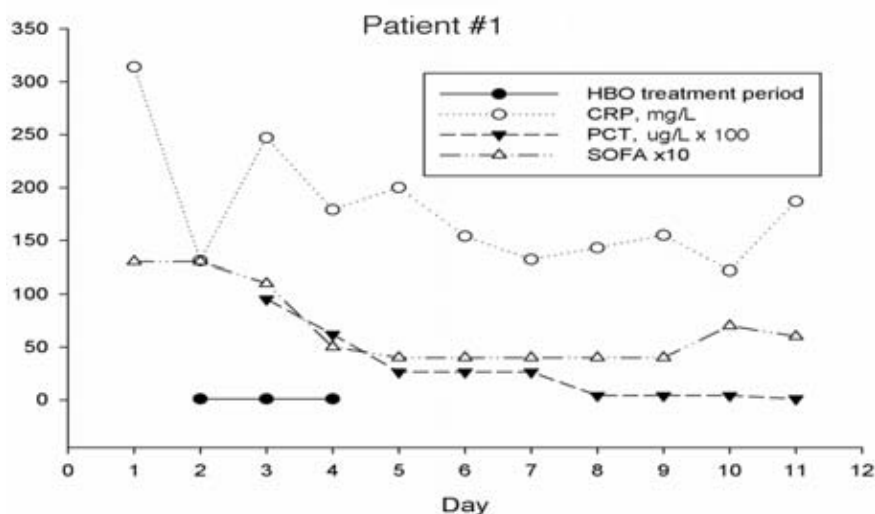


Figure 1. Patient #1. Changes in C-reactive protein (○, mg/L), procalcitonin (▼, ug/L * 100) and Sequential Organ Failure Assessment -score *10 (△) during the first twelve days in hospital. The hyperbaric oxygen treatment period is marked ●. CRP, C-reactive protein; PCT, procalcitonin; SOFA, Sequential Organ Failure Assessment; HBO, hyperbaric oxygen.

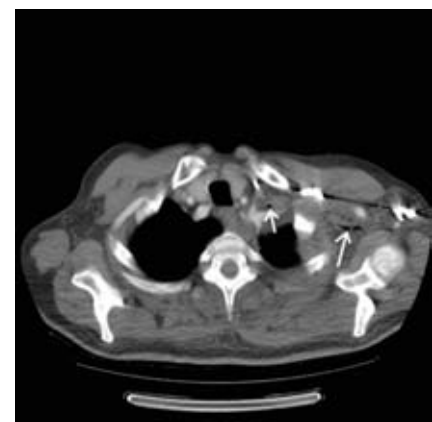


Figure 2. Computed tomography scan of thorax, showing loculations of air in the tissue of the mediastinum (white arrows) in patient #1.

Table 1. Clinical data of patient #1 and #2.

	Localization	Detection method	Microbe
Patient #1	Blood culture	Culture/V3-V4 sequencing	Campylobacter species (rectus/showae)
	Anaerobic blood culture	Microscopy	Gram positive coccus
	Neck	Culture	Peptostreptococcus anaerobius, Propionibacterium acnes
	Mediastinum	V1-V3, group specific primers*	Parvimonas spp., treponema denticola, Prevotella dentalis, Prevotella bivia
	Mediastinum	V3 V4 sequencing*	Porphyromonas gingivalis, Bacterioides species (parabacterioides goldsteinii)
Patient #2	Tonsils	Microscopy Culture	Fusiform gram negative rods Haemophilus parainfluenzae, Streptococcus viridans Aggregatibacter aphrophilus, group B streptococcus, Streptococcus milleri, Prevotella species
	Mediastinum, tonsils	Culture	
	Mediastinum	Culture	Peptostreptococcus species

*Used RipSeq software

Discussion

In each of these three cases we diagnosed the patient with an extensive soft-tissue infection of the neck and mediastinum. Patient #1 and #3 met the criteria for Lemierre's syndrome, and patient #2 had findings consistent with DNM. In patient #1 and #2 several bacteria were identified with an oropharyngeal origin. Both anaerobic and aerobic bacteria were probably involved in the disease of these two patients. Anaerobic involvement was probable also the case in patient #3, as crepitations in the skin were found under clinical examination. The contribution of HBOT to the recovery of each patient will be discussed in the following.

Descending necrotizing infections of the head and neck are rare and the case fatality rate is high. Severe infections of the head and neck often start with symptoms from the source of infection. In Lemierre's syndrome sore throat and neck pain may be early symptoms, followed by signs of a neck mass.¹¹ The origin is often a pharyngotonsillitis or a peritonsillar abscess. In CNF, dysphagia and a sore throat are also common. A dental infection is often the primary source of infection. In DNM, pharyngeal infection is most often the primary source.⁹ In our three cases, all presented with a history of sore throat and dysphagia. Chest pain, pain when swallowing and swelling of the neck were reported. The two patients with Lemierre's syndrome both had oropharyngeal infections with downward spread of infection to the mediastinum. In Lemierre's syndrome the spread is usually metastatic from the thrombophlebitis of the affected vein. The patient with DNM had tonsillitis and an early spread to the mediastinum. In DNM the spread is probably facilitated by gravity, breathing and negative intrathoracic pressure.¹² The systemic effects predominate when the mediastinum becomes more involved; capillary leak, possible respiratory distress syndrome (ARDS) and empyema.

Microbiology

The necrotizing infections described herein are typically polymicrobial, and anaerobic microbes normally harboured in the oral cavity are usually involved. The pathogens identified in these patients are considered apathogenic or of low virulence. Still, all or some have caused progressive infection, even during antimicrobial therapy. All the tested bacteria were sensitive to penicillin G and are considered sensitive to the initial empiric therapy. However, the sub-optimal effect of antibiotics observed was most likely caused by local factors as impaired perfusion, oxygen depletion, impaired immunofunction or bacterial community mediated antibiotic tolerance mechanisms.¹³

The detection of microbes in a polymicrobial setting is difficult. Strictly anaerobic microbes

are easily killed during specimen transport and handling if anaerobic conditions are not maintained. *Fusobacterium spp.*, often considered the main bacteria causing Lemierre's syndrome,¹¹ are extremely sensitive to O₂ and can be missed by traditional culture methods. Some microbes require enriched media, special environmental conditions and prolonged incubation for growth. These microbes are therefore mostly not detected by conventional culture techniques. The usefulness of alternative techniques is illustrated in case 1, where 16SrDNA detection identified in total 6 species that were not identified by conventional culture. 16SrDNA sequencing in mixed infections gives mixed chromatograms where overlying sequences make it difficult to identify which nucleic acid belong to which microbe. This was overcome by using the newly developed software RipSeq that identified 2 microbes (*Porphyromonas gingivalis* and *Bacteroides spp.*).¹⁴ The 16SrDNA sequencing, in this study targeted either or both of the variable gene regions V1-V3 and V3-V4. Using group specific primers and RipSeq we were able to identify an additional 4 microbes. Such detection methods based on genus/species specific nucleic acids are particularly useful in infections caused by fastidious and oxygen sensitive bacteria. Earlier only infections caused by a single bacterial species could be detected by 16 rDNA sequencing, but by using group specific primers and Rip Seq software this can be accomplished also for polymicrobial infections, even after antimicrobial therapy is started, as illustrated in this case report. Susceptibility testing is however, not

possible when molecular methods are used.

Treatment of our patients

All three patients received early and targeted antimicrobial treatment. Surgical therapy was needed in two of the cases. Patient #1 and #2 were treated in a multiplace-chamber due their need of intensive care and respirator (Haux-Quadro 2500-2200). In patient #1, an improvement in the clinical condition was objectively observed after three HBOTs. He received two additional treatments, and his clinical condition further improved, objectively observed by marked reduction of the SOFA-score (Figure 1).

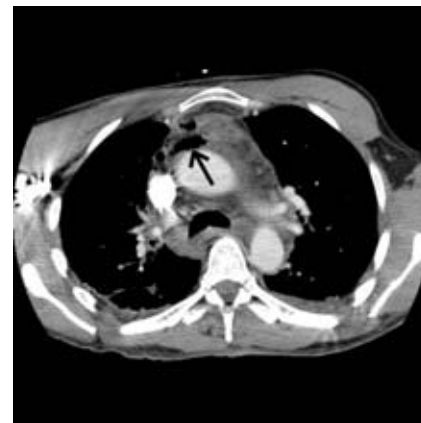


Figure 3. Computed tomography scan of thorax, showing loculations of air in the tissue of the mediastinum (black arrow) in patient #2.

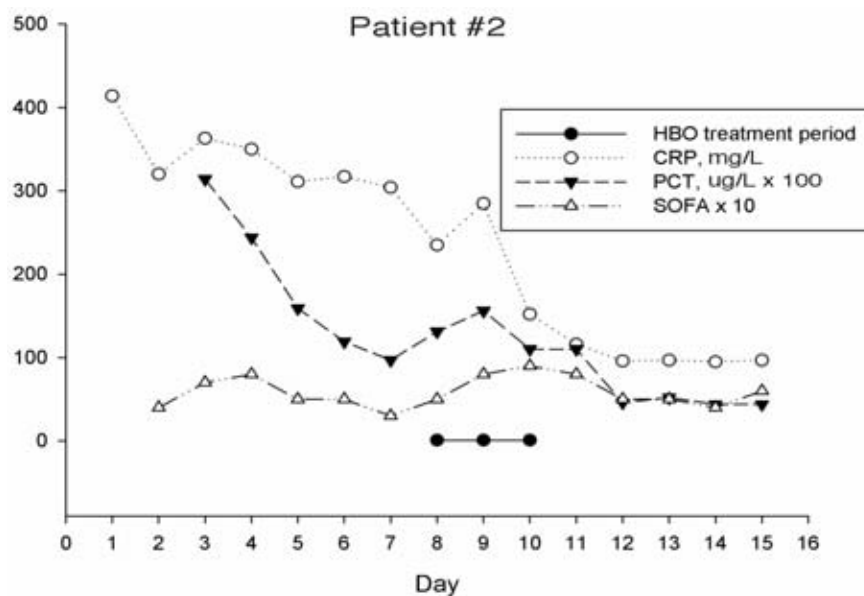


Figure 4. Patient #2. Changes in C-reactive protein (○, mg/L), procalcitonin (▼, ug/L * 100) and Sequential Organ Failure Assessment -score *10 (Δ) during the first 16 days in hospital. The hyperbaric oxygen treatment period is marked ●. HBO, hyperbaric oxygen; CRP, C-reactive protein; PCT, procalcitonin; SOFA, Sequential Organ Failure Assessment.

However, his condition worsened a few days later, and an abscess in the mediastinum was found and removed by drainage. One might argue a need for additional HBOT in this patient, but this was not done. Studies on NF advocate a treatment protocol of at least ten sessions.¹⁵ Patient #2 was early suspected with an anaerobic infection. HBOT was considered at first, but not started as *Clostridium* spp. was not detected during the first surgery. However, his clinical condition worsened and it was not until the start of HBOT at day 5 one was able to get control over his infection and his condition stabilized. Patient #3 did not have an infection suitable for surgery. Instead we started aggressive treatment with antibiotics and HBOT. This patient was treated in a monoplace-chamber (Baramed Hyperbaric Chambers, ETC).

The use of HBOT in conjunction with surgical debridement, antibiotic therapy and maximal critical-care therapy for severe soft tissue infections is widely accepted, but the efficacy of HBO remains unproven.¹⁶ In soft tissue infections, an area of hypoxia develops. The hypoxia impairs phagocytosis, and the drop in pH creates a milieu for growth of anaerobic organisms. The local hypoxia again causes tissue necrosis that may contribute gas production. Gas is frequently seen in crepitant necrotizing infections, as described in our three cases. HBOT provides oxygenation to otherwise ischemic areas, and reduces the impact of hypoxia on leukocyte function.^{13,15,17} The oxygenation of tissue thereby limits the spread and progression of infection. HBOT of infections also occurs via HBO acting as a bactericide or as a bacteriostatic agent to some microorganisms, and through an additive and/or synergistic effect on some antimicrobial drugs.¹⁵ In patient #1 the surgeon reported *vital tissue only* in the affected area, shortly after start of HBOT which may illustrate its therapeutic potential. In all the cases, a clinical improvement was seen after the start of HBOT, but the specific role of HBOT in this improvement is difficult to estimate.

Conclusions

The incidence of cervical necrotizing infections is low also in our hospital. Data on HBOT of such infections are scarce and not conclusive, but somewhat in support of this. Recent availability of HBOT with intensive care facilities at our hospital has led to three HBO treated cases all demonstrating a significant clinical improvement. We also show that HBOT may be used on the basis of only strong clinical suspicion of anaerobic infection. The cases demonstrate that use of *polymerase chain reaction* is especially useful in the diagnostics of anaerobic infections. When HBOT is available, it should be considered as adjunctive treatment in extensive

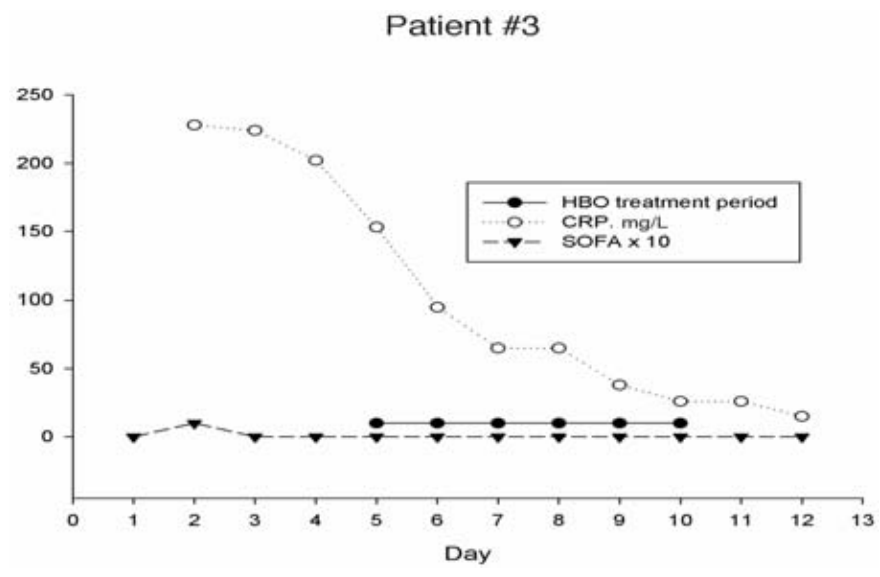


Figure 5. Patient #3. Changes in C-reactive protein (○, mg/L) and Sequential Organ Failure Assessment -score *10 (△) during the first 13 days in hospital. The hyperbaric oxygen treatment period is marked ●. HBO, hyperbaric oxygen; CRP, C-reactive protein; SOFA, Sequential Organ Failure Assessment.

infections with anaerobes, but more studies are needed to evaluate the effect.

References

- Karkos PD, Asrani S, Karkos CD, et al. Lemierre's syndrome: a systematic review. *Laryngoscope* 2009;119:1552-9.
- Mao JC, Carron MA, Fountain KR, et al. Craniocervical necrotizing fasciitis with and without thoracic extension: management strategies and outcome. *Am J Otolaryngol* 2009;30:17-23.
- Wolf H, Rusan M, Lambertsen K, Ovesen T. Necrotizing fasciitis of the head and neck. *Head Neck* 2010; 32:1592-6.
- Lanisnik B, Cizmarevic B. Necrotizing fasciitis of the head and neck: 34 cases of a single institution experience. *Eur Arch Otorhinolaryngol* 2010;267:415-21.
- Hassan Z, Mullins RF, Friedman BC, et al. Treating necrotizing fasciitis with or without hyperbaric oxygen therapy. *Undersea Hyperb Med* 2010;37:115-23.
- Hodgson R, Emig M, Pisarello J. Hyperbaric oxygen (HBO2) in the treatment of Lemierre syndrome. *Undersea Hyperb Med* 2003;30:87-91.
- Flanagan CE, Daramola OO, Maisel RH, et al. Surgical debridement and adjunctive hyperbaric oxygen in cervical necrotizing fasciitis. *Otolaryngol Head Neck Surg* 2009;140:730-4.
- Jallali N, Withey S, Butler PE. Hyperbaric oxygen as adjuvant therapy in the management of necrotizing fasciitis. *Am J Surg* 2005;189:462-6.
- Ridder GJ, Maier W, Kinzer S, et al. Descending necrotizing mediastinitis: contemporary trends in etiology, diagnosis, management, and outcome. *Ann Surg* 2010;251:528-34.
- Undersea and Hyperbaric Medical Society. Hyperbaric oxygen therapy indications. 12 ed. 2008. Available from: <http://membership.uhms.org/?page=indications>
- Chirinos JA, Lichtstein DM, Garcia J, Tamariz LJ. The evolution of Lemierre syndrome: report of 2 cases and review of the literature. *Medicine (Baltimore)* 2002;81:458-65.
- Weaver E, Nguyen X, Brooks MA. Descending necrotizing mediastinitis: two case reports and review of the literature. *Eur Respir Rev* 2010;19:141-9.
- Park MK, Myers RA, Marzella L. Oxygen tensions and infections: modulation of microbial growth, activity of antimicrobial agents, and immunologic responses. *Clin Infect Dis* 1992;14:720-40.
- Kommedal O, Lekang K, Langeland N, Wiker HG. Characterization of polybacterial clinical samples using a set of group-specific broad-range primers targeting the 16S rRNA gene followed by DNA sequencing and RipSeq analysis. *J Med Microbiol* 2011;60:927-36.
- Cimsit M, Uzun G, Yildiz S. Hyperbaric oxygen therapy as an anti-infective agent. *Expert Rev Anti Infect Ther* 2009;7:1015-26.
- Brook I. Management of anaerobic infection. *Expert Rev Anti Infect Ther* 2004;2:153-8.
- Mandell GL. Bactericidal activity of aerobic and anaerobic polymorphonuclear neutrophils. *Infect Immun* 1974;9:337-41.