

Endoscopic and Surgical Treatment of Benign Tracheal Stenosis: A Multidisciplinary Team Approach

Cengiz Özdemir, MD,¹ Celalettin I. Kocatürk, MD,² Sinem Nedime Sökücü, MD,¹
Bugra Celal Sezen, MD,² Ali Cevat Kutluk, MD,² Salih Bilen, MD,² and Levent Dalar MD³

Purpose: Surgical resection and reconstruction are considered the most appropriate approaches to treat post-intubation tracheal stenosis (PITS). Bronchoscopic methods can be utilized as palliative therapy in patients who are ineligible for surgical treatment or who develop post-surgical re-stenosis. We investigated treatment outcomes in patients with benign tracheal stenosis.

Methods: A retrospective review was performed in patients who were diagnosed with PITS. Tracheal resection was performed for operable cases, whereas endoscopic interventions were preferred for inoperable cases with a complex or simple stenosis.

Results: In total, 42 patients (23 treated by bronchoscopic methods, 19 treated by surgery) took part in this study. No significant differences were observed in segment length, the proportion of obstructed airways, or vocal cord distance between the two groups. In all, 15 patients in the bronchoscopic treatment group received a stent. Following the intervention, the cure rates in the bronchoscopic and surgical treatment groups were 43.47% and 94.7%, respectively. A multidisciplinary approach resulted in a cure or satisfactory outcome in 90.5% of the patients while failure was noted in 9.5% of the patients.

Conclusion: Bronchoscopic methods are associated with a lower cure rate compared to surgery. A multidisciplinary approach was helpful for treatment planning in patients with PITS.

Keywords: post-intubation tracheal stenosis, bronchoscopy, tracheal resection

¹Department of Pulmonology, Yedikule Chest Diseases and Surgery Training and Research Hospital, Istanbul, Turkey

²Department of Chest Surgery, Yedikule Chest Diseases and Surgery Training and Research Hospital, Istanbul, Turkey

³Department of Pulmonology, Istanbul Bilim University, Istanbul, Turkey

Received: March 20, 2018; Accepted: May 6, 2018

Corresponding author: Cengiz Özdemir, MD. Department of Pulmonology, Chest Disease and Thoracic Surgery Training and Research Hospital, Istanbul, Turkey

Email: cengizoz78@yahoo.com

©2018 The Editorial Committee of *Annals of Thoracic and Cardiovascular Surgery*. This work is licensed under a Creative Commons Attribution-NonCommercial-NonDerivatives International License.

Introduction

Acquired benign tracheal stenosis most frequently arises from endotracheal intubation or tracheal stenosis in association with a tracheotomy.¹⁾ The frequency of intubation-related tracheal stenosis (post-intubation tracheal stenosis [PITS]) varies from 0.6% to 21%.^{2,3)} Surgical resection and reconstruction are considered the most appropriate approaches to treat PITS.³⁾ However, previous studies reporting the outcomes of surgical resection did not provide data on how inoperable PITS cases were addressed.⁴⁾ Surgical treatment is not the preferred treatment option for all patients due to the characteristics of

the stenosis and patient comorbidities. Bronchoscopic methods can be utilized as palliative therapy in patients who are ineligible for surgical treatment or who develop post-surgical re-stenosis. Bronchoscopic methods include dilatation, laser-assisted dilatation, cryotherapy, and placement of a stent, which may be applied alone or in combination.^{1,4-7} One study reported that bronchoscopic interventions were curative in patients with a simple stenosis, in some patients with a more complex stenosis, and in relatively severe patients, who were inoperable and had a higher number of comorbidities, treated with bronchoscopic interventions.⁸⁾

No optimal treatment algorithm has been agreed upon for intubation-related tracheal stenosis. The majority of the algorithms are based on treatment approaches in turn based on the capabilities and experience of individual centers. In the present study, we investigated the preferred treatment methods and associated outcomes in consecutive cases of benign tracheal stenosis, which were evaluated by a multidisciplinary team comprising experienced interventional pulmonologists and chest surgeons in a tertiary hospital.

Materials and Methods

A retrospective review was performed on consecutive cases diagnosed with PITS at the interventional pulmonology unit of our hospital during January 2013–June 2017. Ethical committee approval was obtained (118-09/11/2017). Data, including demographic characteristics, concomitant diseases, cause and duration of intubation, time until the first assessment, characteristics of the stenosis site, treatment methods applied, complications, and success rate, were collected from the medical charts of the patients. All patients were informed about the study and provided informed consent before any intervention was initiated. Computed tomography of the thorax was applied as a non-invasive imaging method before the intervention and during post-procedural follow-up for the non-emergent cases. Flexible bronchoscopy (FB) and rigid bronchoscopy (RB) examinations were performed by a team that consisted of two interventional pulmonologists and a chest surgeon, who arrived at a consensus decision regarding the treatment approach.

Bronchoscopic procedures

The RB (Efer Endoscopy, La Ciotat, France) was performed in all patients under intravenous general anesthesia, and the procedure was carried out in an operating

room. Localization, length, type, and degree of stenosis were recorded. The degree of stenosis was determined based on the 4-grade classification system of Cotton-Myer. Dilatation was performed by passing the RB through stenotic areas of increasing diameter. Mucosa at the stenotic region was sectioned at the levels of 11 and 1 o'clock using a diode laser (4–25 W pulse mode and 980 nm wavelength [Biolitec Ceralas D25; Biolitec, Jena, Germany]). Cryotherapy (Elektromedizin GmbH, Tübingen, Germany) was performed using rigid or flexible probes. Silicon stents (Novatech, La Ciotat, France and Enbio, Istanbul, Turkey) and self-expandable covered metallic stents (Micro-Tech, Nanjing, China) were used in patients who required a stent. All stents were placed after RB had dilated the airways. Stents were placed according to techniques described previously.^{8,9)}

Treatment algorithm

The characteristics of the stenosis were assessed during the bronchoscopic examination; the presence of stenosis segments >1 cm, accompanied by cartilage involvement, malaise, and inflammation, were considered as “complex stenosis,” whereas the presence of stenosis segments <1 cm, with involvement limited to the mucosa and absence of malaise and cartilage loss, were considered “simple stenosis.”

Following the diagnosis and evaluation, the appropriate treatment approach was selected from among four main options.

- Simple stenosis was initially treated by bronchoscopic dilatation.
- Surgical resection was the first-choice treatment for a complex stenosis (i.e., patients with a good overall health status, a stenosis segment >1 cm, no have severe malaise, and who consented to surgical treatment).
- Patients who did not have a complex stenosis and were not eligible for surgery were treated by bronchoscopy (i.e., inoperable patients due to poor overall health status and comorbidities, patients with serious malaise and segment length <1 cm, or patients who did not provide consent for surgery). A stent was placed after dilatation in such patients.
- Patients with a complex stenosis and segment lengths of 1–2 cm, who did not have accompanying malaise, and in whom full airway opening was achieved after dilatation and who were followed-up without a stent.

Among the patients treated with bronchoscopic interventions, those who underwent dilatation alone were

followed-up by symptom control and FB, if needed, during the first post-procedural month and at 3-month interval thereafter. In cases of recurrent stenosis, dilatation by RB was repeated three times. Patients who had a complex stenosis and received a stent were monitored by FB 24–48 hours after the procedure. Thereafter, they were monitored by symptom control and FB, if required, on postoperative months 1, 3, 6, 12, and 18. Interventions were performed using FB or RB if a stent-associated complication developed. A new stent was placed in patients whose stent was removed during the follow-up period and who developed a re-stenosis.

Surgical procedure

Following induction in the operating room, a surgeon using RB and/or FB assessed all patients. The distance from the stenotic region to the vocal cords, the length of the stenotic region, and the distance from the distal part of the stenotic region to the carina were re-evaluated.

The same surgeon performed the whole procedure. Based on the grade of tracheal stenosis, patients underwent a cervical thoracotomy with a collar cut, a partial sternal cut with a collar, or a lateral muscle-preserving thoracotomy. The cricotracheal/tracheal resection technique described by Grillo and Pearson was used.^{10,11)}

Tracheotomy stoma, if any, was excised along with the stenotic segment. The distal airway was ventilated from the surgical side with a number-7 spiral intubation tube (flexometallic tube). Traction sutures (3/0 polypropylene [Ethicon, Somerville, NJ, USA]) were placed on the proximal and distal segments. The anastomosis was freed from tension by performing flexion maneuvers based on the size and location of the tracheal resection. Cervical flexion and anterior cervico-mediastinal mobilization were performed in all cases. Suprahyoid, carinal, hilar, and pericardial flexion maneuvers were also performed in patients for whom the above-described flexion was insufficient. The membranous surface of the trachea was sutured continuously with 3/0 Vicryl (Ethicon). An end-to-end anastomosis was performed on the anterior side with single 3/0 PDS (polydioxanone; Ethicon) sutures. Before the anastomosis was completed, the intubation tube in the surgical area was removed, and the endotracheal intubation tube was progressed into the distal tracheal region. After the anastomosis was completed, air leakage was checked with 20–30 cm H₂O pressure. The anastomosis line was supported by the thyroid isthmus and strap muscles. Jaw sutures were placed to prevent extension of the neck. All patients were followed-up

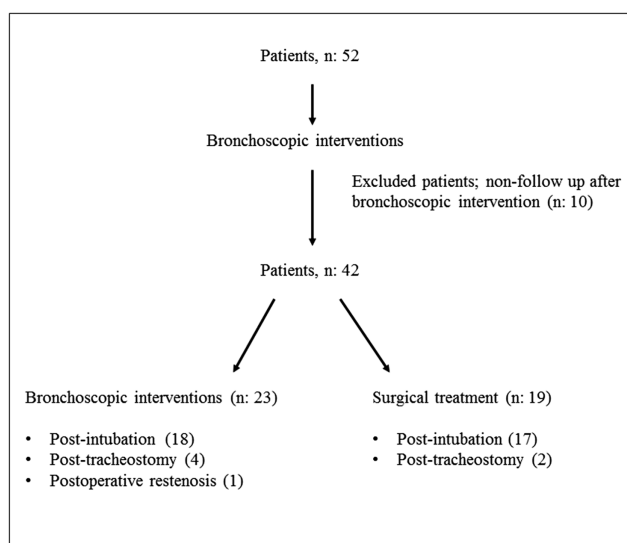


Fig. 1 Follow-up chart of the patients evaluated in the interventional pulmonology unit and causes of tracheal stenosis.

in the intensive care unit during the early postoperative period. The jaw sutures were removed on postoperative day 7. Patients were asked to visit the polyclinics on postoperative months 1, 3, 6, and 12 for a check-up.

Six months after the interventions in both groups, patients who were asymptomatic and did not develop re-stenosis were considered “cured”; patients who had a stent and were followed-up asymptotically were considered “satisfactory”; and patients who were followed-up by permanent tracheotomy or Montgomery-T tube or died due to the procedure were considered “failure.”

Statistical analyses were performed using SPSS software (ver. 22.0; SPSS, Inc., Chicago, IL, USA). Normally distributed continuous variables are expressed as means \pm standard deviation. Non-normally distributed continuous variables are summarized as medians. Categorical variables are expressed as percentages. Comparisons of numerical variables between two independent groups were made using the chi-square, Mann–Whitney *U* test, or independent samples *t*-test, as appropriate. A *p* value <0.05 was considered significant.

Results

In all, 52 patients with PITS presented to the interventional pulmonology unit during the time period covered by this study. A follow-up chart of the patients evaluated and causes of the tracheal stenoses are given in **Fig. 1**.

Of the 42 patients included in the study, 24 were males (57.1%) with a mean age of 50.5 ± 2.99 years

Table 1 Demographic and clinical characteristics of patients

	Total	Bronchoscopic treatment group	Surgical treatment group	p value*
Number of patients (%)	42	23 (54.7)	19 (45.3)	
Age	50.5 ± 2.99 (18–77)	55.86 ± 3.60 (21–77)	43.05 ± 14.86 (18–65)	0.015
Gender, male (%)	24 (57.1)	12 (52.2)	12 (63.2)	0.486
Intubation time (days)	16.33 ± 2.05 (1–50)	16.35 ± 2.76 (1–50)	16.31 ± 11.49 (2–45)	0.902
Presentation time (days)	64.13 ± 11.46 (10–360)	94.95 ± 20.81 (10–365)	55 (IQR: 72.5) (30–1000)	0.789
Comorbidities (%)				
Diabetes mellitus	14 (33.3)	12 (52.2)	2 (10.5)	0.003
Hypertension	15 (35.7)	12 (52.2)	3 (15.8)	0.11
Chronic obstructive pulmonary disease	8 (19)	7 (30.4)	1 (5.3)	0.03
Chronic heart failure	4 (9.5)	4 (17.4)	0	0.043
Ischemic heart disease	9 (21.4)	7 (30.4)	2 (10.5)	0.111
Renal insufficiency	4 (9.5)	4 (17.4)	0	0.043
Cerebrovascular disease	6 (14.3)	4 (17.4)	2 (10.5)	0.538
Steroid use	2 (4.8)	1 (4.3)	1 (5.3)	0.893
Malignancy history	4 (9.5)	4 (17.4)	0	0.043

*p values were compared between both treatment groups. IQR: interquartile range

(range: 18–77 years). The mean duration of intubation was 16.33 ± 2.05 days (range: 1–50 days), and the mean interval between intubation and hospital admission was 64.13 ± 11.46 days (range: 10–360 days). In total, 23 patients (54.7%) were treated with bronchoscopic methods, and 19 (45.3%) with surgery. The group treated by bronchoscopic methods was comprised of older patients with a significantly higher rate of comorbidities (**Table 1**).

The number of FB/RB procedures and dilatations was greater among the patients in the bronchoscopy group. No significant difference was observed regarding the length of the stenosis segment or distance to the vocal cords between the groups. Malaise was present in seven patients in the bronchoscopic group and in one patient in the surgical group ($p < 0.05$) (**Table 2**). Airway obstruction was of grade II or III in 22 patients in the bronchoscopic group, and in all patients in the surgical group. Obstruction involved the subglottic region in eight patients in both groups.

Figure 2 summarizes the treatment algorithms and outcomes. A cure was achieved after one to three sessions of dilatation in two patients with a simple stenosis, and in four patients with a complex stenosis and stenosis segment length of 1–2 cm. The mean segment length of these four cases was 1.13 ± 0.25 cm (range: 1–1.5 cm), which was significantly different from that of the remaining complex stenosis cases (2.44 ± 1.57 cm [range: 1–7 cm]; $p = 0.04$). One patient with a complex stenosis and a history of ischemic heart disease died due to myocardial

infarction 48 hours after RB, and a tracheotomy was performed in one patient for whom the need for mechanical ventilation after dilatation persisted. A silicone stent was placed in the remaining 15 cases with a complex stenosis.

The mean duration of follow-up for the stented cases was 16.86 ± 3.09 months (range: 1–40 months); stents were removed in two of these cases due to subglottic stenosis and stent migration. One of these patients was followed-up after tracheotomy, and the other patient was monitored with a Montgomery T-tube. Of the remaining 13 cases that were followed-up after stent placement, the stents were removed in four cases after a mean follow-up of 15.25 ± 3.27 months (range: 7–21 months), and no recurrence was noted. The stent was removed 20 months later in one case, and a new stent was placed after the patient developed recurrent stenosis. In total, 10 patients who still have stents are continuing to be followed up (mean duration, 20.22 ± 4.50 months [range: 4–40 months]).

During follow-up of 15 patients who received a stent, 10 (66.7%) developed mucostasis, while granulation tissue formed in eight patients (53.3%) and stent migration occurred in four (26.7%) others. To manage complications, granulation tissue was treated with cryotherapy in eight cases. Of four patients showing stent migration, the stent was replaced in the region of stenosis in two patients, and re-migration did not occur. Of the remaining patients, one underwent a tracheotomy, and the other received a Montgomery T-tube.

Table 2 Bronchoscopic findings of patients and bronchoscopic procedures

	Bronchoscopical treatment group (n: 23)	Surgical treatment group (n: 19)	p value
Flexible bronchoscopy number	3 (IQR: 5) (0–24)	1 (IQR: 2) (0–13)	0.02
Rigid bronchoscopy number	3 (IQR: 2) (1–15)	2 (IQR: 1) (1–13)	0.03
Obstruction ratio	80.00 ± 2.99 (30–95)	79.47 ± 8.95 (60–90)	0.431
Segment length	2.07 ± 0.31 (0.8–7)	1.98 ± 0.81 (1.0–3.7)	0.560
Malaise (%)	7 (30.4)	1 (5.3)	0.03
Distance to vocal cords	2.80 ± 0.32 (1–6.5)	3.61 ± 1.95 (2–9)	0.133
Cryotherapy (%)	8 (34.8)	2 (10.5)*	0.059
Diode laser (%)	1 (4.3)	1 (5.3)	0.893
Dilatation number	2.09 ± 0.37 (0–8)	1.63 ± 0.23 (1–5)	0.462

*Cryotherapy; a patient who had undergone restenosis and underwent covered self-expandable metallic Y stenting and a patient who developed with atelectasis due to postoperative retention of secretion. IQR: interquartile range

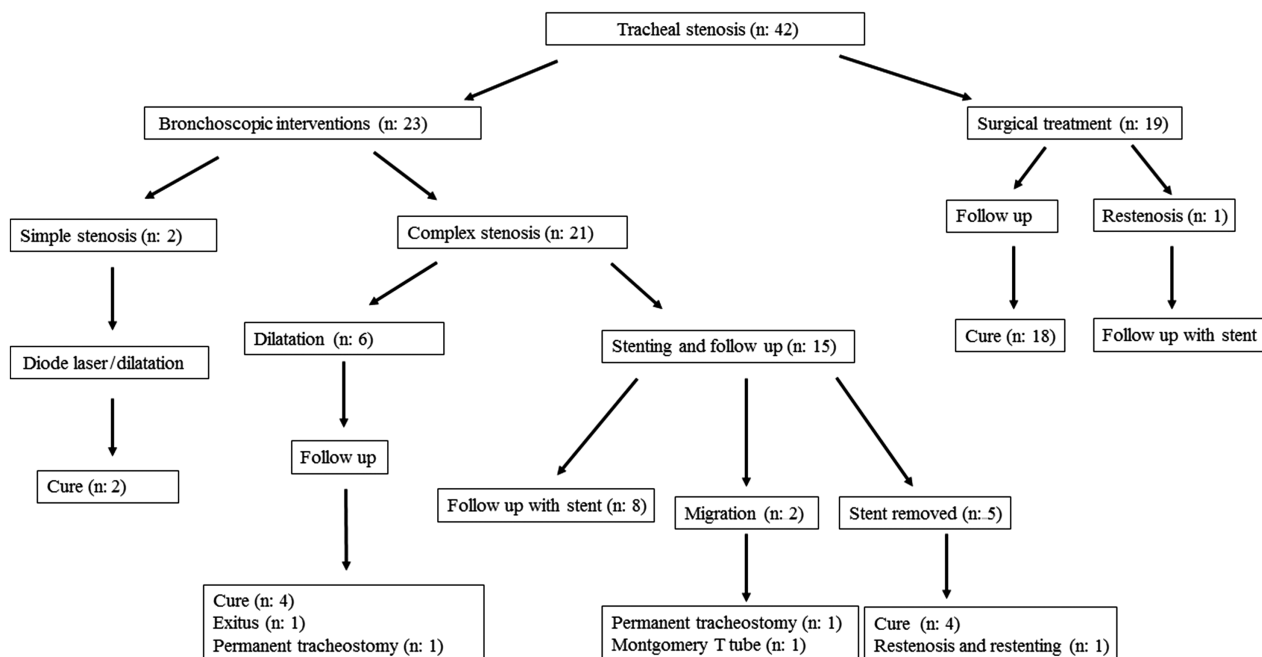


Fig. 2 Therapeutic management algorithm for patients with PITS. PITS: post-intubation tracheal stenosis

The surgical treatment group procedures were collar incision in 14 (73.7%), thoracotomy in 3 (15.8%), and collar with partial sternotomy incision in 2 (10.5%) cases. Tracheal flexion was performed in all patients, while suprahyoid flexion, carinal flexion, and carinal-hilar-pericardial flexion in combination were each used in two patients.

Seven (36.8%) patients developed postoperative complications, including four cases of sublobar atelectasis, two of temporary aphonia, two of wound infections, two of atrial fibrillation, one of pneumonia, and one of postoperative respiratory failure requiring intubation. One patient developed re-stenosis at the anastomosis line at postoperative week 3. As a silicon stent could not be

placed in the stenotic region (which also involved the carinal level), a fully covered self-expandable metallic Y stent was inserted and the patient is being followed-up with a stent (for 10 months). There was no postoperative mortality.

In total, a cure was achieved in 10 cases (43.47%) treated with bronchoscopic methods. Satisfactory outcomes were obtained in nine patients (39.13%) who are still being followed-up with a stent without symptoms. Bronchoscopic interventions failed in four (17.39%) cases. Notably, the surgical treatment approach was successful in 18 of 19 patients (94.7%) while the outcome was of failure in the remaining patient (5.3%) (Table 3).

Table 3 Results of multidisciplinary approach

	Bronchoscopic treatment group	Surgical treatment group	Total
Cure, % (n)	43.47 (10)	94.7 (18)	66.7 (28)
Satisfactory, % (n)	39.13 (9)	0	23.8 (10)*
Failure, % (n)	17.39 (4)	5.3 (1)	9.5 (4)

*Nine patients underwent bronchoscopic treatment, one patient failed in surgical treatment group, and stent was applied.

Discussion

Surgical resection and reconstruction are considered the gold standard of therapy for PITS but cannot be performed in all patients. Cardiovascular, respiratory, and neurologic comorbidities represent the greatest obstacles to surgery.⁴⁾ In the present study, comorbidities were more frequent in the inoperable patient group, whose only option was to undergo a bronchoscopic intervention. As not all patients with benign tracheal stenosis are eligible for surgical resection, it is impossible to cure all patients with bronchoscopic methods. Moreover, a significant problem of bronchoscopic interventions in operable patients relates to the risk of increasing the length of stenosis by applying procedures such as stent placement, which may complicate or even preclude any future curative surgery.^{1,12)} Therefore, a multidisciplinary approach should be applied, as this both ensures selection of the most appropriate treatment method for each patient and facilitates the management of inoperable patients. Bronchoscopic treatment methods were performed in a higher proportion of patients in our study (54.7%), and a successful outcome was achieved in 90.5% (66.7% cure and 23.8% satisfactory) of the patients using a multidisciplinary approach.

At different centers, algorithms for treating benign tracheal stenosis are mostly based on the facilities and experience of individual units, which prevents the development of a standard treatment algorithm. The success rates of surgical resection and reconstruction vary from 71% to 95%.^{3,13–15)} Grillo reported an operation failure rate of 3.7% and a mortality rate of 2.4%.³⁾ Overall, the success rate of surgical treatment varies from 71% to 95%.^{3,16–19)}

Different findings have been reported regarding the efficacy of bronchoscopic interventions for treating PITS. In cases of simple stenosis, the success rate of mucosal sparing with laser and mechanical dilatation varies from 60% to 100%.^{1,6,8,20,21)} Bronchoscopic interventions were associated with a lower cure rate in complex stenosis cases. The relapse rate after dilatation and laser-assisted dilatation is 90%, while stents provide a cure in 17.6% of cases.²¹⁾

Cavaliere et al. reported that endoscopic interventions provided good results in 66% of benign tracheal stenosis cases, whereas Gallucio reported cure rates of 96% and 69% for simple and complex stenosis, respectively.^{1,7)} The differences in the reported results may arise from the diversity of the treatment algorithms, as well as from differences in the definition of potential stenotic regions. In particular, other than the presence of a segment >1 cm, the definition of a complex stenosis may or may not include characteristics such as malaise, loss of cartilage support, and the presence of scar tissue, indicating that the group may not always be homogeneous.²²⁾ In our study, mechanical dilatation alone conferred a 100% cure rate in patients with a complex stenosis, short stenosis segment, and no accompanying malaise. Similar to the simple stenosis cases, the complex stenosis subgroup appeared to have morphologic characteristics that could be cured by repetitive mechanical dilatation. Monitoring outcomes of endoscopic interventions may be the proper approach for this group of patients, even if they are eligible for surgical resection.

Stent-related complications are the greatest concern associated with airway stenting. Previous studies reported the development of granulation tissue in 19.3%–33%, migration in 5%–41.1%, and mucostasis in 30%–43% of cases.^{8,23,24)} In the present study, more than half of the patients developed mucostasis and granulation tissue. Complications prevent the control of symptoms, resulting in repetitive bronchoscopic interventions. In the present study, the numbers of FB and RB procedures were higher in the group treated bronchoscopically. These interventions were performed to remove the mucostasis and granulation tissue that formed at the proximal and distal tips of the stent. In this study, repetitive cryotherapy sessions were performed in eight cases due to granulation tissue. Although cryotherapy has a late onset of action, as a safe method for removing granulation tissue (because it does not result in additional critical airway stenosis), it is preferable.

Previous studies investigating stenting procedures for benign tracheal stenosis reported different durations of stent persistence. While this is not a generally used

approach, stents can be removed after 6–12 months, and the patients monitored for recurrence. Four studies reported that stents can be removed after an average of 6, 11.6, 11.9, and 18 months, respectively.^{1,4,7,8)} These studies also reported different results regarding the risk of re-stenosis after removing the stent. In some cases, removing the stent alone may increase the risk of re-stenosis. In one study, tracheotomy was performed before stent placement, resulting in a three-fold increase in the probability of stent persistence.²⁴⁾ Gaissert et al.²⁵⁾ stated that successful treatment with a stent can be achieved by preserving cartilage and wall stability. Another study reported that long segment stenosis might affect the success of stenting, whereas other studies reported the opposite finding.^{24,26)} In the present study, stents were removed after an average of 15.25 ± 3.27 months (range: 7–21 months), and 10 patients with a stent have been followed-up for 20.22 ± 4.50 months (range: 4–40 months).

Bronchoscopic intervention remains the only treatment choice for patients who develop re-stenosis after removal of a stent. After removing airway stents, the reported rates of recurrence were 24.2% (n = 8/33), 25.8% (n = 32/124), and 18% (n = 13/73).^{1,7,8)} Stenting may be the only option for disease control in almost one-quarter of patients, despite the existence of other interventions. There is still no clear evidence indicating the type of patients with PITS who should be followed-up with a stent over the long term. Thus, we recommend that inoperable patients with complex stenosis should be followed-up with a stent for a longer duration provided that there are no stent-related complications. The stent can be removed at an earlier time if the initial aim of stenting was to provide bridging until an operation, or if the patient develops a major stent-related complication.

Few studies have compared bronchoscopic and surgical approaches to treat intubation-related tracheal stenosis. Mandour et al.²⁷⁾ reported that the rate of decannulation was 87% in an endoscopic treatment group of 13 patients, and 100% in an operative group of 15 patients. Morphologic characteristics of the stenotic segments were not clearly reported for either of the groups in their study, which included patients with different etiologies and made no distinction between malignant and benign disease. Those authors reported that laser-assisted dilatation with and without stenting was useful as palliative treatment for patients in whom surgery was contraindicated.

Herrington et al.²⁸⁾ reported that patients with a laryngo-tracheal stenosis needed repetitive interventions when they were initially treated by dilatation. Cuisnier et al.²⁹⁾

reported success rates of 91%, 79%, and 50% with surgery, stenting, and repetitive dilatation, respectively.²⁹⁾ Melkane et al. reported early term decannulation rates of 50% and 84.2% in surgical and endoscopic treatment groups, respectively. However, at the end of a 6-month follow-up, the decannulation rate increased to 85.7% in the surgery group, while it remained at 84.2% in the endoscopy group. Melkane et al. reported that both methods produced excellent outcomes, as long as the treatment strategy was predefined based on objective criteria.³⁰⁾ All studies reviewed herein included heterogeneous patient groups, and they also utilized very different treatment algorithms. Accordingly, the outcomes of each treatment approach varied among the studies.

The success rate of bronchoscopic treatment was lower than that of surgery in the present study, which agrees with most previous studies: this is probably because patients who underwent bronchoscopic treatment had more complex stenosis segments and a higher number of comorbidities. The most important factor in treatment success is evaluating patients with a multidisciplinary approach beginning at the initial diagnosis.

The most important limitations of this study include the relatively low number of patients and its retrospective nature. Although our unit monitored a large number of patients with tracheal stenosis during this study, patients who were lost to follow-up after bronchoscopic interventions were excluded.

Conclusion

There is still no clearly defined optimal approach to treat and manage patients with PITS. However, our findings suggest that treatment success could be increased by use of a multidisciplinary approach. Although bronchoscopic methods were associated with a lower cure rate compared to surgery, these interventions represent a critical step for all treatment modalities used in this patient population. Future studies should focus on defining patient subgroups that could be cured by bronchoscopic intervention.

Acknowledgment

The authors thank to Turkish Respiratory Society for their support of language editing.

Disclosure Statement

The authors have no conflict of interest.

References

- 1) Galluccio G, Lucantoni G, Battistoni P, et al. Interventional endoscopy in the management of benign tracheal stenoses: definitive treatment at long-term follow-up. *Eur J Cardiothorac Surg* 2009; **35**: 429-33; discussion 933-4.
- 2) Stauffer JL, Olson DE, Petty TL. Complications and consequences of endotracheal intubation and tracheotomy. A prospective study of 150 critically ill adult patients. *Am J Med* 1981; **70**: 65-76.
- 3) Grillo HC, Donahue DM, Mathisen DJ, et al. Postintubation tracheal stenosis. Treatment and results. *J Thorac Cardiovasc Surg* 1995; **109**: 486-92; discussion 492-3.
- 4) Brichet A, Verkindre C, Dupont J, et al. Multidisciplinary approach to management of postintubation tracheal stenoses. *Eur Respir J* 1999; **13**: 888-93.
- 5) Martinez-Ballarín JI, Diaz-Jimenez JP, Castro MJ, et al. Silicone stents in the management of benign tracheobronchial stenoses. Tolerance and early results in 63 patients. *Chest* 1996; **109**: 626-9.
- 6) Mehta AC, Lee FY, Cordasco EM, et al. Concentric tracheal and subglottic stenosis. Management using the Nd-YAG laser for mucosal sparing followed by gentle dilatation. *Chest* 1993; **104**: 673-7.
- 7) Cavaliere S, Bezzi M, Toninelli C, et al. Management of post-intubation tracheal stenoses using the endoscopic approach. *Monaldi Arch Chest Dis* 2007; **67**: 73-80.
- 8) Dalar L, Karasulu L, Abul Y, et al. Bronchoscopic treatment in the management of benign tracheal stenosis: choices for simple and complex tracheal stenosis. *Ann Thorac Surg* 2016; **101**: 1310-7.
- 9) Özdemir C, Sökücü SN, Karasulu L, et al. Placement of self-expandable bifurcated metallic stents without use of fluoroscopic and guidewire guidance to palliate central airway lesions. *Multidiscip Respir Med* 2016; **11**: 15.
- 10) Pearson FG, Andrews MJ. Detection and management of tracheal stenosis following cuffed tube tracheostomy. *Ann Thorac Surg* 1971; **12**: 359-74.
- 11) Grillo HC. The management of tracheal stenosis following assisted respiration. *J Thorac Cardiovasc Surg* 1969; **57**: 52-71.
- 12) Rea F, Callegaro D, Loy M, et al. Benign tracheal and laryngotracheal stenosis: surgical treatment and results. *Eur J Cardiothorac Surg* 2002; **22**: 352-6.
- 13) George M, Lang F, Pasche P, et al. Surgical management of laryngotracheal stenosis in adults. *Eur Arch Otorhinolaryngol* 2005; **262**: 609-15.
- 14) Marques P, Leal L, Spratley J, et al. Tracheal resection with primary anastomosis: 10 years experience. *Am J Otolaryngol* 2009; **30**: 415-8.
- 15) Guyton D, Banner MJ, Kirby RR. High-volume, low-pressure cuffs. Are they always low pressure? *Chest* 1991; **100**: 1076-81.
- 16) Primov-Fever A, Talmi YP, Yellin A, et al. Cricotracheal resection for airway reconstruction: the sheba medical center experience. *Isr Med Assoc J* 2006; **8**: 543-7.
- 17) Couraud L, Jougon JB, Velly JF. Surgical treatment of nontumoral stenoses of the upper airway. *Ann Thorac Surg* 1995; **60**: 250-9; discussion 259-60.
- 18) Marel M, Pekarek Z, Spasova I, et al. Management of benign stenoses of the large airways in the university hospital in Prague, Czech Republic, in 1998–2003. *Respiration* 2005; **72**: 622-8.
- 19) Bisson A, Bonnette P, el Kadi NB, et al. Tracheal sleeve resection for iatrogenic stenoses (subglottic laryngeal and tracheal). *J Thorac Cardiovasc Surg* 1992; **104**: 882-7.
- 20) Dutau H, Breen DP. Endobronchial laser treatment: An essential tool in therapeutic bronchoscopy. *Eur Respir Monogr* 2010; **48**: 149-160.
- 21) Baugnée PE, Marquette CH, Ramon P, et al. [Endoscopic treatment of post-intubation tracheal stenosis. Apropos of 58 cases]. *Rev Mal Respir* 1995; **12**: 585-92. (in French)
- 22) Murgu SD, Colt HG. Combined optical coherence tomography and endobronchial ultrasonography for laser-assisted treatment of postintubation laryngotracheal stenosis. *Ann Otol Rhinol Laryngol* 2013; **122**: 299-307.
- 23) Jeong BH, Um SW, Suh GY, et al. Results of interventional bronchoscopy in the management of postoperative tracheobronchial stenosis. *J Thorac Cardiovasc Surg* 2012; **144**: 217-22.
- 24) Terra RM, Bibas BJ, Minamoto H, et al. Decannulation in tracheal stenosis deemed inoperable is possible after long-term airway stenting. *Ann Thorac Surg* 2013; **95**: 440-4.
- 25) Gaissert HA, Grillo HC, Mathisen DJ, et al. Temporary and permanent restoration of airway continuity with the tracheal T-tube. *J Thorac Cardiovasc Surg* 1994; **107**: 600-6.
- 26) Kim SC, Kim SH, Kim BY. Successful decannulation of T-tubes according to type of tracheal stenosis. *Ann Otol Rhinol Laryngol* 2010; **119**: 252-7.
- 27) Mandour M, Remacle M, Van de Heyning P, et al. Chronic subglottic and tracheal stenosis: endoscopic management vs. surgical reconstruction. *Eur Arch Otorhinolaryngol* 2003; **260**: 374-80.
- 28) Herrington HC, Weber SM, Andersen PE. Modern management of laryngotracheal stenosis. *Laryngoscope* 2006; **116**: 1553-7.
- 29) Cuisnier O, Righini Ch, Pison Ch, et al. [Surgical and/or endoscopic treatment of acquired tracheal stenosis in adult patients]. *Ann Otolaryngol Chir Cervicofac* 2004; **121**: 3-13. (in French)
- 30) Melkane AE, Matar NE, Haddad AC, et al. Management of postintubation tracheal stenosis: appropriate indications make outcome differences. *Respiration* 2010; **79**: 395-401.