

## Case Series

## Brain metastasis from uterine serous carcinoma: A case report and review of literature

Tania Sierra<sup>a,1</sup>, Long Nguyen<sup>a</sup>, Justin Mascitelli<sup>a</sup>, Tamara Kalir<sup>b</sup>, David Fishman<sup>a</sup><sup>a</sup> Department of Obstetrics, Gynecology & Reproductive Science, Icahn School of Medicine at Mount Sinai, 1176 Fifth Ave., Box 1170, New York, NY 10029, United States<sup>b</sup> Department of Pathology, Icahn School of Medicine at Mount Sinai, United States

## ARTICLE INFO

## Article history:

Received 6 November 2014

Accepted 3 January 2015

Available online 15 January 2015

## Keywords:

Uterine papillary serous carcinoma

Brain metastasis

## Introduction

While endometrial cancer is the most common gynecological cancer with a generally favorable prognosis, the histological subtype of serous carcinoma is more aggressive and fortunately uncommon. Uterine serous carcinoma (USC) accounts for about 10% of cases of endometrial cancer and yet 39% of its deaths (Boruta et al., 2009). Brain metastasis from endometrial cancer is also rare, with a rate of 0.6% from a review of over 10,000 patients (Piura and Piura, 2012). This recent review of 35 studies by Piura et al. identified 115 cases of endometrial cancer that metastasized to the brain, of which 4 were USC (Piura and Piura, 2012). A further review of the literature uncovered an additional 4 cases. Here we present a new case from our institution, review the existing literature, and discuss current treatment options.

## Case report

The patient is a 55 year-old woman G1P1001 with no significant medical history who was diagnosed with stage IIIC2 USC in Cartagena, Spain. She initially presented with postmenopausal bleeding and pelvic fullness. A CT scan was consistent with an endometrial and left adnexal solid mass, retroperitoneal lymphadenopathy, mild ascites, grades I–II ureterohydronephrosis, and nonspecific pulmonary micronodules. Laboratory studies revealed an elevated CA-125 level of 121 units/mL. Subsequent MRI suggested that the mass invaded greater than 50% of

thickness of the myometrium. In July 2012, she underwent a total abdominal hysterectomy, bilateral salpingo-oophorectomy, pelvic and para-aortic lymph node dissection, omentectomy, and appendectomy, followed by six cycles of carboplatin/paclitaxel, pelvic radiation, and vaginal brachytherapy. She was monitored with serial CT images of the chest/abdomen/pelvis and CA-125 levels. Imaging in April 2013 was negative and CA-125 level was 26 units/mL in May 2013. She then immigrated to the US.

On June 2013, the patient presented to the emergency room with headache and dizziness of 3 days duration. She also reported an episode of urinary incontinence and near-syncope but denied any other focal neurological deficits. Her neurological exam was normal. A head CT scan revealed significant bifrontal edema with suggestion of an underlying lesion. An MRI demonstrated a well-circumscribed heterogeneously enhancing mass involving the anterior body of the corpus callosum and extending superiorly to the falx cerebri, measuring 3.6 × 4.1 cm (Fig. 1). Her CA-125 level was 107 units/mL. A CT of the chest, abdomen and pelvis was negative for metastatic disease.

Later that month, she underwent a bifrontal craniotomy and tumor resection via right sided para-falcine approach. Histology revealed cerebral metastasis from serous carcinoma with immunohistochemistry profile (CK7+, CK8/18+, CK20–, CDX2–, BRST2–, TTF1–) consistent with primary endometrial carcinoma (Fig. 2). Postoperatively, she developed bilateral pulmonary emboli with a saddle embolism component.

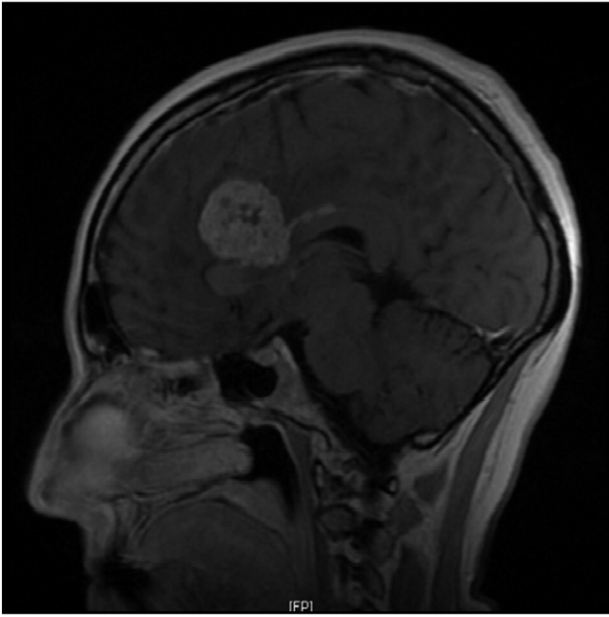
The patient was subsequently evaluated for consolidative whole brain radiation (WBRT) vs. stereotactic radiosurgery (SRS) to the post-operative cavity and residual tumor. Due to the size of the postoperative bed, as well as rapid interval post-surgical growth, she was given WBRT followed by chemotherapy (gemcitabine and carboplatin). Residual tumor was left attached to the corpus callosum and pericallosal arteries, as it was thought that aggressive resection of this portion would carry a high risk of post-surgical neurologic morbidity; however about 20 days later, reimaging suggested a continued growth of the residual tumor posteriorly along the corpus callosum and superiorly into the frontal lobes. In February 2014, imaging revealed metastatic lung nodules. As of submission date, she is alive with disease on chemotherapy.

## Discussion

USC is an uncommon form of endometrial cancer that rarely metastasizes to the brain. Herein we present a summary of the eight reported cases in the literature; our case report marks the ninth. An extraction of

E-mail addresses: [tania.sierra@mssm.edu](mailto:tania.sierra@mssm.edu) (T. Sierra), [long.nguyen@mssm.edu](mailto:long.nguyen@mssm.edu) (L. Nguyen), [justin.mascitelli@mssm.edu](mailto:justin.mascitelli@mssm.edu) (J. Mascitelli), [tamara.kalir@mssm.edu](mailto:tamara.kalir@mssm.edu) (T. Kalir), [david.fishman@mssm.edu](mailto:david.fishman@mssm.edu) (D. Fishman).

<sup>1</sup> Fax: +1 212 241 3833.



**Fig. 1.** Preoperative sagittal MRI with IV contrast showing enhancing mass involving the anterior body of the corpus callosum.

clinicopathological features (age, stage, grade, lymphovascular space involvement), time interval to brain metastasis, diagnostic findings (number and location of brain metastases, presence of systemic disease), treatment, and survival is summarized in Table 1 (Petru et al., 2001; Gulsen and Terzi, 2013; Chura JC et al., n.d.; Gien et al., 2004; Talwar and Cohen, 2012; Dietrich et al., 2005; Comert et al., 2012).

Among the nine cases of USC metastatic to the brain, the median age was 69.5 with a median survival of 5 months since diagnosis of brain metastasis. Our case report is the youngest patient at 55 and she is still alive at 12 months, currently undergoing treatment.

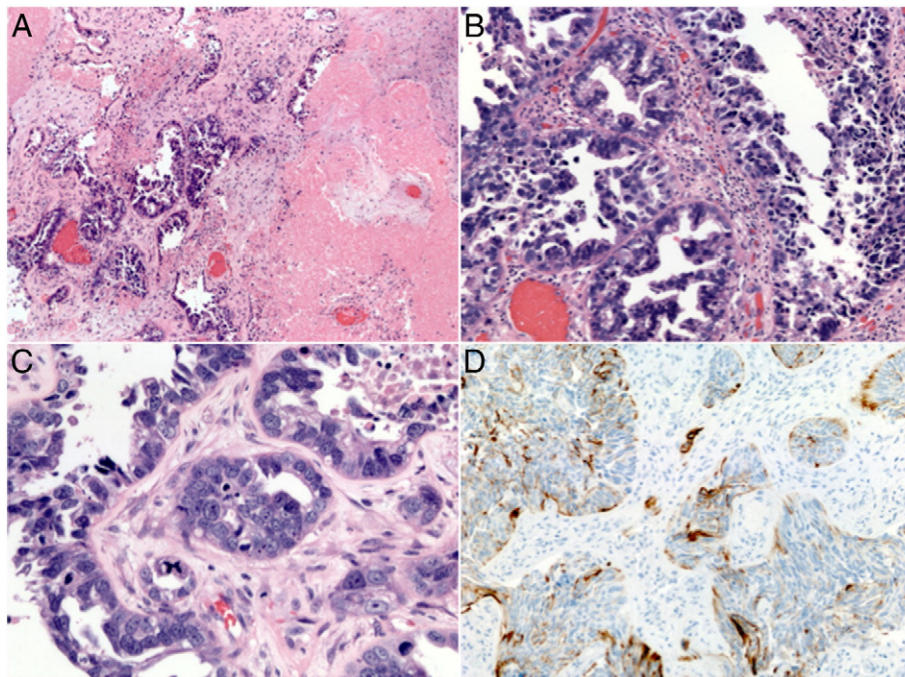
The stages of USC were varied, with 4 stage I, 3 stage III, 1 unstaged, and 1 unreported stage. This variation translated into a large interval of diagnosis of brain metastasis from USC, with a median interval of 23 months (range, 0.6 months to greater than 5 years). This is consistent with the previous finding of a median of 17 months (range, 2 to 108 months) for all endometrial carcinoma (Piura and Piura, 2012).

Most of the cancers were high-grade with >50% myometrial invasion and signs of systemic disease at the time of brain metastasis (although 3 cases showed no other sites of metastases). This finding is also similar to Piura et al.'s conclusion that 80% of patients who developed brain metastases from endometrial carcinoma presented with high-grade disease and about half had disseminated disease, although certainly our case series yields far too few numbers to state any definitive conclusions (Piura and Piura, 2012).

The quantity and location of lesions in the nine cases reviewed varied considerably. A third of brain metastatic lesions were solitary, a third were multiple, and a third were unreported. Given that the route of spread is primarily hematological when metastatic to the brain, the lesions demonstrated wide spatial distribution.

The treatments for brain metastasis include: WBRT, excisional surgery (i.e. craniotomy), radiosurgery, and chemotherapy. While metastatic brain tumors are the most common intracranial tumor (typically from the lung, breast, renal, and gastrointestinal cancers), treatment varies according to lesion number, accessibility, and overall prognosis. There is no standard of care for USC brain metastasis given the paucity of cases, although general principles from neurosurgery may be followed. Traditionally, solitary brain lesions would undergo resection followed by WBRT and multiple lesions would receive WBRT (Piura and Piura, 2012). In the present case series, 3 patients underwent surgical resection (1 with a solitary lesion, 1 resected one of three lesions that was causing mass effect, and 1 unspecified lesion) (Petru et al., 2001; Gulsen and Terzi, 2013; Chura JC et al., n.d.). Only 1 patient underwent radiosurgery as part of multimodal therapy and 5 patients underwent WBRT.

Chemotherapeutic regimens for brain metastasis are difficult to select because of the paucity of data for endometrial cancer and the likelihood of concomitant systemic disease—5 of the 9 case reports had



**Fig. 2.** (A) Microscopic low-power view showing brain parenchyma infiltrated by carcinoma and extensive areas of necrosis (H&E,  $\times 40$ ). (B) Medium-power view showing tumor forming glandular structures and a pseudopapillary arrangement of the tumor cells (H&E,  $\times 200$ ). (C) High-power view showing highly pleomorphic tumor cells and one atypical tetra-polar mitotic figure (blue arrow, H&E,  $\times 400$ ). (D) Tumor cells with positive cytokeratin-7 immunohistochemical stain (CK7,  $\times 200$ ).

**Table 1**  
Summary of nine case reports of brain metastasis from USC.

	Case 1	Case 2	Case 3	Case 4	Case 5	Case 6	Case 7	Case 8	Case 9
	Petru 2001	Gien 2003	Gien 2003	Dietrich 2005	Chura 2007	Comert 2012	Talwar 2012	Gulsen 2013	Sinal 2013
Age at diagnosis of metastasis	60	72	82	72	63	Unknown	68	71	55
Stage	Unstaged	IIIC	IIB	IC	IA	IB	IA	Unknown	IIIC2
Grade	3	Unknown	Unknown	Unknown	3	3	3	Unknown	3
LVSI	+	+	–	Unknown	Unknown	Unknown	–	Unknown	+
Depth of myometrial invasion	"Deep, serosal involvement"	>50%	>50%	>50%	<50%	>50%	0%	Unknown	>50%
Interval (months) between primary diagnosis & brain metastasis	N/A*	40	24	22	0.6	2	>60	27	11
Number of brain metastases	Solitary	Multiple	Multiple	Unknown	Unknown	Solitary	Unknown	Multiple	Solitary
Systemic disease	None	Lung	Vault	Liver, lung	None	"Disseminated abdominal spread"	Lung	Unknown	None
Lesion location	R cerebellum	Cerebellum, L temporal	R frontal, R parietal, bioccipital	Unknown	Unknown	Unknown	Unknown	Posterior fossa, R frontal lobe	Bifrontal tumor
Surgical excision	+	–	–	–	+	–	–	+	+
Brain metastasis treatment	Radiosurgery, chemotherapy, medroxyprogesterone	WBRT	Steroids	Unknown	WBRT, chemotherapy	Unknown	WBRT, chemotherapy	WBRT, chemotherapy	WBRT, chemotherapy
Brain metastasis survival (months)	15	5	0.25	2	9.2	5	>3	>9	Alive with disease, >12

systemic disease. Additionally, previous chemotherapy agents used need to be considered, as metastatic lesions may be chemoresistant. One agent with supporting data is topotecan, known to freely cross the blood–brain barrier, with activity against lung cancer brain metastasis (Wong and Berkenblit, 2004; Langer and Mehta, 2005). Paclitaxel has also been studied for brain metastasis, in combination with WBRT, but it did not show an improvement in median survival (Glantz et al., 1999).

The treatment outcomes for these patients are difficult to interpret, as the stage, extent of disease, and individual health must be taken into consideration to judge success. However, the median survival since diagnosis of brain metastasis was poor at 5 months, which is the exact same finding that Piura et al. note in their review of 115 cases of endometrial cancer (91 with available data). This suggests that perhaps mortality is due to the presence of brain metastasis and overall disease and not the histological type of cancer—although, again, with a small case series no firm conclusions should be made. Piura et al. conclude that longer survival results when multimodal therapy is used, such as surgery/radiosurgery followed by WBRT with or without chemotherapy (22 months) versus WBRT alone (2 months) or craniotomy alone (2.25 months). Our findings support this conclusion. Additionally, a randomized trial showed that surgical resection plus radiotherapy results in better survival and quality of life compared to radiotherapy alone for solitary brain metastases (Patchell et al., 1990). Of note, this study included 48 patients with Karnofsky performance scores >70% and primary cancers from lung, breast, GI, GU, and melanoma. When patient status is otherwise reassuring, especially in the presence of a solitary lesion, we support multimodal therapy including surgical resection.

## Conclusion

This is the ninth case report of USC brain metastasis published in the literature. Although it is an uncommon type of uterine carcinoma, this case review suggests that USC resembles other endometrial cancers in regard to its high-grade nature, interval to brain metastasis, survival, and treatment outcomes. However, the scarcity of reported cases necessitates highly individualized therapy, as there is no standard of management. When appropriate, it seems that multimodal therapy offers the best hope.

## Conflicts of interest statement

The authors report no conflict of interest.

## References

- Boruta, D.M., Gehrig, P.A., Fader, A.N., Olawaiye, A.B., Oct 2009. Management of women with uterine papillary serous cancer: a Society of Gynecologic Oncology (SGO) review. *Gynecol. Oncol.* 115 (1), 142–153.
- Chura, J.C., Marushin, R., Boyd, A., Ghebre, R., Geller, M.A., 2007. Argenta PA: Multimodal therapy improves survival in patients with CNS metastasis from uterine cancer: a retrospective analysis and literature review. *Gynecol. Oncol.* 107 (1), 79–85.
- Comert, C.E., Bildaci, T.B., Karakaya, B.K., Tarhan, N.C., Ozen, O., Gulsen, S., et al., 2012. Outcomes in 12 gynecologic cancer patients with brain metastasis: a single center's experience. *Turk. J. Med. Sci.* 42, 385–394.
- Dietrich III, C.S., Modesitt, S.C., DePriest, P.D., Ueland, F.R., Wilder, J., Reedy, M.B., Pavlik, E.J., Kryscio, R., Cibull, M., Giesler, J., Manahan, K., Huh, W., Cohn, D., Powell, M., Slomovitz, B., Higgins, R.V., Merritt, W., Hunter, J., Puls, L., Gehrig, P., van Nagell Jr., J.R., Dec 2005. The efficacy of adjuvant platinum-based chemotherapy in Stage I uterine papillary serous carcinoma (UPSC). *Gynecol. Oncol.* 99 (3), 557–563.
- Gien, L.T., Kwon, J.S., D'Souza, D.P., et al., 2004. Brain metastases from endometrial carcinoma: a retrospective study. *Gynecol. Oncol.* 93, 524–528.
- Glantz, M., Choy, H., Chakravarthy, A., et al., 1999. A randomized phase III trial of concurrent paclitaxel and whole brain radiotherapy (WBRT) vs. WBRT alone for brain metastases. *Proc. Am. Soc. Clin. Oncol.* 18, 140a (abstract 535).
- Gulsen, S., Terzi, A., Aug 28 2013. Multiple brain metastases in a patient with uterine papillary serous adenocarcinoma: treatment options for this rarely seen metastatic brain tumor. *Surg. Neurol. Int.* 4, 111.
- Langer, C.J.I., Mehta, M.P., Sep 1 2005. Current management of brain metastases, with a focus on systemic options. *J. Clin. Oncol.* 23 (25), 6207–6219.

- Patchell, R.A., Tibbs, P.A., Walsh, J.W., Dempsey, R.J., Maruyama, Y., Kryscio, R.J., et al., 1990. A randomized trial of surgery in the treatment of single metastases to the brain. *N. Engl. J. Med.* 322, 494–500.
- Petru, E., Lax, S., Kurschel, S., Gücer, F., Sutter, B., May 2001. Long-term survival in a patient with brain metastases preceding the diagnosis of endometrial cancer. Report of two cases and review of the literature. *J. Neurosurg.* 94 (5), 846–848.
- Piura, E., Piura, B., 2012. Brain metastases from endometrial carcinoma. *ISRN Oncol.* 2012, 581749.
- Talwar, S., Cohen, S., 2012. Her-2 targeting in uterine papillary serous carcinoma. *Gynecol. Oncol. Case Rep.* 2 (3), 94–96 (May 8).
- Wong, E.T., Berkenblit, A., 2004. The role of topotecan in the treatment of brain metastases. *Oncologist* 9 (1), 68–79.