



REVIEW ARTICLE

Skeletal and airway stability after mandibular setback in patients with mandibular prognathism: A systematic review



Mohammed A. AlZayer^{a,*}, Yiu Yan Leung^b

^a Oral and Maxillofacial Surgery, Dammam Medical Complex, Saudi Arabia

^b Oral and Maxillofacial Surgery, Faculty of Dentistry, The University of Hong Kong, Hong Kong

Received 22 June 2019; revised 18 February 2020; accepted 23 February 2020

Available online 6 March 2020

KEYWORDS

Class III malocclusion;
Orthognathic procedures;
Mandibular setback;
Radiographic imaging;
Hyoid bone;
Airway changes

Abstract *Aim:* To perform a systematic review to answer the clinical question “What are the longitudinal skeletal and airway changes after mandibular setback orthognathic procedures?”

Materials and methods: A systematic search including computer search of different databases with specific keywords, manual search through three international journals and reference list search was performed. Articles that were reporting the skeletal and airway changes after mandibular setback orthognathic procedures were evaluated with five predetermined criteria.

Results: Six articles with a total of 217 patients entered the final review. All were rated to be of moderate bias risk. Four studies evaluated the skeletal and airway changes using two-dimensional (lateral) cephalometric radiographic imaging, whereas the other two studies used three-dimensional imaging with cone-beam computed tomography. In the two-dimensional studies, skeletal relapses from T0 (immediate postoperative) to T1 (postoperative 1–6 months) ranged from –2.14 mm to 0.30 mm, whereas skeletal relapses from T1 to T2 (postoperative 1 year) ranged from –0.90 mm to 1.23 mm. In the three-dimensional studies, skeletal relapse from T1 to T2 ranged from –0.26 mm to 1.53 mm. All included studies reported that there were no significant skeletal relapses after mandibular setback procedures. Regarding airway changes, airway changes from preoperative to T0/T1 ranged from –0.30 mm to –2.32 mm in the two-dimensional studies. Airway changes from T0 to T1 ranged from –0.70 mm to –1.63 mm, whereas airway changes from T1 to T2 ranged from 0.11 mm to 0.60 mm, respectively.

Conclusions: This systematic review showed there was insignificant skeletal relapse after mandibular setback orthognathic procedures. It was noted a small increase of the airway over

* Corresponding author at: Oral and maxillofacial Surgery department, Dammam Medical Complex, King Khalid Street, Dammam 32245, Saudi Arabia.

E-mail address: malzayer@moh.gov.sa (M.A. AlZayer).

Peer review under responsibility of King Saud University.



the first post-operative year in studies using 2-dimensional radiography. However, such finding was not consistent in studies using 3-dimensional imaging with volumetric analysis of the airway changes.

© 2020 The Authors. Production and hosting by Elsevier B.V. on behalf of King Saud University. This is an open access article under the CC BY-NC-ND license (<http://creativecommons.org/licenses/by-nc-nd/4.0/>).

Contents

1. Introduction	170
2. Materials and methods	170
2.1. First-round search	170
2.2. Second-round search	171
2.3. Third-round: Evaluation	171
3. Results	171
3.1. General findings	171
3.2. Two-dimensional skeletal and airway changes after mandibular setback procedures	172
3.2.1. Skeletal changes at each postoperative period: T0 (Immediate), T1 (1–6 months) and T2 (1 year) Table 2	172
3.2.2. Airway changes at each postoperative period: T0 (Immediate), T1 (1–6 months) and T2 (1 year) Table 2	174
3.3. Three-dimensional skeletal and airway changes after mandibular setback procedures	174
3.3.1. Skeletal change at each postoperative period: T1 (4 to 6 months), T2 (1 year), and T3 (2 years) Table 3	174
3.3.2. Airway changes at the postoperative periods: T1 (4–6 months), T2 (1 year) and T3 (2 years) Table 3	174
4. Discussion	175
5. Conclusion	175
CRediT authorship contribution statement	175
Declaration of Competing Interest	175
Acknowledgments	176
References	176

1. Introduction

Class III skeletal deformity may occur as a result of mandibular hyperplasia, maxillary hypoplasia, or a combination of the two situations. Orthognathic surgery can help correct the dentofacial deformity. It may involve single-jaw or double-jaw orthognathic procedures to achieve improved functional and aesthetic outcomes, depending on the nature of the deformities in the maxilla, the mandible, or both. When mandibular orthognathic procedures are performed to correct mandibular prognathism, the anatomical structures at the tongue base that are attached to the mandibular bone and form part of the upper airway are also re-positioned. In recent decades, researchers and clinicians have paid increased attention to airway changes after orthognathic surgery to correct mandibular prognathism. Studies using lateral cephalograms have portrayed such airway changes in two dimensions (Samman et al., 2002; Hochban et al., 1996; Enacar et al., 1994; Tselnik and Pogrel, 2000). Recently, with advances in radiography, three-dimensional measurements of airway changes have become more popular and have offered a more detailed view of airway changes after orthognathic surgery (Kawamata et al., 2000; Park et al., 2012).

From a purely anatomical perspective, airway reduction is an expected consequence of mandibular setback procedures. That said, various reports have demonstrated differing results on long-term airway changes. Some researchers have suggested that airway reduction could be permanent and might even pose

a risk for developing obstructive sleep apnea (Enacar et al., 1994). However, other reports have indicated no such risk of long-term airway changes after mandibular setback procedures (Hochban et al., 1996). The full effect on the airway at different postoperative time points after mandibular setback procedures remains incompletely known.

The aim of this study is, therefore, to perform a systematic review to answer the following clinical question: “What are the longitudinal skeletal and airway changes after mandibular setback orthognathic procedures?”

2. Materials and methods

The study is a systematic review with two search rounds and an evaluation round. Articles that were eligible were selected for final review for evaluation of their bias risk.

2.1. First-round search

A literature search was performed to identify articles reporting on skeletal and airway changes after orthognathic surgery for patients with mandibular prognathism. This search employed three computer databases: the National Library of Medicine (PubMed), Scopus, and Cochrane Library. No restrictions on language, publication date, or publication status were imposed. The search date window ended with March 3, 2015. The search terms were as follows:

["Orthognathic surgery" OR "Mandibular setback" OR "Skeletal class III" OR "Prognathism"] AND ["Posterior airway space" OR "Pharyngeal airway" OR "Airway"].

The titles and abstracts of these articles were screened. Articles relevant to skeletal and airway stability after orthognathic surgery in prognathic patients were retrieved and included in the next round.

2.2. Second-round search

To improve coverage of the literature, a manual search was done through three international peer-reviewed oral and maxillofacial surgery journals, namely the Journal of Oral and Maxillofacial Surgery, the International Journal of Oral and Maxillofacial Surgery, and the British Journal of Oral and Maxillofacial Surgery. Dates of publication were limited to the period between March 2005 and March 2015. Articles found to be relevant to skeletal and airway changes after mandibular setback orthognathic surgery were selected in this round.

This round included a search of articles from the reference lists of articles selected from the first-round search and the manual search. Also selected were relevant articles not drawn from the first-round search or the manual search.

All the selected articles from the two rounds entered the third round for evaluation.

2.3. Third-round: Evaluation

All articles that entered this round were evaluated using the following criteria:

- (1) The article must clearly report skeletal changes and relapse by reporting the B-point of the mandible in millimeters (mm).
- (2) The article must clearly report airway measurements at the level of the tongue using a standardized method.
- (3) The follow-up period for study subjects must not be less than one postoperative year.

- (4) The article must report skeletal and airway measurements at all the following stages: preoperative, early postoperative (within 6 months), and late postoperative (1 year or more).
- (5) The article must be a prospective or retrospective clinical trial or an observational study.

Articles fulfilling all five criteria were selected for final review. They were then analyzed with regard to their reported data on skeletal and airway changes after mandibular setback in patients with mandibular prognathism. Articles not fulfilling all criteria in this round were excluded from further review.

Each article in the final review was rated for its bias risk level (low, moderate, or high) using five criteria:

1. The population was randomly selected.
2. The inclusion criteria were clearly defined.
3. The exclusion criteria were clearly defined.
4. The follow-up period was clearly reported.
5. Measurement and statistical analysis were clearly executed and validated.

The risk of bias was categorized as low for articles meeting all five of these criteria, moderate for articles meeting four of the criteria, and high for articles meeting three or fewer of the criteria.

3. Results

3.1. General findings

In the first-round electronic search, PubMed yielded 305 hits, with 14 additional hits coming from Scopus using keyword combinations. The Cochrane Library yielded two hits, but these were found to be duplicates of the hits from PubMed. Based on screening, 32 of these articles were relevant to skeletal and airway changes after orthognathic surgery for patients with mandibular prognathism and were, therefore, selected to enter the next round. The other 287 articles were not relevant

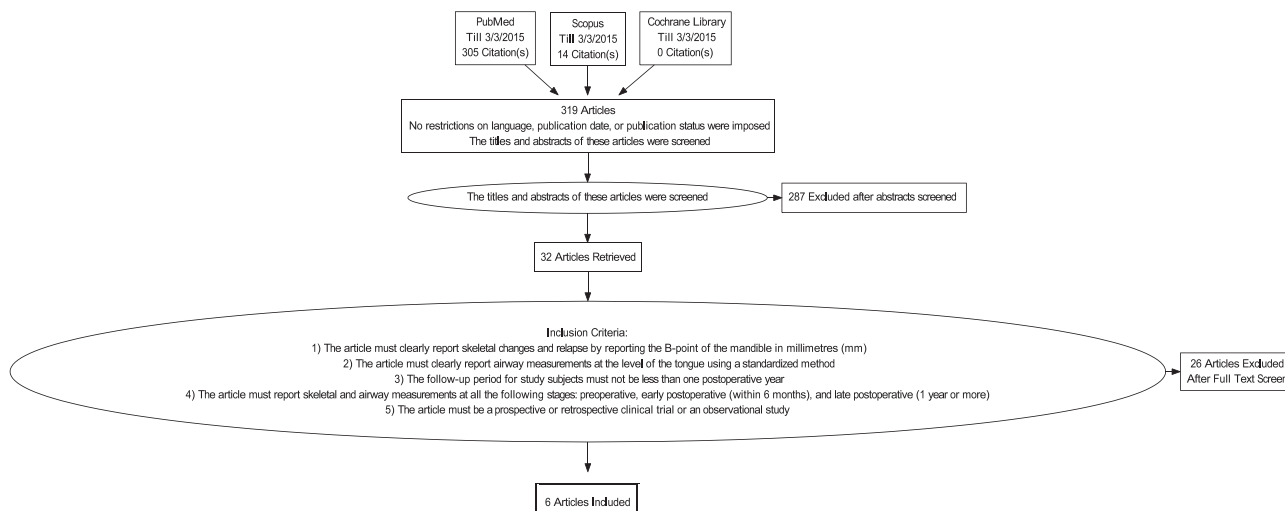


Fig. 1 PRISMA chart of the article selection process.

Table 1 Characteristics of the studies included.

Author	Year	Type of study	Sex (male/female)	Mean age	Mean of mandibular setback	No. Of patients One-jaw two-jaw	Image for analysis	Follow-up period
Eggensperger et al.	2005	RS	9/3	M: 41 F: 28	5.6 mm	12	Cephalometric analysis	1 week/6 month/14 months/12 years
Hwang et al.	2010	PS	30/30	M:23.1 F:23.3	5.43 mm	15	Cephalometric analysis	Immediate/1 month/1 year
Park et al.	2012	PS	23/13	22.97	N.M.	20	CBCT	4.6 month/1.4 year
Becker et al.	2012	RS	20/38	N.M.	N.M.	0	Cephalometric analysis	2–4 Month/6–12 month
Efendiyeva et al.	2014	RS	10/16	M: 21.4 F: 23.12	3.97 mm	0	Cephalometric analysis	5 months/1.4 years/3 years/5 years
Shin et al.	2015	RS	8/7	27.4	N.M.	0	CBCT	6 month/1 year/2 year

CBCT: Cone Beam Computed Tomograph; PS: Prospective Study; RS: retrospective study; N.M.: Not Mentioned.

and were excluded. In the second-round search, no additional relevant articles were found in the manual search or the reference list search. The full texts of these 32 articles from round one were evaluated by the four criteria in the third round for evaluation. Only six articles fulfilled all criteria and were, therefore, selected for final review. The other 26 articles failed to meet one or more of the listed criteria and were excluded. A flow diagram of the article selection process is presented in Fig. 1.

The six studies in the final review were evaluated for bias risk level. None of the six articles met the criterion of random selection of the studied population, but all six fulfilled the other four criteria. All six articles were thus rated as having moderate bias risk.

Characteristics of the included articles are presented in Table 1. The articles included four retrospective studies and two prospective studies, with a total of 217 patients. Five studies used sagittal split ramus osteotomy (SSRO), and one study used intra-oral vertical ramus osteotomy for the mandibular setback procedure. Four studies used two-dimensional (lateral) cephalometrics radiography analysis, whereas two studies used a three-dimensional cone beam computer tomography (CBCT) analysis.

All six studies reported the B-point and monitored skeletal changes.

Due to heterogeneity in the timing of postoperative follow-ups in the four two-dimensional analyses, the follow-up periods were categorized into four subsets: “Immediate,” “1–6 months,” “1 year,” and “More than 1 year.”

For the two studies reporting 3-dimensional changes, the follow-up periods were categorized into three subsets: “4–6 months,” “1 year,” and “2 years.”

3.2. Two-dimensional skeletal and airway changes after mandibular setback procedures

Four articles described skeletal and airway changes after mandibular setback procedures using two-dimensional lateral cephalometrics (Becker et al., 2012; Eggensperger et al., 2005; Hwang et al., 2010; and Efendiyeva et al., 2014). Three studies were retrospective, and one was prospective. A total of 156 patients underwent mandibular setback surgery as part or whole of the orthognathic surgery. Two studies reported changes immediately postoperatively (Eggensperger et al., 2005; Hwang et al., 2010). All four studies reported follow-ups between 1 and 6 months postoperatively and one year postoperatively. Two studies reported a long-term follow-up (3 years, 5 years, and 12 years postoperatively). To reduce heterogeneity of the analyzed results, skeletal and airway changes beyond 1 year postoperatively were not analyzed in this systematic review.

3.2.1. Skeletal changes at each postoperative period: T0 (Immediate), T1 (1–6 months) and T2 (1 year) Table 2

At immediate postoperative follow-up (T0), Eggensperger et al. (2005) reported the mean movement of the B-point after mandibular setback procedures to be -5.60 mm, whereas Hwang et al. (2010) reported -5.43 mm (Table 2). Between T0 and early postoperative follow-up (T1), mean skeletal change was reported by Eggensperger et al. (2005) to be 0.30 mm, whereas Hwang et al. (2010) reported a mean change

Table 2 Postoperative skeletal and airway changes at different time points reported in the included studies using two-dimensional measurements. Measurements are in millimeters compared with preoperative measurement.

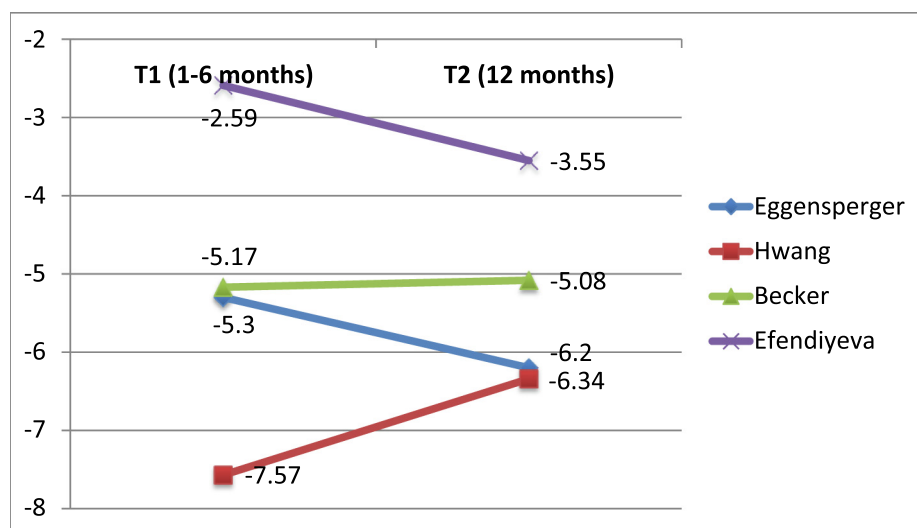
Study	T0 (Immediate)	T1 (1–6 months)	T0 to T1	T2 (12 months)	T1 to T2	T0 to T2
Skeletal Changes						
Eggensperger et al.	–5.6 mm	–5.3 mm	0.3 mm	–6.2 mm	–0.9 mm	–0.6 mm
Hwang et al.	–5.43 mm	–7.57 mm	–2.14 mm	–6.34 mm	1.23 mm	–0.91 mm
Becker et al.	N.M.	–5.17 mm	N/A	–5.08 mm	0.08 mm	N/A
Efendiyeva et al.	N.M.	–2.59 mm	N/A	–3.55 mm	–0.96 mm	N/A
Airway Changes						
Eggensperger et al.	–0.3 mm	–1 mm	–0.7 mm	–0.4 mm	0.6 mm	–0.1 mm
Hwang et al.	–0.67 mm	–2.3 mm	–1.63 mm	–1.86 mm	0.44 mm	–1.19 mm
Becker et al.	N.M.	–2.32 mm	N/A	–2.21 mm	0.11 mm	N/A
Efendiyeva et al.	N.M.	–1.13 mm	N/A	–0.81 mm	0.32 mm	N/A

(N.M.: Not Mentioned; N/A: Not Applicable. Negative value indicates posterior displacement; positive value indicates anterior displacement.)

Table 3 Postoperative skeletal and airway changes at different time points reported in the included studies using three-dimensional measurements.

Study	T0 (pre-op)	T1 (4–6 months)	T0 to T1	T2 (1–1.4 year)	T1 to T2	T3 (2 years)	T2 to T3
Skeletal Changes							
Shin et al. (n = 15)							
B-point (mm)	N/A	N/A	–7.75	–8.01	–0.26	–7.83	0.18
Park et al. (n = 36)							
B-point (mm)	N/A	N/A	–7.56	–6.03	1.53	N.M.	N.M.
Airway Changes							
Shin et al. (n = 15)							
Oropharyngeal Volume (mm ³)	N.M.	N.M.	–1649.47	N.M.	–1,438.73	N.M.	1,324.52
Hypopharyngeal Volume (mm ³)	N.M.	N.M.	–3995.8	N.M.	–1,623.34	N.M.	1,754.68
Park et al. (n = 36)							
Oropharyngeal Volume (mm ³)	11,281.94	8,775.68	–2,506.26	9,007.77	232.09	N.M.	N.M.
Hypopharyngeal Volume (mm ³)	14,003.39	12,510.80	–1,492.59	13,394.74	883.94	N.M.	N.M.

(N.M.: Not Mentioned; N/A: Not Applicable. A negative value indicates posterior displacement of mandible or decrease in airway volume; a positive value indicates anterior displacement of mandible or increase in airway volume.)

**Fig. 2** Postoperative two-dimensional *skeletal* changes (mm) between T1 (1–6 months) and T2 (12 months) compared to preoperative measurement. (A negative value indicates posterior movement.)

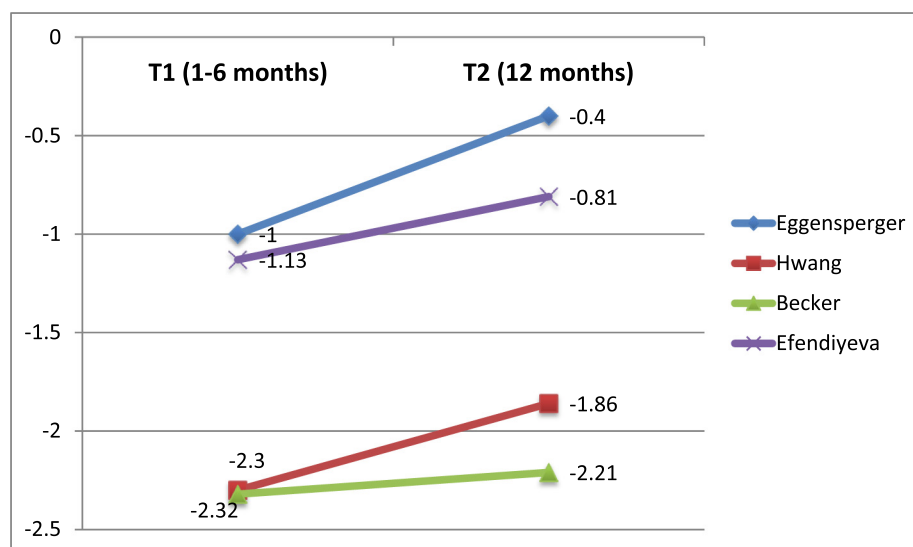


Fig. 3 Postoperative two-dimensional *airway* changes (mm) between T1 (1–6 months) and T2 (12 months) compared to preoperative measurement in two-dimensional measurements. (A negative value indicates posterior movement.)

of -2.14 mm. All four included studies calculated skeletal changes between T1 and 1 year post operation (T2). The mean change from T1 to T2 was reported to range from -0.90 mm to 1.23 mm. Eggensperger et al. (2005) reported the mean skeletal change from T0 to T2 to be -0.60 mm, whereas Hwang et al. (2010) reported the mean skeletal change to be -0.91 mm. Skeletal changes in each study from T1 to T2 are presented in Fig. 2. Three studies reported further posterior movement of the B-point of the mandible, and one study reported relapse of setback at T2 compared to T1. All four two-dimensional studies reported no statistically significant skeletal relapse between any pair of time points.

3.2.2. Airway changes at each postoperative period: T0 (Immediate), T1 (1–6 months) and T2 (1 year) Table 2

At immediate postoperative follow-up (T0), Eggensperger et al. (2005) reported the mean airway reduction after mandibular setback procedures to be 0.30 mm, whereas Hwang et al. (2010) reported a mean reduction of 0.67 mm. Mean airway change between T0 and T1 was reported by Eggensperger et al. (2005) to be -0.70 mm, whereas Hwang et al. (2010) reported a mean change of -1.63 mm. All four studies compared airway changes between T1 and T2, with mean reported airway change ranging from 0.11 mm to 0.60 mm. Eggensperger et al. (2005) reported a mean airway change of -0.10 mm from T0 to T2, whereas Hwang et al. (2010) reported a mean of -1.19 mm. The mean airway change from T1 to T2 for each study is presented in Fig. 3. All four two-dimensional studies indicated an increase in the airway from T1 to T2.

3.3. Three-dimensional skeletal and airway changes after mandibular setback procedures

Two articles analyzed three-dimensional skeletal and airway changes using CBCT (Shin et al., 2015; Park et al., 2012). A total of 51 patients were included in these two studies. The assessment time points were categorized as follows: pre-

surgery (T0), postoperative 4 to 6 months (T1), 1 year (T2), and two years (T3).

3.3.1. Skeletal change at each postoperative period: T1 (4 to 6 months), T2 (1 year), and T3 (2 years) Table 3

Between T0 and early postoperative follow-up (T1), mean mandibular setback was reported by Shin et al. (2015) to be 7.75 mm, whereas Park et al. (2012) reported a mean of 7.56 mm. However, by the T2 time point, Shin et al. (2015) reported a further posterior movement of the B-point by -0.26 mm, whereas Park et al. (2012) reported anterior movement (relapse) of the B-point by 1.53 mm. For Shin et al. (2015), the 0.18 mm mean relapse of the B-point occurred between T2 and T3. However, both three-dimensional studies reported no statistically insignificant mandibular setback relapse between any pair of time points.

3.3.2. Airway changes at the postoperative periods: T1 (4–6 months), T2 (1 year) and T3 (2 years) Table 3

Both three-dimensional studies reported volumetric measurements for the oropharyngeal airway and the hypopharyngeal airway as an effect of mandibular setback procedures. For airway changes between T0 and T1, Shin et al. (2015) reported a mean oropharyngeal airway reduction of $1,649.47$ mm³ and a mean hypopharyngeal airway reduction of $3,995.8$ mm³ compared to the preoperative status. Park et al. (2012) also noted a drastic reduction of airways between T0 and T1: a mean oropharyngeal airway reduction of $2,506.26$ mm³ and a mean hypopharyngeal airway reduction of $1,492.59$ mm³. Between T1 and T2, Shin et al. (2015) reported further reductions, with a mean oropharyngeal airway reduction of $1,438.73$ mm³ and a mean hypopharyngeal airway reduction of $1,623.34$ mm³. However, Park et al. (2012) noted increases in both airway measurements (232.09 mm³ for the oropharyngeal airway and 883.94 mm³ for the hypopharyngeal airway) rather than reductions, contradicting the findings of Shin et al. (2015). Between T2 and T3, Shin et al. (2015) reported increases rather than reductions, with a mean oropharyngeal airway increase of

1,324.52 mm³ and a mean hypopharyngeal airway increase of 1,754.68 mm³.

4. Discussion

The key findings of this systematic review of longitudinal skeletal and airway changes after mandibular setback procedures were as follows:

1. Skeletal relapses in all included studies were reported to be statistically insignificant.
2. Airway measurements for all included studies indicated significant reduction in the early postoperative period.
3. Two-dimensional studies generally reported an airway increase at postoperative 12 months when compared to postoperative 1–6 months.
4. The two three-dimensional studies disagreed on the direction of airway changes at postoperative 1 to 1.4 years when compared to postoperative 4–6 months.

The aim of this study was to review longitudinal skeletal and airway changes after mandibular setback procedures. Several studies have been undertaken to investigate the effect of mandibular setback osteotomy on airway size. However, the heterogeneity of assessment methods, variable assessment criteria, incomplete reporting of outcomes, and variable follow-up periods lead to difficulty in interpreting and comparing results across all studies. Reviewed studies were varied in terms of the points used to assess the airway, the assessment technique used, the amount of mandibular setback, and the patients' age and gender.

In the current review, skeletal relapses in all included studies were reported to be statistically insignificant. Similarly, Saitoh et al. reported non-significant changes of the anteroposterior mandibular position in the long-term follow-up period (Saitoh, 2004). Skeletal relapse is a frequent complication after orthognathic surgery (Gu et al., 2000). Mobarak et al. reported the incidence of skeletal relapse from mandibular setback at the B-point to be 19% after 3 years' follow-up, with most of the relapse (72%) taking place during the first 6 months after setback surgery (Mobarak et al., 2000). Several factors have been proposed as causes of mandibular relapse. Hyoid position and suprahyoid musculature might have an effect on skeletal relapse after mandibular setback. Gu et al. (2000) reported that the tendency of the mandible to relapse might be due the postoperative posterior and inferior position of hyoid bone. They proposed this might decrease the length and tension of suprahyoid muscles and create a force acting to return the muscle to its original resting position, which resulted in relapse of the mandible.

In this review, all included studies indicated a significant reduction in airway measurements in the early postoperative period. Similarly, many studies have reported airway reduction as an initial response to mandibular setback (Achilleos, 2000; Enacar et al., 1994; Hochban et al., 1996; Kawamata et al., 2000; Saitoh, 2004; Tselnik and Pogrel, 2000). Posterior and inferior movement of the hyoid bone has been associated with the airway reduction in several studies (Achilleos, 2000;

Kawamata et al., 2000). The tongue, moving along with the hyoid bone, may be the cause of restriction of the airway space (Enacar et al., 1994).

Long-term airway changes after mandibular setback remain controversial. Enacar et al. (1994) reported that narrowing of the hypopharyngeal airway could be permanent. Kawamata et al. (2000) performed a three-dimensional evaluation of morphologic changes after mandibular setback and found that the diminished airway did not indicate recovery after 1 year follow-up. In contrast to the results of the studies included in this review, that study indicated some recovery of the airway space.

In the current review, the two-dimensional studies generally reported airway increase at postoperative 12 months when compared to postoperative 1–6 months, yet the airway had not fully recovered. Hochban et al. (1996) reported reduction of the airway after mandibular setback procedures, followed by recovery after the 1 year follow-up period. Initial reduction of the airway, followed by recovery during the follow-up period, might be affected by the position of the hyoid bone. According to Gu et al., (2000) the hyoid bone tends to return to its preoperative position but never regains its original location.

In three-dimensional studies included in this review, contradictory results appeared regarding airway changes at postoperative 1–1.4 years compared to postoperative 4–6 months. In a recent review, Park et al. reported a slight increase in airway volume after a 1 year follow-up (2012). In contrast, Shin et al. (2015) reported a progressive reduction in airway volume after 1 year postoperatively. Their study reported that the hyoid bone did not return to its original position until 2 years postoperatively, in contrast to other studies reporting that hyoid return to its original position after 1 year (Tselnik and Pogrel, 2000; Liukkonen et al., 2002).

5. Conclusion

This systematic review found no statistically significant skeletal relapse after mandibular setback orthognathic procedures, but did find statistically significant airway reduction in the early postoperative period. Two-dimensional radiography noted a small airway increase over the first postoperative year. However, such a finding was not consistent in studies using three-dimensional imaging with volumetric analysis of airway change. We recommend more prospective studies with standardized follow-up periods and measurement landmarks. These standardizations are required to effectively observe long-term airway changes in relation to skeletal changes in class III patients after mandibular setback surgery.

CRedit authorship contribution statement

Mohammed A. AlZayer: Conceptualization, Methodology, Writing - original draft, Writing - review & editing. **Yiu Yan Leung:** Writing - review & editing, Supervision.

Declaration of Competing Interest

The authors declare that they have no known competing financial interests or personal relationships that could have appeared to influence the work reported in this paper.

Acknowledgments

This research did not receive any specific grant from funding agencies in the public, commercial, or not-for-profit sectors.

References

- Achilleos, S., 2000. Surgical mandibular setback and changes in uvuloglossopharyngeal morphology and head posture: a short- and long-term cephalometric study in males. *European J. Orthodontics*. <https://doi.org/10.1093/ejo/22.4.383>.
- Becker, O.E., Avelar, R.L., Göelzer, J.G., do Nascimento Dolzan, A., Júnior, O.L., De Oliveira, R.B., 2012. Pharyngeal airway changes in class III patients treated with double jaw orthognathic surgery—maxillary advancement and mandibular setback. *J. Oral Maxillofacial Surgery*. <https://doi.org/10.1016/j.joms.2012.07.052>.
- Efendiyeva, R., Aydemir, H., Karasu, H., Toygar-Memikoğlu, U., 2014. Pharyngeal airway space, hyoid bone position, and head posture after bimaxillary orthognathic surgery in Class III patients: long-term evaluation. *Angle Orthod.* 84, 773–781.
- Eggensperger, N., Smolka, W., Iizuka, T., 2005. Long-term changes of hyoid bone position and pharyngeal airway size following mandibular setback by sagittal split ramus osteotomy. *J. Craniofacial Surg.* 33, 111–117.
- Enacar, A., Aksoy, A.U., Sençift, Y., Haydar, B., Aras, K., 1994. Changes in hypopharyngeal airway space and in tongue and hyoid bone positions following the surgical correction of mandibular prognathism. *Int. J. Adult Orthodon. Orthognath. Surg.* 9, 285–290.
- Gu, G., Gu, G., Nagata, J., Suto, M., Anraku, Y., Nakamura, K., Kuroe, K., Ito, G., 2000. Hyoid position, pharyngeal airway and head posture in relation to relapse after the mandibular setback in skeletal Class III. *Clin. Orthod. Res.* 3, 67–77.
- Hochban, W., Schürmann, R., Brandenburg, U., Conradt, R., 1996. Mandibular setback for surgical correction of mandibular hyperplasia—does it provoke sleep-related breathing disorders?. *Int. J. Oral Maxillofac. Surg.* 25, 333–338.
- Hwang, S., Chung, C.J., Choi, Y.-J., Huh, J.-K., Kim, K.-H., 2010. Changes of hyoid, tongue and pharyngeal airway after mandibular setback surgery by intraoral vertical ramus osteotomy. *Angle Orthod.* <https://doi.org/10.2319/040209-188.1>.
- Kawamata, A., Fujishita, M., Arijji, Y., Arijji, E., 2000. Three-dimensional computed tomographic evaluation of morphologic airway changes after mandibular setback osteotomy for prognathism. *Oral Surg. Oral Med. Oral Pathol. Oral Radiol. Endod.* 89, 278–287.
- Liukkonen, M., Vähätalo, K., Peltomäki, T., Tiekso, J., Happonen, R.-P., 2002. Effect of mandibular setback surgery on the posterior airway size. *Int. J. Adult Orthodon. Orthognath. Surg.* 17, 41–46.
- Mobarak, K.A., Krogstad, O., Espeland, L., Lyberg, T., 2000. Long-term stability of mandibular setback surgery: a follow-up of 80 bilateral sagittal split osteotomy patients. *Int. J. Adult Orthodon. Orthognath. Surg.* 15, 83–95.
- Park, S.-B., Kim, Y.-I., Son, W.-S., Hwang, D.-S., Cho, B.-H., 2012. Cone-beam computed tomography evaluation of short- and long-term airway change and stability after orthognathic surgery in patients with class III skeletal deformities: Bimaxillary surgery and mandibular setback surgery. *Int. J. Oral Maxillofac. Surg.* 41 (1), 87–93.
- Saitoh, K., 2004. Long-term changes in pharyngeal airway morphology after mandibular setback surgery. *Am. J. Orthod. Dentofacial Orthop.* 125, 556–561.
- Samman, N., Tang, S.S., Xia, J., 2002. Cephalometric study of the upper airway in surgically corrected class III skeletal deformity. *Int. J. Adult Orthodon. Orthognath. Surg.* 17, 180–190.
- Shin, J.-H., Kim, M.-A., Park, I.-Y., Park, Y.-H., 2015. A 2-year follow-up of changes after bimaxillary surgery in patients with mandibular prognathism: 3-dimensional analysis of pharyngeal airway volume and hyoid bone position. *J. Oral Maxillofac. Surg.* <https://doi.org/10.1016/j.joms.2014.10.009>.
- Tselnik, M., Pogrel, M.A., 2000. Assessment of the pharyngeal airway space after mandibular setback surgery. *J. Oral Maxillofac. Surg.* 58, 282–5; discussion 285–7.