



Case Report

Cervical spine computed tomography motion artifact mimicking spine injury in a patient with severe head injury

Abiodun Idowu Okunlola¹, Paul Olukayode Abiola¹, Olakunle Fatai Babalola¹, Chijioke Cosmas Achebe²

Departments of ¹Surgery and ²Radiology, Federal Teaching Hospital, Ido Ekiti/Afe Babalola University, Ado Ekiti, Nigeria.

E-mail: *Abiodun Idowu Okunlola - okunlolaai@abuad.edu.ng; Paul Olukayode Abiola - abiolapaul@rocketmail.com; Olakunle Fatai Babalola - olakunlebabs@yahoo.com; Chijioke Cosmas Achebe - achikky26@gmail.com



*Corresponding author:

Abiodun Idowu Okunlola,
Department of Surgery, Federal
Teaching Hospital, Ido Ekiti/
Afe Babalola University, Ado
Ekiti, Nigeria.

okunlolaai@abuad.edu.ng

Received : 05 May 2021

Accepted : 09 July 2021

Published : 03 August 2021

DOI

10.25259/SNI_449_2021

Quick Response Code:



ABSTRACT

Background: Craniocervical CT scan is an essential part of the routine evaluation of patient with moderate and severe head injury to rule out associated cervical spine injury. Computed tomography motion artifacts can affect clinical decision making. The aim of this report is to emphasize that motion artifact still exists despite advance in technology and this can pose clinical challenge.

Case Description: A 20-year-old man presented to our facility with severe head injury GCS 8. Craniocervical CT scan reported 75% C3 on C4 anterior subluxation and urgent spinal stabilization surgery was recommended. A static lateral cervical spine X-ray showed normal bony alignment. He was successfully managed and dynamic studies after recovery were normal.

Conclusion: Cervical spine CT motion artifact can lead to unneeded surgery but routine clinical evaluation and cervical spine static and dynamic X-rays may be sufficient to resolve the puzzle.

Keywords: Cervical spine X-ray, Cervical spine, Computed tomography, Head injury, Motion artifact

INTRODUCTION

Evaluation of patient with severe traumatic brain injury is not complete until cervical spine is screened.^[6] History and physical examinations are complemented by the use of diagnostic imaging for optimal patient evaluation.^[1] Traumatic brain injury is associated with cervical spine injury and patient evaluation usually involved screening of the cervical spine.^[4] There is tremendous evolution of the technologies involved in neuroimaging.^[2]

Routine spine X-ray has been replaced with more sophisticated computed tomography in evaluation of spine trauma.^[6,10] The latest technology of CT scanning is not without its own demerit which includes various artifacts which may affect clinical decision making.^[2,8,11] In such circumstances, simple static radiograph of the spine may be adequate to resolve the puzzles.^[1] The objective of this review is to document clinical challenges posed by the cervical spine CT artifact in an unconscious patient and to emphasize that motion artifact still exists despite advance in technology and this can pose clinical challenge.

This is an open-access article distributed under the terms of the Creative Commons Attribution-Non Commercial-Share Alike 4.0 License, which allows others to remix, tweak, and build upon the work non-commercially, as long as the author is credited and the new creations are licensed under the identical terms.

©2021 Published by Scientific Scholar on behalf of Surgical Neurology International

CASE REPORT

A 20-year-old man brought to our facility unconscious following rider motorcycle accident. Examination revealed a young man unconscious with Glasgow Coma Score of 8. Both pupils were 3 mm and briskly reactive to light. He moves all limbs spontaneously. There was left parieto-occipital scalp abrasion. Examination of other systems was normal.

Clinical diagnosis of severe head injury was made. Cranial CT scan showed left parietal skull fracture with underlying punctate cerebral contusions. Cervical spine CT scan [Figure 1] reported as 75% C3 on C4 anterior subluxation and suggested need for urgent spinal fixation. A review of the cervical spine CT scan showed double shadow which suggested CT motion artifact and 75% C3 on C4 anterior subluxation was not compatible with spontaneous respiration and limbs movement in the patient which necessitated request for supine lateral x-ray [Figure 2] of the cervical spine on posttraumatic day 2 which showed no fracture or malalignment. He was maintained on rigid neck collar. He had progressive neurological improvement. Neurological status improved to GCS 15 on posttraumatic day 18 with power Grade 5 in all extremities muscle groups. He had erect cervical spine flexion and extension X-rays studies [Figure 3] on posttraumatic day 18 which showed normal bone alignment without radiological instability. The rigid neck collar was removed and he was discharged home. Six-month posttrauma follow-up review showed no neurological deficit and he has resumed normal activities.

DISCUSSION

The role of routine history and physical examination in the management of patient with traumatic brain injury cannot be replaced but complimented by the neuroimaging facilities.^[1] It is mandatory to clear cervical spine in the setting of severe traumatic brain injury.^[2] The easiest method has been to extend the cranial CT scan to craniocervical CT scan.^[10] It is very fast, easy, and reliable but cervical spine CT artifact can mimic spinal instability thereby subjecting the patient to the risk of unneeded surgery or diagnostic puzzle to the clinicians.^[7]

The impact of CT artifact on the patient may include unneeded surgery, transfer to another facility and delay in critical decision making due to fear of secondary cervical spinal cord injury.^[1,6] This may be a diagnostic puzzle for both the radiologist and attending clinicians. The index patient with severe traumatic brain injury and the radiologist reported 75% C3 on C4 anterior subluxation caused initial suggestion of urgent need for spinal stabilization. A further critical review of the cervical spine CT bone window showed double shadow with the reported subluxation. The findings necessitated plain radiograph which was normal. Computed tomography has offered better resolution and anatomical definition of the spine but there is a baseline role of the

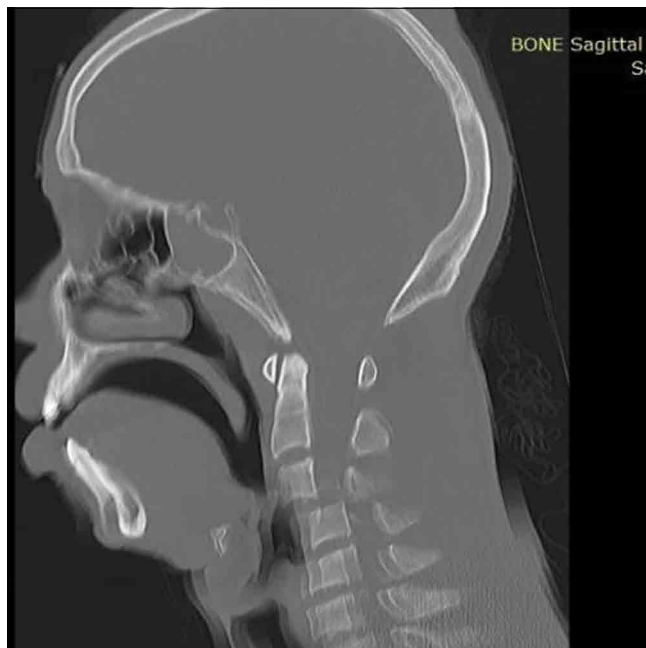

Figure 1: Cervical spine CT sagittal bone window showing C3 on C4 anterior subluxation.

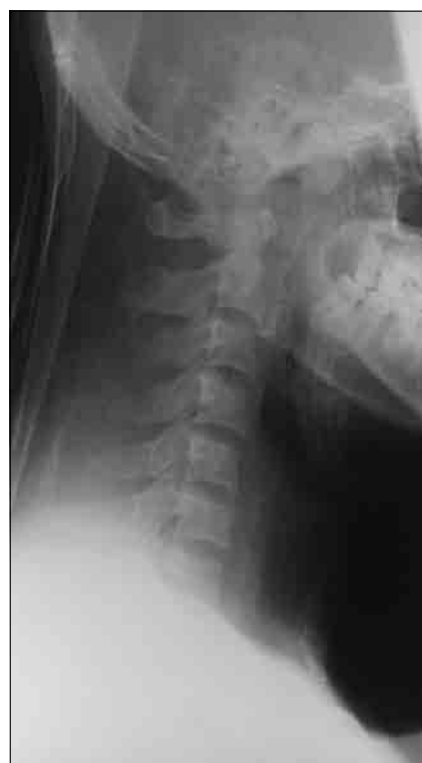

Figure 2: Lateral cervical spine X-ray taken with rigid neck collar 2nd day posttrauma in intensive care unit.

routine plain spine X-ray which should be explored before critical decision making to prevent the stress of unnecessary surgery or transfer.^[7]

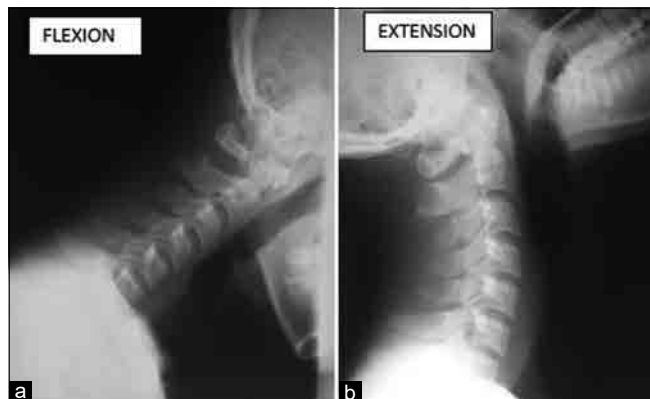


Figure 3: Lateral cervical spine (a) flexion and (b) extension X-ray taking on the 18th day posttrauma.

Static and dynamic cervical spine radiograph with or without cervical spine MRI is usually adequate to exclude cervical spine CT artifact mimicking cervical spine injury.^[9] Repeat cervical spine CT scan is an option but it is relatively more expensive and poses higher radiation risk than cervical spine radiograph, and the artifact may be repeated in a restless patient.^[3,5]

CONCLUSION

Cervical spine CT artifact can lead to unneeded surgery but routine clinical evaluation and supine static cervical spine X-rays may be sufficient to resolve the puzzle.

Declaration of patient consent

The authors certify that they have obtained all appropriate patient consent.

Financial support and sponsorship

Nil.

Conflicts of interest

There are no conflicts of interest.

REFERENCES

1. Bastos MD, Lee EY, Strauss KJ, Zurakowski D, Tracy DA, Boisselle PM. Motion artifact on high-resolution CT images of pediatric patients: Comparison of volumetric and axial CT methods. *Am J Roentgenol* 2009;193:1414-8.
2. Boas FE, Fleischmann D. CT artifacts: Causes and reduction techniques. *Imaging Med* 2012;4:229-40.
3. Ertel AE, Robinson BR, Eckman MH. Cost-effectiveness of cervical spine clearance interventions with litigation and long-term-care implications in obtunded adult patients following blunt injury. *J Trauma Acute Care Surg* 2016;81:897-904.
4. Holly L, Kelly D, Counelis G, Blinman T, McArthur D, Cryer H. Cervical spine trauma associated with moderate and severe head injury: Incidence, risk factors, and injury characteristics. *J Neurosurg* 2002;96:285-91.
5. Holmes JE, Akkinipalli R. Computed tomography versus plain radiography to screen for cervical spine injury: A meta-analysis. *J Trauma* 2005;58:902-5.
6. Nazir M, Khan SA, Raja RA, Bhatti SN, Ahmed E. Cervical spinal injuries in moderate to severe head injuries. *J Ayub Med Coll Abbottabad* 2012;24:100-2.
7. Patel SH, Moore TA. Motion artifact on computed tomography scan suggesting an unstable 3-column spine injury: Case report of a "near miss" root cause of unneeded surgery. *Patient Saf Surg* 2013;7:35.
8. Ritchie CJ, Crawford CR, Godwin JD, King KF, Kim Y. Correction of computed tomography motion artifacts using pixel-specific back-projection. *IEEE Trans Med Imaging* 1996;15:333-42.
9. Sugimoto Y, Ito Y, Shiozaki Y, Shimokawa T, Mazaki T. Motion induced artifact mimicking cervical dens fracture on the CT Scan: A case report. *Asian Spine J* 2012;6:216-8.
10. Vahldiek JL, Thieme S, Hamm B, Niehues SM. Incidence of combined cranial and cervical spine injuries in patients with blunt minor trauma: Are combined CT examinations of the head and cervical spine justified? *Acta Radiol* 2016;58:856-60.
11. Zhang D, Marques L, Serafim A, Cabral J. Computed tomography artifacts mimicking Type II odontoid fractures: Report of two cases and review of the literature. *Interdiscip Neurosurg Adv Tech Case Manag* 2020;19:1-5.

How to cite this article: Okunlola AI, Abiola PO, Babalola OF, Achebe CC. Cervical spine computed tomography motion artifact mimicking spine injury in a patient with severe head injury. *Surg Neurol Int* 2021;12:390.