



Case report

Life Threatening haemoptysis in primary lung cancer-signet ring cell carcinoma

Shamsuddin Anwar^{*}, Sudeep Acharya, Dany Elsayegh, Alisa Sokoloff, Maryam Rehan

Staten Island University Hospital, Northwell Health, United States

ARTICLE INFO

Keywords:

Lung cancer
Critical care
Oncology

ABSTRACT

Primary signet ring cell carcinoma of the lung is a rare non-small cell carcinoma of the lung with extremely aggressive features and poor prognosis. The diagnosis mainly required tissue biopsy with immunohistochemical analysis and gene mutation studies. We describe a unique case of primary signet ring cell carcinoma of the lung presenting with life threatening haemoptysis along with literature review of prognosis and management of this rare clinical entity.

1. Case description

A 57-year old male with pertinent past medical history of diabetes and hypertension presented to the emergency department with active haemoptysis. Patient had relevant social history of 44 pack years of smoking. He initially developed mild haemoptysis hence was evaluated by his primary care physician one month ago. The initial chest X-ray (Fig. 1) showed right sided lung mass suspicious of malignancy prompting the patient to undergo Positron Emission Tomographic (PET) scan which re-demonstrated right sided lung mass along with diffuse mediastinal & cervical lymphadenopathy and adrenal gland metastasis (Fig. 2).

The patient was scheduled for biopsy of the mass for identification of the malignancy however, the haemoptysis worsened to the point that he started actively throwing up blood clots from his mouth prompting his visit to the emergency department. The patient remained stable hemodynamically despite having active haemoptysis of >150 mL (ml) in 24 hours. He was emergently evaluated by the pulmonary and critical team and underwent bronchoscopy with argon plasma coagulation (APC) cauterization to control the bleeding and biopsies were taken. As part of staging of malignancy, he also underwent magnetic resonance imaging (MRI) of the brain which showed a punctuate right cerebellar lesion with mild edema consistent for metastasis (Fig. 3).

The initial pathology of the lung mass suggested signet cell features so the patient underwent esophagogastroduodenoscopy (EGD) to exclude gastric cancer as the primary malignancy. The EGD demonstrated normal mucosa with mild non-erosive gastritis, thereby establishing the diagnosis of primary signet cell adenocarcinoma of the lung.

The immunohistochemical staining showed neoplastic cells positive for CK7, TTF-1 and mucicarmine while CK20, p63, CK 5&6 were negative. The tumor proportion score (TPS) for PD-L1 protein expression was 0%.

The patient was hemodynamically stabilized with resolution of haemoptysis after bronchoscopy and cauterization. As the lesion in the brain was very small and patient remained asymptomatic, radiation oncology recommended no further intervention at this time with short tapered course of high dose steroids. Next generation sequencing (NGS) studies were sent for further characterization of the adenocarcinoma. A total of seven disease relevant genes with no alterations resulted, which included ALK, BRAF, EGFR, ERBB2, MET, RET and ROS1. No micro-satellite instability was noted. As no driver mutations were noted in the NGS, patient was decided to be initiated on platinum based (carboplatin) and paclitaxel intravenous chemotherapy every week for three weeks with one week off between each cycle. As biomarker K-ras G12 C mutation on genomic profiling was noted immune check point inhibitor pembrolizumab has been added to the therapy. The patient is currently being followed closely with haematology oncology for clinical response to chemotherapy.

2. Discussion

Primary signet ring cell carcinoma (SRCC) is a rare subtype of lung adenocarcinoma with often poorly differentiated cells. More commonly SRCC in the lung is seen as a metastatic lesion with primary cancer arising from different organs such as stomach, bladder, prostate and breast [1]. According to one literature review, the rarity of SRCC can be estimated as approximately 0.5% of the all the adenocarcinomas of the

^{*} Corresponding author.

E-mail address: Shamsduhs15@gmail.com (S. Anwar).

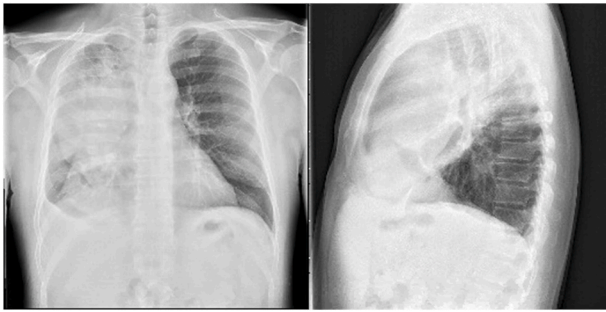


Fig. 1. Chest X-ray.

lung [2]. The median age of individuals affected with SRCC was noted to be 64 years, slightly lower as compared to the age of overall population affected with lung adenocarcinomas (median age 67). The study also suggested that approximately 49.2% of the SRCC patients were already in Stage IV at the time of presentation as compared to 36.8 % in overall lung adenocarcinoma and decreased overall survival (6 months vs 10 months, respectively) suggesting highly aggressive nature. The primary site of malignancy in signet cell carcinoma has been noted as an independent prognostic factor with 5-year survival rate of primary SRCC of the lung noted to be approximately 11% [3].

The patients may present with subtle and non-specific symptoms of weight loss, cough, chest pain, difficulty in breathing and haemoptysis. Life threatening haemoptysis as described in our clinical scenario was a unique presentation of the SRCC. Like all cancers, the definitive diagnosis of primary lung SRCC is made by tissue biopsy with histopathological examination and immunohistochemical staining. On histology, the cells demonstrate clear cytoplasm with peripherally displaced hyperchromatic nuclei with distinct cell borders [4]. The immunohistochemical staining profile for primary lung SRCC variably features positive markers such as TTF-1, CK-7, p63 and mucicarmine with negative for CK20, CK 5/6, chromogranin, synaptophysin and vimentin [5,6].

In order to determine the lung being the primary origin for SRCC, it is also important to exclude the possibility of metastatic with primary origin for SRCC elsewhere such as stomach, breast and prostate. Our patient failed to demonstrate any active malignancy of initial PET scan in other organ systems and underwent EGD with biopsies to rule out gastric origin of cancer. This conclusion is further supported with immunohistochemistry (positive CK7 and TTF-1 and negative CK20) which suggests primarily a lung cancer [7]. Fluorescence in situ

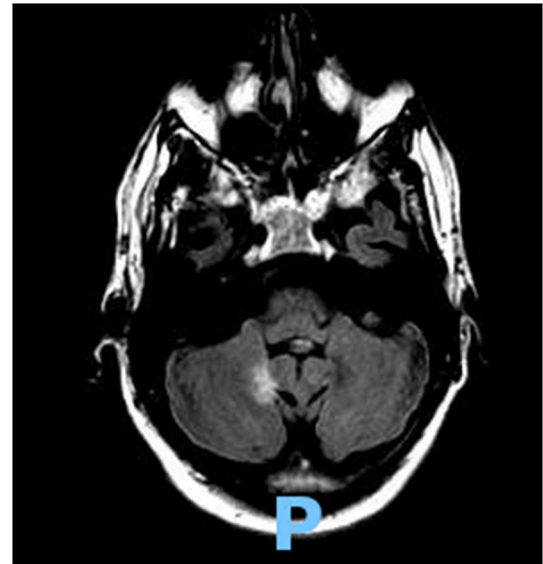

Fig. 3. MRI of the brain.

hybridization (FISH) in primary lung SRCC may often demonstrate ALK gene translocation with EML4-ALK fusion and absence of EGFR and KRAS mutations. These mutations may have a therapeutic significance as tumors with EML4-ALK translocation have shown to some response to ALK inhibitor Crizotinib and K-ras with immune check point inhibitors like Pembrolizumab [8–10]. Utilization of next generation sequence to check for driver mutations specially in advanced non-small cell lung carcinoma has increasingly become a standard part of diagnostic work-up. It enables in checking for various driver mutations including EGFR, ALK, ROS-1 and provides useful information in choosing chemotherapy as well as median survival age [11]. Our patient failed to show any such driver mutation on next generation sequencing. In oncologic literature chemotherapeutic agents such as platinum based (cisplatin) and microtubule assembly destabilizer (docetaxel) also have been used with benefit to some extent however the prognosis of primary lung SRCC remains poor [12].

3. Conclusion

Primary signet ring cell carcinoma of the lung is a rare tumor which has been described to have very aggressive natural course and poor

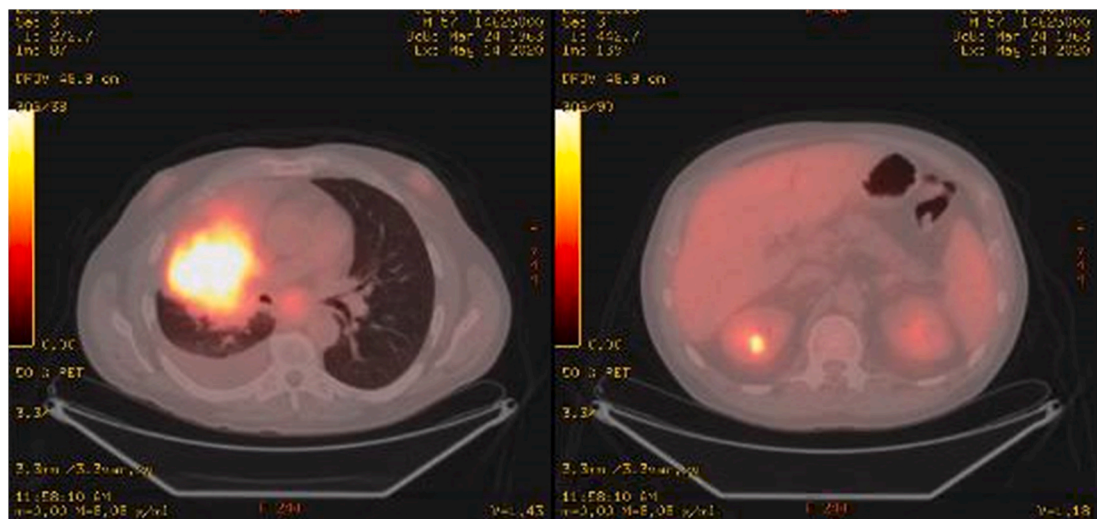


Fig. 2. Pet scan showing right lung mass and adrenal gland metastasis.

outcomes as compared to other tumors of the lungs. Its diagnosis needs a thorough investigation to correctly differentiate a primary lung SRCC from metastatic SRCC with the utilization of appropriate immunohistochemical staining, imaging studies and identifying gene mutations. More data is required to assess the efficacy and survival benefits of various treatment options.

CRediT authorship contribution statement

Shamsuddin Anwar: Writing - original draft. **Sudeep Acharya:** Writing - original draft. **Dany Elsayegh:** Writing - original draft. **Alisa Sokoloff:** Writing - original draft. **Maryam Rehan:** Writing - original draft.

Declaration of competing interest

I am submitting a manuscript for publication entitled 'LIFE THREATENING HAEMOPTYSIS IN PRIMARY LUNG CANCER-SIGNET RING CELL CARCINOMA' As a corresponding author, I would like to declare that I know of no conflict of interest for this case report, and none of the authors have received any financial support for this work that could have influenced its outcome. As a corresponding author, I confirm that the manuscript has been read and approved by all the named co-authors (Shamsuddin Anwar M.D Sudeep Acharya M.D, Dany ElSayed M.D, Alisa Sokoloff M.D, Maryam Rehan M.D). Feel free to contact me on my email for any questions or concerns.

References

- [1] S. Livieratos, J.K. Smith, E. Fatakhov, C.F. Koch Jr., Primary signet ring cell carcinoma of the lung: a rare subtype, *BMJ Case Rep.* 2013 (2013), <https://doi.org/10.1136/bcr-2013-200111> bcr2013200111. Published 2013 Sep. 20.

- [2] S.H. Ou, A. Ziogas, J.A. Zell, Primary signet-ring carcinoma (SRC) of the lung: a population-based epidemiologic study of 262 cases with comparison to adenocarcinoma of the lung, *J. Thorac. Oncol.* 5 (4) (2010) 420–427, <https://doi.org/10.1097/JTO.0b013e3181ce3b93>.
- [3] S.G. Wu, X.T. Chen, W.W. Zhang, et al., Survival in signet ring cell carcinoma varies based on primary tumor location: a Surveillance, Epidemiology, and End Results database analysis, *Expet Rev. Gastroenterol. Hepatol.* 12 (2) (2018) 209–214, <https://doi.org/10.1080/17474124.2018.1416291>.
- [4] C.Y. Castro, C.A. Moran, D.G. Flieder, S. Suster, Primary signet ring cell adenocarcinomas of the lung: a clinicopathological study of 15 cases, *Histopathology* 39 (4) (2001) 397–401, <https://doi.org/10.1046/j.1365-2559.2001.01224.x>.
- [5] J.M. Boland, J.A. Wampfler, J.S. Jang, et al., Pulmonary adenocarcinoma with signet ring cell features: a comprehensive study from 3 distinct patient cohorts, *Am. J. Surg. Pathol.* 38 (12) (2014) 1681–1688, <https://doi.org/10.1097/PAS.0000000000000280>.
- [6] T. Terada, Primary signet-ring cell carcinoma of the lung: a case report with an immunohistochemical study, *Int. J. Clin. Exp. Pathol.* 5 (2) (2012) 171–174.
- [7] S. Danzinger, W.J. Köstler, M. Funovics, et al., Signet ring cell carcinoma of the lung: a diagnostic pitfall in pregnancy, *Case Rep Obstet Gynecol* 2019 (2019), <https://doi.org/10.1155/2019/9461579>, 9461579. Published 2019 Jun 12.
- [8] A. Yoshida, K. Tsuta, S. Watanabe, et al., Frequent ALK rearrangement and TTF-1/p63 co-expression in lung adenocarcinoma with signet-ring cell component, *Lung Canc.* 72 (3) (2011) 309–315, <https://doi.org/10.1016/j.lungcan.2010.09.013>.
- [9] Y.Q. Hao, H.P. Tang, H.Y. Liu, Primary signet-ring cell carcinoma of the lung treated with crizotinib: a case report, *Oncol Lett* 9 (5) (2015) 2205–2207, <https://doi.org/10.3892/ol.2015.3003>.
- [10] H. Adderley, F.H. Blackhall, C.R. Lindsay, KRAS-mutant non-small cell lung cancer: converging small molecules and immune checkpoint inhibition, *EBioMedicine* 41 (2019) 711–716, <https://doi.org/10.1016/j.ebiom.2019.02.049>.
- [11] M. Takeda, K. Sakai, T. Takahama, K. Fukuoka, K. Nakagawa, K. Nishio, New era for next-generation sequencing in Japan, *Cancers* 11 (6) (2019) 742, <https://doi.org/10.3390/cancers11060742>.
- [12] O. Kocas, F. Selcukbiricik, A. Bilici, et al., Primary signet ring cell carcinoma of the lung with cerebellar metastasis showing full response to Cisplatin and docetaxel therapy, *Case Rep Oncol Med* 2014 (2014), 968723, <https://doi.org/10.1155/2014/968723>.